

# Duraplasty using amniotic membrane versus temporal muscle fascia: A clinical comparative study

*by* Dr Purwati

---

**Submission date:** 03-Feb-2020 11:11AM (UTC+0800)

**Submission ID:** 1250393672

**File name:** 1.\_Duraplasty\_using\_amniotic\_membrane.pdf (903.06K)

**Word count:** 3841

**Character count:** 20462



Contents lists available at ScienceDirect

# Journal of Clinical Neuroscience

journal homepage: [www.elsevier.com/locate/jocn](http://www.elsevier.com/locate/jocn)



Tools and techniques

## 18 Duraplasty using amniotic membrane versus temporal muscle fascia: A clinical comparative study



Agus Turchan<sup>a,d</sup>, Taufiq Fatchur Rochman<sup>b</sup>, Arie Ibrahim<sup>b</sup>, Dyah Fauziah<sup>c</sup>, Joni Wahyuhadi<sup>a,d</sup>,  
M. Arifin Parenrengi<sup>a,d</sup>, Asra Al Fauzi<sup>a,d,\*</sup>, Erliano Sufarnap<sup>d</sup>, Abdul Hafid Bajamal<sup>a,d</sup>, Ferdiansyah<sup>e</sup>,  
Heri Suroto<sup>e</sup>, Purwati<sup>e</sup>, Fedik Abdul Rantam<sup>f</sup>, Adanti Wido Paramadini<sup>d</sup>, Christianto Benjamin Lumenta<sup>g</sup>

<sup>a</sup> Department of Neurosurgery, Universitas Airlangga, Dr. Soetomo General Hospital, Surabaya, Indonesia  
<sup>b</sup> Department of Neurosurgery, A. Wahidin Sjahrani General Hospital, Mulawarman University, Samarinda, Indonesia  
<sup>c</sup> Department of Pathology Anatomy, Universitas Airlangga, Dr. Soetomo General Hospital, Surabaya, Indonesia  
<sup>d</sup> Surabaya Neuroscience Institute, Surabaya, Indonesia  
<sup>e</sup> Cell and Tissue Bank, Dr. Soetomo General Hospital, Surabaya, Indonesia  
<sup>f</sup> Stem Cell Research and Development Center, Universitas Airlangga, Surabaya, Indonesia  
<sup>g</sup> Department of Neurosurgery, Bogenhausen Academic Teaching Hospital, Technical University of Munich, Germany

### 21 ARTICLE INFO

Article history:  
Received 18 July 2017  
Accepted 18 January 2018

Keywords:  
Duraplasty  
Amniotic membrane  
Fascia  
Comparison

### ABSTRACT

In the field of neurosurgery, often the dura mater cannot be sutured, and consequently, it requires a duraplasty procedure using a dural fascial graft. Since 1890, various materials have been researched as dura mater substitutes. Amniotic membrane, for example, is suitable as a dural graft material and has been used in neurosurgery since 2012. However, there has been little research on human patient's dural healing after the use of amniotic membrane in their duraplasty procedure. To address this gap, a clinical experimental study was undertaken to evaluate the human dural healing of 16 patients who had undergone duraplasty in decompressive craniectomy surgery at Dr. Soetomo General Hospital, Surabaya. The amniotic membrane allograft, was sutured to cover the dural defect for eight randomly chosen patients (Group I). The fascial autograft from the temporal muscle had been applied for eight other patients (Group II). Between 10 and 20 weeks after surgery, the patients underwent cranioplasty and dural healing evaluation by cerebrospinal fluid (CSF) leakage testing through the edge of the dural defect. The fibrocyte infiltration around the edge of the dural defect was examined histologically. Statistical analysis, using an independent *t*-test, was performed with a confidence interval of 95%. The results of the clinical and histological analysis suggest that an amniotic membrane graft was able to provide watertight dural closure and adequate fibrocyte infiltration comparable with that provided by temporalis muscle fascia. This study shows that using an amniotic membrane in neurosurgery has a potential advantage over an alternative dural healing.

8  
© 2018 Elsevier Ltd. All rights reserved.

### 1. Introduction

During cranial neurosurgery, duraplasty procedures need to be performed for the following situations: 1) a missing or removed part of the dura mater; 2) dura mater fistula repair; or 3) the enlargement of the dura mater or intracranial compartment [1]. These cases require watertight dural closure to minimize the risk of cerebrospinal fluid (CSF) fistula, infection, herniation, brain cortex scarring, and adhesions [2].

<sup>3</sup>  
\* Corresponding author at: Department of Neurosurgery, Universitas Airlangga, Dr. Soetomo General Hospital, Surabaya, Indonesia.  
E-mail address: [asra-a-f-11@pasca.unair.ac.id](mailto:asra-a-f-11@pasca.unair.ac.id) (A.A. Fauzi).

Since 1890, various materials have been researched for dura mater grafting, from metal sheets and autologous/homologous body tissues to allogeneic tissues and biosynthetic materials; however, exploration of materials continues [3]. Ideally, the material for the dura mater substitute should be inert, nontoxic, non-carcinogenic, water-resistant, able to maintain stitches without sticking to the cortex, easy to obtain, sterile, and inexpensive [4].

Generally, a synthetic graft material is rejected by a patient's body due to a local tissue inflammatory reaction marked by irritation of the cortex underneath the brain, excessive scar tissue formation, meningitis, and bleeding [5]. In addition, a synthetic graft is relatively expensive compared with autologous or allogeneic graft. Cadaveric human dura mater for graft material is no

longer used as an alternative because of its association with infectious and carried prion diseases, such as Creutzfeldt-Jakob disease [6]. However, using graft materials from autologous body tissues or autografts, such as the pericranium, fascia lata, and temporalis muscle fascia, does not pose a risk of infectious disease yet does require excision [3]. The ideal dural graft should be unite with native dura but not adhere to brain, degradable and replaced with surrounding tissue while providing an adequate patch until then [7].

The amniotic membrane has been used in surgery since 1910, especially in plastic and eye surgery, due to its ability to stimulate the epithelization process, inhibit excessive fibrosis, inhibit inflammation and angiogenesis, decrease the immune response, and provide antimicrobial and antiviral effects [8]. This material is also effective as a wound dressing, moistening the wound surface and thereby accelerating the wound-healing process [8]. During this process, amniotic membrane reduces the pain score in adults, quiets distressed children, and provides a mechanical barrier to microbial invasion [8].

We performed this study to examine, through a clinical and histological review, the healing results of human duraplasty using an amniotic membrane graft.

## 2. Methods

This study received legal and ethical clearance from the local medical research ethics committee of Dr. Soetomo General Hospital, Surabaya, Indonesia, following the regulatory guidelines of the country. Also, a research permit was obtained from the Research and Development Division of East Java, Province Government, Indonesia. Informed consent documents, details of the medical treatment, and other necessary approval documents were delivered to all patients involved in the study prior to its commencement. Informed consent was obtained from all the patients included in the study. The sample grouping was formed using a simple randomization method.

Inclusion criteria included an age of 15–60 years, moderate head injury, severe head injury, and spontaneous intracerebral hemorrhage cases. Exclusion criteria included malnutrition, diabetes mellitus, and infection.

## 3. Tools and materials

Duraplasty with amniotic membrane graft treatment required a basic procedure of craniotomy with general anesthesia. A microscope was used for histological examination. The study materials were temporal muscle fascia, which had been obtained from clinical study subjects, and a 10 × 10-cm 16 layers amniotic membrane allograft, which had been processed at the Tissue Bank Unit at the Dr. Soetomo General Hospital.

## 4. Preparation of amniotic membrane

Fresh placentas from normal baby deliveries were collected aseptically in the childbirth or operating room. Placentas that were contaminated by meconium were excluded. A suitable placenta was then placed in a sterile container of physiological NaCl solution and antibiotic solution. The amniotic membrane was then separated from the placenta, washed with physiological NaCl solution, and finally stored at a temperature of 4 °C. The sample could not be stored for more than four days before processing.

The entire process was performed under sterile conditions, and each step of the process was noted in logbooks. At the end of preparation, tissue samples were taken from the remaining leaching solution of NaCl for microbiological examination before the packaging process.

Subsequently, the amniotic membrane was soaked in a solution of 0.05% sodium hypochlorite for 10 min; therefore, the pH solu-

tion was neutral. Next, the amniotic membrane was placed in a water bath shaker filled with sterile physiological NaCl solution kept at room temperature. The NaCl solution was replaced every 15 min for 2.5 h. A few drops of NaCl solution were taken for microbiological examination.

The amniotic membrane was washed, stretched, and placed on a sterile gauze pad, with the chorion side facing the screen before being cut into the desired size. This process was performed in a laminar airflow cabinet. The membrane was placed on a sterile tray and stored in a deep freezer for 24 h as part of a freeze-drying process. Before the process began, the drying room was cleaned with 70% alcohol and then cooled to a temperature of –40 °C. The freeze-drying was run for six hours until the water content of the amniotic membrane had reached approximately 6–7%. The membrane was sterilized using ethylene oxide to eliminate microorganism or bacteria.

The packaging process took place in the laminar airflow cabinet, using three layers of polyethylene plastic. A sealing process was performed using a vacuum sealer. A label was placed between the second and third layers and provided complete data on the graft material (graft type, batch number, number of donors, graft number, date of sterilization, sterilization type, expiration date, storage recommendations, and additional information).

## 5. Clinical study

Legal approval for the surgery and a research permit from each patient's family was obtained prior to the patient undergoing decompressive craniectomy surgery under general anesthesia. The average size of the craniotomy had to be at least 10 × 5 cm. After removing intracranial hematoma lesions, duraplasty was then performed with an average area of 5 × 2 cm. In the first treatment group, duraplasty was performed with an amniotic membrane graft. In the second group, duraplasty was performed with a temporalis muscle fascial graft. Each graft was stitched together on the edge of the dura with silk thread 4/0. The periosteum, muscle, and scalp were then closed layer by layer. The craniectomy bone flap was kept sterile in the Tissue Bank Unit at Dr. Soetomo General Hospital.

After 10–20 weeks, cranioplasty was performed using an autograft calvarian bone. The incision and dissection of the scalp, muscle, and periosteum were performed layer by layer so that the dura mater and graft could be identified by any sign of local infections, surgical site leaks, extra-dural fluid collections, and other local abnormalities. The dura and graft site were soaked in povidone-iodine, and then

10 ml of isotonic saline solution were injected into the subdural cavity using a 26 g needle. CSF leakage was then checked on the edge of the dural graft stitching. The disappearance of povidone-iodine swabs on the dura mater and the graft indicated CSF leakage. Once the checking was done, the dura mater and graft were flushed with sterile isotonic saline. The sample for histological analysis was obtained by cutting the edge of the dural graft suture into a size of 0.5 × 0.5 cm. Histological specimens were fixed with formalin. The edges of the defect and the dural graft were primarily stitched using silk thread 4/0. Autograft cranioplasty was performed using miniplate screw fixation. The periosteum, muscle, and skin were then closed layer by layer.

The treatment and control groups underwent cranioplasty and sampling of dura mater at 10–20 weeks (after decompressive craniectomy operations). The cranioplasty period differed due to variations in the length of post operative care for each research subjects, related to the severity of the intracranial pathology acquired, as well as the limitations in scheduling subsequent surgery for cranioplasty (Table 1).

**Table 1**

Patient data.

Specimen Identity	Gender	Age	Diagnosis	Pathology	GCS	GOS	Time
F7060099	L	24	Severe head injury	SDH	8	5	10w
F7060101	L	25	Severe head injury	SDH, ICH	7	4	13w
F7060107	L	26	Moderate head injury	SDH, ICH	12	5	11w
F7060094	L	27	Severe head injury	SDH	8	5	10w
F7060105	P	31	Moderate head injury	SDH, ICH	12	5	10w
F7060109	L	35	Severe head injury	SDH, ICH	8	4	20w
F7060111	P	47	Severe head injury	SDH	7	4	10w
F7060096	L	49	Stroke	SDH	13	4	10w
F7060090	L	19	Severe head injury	SDH, ICH	5	4	10w
F7060088	P	21	Severe head injury	SDH	7	4	15w
F7060092	L	23	Severe head injury	SDH, ICH	5	4	12w
F7060080	L	24	Severe head injury	SDH, ICH	8	5	15w
F7060103	L	36	Severe head injury	SDH	7	4	11w
F7060084	P	42	Moderate head injury	SDH, ICH	12	4	13w
F7060082	L	56	Stroke	ICH	13	5	10w
F7060086	L	59	Stroke	ICH	12	4	15w

\*w: weeks, SDH: subdural hematoma, ICH: intracerebral hematoma.

## 6. Histological analysis

Pieces from the edges of the dural grafts were fixed in formalin and Hematoxylin Eosin (H&E) stained. The histological samples were analyzed by a microscope using a magnification of 40× and

**Table 2**

Baseline characteristics of subjects.

Variables	Fascia (Control Group)	Amniotic (Treatment Group)	P value
Age (mean, SD)	35	33	0.768
Sex			
Male (n = 8)	6	2	1.000
Female (n = 8)	6	2	
Intracranial lesion (n,% of total per group)			
Traumatic SDH	3 (18.8%)	2 (12.5%)	0.700
Traumatic SDH ICH	2 (12.5%)	6 (37.5%)	
Stroke ICH	3 (18.8%)	0 (0.0%)	
GCS			
3–8 (n = 10)	6	4	
9–13 (n = 6)	3	3	0.696*
GOS			
4 (n = 10)	6	4	
5 (n = 6)	2	4	0.302*

\* Note: P value is significant if  $p < 0.05$ .

then evaluated for fibrocyte infiltration thickness at the edges of the dural grafts.

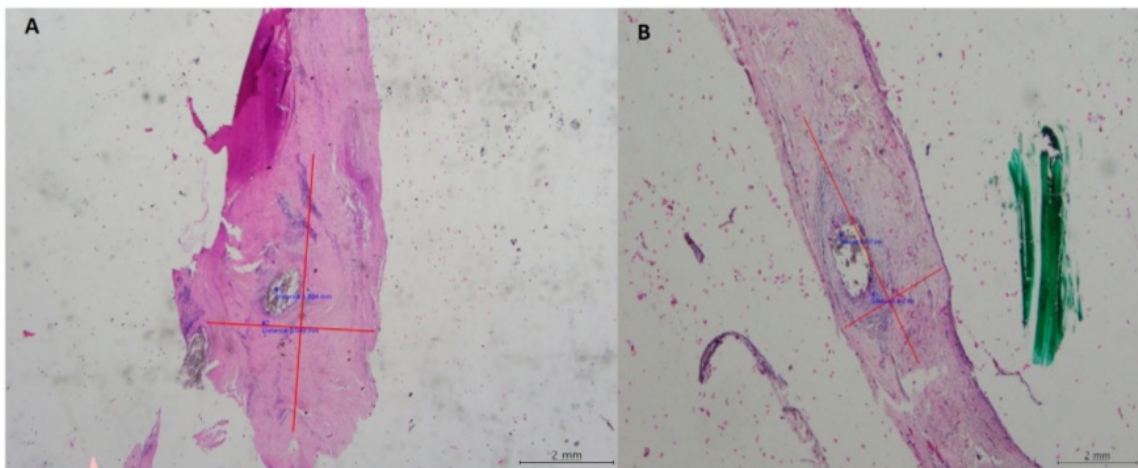
### 6.1. Data analysis

- Population: All patients who underwent decompressive craniectomy surgery at Dr. Soetomo Hospital.
- Sample: All patients who underwent duraplasty and cranioplasty surgery at Dr. Soetomo Hospital who met the inclusion criteria and were willing to participate in the research by providing informed consent. Purposive sampling was used in this research.

The research data were statistically analyzed with an independent two-sample *t*-test on the IBM SPSS Statistics 20 program. The level of significance for the hypothesis test was 0.05.

## 7. Results

The mean age of the control group was 35 years (SD 15.9). In the treatment group, the mean age obtained was 33 years (SD 9.9). The two-sample *t*-test obtained a *p*-value of 0.768 (Table 2). There were 12 males (75%) and four females (25%) in the entire research



**Fig. 1.** Microscopic histological examination display with H&E staining at 40× magnification. a. Sample number 3 in amniotic membrane graft group showed 5.89 × 3.57-mm fibrocyte infiltration; b. Sample number 2 in fascial graft group showed fibrocyte infiltration of 6.14 × 2.82 mm.

**Table 3**  
Results of histological examination (length and width of fibrocyte tissue infiltration).

Fibrocyte infiltration	Graft Type	Quantity	Mean	Standard deviation	P-value*
Length of Tissue	Fascia	8	7.8588	2.49949	0.82
	Amniotic	8	8.1238	2.01142	
Width of Tissue	Fascia	8	3.5725	1.76452	0.52
	Amniotic	8	4.1288	1.60022	

\* Note: The p-value of independent two-sample t-test is significant if  $p < 0.05$ .

sample. There were six males (75%) and two females (25%) in the treatment group and six males (75%) and two females (25%) in the control group (Table 2).

Regarding the craniocervical pathology of the study sample, three patients (18.75%) in the control group and two patients (12.5%) in the treatment group had a traumatic brain injury with subdural hematoma. Two patients (12.5%) in the control group and six patients (37.5%) in the treatment group had a traumatic brain injury with subdural and intracerebral hematoma. Meanwhile, three patients (18.75%) in the control group and three patients (18.75%) in the treatment group had stroke intracerebral hematoma (Table 2).

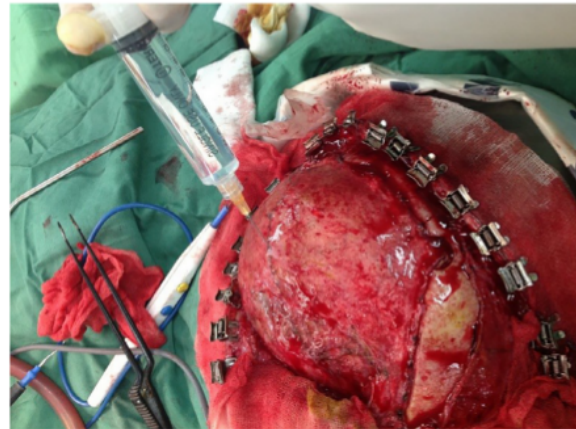
Histopathological examination with H&E staining showed dense fibrocyte infiltration in the amniotic membrane graft (Fig. 1); the mean length of the tissue was 8.12 mm (SD 2.01), and the mean width of the tissue was 4.12 mm (SD 1.60). In the group with the fascial graft, the mean length of the tissue was 7.85 mm (SD 2.49), and the mean width of the tissue was 3.57 mm (SD 1.76) (Table 3).

## 8. Discussion

The search for an ideal dural substitute has been one of the main challenges in neurosurgery. There are some studies which explore the material of dural substitution yet few human clinical studies have been conducted [1]. Several types of biomaterial that have already been tested in relation to include allograft, xenograft, and synthetic material [7] and muscle fascia remains the most accepted autologous implant in general use [1]. Sheets of Polytetrafluoroethylene (PTFE) have also been used as an alternative for dural graft but it was not fuse with surrounding tissue. Since most synthetic material was nonabsorbable including PTFE, it has been reported to have many complications, including rejection, irritation of the cerebral cortex, excessive scar formation, meningitis, and hemorrhage [7].

Amniotic membrane has advantages as allogeneic material for tissue replacement procedures. The importance of amniotic membrane resides in its potential to unite well with surrounding natural tissue, reduce inflammation, enhance epithelialization and wound healing. Davis, in 1910, was the first clinician to successfully use a fetal amniotic membrane for skin transplantation [8]. In 1940, De Roth first reported the use of amniotic membrane on the ocular surface [8]. However, using an amniotic membrane graft as a cover material for dural defects (in duraplasty procedures) is quite a new option. The first study on this, by Tomita (2012), found that the amniotic membrane could be used for graft filling to close dural defects during skull base surgery without causing tissue rejection, infection, or CSF leakage. A flaw in this research, however, was that it was limited to postoperative clinical observation, irrespective of histological changes.

In this study, we examined the watertight effect of amniotic membrane grafts, by making 0.9% NaCl fluid injections into the subdural cavity. This research used, as a control group, patients who underwent a dural graft with temporalis muscle fascia. Our



**Fig. 2.** CSF leakage test on sample number 6 of treatment group. No leaks were found in the connection area with the dura mater–amniotic membrane graft.

results showed that samples with amniotic membrane graft treatment could be sutured along the edges of the dural defect. There was no CSF leakage present during clinical care, and CSF fistulas were not shown during treatment (Fig. 2). While performing cranioplasty surgery, we also conducted observations and found no infections or extra-dural fluid collections.

Parizek (1997) reported, over the course of 20 years, the complications from 2665 duraplasty procedures that used allogeneic and xenogeneic fascia lata, pericardium, and dura mater. The complications occurred in 194 cases (7.3%), including CSF fistula, meningitis, epidural infection, chiasma compression, and pseudomeningocele [3]. Two patients died due to severe meningitis [3]. Earlier, Thadani (1988) had reported a rare delayed complication of Creutzfeldt-Jacob disease after a duraplasty operation using a cadaveric dura mater graft. Other complications of recurrent subarachnoid bleeding were reported after duraplasty that used synthetic material (silastic-coated teflon), it was suggested that bleeding occurred because of a rupture of fragile capillaries formed in the neomembrane enveloping the graft [5]. In our study, we did not find any of the complications mentioned, but the limitation is that this study only involved a small number of patients, with short observation periods.

The ideal duraplasty material should be immunologically inert, nontoxic, and unable to spread infectious disease [7]. Amniotic membrane has some advantages in its ability to reduce inflammation and enhance epithelialization and wound healing, its lack of immunogenicity, and its antimicrobial properties [8]. To prevent iatrogenic disease transmission or infection from allogeneic graft material, there should be a protocol that donors must be free of systemic disease, with careful serological screening [3,6]. The tissue bank which processes the material should routinely improve their decontamination and sterilization methods [3].

Our results corroborate a previous study conducted by Tomita (2012). The amniotic membrane graft used in human subjects did not cause tissue rejection, infection, or CSF leakage [7]. In addition, it was revealed that the fibrocyte infiltration thickness of the amniotic membrane graft group was as adequate as the fascial graft group. Amniotic membrane serves as a substitute material which facilitates epithelial cell migration, promotes epithelial differentiation, and prevents epithelial apoptosis [8]. Amniotic

membrane <sup>2</sup> is used not only as a substitute but also as a scaffold upon which cells can migrate and regenerate, forming new and healthy tissue [7].

## 9. Conclusion

<sup>9</sup> Based on the results from this clinical comparative study, it can be concluded that duraplasty healing using an amniotic membrane graft is as effective and safe as that using a fascial graft. An intra-operative observation and an histological review revealed that the use of an amniotic membrane graft was able to provide a watertight effect and was capable of stimulating adequate fibrocyte infiltration for edge healing of the dura mater defect. This research could serve as an initial clinical study to show that amniotic membrane grafts have a potential advantage as a dural substitute. An additional long-term study of this material on a larger population is necessary to complete this present study.

## Ethical standards

<sup>1</sup> The study was conducted with the understanding and consent of the human subjects. <sup>7</sup> The Ethical Committee at Dr. Soetomo General Hospital approved this study.

## Appendix A. Supplementary data

Supplementary data associated with this article can be found, in the online version, at <https://doi.org/10.1016/j.jocn.2018.01.069>.

## References

- [1] Mello L, Feltrin L, Fontes NP. Duraplasty with biosynthetic cellulose: an experimental study. *J Neurosurg* 1997;86:143–50.
- [2] Fontana R, Talamonti G, D'Angelo V, Arena O, Monte V, Collice M. Spontaneous haematoma as unusual complication of silastic dural substitute. Report of 2 cases. *Acta Neurochir (Wien)* 1992;115:64–6. <https://doi.org/10.1007/BF01400594>.
- [3] Parížek J, Měrická P, Husek Z, Suba P, Spacek J, Nemecek S, et al. Detailed evaluation of 2959 allogeneic and xenogeneic dense connective tissue grafts (fascia lata, pericardium, and dura mater) used in the course of 20 years for duraplasty in neurosurgery. *Acta Neurochir (Wien)* 1997;139:827–38.
- [4] Keller J, Ongkiko CMJ, Saunders M. Repair of spinal dural defects an experimental study. *J Neurosurg* 1984;60:1022–8.
- [5] Simpson D, Robson A. D. S, A. R. Recurrent subarachnoid bleeding in association with dural substitute. Report of three cases. *J Neurosurg* 1984;60:408–9. <https://doi.org/10.3171/jns.1984.60.2.0408>.
- [6] Thadani V, Penar PL, Partington J, Kalb R, Janssen R, Schonberger LB, et al. Creutzfeldt-Jakob disease probably acquired from a cadaveric dura mater graft. *J Neurosurg* 1988;69:766–9.
- [7] Tomita T, Hayashi N. New Dried Human Amniotic Membrane Is Useful as a Substitute for Dural Repair after Skull Base Surgery. *J Neurol Surg B* 2012;1:302–7.
- [8] Baradaran-rafi A, Aghayan H, Arjmand B. Amniotic Membrane Transplantation. *Iran J Ophthalmic Res* 2007;2:58–75.

# Duraplasty using amniotic membrane versus temporal muscle fascia: A clinical comparative study

## ORIGINALITY REPORT

15%

SIMILARITY INDEX

12%

INTERNET SOURCES

12%

PUBLICATIONS

0%

STUDENT PAPERS

## PRIMARY SOURCES

1	<a href="http://pubstemcell.com">pubstemcell.com</a> Internet Source	3%
2	<a href="http://www.thieme-connect.com">www.thieme-connect.com</a> Internet Source	2%
3	<a href="http://openneurologyjournal.com">openneurologyjournal.com</a> Internet Source	1%
4	<a href="http://publicatio.bibl.u-szeged.hu">publicatio.bibl.u-szeged.hu</a> Internet Source	1%
5	<a href="http://www.wis-injury.com">www.wis-injury.com</a> Internet Source	1%
6	Choung, Lee, Ham, Lee, Kim, Pang, Jahng, Lee. "Effectiveness of Low-Level Laser Therapy with a 915 Nm Wavelength Diode Laser on the Healing of Intraoral Mucosal Wound: An Animal Study and a Double-Blind Randomized Clinical Trial", Medicina, 2019 Publication	1%
7	<a href="http://eprints.gla.ac.uk">eprints.gla.ac.uk</a>	

1%

8

[repository.bilkent.edu.tr](http://repository.bilkent.edu.tr)

Internet Source

1%

9

"Accepted Abstracts from the International Brain Injury Association's Ninth World Congress on Brain Injury", Brain Injury, 2012

Publication

1%

10

[optometrytimes.modernmedicine.com](http://optometrytimes.modernmedicine.com)

Internet Source

1%

11

Amniotic Membrane, 2015.

Publication

<1%

12

Pascale D. Leclercq. "Simple Morphometry of Axonal Swellings Cannot Be Used in Isolation for Dating Lesions after Traumatic Brain Injury", Journal of Neurotrauma, 10/2002

Publication

<1%

13

"Neurovascular Surgery", Springer Science and Business Media LLC, 2019

Publication

<1%

14

Luis Renato Mello. "Duraplasty with biosynthetic cellulose: an experimental study", Journal of Neurosurgery, 01/1997

Publication

<1%

15

[www.butterflyitalia.com](http://www.butterflyitalia.com)

Internet Source

<1%



---

16

Donald Simpson. "Recurrent subarachnoid bleeding in association with dural substitute : Report of three cases", Journal of Neurosurgery, 02/1984

Publication

<1%

---

17

Youn-Kwan Park. "Prevention of Arachnoiditis and Postoperative Tethering of the Spinal Cord with Gore-Tex Surgical Membrane: An Experimental Study with Rats", Neurosurgery, 04/1998

Publication

<1%

---

18

[unair.ac.id](http://unair.ac.id)

Internet Source

<1%

---

19

[thejns.org](http://thejns.org)

Internet Source

<1%

---

20

[www.thejcdp.com](http://www.thejcdp.com)

Internet Source

<1%

---

21

[sosyalarastirmalar.org](http://sosyalarastirmalar.org)

Internet Source

<1%

---

22

[insights.ovid.com](http://insights.ovid.com)

Internet Source

<1%

---

Exclude quotes

Off

Exclude matches

< 10 words

Exclude bibliography

On

