



Aalborg Universitet

AALBORG UNIVERSITY  
DENMARK

## Endoscopic Ultrasound-Guided Transesophageal Pericardiocentesis in the Treatment of Localized Cardiac Tamponade Following Coronary Perforation

Lundahl, Camilla; Ejstrup, Per; Christensen, Martin Kirk

*Published in:*  
JACC. Case reports

*DOI (link to publication from Publisher):*  
[10.1016/j.jaccas.2024.102346](https://doi.org/10.1016/j.jaccas.2024.102346)

*Creative Commons License*  
CC BY-NC-ND 4.0

*Publication date:*  
2024

*Document Version*  
Publisher's PDF, also known as Version of record

[Link to publication from Aalborg University](#)

*Citation for published version (APA):*  
Lundahl, C., Ejstrup, P., & Christensen, M. K. (2024). Endoscopic Ultrasound-Guided Transesophageal Pericardiocentesis in the Treatment of Localized Cardiac Tamponade Following Coronary Perforation. *JACC. Case reports*, 29(11), Article 102346. <https://doi.org/10.1016/j.jaccas.2024.102346>

### General rights

Copyright and moral rights for the publications made accessible in the public portal are retained by the authors and/or other copyright owners and it is a condition of accessing publications that users recognise and abide by the legal requirements associated with these rights.

- Users may download and print one copy of any publication from the public portal for the purpose of private study or research.
- You may not further distribute the material or use it for any profit-making activity or commercial gain
- You may freely distribute the URL identifying the publication in the public portal -

### Take down policy

If you believe that this document breaches copyright please contact us at [vbn@aub.aau.dk](mailto:vbn@aub.aau.dk) providing details, and we will remove access to the work immediately and investigate your claim.

## CASE REPORT

### CLINICAL CASE

# Endoscopic Ultrasound-Guided Transesophageal Pericardiocentesis in the Treatment of Localized Cardiac Tamponade Following Coronary Perforation



Camilla Lundahl, MD,<sup>a</sup> Per Ejstrud, MD,<sup>b</sup> Martin Kirk Christensen, MD<sup>a</sup>

#### ABSTRACT

We present a case of an 81-year-old male patient who developed a posteriorly localized pericardial effusion and tamponade of the left atrium after percutaneous intervention of the right coronary artery. Endoscopic ultrasound-guided transesophageal pericardiocentesis was performed when conventional transthoracic and surgical access options were associated with unacceptable risk. (J Am Coll Cardiol Case Rep 2024;29:102346) © 2024 The Authors. Published by Elsevier on behalf of the American College of Cardiology Foundation. This is an open access article under the CC BY-NC-ND license (<http://creativecommons.org/licenses/by-nc-nd/4.0/>).

#### HISTORY OF PRESENTATION

An 81-year-old male patient with a history of coronary artery bypass grafting in 2004 and symptoms of unstable angina pectoris was admitted for elective coronary angiography and had percutaneous coronary

intervention performed on his severely calcified right coronary artery. During the procedure, a small distal wire perforation was noticed and coiled. The patient was stable and asymptomatic during the procedure.

Shortly after the procedure, the patient developed chest pain and dyspnea and became hypotensive with a blood pressure of 95/60 mm Hg. He was stabilized on fluids.

#### LEARNING OBJECTIVES

- To understand the relevance of exploring alternative pericardiocentesis approaches in high-risk patients presenting with cardiac tamponade.
- To be able to evaluate utility and feasibility of transesophageal EUS pericardiocentesis as an alternative approach for draining posterior pericardial effusions.

#### PAST MEDICAL HISTORY

The patient had a past medical history of hypertension, hypercholesterolemia, and ischemic heart disease. In 2004, he underwent a coronary artery bypass grafting procedure, and in 2008 he experienced an episode of ventricular tachycardia, which led to the implantation of a biventricular implantable cardioverter defibrillator.

From the <sup>a</sup>Department of Cardiology, Aalborg University Hospital, Aalborg, Denmark; and the <sup>b</sup>Department of Gastrointestinal Surgery, Aalborg University Hospital, Aalborg, Denmark.

The authors attest they are in compliance with human studies committees and animal welfare regulations of the authors' institutions and Food and Drug Administration guidelines, including patient consent where appropriate. For more information, visit the [Author Center](#).

Manuscript received February 9, 2024; revised manuscript received March 12, 2024, accepted March 20, 2024.

**ABBREVIATIONS  
AND ACRONYMS****EUS** = endoscopic ultrasound**DIFFERENTIAL DIAGNOSIS**

The differential diagnosis included in-stent thrombosis, cardiogenic shock, and cardiac tamponade.

**INVESTIGATIONS**

Acute echocardiography revealed a localized pericardial effusion posteriorly resulting in collapse of the left atrium but with no direct influence on the left and right ventricular function. Computed tomography imaging was performed, confirming the presence of an effusion situated in the posterior region of the pericardium, near the esophagus (**Figure 1, Video 1**). The effusion measured 9 × 5 cm.

**MANAGEMENT**

The initial treatment approach was conservative, but after 4 days of observation, the patient developed pulmonary hypertension with a tricuspid regurgitation gradient of 60 mm Hg and bilateral pleural effusion. Bilateral pleurocentesis was performed.

The patient became increasingly symptomatic and hypotensive, setting the indication for pericardiocentesis. Conventional transthoracic pericardiocentesis was deemed impossible due to the localization of the pericardial effusion. The Heart team was called, and a thoracic surgical option was discussed at length. This was perceived as carrying a very high risk of death due to the patient's age, prior

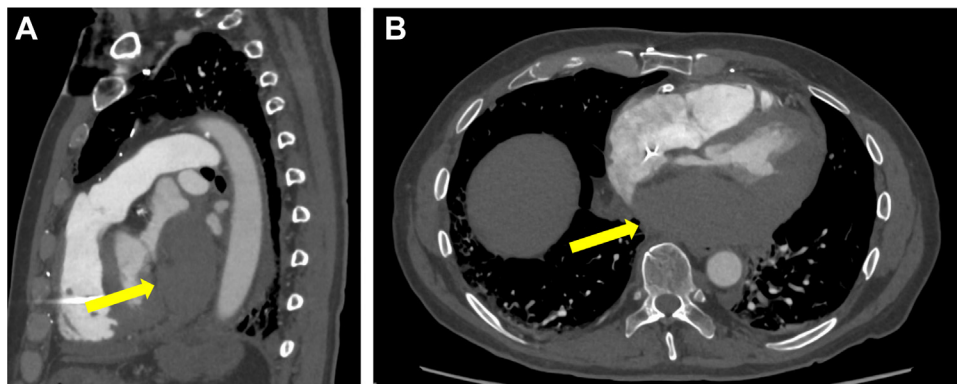
coronary artery bypass grafting, ongoing anticoagulant and platelet-inhibiting therapy, and the compression of the left atrium.

The patient gave his consent to undergo experimental transesophageal endoscopic ultrasound (EUS)-guided pericardiocentesis. To reduce the risk of infection, intravenous antibiotics were administered before and after the procedure.

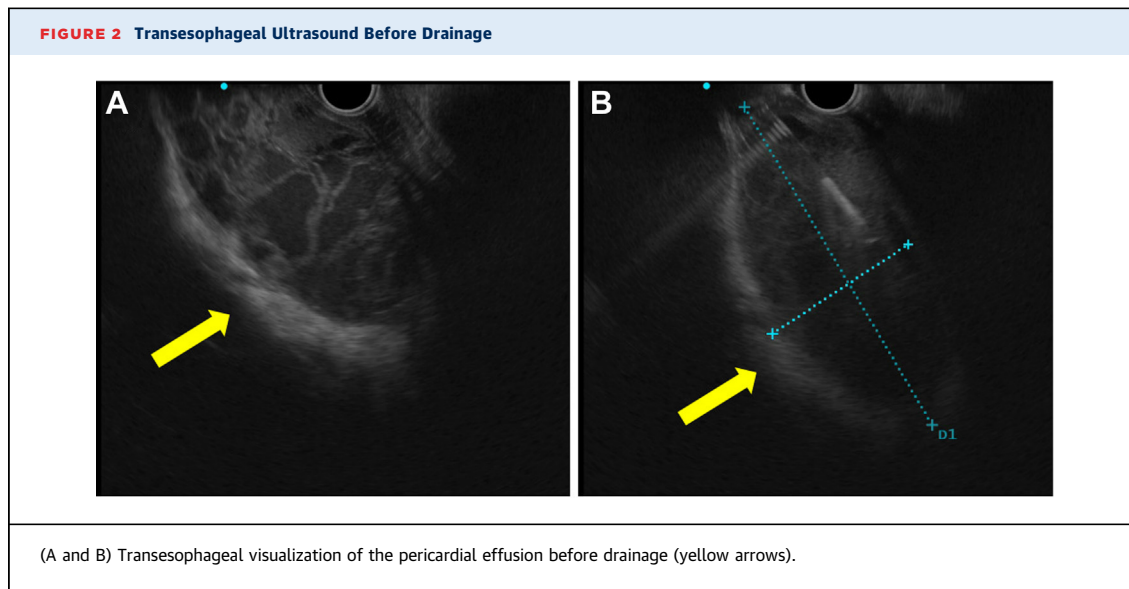
The procedure was performed with the patient in conscious sedation with a combination of remimazolam (Byfavo, Eagle Pharmaceuticals) and alfentanil (Rapifen, Piramal Critical Care). With the patient in the left lateral position, a linear echoendoscope (GF-UCT180, Olympus America) was passed from the mouth to the distal esophagus. A window for puncture through the esophagus was chosen using Doppler imaging. With a 19-gauge needle (Cook Medical), 53 mL of hemorrhagic fluid was successfully aspirated from the pericardial effusion without complications (**Figures 2 to 4, Videos 2 and 3**). Immediate echocardiography after the procedure revealed a significant reduction in the pericardial effusion, along with the absence of left atrium collapse.

**DISCUSSION**

Echocardiography-guided transthoracic pericardiocentesis is the first choice of intervention for drainage of pericardial effusions. The procedure has a low rate of complications and a high success rate.<sup>1,2</sup> However, in rare cases, the procedure cannot be performed safely due to the location of the pericardial effusion. A surgical

**FIGURE 1** Computed Tomography Imaging

(A and B) Computed tomography imaging shows fluid accumulation in the posterior pericardium (yellow arrows) near the esophagus.



option is often possible, but the operation is not without risk of further complications.

EUS-guided access to mediastinal masses and lymph nodes is widely used successfully and safely.<sup>3,4</sup> Because this technique enables ultrasound visualization of the mediastinum, including the posterior pericardium and left atrium, it provides an optimal route for evacuating fluid accumulated in that space. This approach may especially be considered in frail patients for whom surgical intervention poses a significantly higher risk.

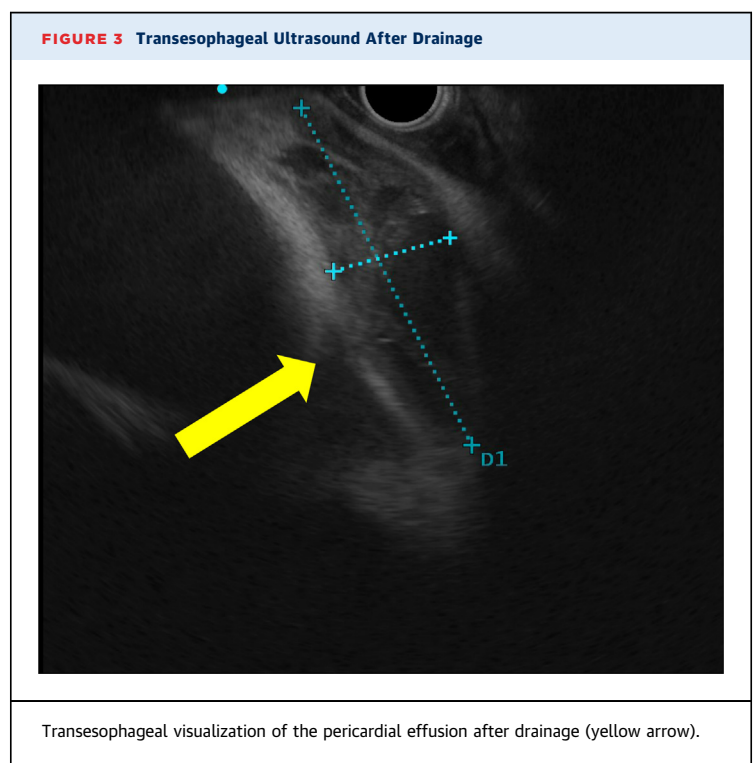
In a 59-year-old male patient, we applied the same procedure and approach as described earlier, to successfully aspirate 84 mL of fluid from the posterior pericardium of the patient. However, only a few cases of EUS-guided pericardiocentesis of the posterior pericardium have been reported.<sup>5-7</sup> Successful transbronchial pericardiocentesis has also been reported.<sup>8,9</sup> These alternative methods to pericardiocentesis might be an adequate strategy of intervention in cases in which conventional percutaneous drainage is impossible, or where surgical evacuation of the pericardium is deemed too high risk. Further clinical research is needed to assess safety of the procedure, success rate, and optimal setup when used for drainage of the pericardium.

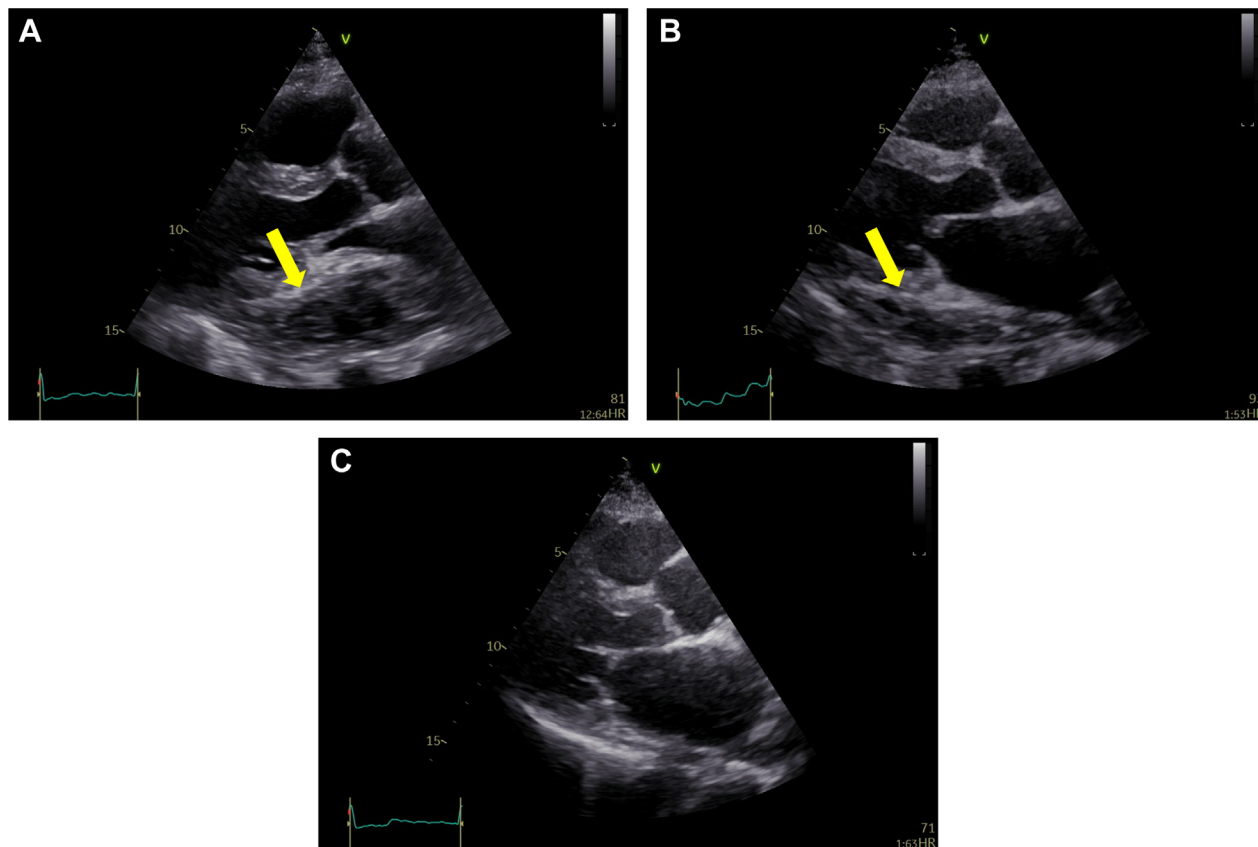
### FOLLOW-UP

At the 1.5-month follow-up, the patient remained asymptomatic, and an echocardiography revealed absence of pericardial effusion and a preserved left ventricular ejection fraction.

### CONCLUSIONS

EUS-guided pericardiocentesis is an alternative method and might be considered for evacuation of pericardial effusion located in the posterior pericardium. However, further clinical research on the method is needed.



**FIGURE 4** Echocardiography

Transthoracic echocardiography showing parasternal long-axis view of the pericardial effusion (yellow arrows) preprocedurally (A), postprocedurally (B), and at the 1.5-month follow-up (C).

#### FUNDING SUPPORT AND AUTHOR DISCLOSURES

The authors have reported that they have no relationships relevant to the contents of this paper to disclose.

**ADDRESS FOR CORRESPONDENCE:** Dr Camilla Lundahl, Department of Cardiology, Aalborg University Hospital, Hobrovej 18-22, 9000 Aalborg, Denmark. E-mail: [c.lundahl@rn.dk](mailto:c.lundahl@rn.dk).

#### REFERENCES

1. Tsang TSM, Enriquez-Sarano M, Freeman WK, et al. Consecutive 1127 therapeutic echocardiographically guided pericardiocenteses: clinical profile, practice patterns, and outcomes spanning 21 years. *Mayo Clin Proc.* 2002;77(5):429-436. <https://doi.org/10.4065/77.5.429>
2. Tsang TSM, Freeman WK, Sinak LJ, Seward JB. Echocardiographically guided pericardiocentesis. *Mayo Clin Proc.* 1998;73(7):647-652. [https://doi.org/10.1016/s0025-6196\(11\)64888-x](https://doi.org/10.1016/s0025-6196(11)64888-x)
3. O'Toole D, Palazzo L, Arotçarena R, et al. Assessment of complications of EUS-guided fine-needle aspiration. *Gastrointest Endosc.* 2001;53(4):470-474. <https://doi.org/10.1067/MGE.2001.112839>
4. Wiersema MJ, Vazquez-Sequeiros E, Wiersema LM. Evaluation of mediastinal lymphadenopathy with endoscopic US-guided fine-needle aspiration biopsy. *Radiology.* 2001;219(1):252-257. <https://doi.org/10.1148/RADIOLOGY.219.1.R01AP44252>
5. Yusuke H, Naotaka M, Masaa N. Alternative approach to pericardial effusion: EUS guided transesophageal pericardiocentesis. *Endoscopy.* 2011;43(suppl 3):A170. <https://doi.org/10.1055/s-0031-1292241>
6. Hashimoto Y, Inoue K. Endoscopic ultrasound-guided transesophageal pericardiocentesis: an alternative approach to a pericardial effusion. *Endoscopy.* 2016;48(suppl 1):E71-E72. <https://doi.org/10.1055/s-0032-1326074>

7. Dwivedi S, Berg M, Eidem M, et al. Endoscopic ultrasound-guided pericardiocentesis in a patient with disseminated cryptococcus infection. *Gastrointest Endosc*. 2009;69(2):S240. <https://doi.org/10.1016/j.gie.2008.12.120>

8. Sharma RK, Khanna A, Talwar D. Endobronchial ultrasound: a new technique of pericardiocentesis


in posterior loculated pericardial effusion. *Chest*. 2016;150(5):e121-e123. <https://doi.org/10.1016/j.chest.2016.03.013>

9. Ceron L, Manzato M, Mazzaro F, Bellavere F. A new diagnostic and therapeutic approach to pericardial effusion. *Chest*. 2003;123(5):1753-1758. <https://doi.org/10.1378/chest.123.5.1753>

---

**KEY WORDS** cardiac tamponade, endoscopic ultrasound, transesophageal pericardiocentesis

---

 **APPENDIX** For supplemental videos, please see the online version of this paper.