

Case Report

Excision and Reconstruction of Atypical Chest Dermatofibrosarcoma Protuberans Tumor: A Case Report and Literature Review

Mohamed Badie Ahmed^{a, b} Fatima Saoud Al-Mohannadi^a
Abdelrahman Badie Ahmed^c Mahmoud Althalathini^d Abeer Alsherawi^a

^aPlastic Surgery Department, Hamad General Hospital, Hamad Medical Corporation, Doha, Qatar; ^bCollege of Medicine, QU Health, Qatar University, Doha, Qatar; ^cCollege of Medicine, Modern University for Technology and Information, Cairo, Egypt; ^dPlastic Surgery Department, Clinica Joelle, Doha, Qatar

Keywords

Dermatofibrosarcoma protuberans · Malignant sarcoma · Skin cancer

Abstract

Introduction: Dermatofibrosarcoma protuberans (DFSP) originated as keloid sarcoma, gaining its current designation in 1925. DFSP exhibits slow growth, categorizing it as a low- to intermediate-grade malignant sarcoma. Initially presenting as a small, firm, irregular skin nodule, it undergoes sudden, rapid growth, forming a prominent mass. While locally aggressive, distant metastasis is rare. DFSP affects mainly the torso then proximal extremities. **Case Presentation:** In this case study, we described a 57-year-old male individual who presented with a chest midline swelling that was progressing in size. A punch biopsy showed inconclusive results. Thus, a wide local excision was carried out along with sending the initial biopsy slides to Mayo Clinic for second opinion. A diagnosis of DFSP was confirmed, which is an uncommon and locally aggressive tumor affecting soft tissues. The primary histological diagnosis relies on immunohistochemical stains, enabling the distinction between DFSP and other fibrous tumors. **Conclusion:** Diagnosing DFSP is challenging due to its similarity to other skin lesions. A multidisciplinary approach is vital for accurate diagnosis and management.

© 2024 The Author(s).
Published by S. Karger AG, Basel

Level of Evidence: Level IV, case study.

Correspondence to:
Mohamed Badie Ahmed, ma1510062@qu.edu.qa; mahmed104@hamad.qa

Introduction

Dermatofibrosarcoma protuberans (DFSP) was initially identified as keloid sarcoma until 1925 when it was named as DFSP by Hoffman [1]. It occurs in middle-aged men, has a slow growth rate, and is considered low- to intermediate-grade malignant sarcoma. It starts as a very small nodular skin lesion that is firm and irregular, varying in color from flesh to reddish brown. Its size remains stable for many years; however, it then undergoes a very rapid period of growth, forming a conspicuous mass. Other presentations of DFSP are morphea-like, atrophic, sclerotic, and violaceous plaque without nodularity that might ulcerate. It is locally aggressive but rarely metastasize distantly. It is usually found on the torso, then proximal extremities [2, 3].

Around 90% of DFSP tumors have a translocation of chromosome t(17; 22). The translocation fuses the collagen gene (COL1A1) with the platelet-derived growth factor (PDGF) gene. The fibroblast, the cell of origin of this tumor, expresses the fusion gene in the belief that it codes for collagen. The tissue is often positive for CD34 [4, 5].

Surgical excision is the recommended method of therapy [6]. In addition, chemotherapy and radiation therapy can be used sometimes. There is clinical evidence that imatinib might be effective for tumors positive for the t(17; 22) translocation because it inhibits PDGFB [7].

In this paper, we present a case of atypical DFSP that underwent excision and reconstruction with full-thickness skin graft. The CARE Checklist has been completed by the authors for this case report, attached as online supplementary material (for all online suppl. material, see <https://doi.org/10.1159/000536062>).

Case Presentation

This is a case of a 57-year-old diabetic male patient on insulin, presented with a chest midline swelling that has been very small and stable in size for the last 25 years. It started to grow from 1 mm to 7 cm in diameter in the last 10 months. Upon examination: around 6*7 cm swelling at mid sternum, reaching sternum bone, not fixed but tethered with overlying (Fig. 1). Very red with a few satellite lesion next to the base, it is partially mobile, not painful with no fluctuation and signs of infection. CT thorax with contrast showed a 45-mm solid lesion of the skin of the anterior thoracic wall impressive of malignant neoplasm.

The chest punch biopsy (4 mm) showed: A – Spindle cell proliferation with a few scattered mast cells in the background. B – Morphological features suggest a neural origin; however, immunophenotyping is not specific (only weak CD34 expression and possible factor XIIIa staining focally). C – No overt features of malignancy were seen. Histopathologist commented that this is a spindle cell proliferation with variable cellularity but without any overt features of malignancy. However, immunophenotype (despite a wide panel) has been noncontributory in subtyping this. Therefore, the slides are sent to Mayo Clinic for a second opinion and a final report.

Mayo Clinic laboratories reported that immunohistochemical stains showed weak staining for CD34 and negative staining for ERG, estrogen receptor, progesterone receptor, S100, SOX10, STAT6, Glut-1, CDK4, CD117, ALK, HHV8, and CD68. Molecular studies showed abnormal results indicating rearrangement involving the PDGB gene region. ALK stain shows high background. These findings are consistent with DFSP. No evidence of fibrous sarcoma is identified in the biopsy. FISH study for PDGFB (22q13) was positive. Thus, a diagnosis of DFSP was confirmed.

The patient underwent an operation of wide and deep excision to the level of pectoralis major muscle fascia and periosteum of the sternum (Fig. 2). Coverage was done with

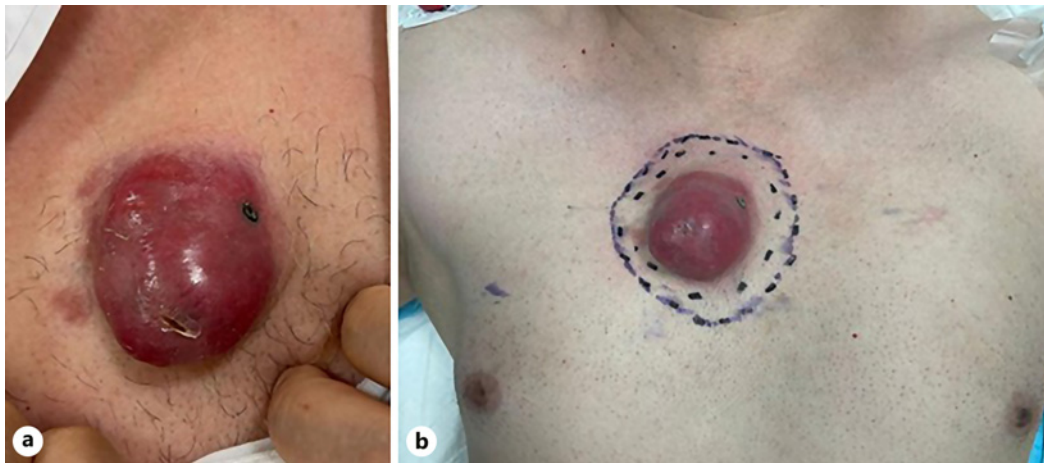


Fig. 1. a, b Preoperative pictures of the chest DFSP tumor.

full-thickness skin graft from the left groin (Fig. 3). The excised sample pathology report showed completely excised DFSP lesion with morphological features that are more obviously atypical with cellular storiform component. In addition, more diffuse and strong CD34 expression in some blocks/areas were observed. These features are in keeping with a diagnosis of DFSP on the excised sample as well. The follow-up clinic visits showed a well-taken skin graft with a clean, dry wound and no signs of infection or hematoma collection (Fig. 4).

Discussion

In this case report, we presented a 57-year-old male patient diagnosed with DFSP, a rare and locally aggressive soft tissue tumor. The main histologic diagnosis is done through immunohistochemical stains that allows the differentiation between DFSP and other fibrous tumors, which are CD34, factor XIIIa, stromelysin-3 (ST3), and apolipoprotein D (Apo D) [8]. Our diagnosis was inconclusive by the initial histopathological examination, due to weak CD34 expression which was challenging and atypical in its features. This has required a second opinion from Mayo Clinic that confirmed our diagnosis. They have confirmed the diagnosis with molecular study that showed a positive FISH study for PDGFB (22q13) and high ALK stain in background. Molecular and cytogenetic studies have shown more than 90% of DFSP are characterized by one of two features. They are either a supernumerary ring chromosomes derived from chromosomes 17 and 22 or chromosomal translocation t(17; 22) (q22; q13), which results in the fusion of collagen type 1-alpha 1 (COL1A1 at 17q22) and platelet-derived growth factor beta (PDGFB at 22q13) genes. The gene fusion places the PDGFB gene under the control of the COL1A1 promoter [4, 9, 10].

Several cases of chest DFSP have widely variable presentations, and a few of them have experienced recurrence. However, the majority showed clearance of the tumor in their follow-ups [11–13].

Surgical excision with clear margins remains the primary treatment modality for DFSP and is crucial to minimize the risk of recurrence [14, 15]. Mohs micrographic surgery (MMS) along with wide local excision are the main surgical options. MMS provides histopathological control while minimizing tissue defects. Therefore, several studies recommended MMS over wide local excision [16, 17]. On the other hand, MMS is considered a lengthy procedure and requires specific equipment and staff training. Thus, it might not be available in all clinics or

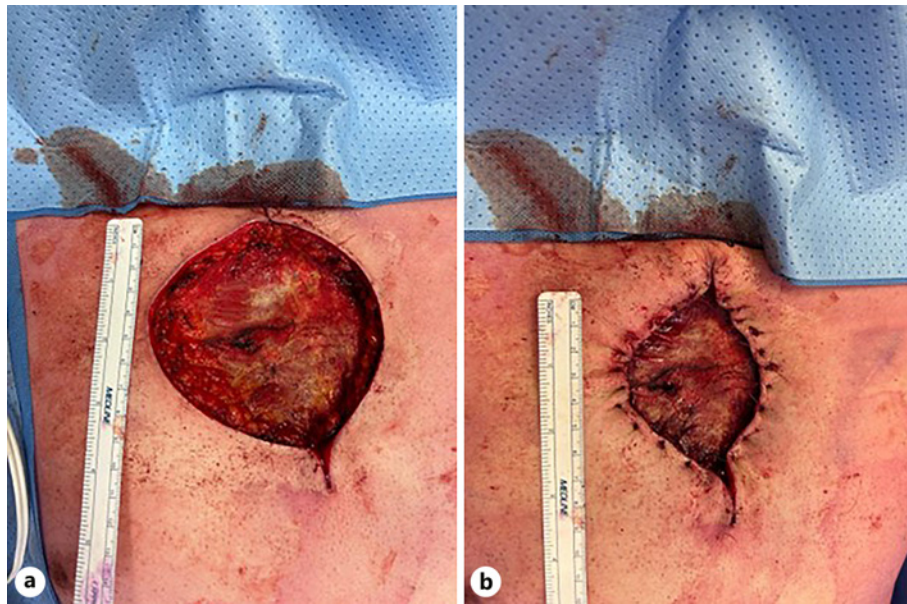

Fig. 2. **a** Intraoperative picture after the lesion excision. **b** Intraoperative picture after undermining and minimizing the defect size.

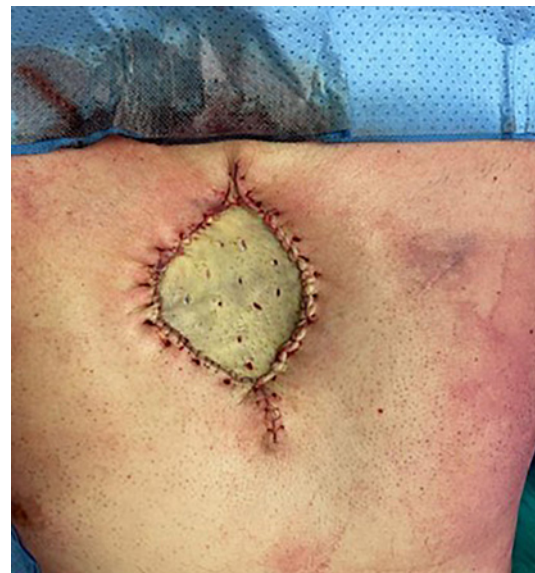

Fig. 3. Intraoperative picture after applying full-thickness skin graft taken from the groin to cover the defect.

hospitals. In our case, the patient underwent wide local surgical resection, ensuring complete removal of the tumor. The surgical margin in DFSP should be assessed at macroscopic (intraoperative) and microscopic (histology) levels. The European consensus-based guideline suggests utilizing 3-cm safety margin [18]. However, several variable safety margin cutoffs have been suggested in the literature [19, 20]. In our case, we opted for a 2-cm safety margin and the histology results reported clear margins. Adjuvant radiotherapy was not deemed necessary due to the absence of high-risk features.

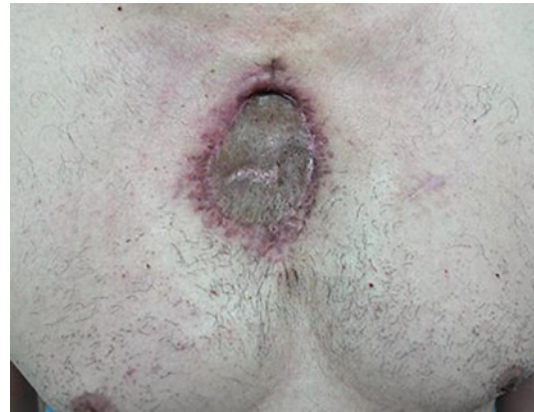

Fig. 4. Eight weeks of postoperative picture after applying full-thickness skin graft.

Long-term follow-up is essential in DFSP cases due to its potential for local recurrence. Although rare, distant metastasis has been reported in some cases (2–5%) [21]. Our patient will be closely monitored for any signs of recurrence or metastasis.

It is worth noting that the diagnosis of DFSP can be challenging, as it may mimic other benign or malignant skin lesions. Therefore, a multidisciplinary approach involving dermatologists, pathologists, and oncologists is crucial for accurate diagnosis and optimal management.

In conclusion, this case report highlights the importance of cytogenetic and molecular studies in early recognition and diagnosis of DFSP which allows an appropriate management at early stages of this tumor. Surgical excision with clear margins remains the cornerstone of treatment, while long-term follow-up is necessary to monitor for recurrence or metastasis.

Acknowledgment

We thank the Qatar National Library for funding the open access publication of this paper.

Statement of Ethics

Ethical approval is not required for this study in accordance with local or national guidelines. Written informed consent was obtained from the patient for publication of this case report and any accompanying images.

Conflict of Interest Statement

None of the authors has a financial interest in any of the products, devices, or drugs mentioned in this manuscript.

Funding Sources

This study received funding from Qatar National Library for open access publication.

Author Contributions

The authors confirm contribution to the manuscript as follows: study conception and design: M.B.A. and A.A.; data collection: M.B.A., F.S.A.-M., A.B.A., and A.A.; analysis and interpretation of results: M.B.A., A.B.A., and M.A.; and draft manuscript preparation: M.B.A., A.B.A., and F.S.A.-M. All authors reviewed the results and approved the final version of the manuscript.

Data Availability Statement

All data generated or analyzed during this study are included in this article and its online supplementary material files. Further inquiries can be directed to the corresponding author.

References

- 1 Hoffmann E. I. Über das knollentreibende Fibrosarkom der Haut (Dermatofibrosarkoma protuberans). *Dermatology*. 1925;43(1-2):1-28.
- 2 Shimizu A, O'Brien KP, Sjöblom T, Pietras K, Buchdunger E, Collins VP, et al. The dermatofibrosarcoma protuberans-associated collagen type Ialpha1/platelet-derived growth factor (PDGF) B-chain fusion gene generates a transforming protein that is processed to functional PDGF-BB. *Cancer Res*. 1999;59(15):3719-23.
- 3 Rutgers EJ, Kroon BB, Albus-Lutter CE, Gortzak E. Dermatofibrosarcoma protuberans: treatment and prognosis. *Eur J Surg Oncol*. 1992;18(3):241-8.
- 4 Sirvent N, Maire G, Pedeutour F. Genetics of dermatofibrosarcoma protuberans family of tumors: from ring chromosomes to tyrosine kinase inhibitor treatment. *Genes Chromosomes Cancer*. 2003;37:1-19.
- 5 Patel KU, Szabo SS, Hernandez VS, Prieto VG, Abruzzo LV, Lazar AJF, et al. Dermatofibrosarcoma protuberans COL1A1-PDGFB fusion is identified in virtually all dermatofibrosarcoma protuberans cases when investigated by newly developed multiplex reverse transcription polymerase chain reaction and fluorescence in situ hybridization assays. *Hum Pathol*. 2008;39(2):184-93.
- 6 Dimas D, Boutas I, Potiris A, Koufopoulos N, Balalis D, Sitara K, et al. Dermatofibrosarcoma protuberans of the breast: a case study. *Mol Clin Oncol*. 2021;14(3):50.
- 7 Criscione VD, Weinstock MA. Descriptive epidemiology of dermatofibrosarcoma protuberans in the United States, 1973 to 2002. *J Am Acad Dermatol*. 2007;56(6):968-73.
- 8 Kim HJ, Lee JY, Kim SH, Seo YJ, Lee JH, Park JK, et al. Stromelysin-3 expression in the differential diagnosis of dermatofibroma and dermatofibrosarcoma protuberans: comparison with factor XIIIa and CD34. *Br J Dermatol*. 2007;157(2):319-24.
- 9 Simon M-P, Pedeutour F, Sirvent N, Grosgeorge J, Minoletti F, Coindre J-M, et al. Deregulation of the platelet-derived growth factor B-chain gene via fusion with collagen gene COL1A1 in dermatofibrosarcoma protuberans and giant-cell fibroblastoma. *Nat Genet*. 1997;15(1):95-8.
- 10 Bianchini L, Maire G, Guillot B, Joujoux J-M, Follana P, Simon M-P, et al. Complex t(5;8) involving the CSPG2 and PTK2B genes in a case of dermatofibrosarcoma protuberans without the COL1A1-PDGFB fusion. *Virchows Arch*. 2008;452(6):689-96.
- 11 Hussain N, Naveed MZ, Haider G. Re-recurrent Dermatofibrosarcomaprotuberans of the chest wall. *J Pak Med Assoc*. 2015;65(3):324-6.
- 12 Kimura K, Inadomi T, Yamauchi W, Yoshida Y, Kashimura T, Terui T. Dermatofibrosarcoma protuberans on the chest with a variety of clinical features masquerading as a keloid: is the disease really protuberant? *Ann Dermatol*. 2014;26:643-5.
- 13 Zhang Z, Cen Y, Qing Y, Wang H, Liu X. Dermatofibrosarcoma protuberans of the chest wall: three-dimensional wide excision and reconstruction. *Chin Med J*. 2014;127(2):386-8.
- 14 Vandeweyer E, De Saint Aubain Somerhausen N, Gebhart M. Dermatofibrosarcoma protuberans: how wide is wide in surgical excision? *Acta Chir Belg*. 2002;102(6):455-8.
- 15 Miyakawa E, Fujimoto H, Miyakawa K, Nemoto K, Kozawa K, Sugano I, et al. Dermatofibrosarcoma protuberans. CT findings with pathologic correlation in 6 cases. *Acta Radiol*. 1996;37(3 Pt 1):362-5.
- 16 Lowe GC, Onajin O, Baum CL, Otley CC, Arpey CJ, Roenigk RK, et al. A comparison of mohs micrographic surgery and wide local excision for treatment of dermatofibrosarcoma protuberans with long-term follow-up: the Mayo clinic experience. *Dermatol Surg*. 2017;43(1):98-106.
- 17 Veronese F, Boggio P, Tiberio R, Gattoni M, Fava P, Caliendo V, et al. Wide local excision vs. Mohs Tübingen technique in the treatment of dermatofibrosarcoma protuberans: a two-centre retrospective study and literature review. *Acad Dermatol Venereol*. 2017;31(12):2069-76.

- 18 Saiag P, Grob J-J, Lebbe C, Malvehy J, Del Marmol V, Pehamberger H, et al. Diagnosis and treatment of dermatofibrosarcoma protuberans. European consensus-based interdisciplinary guideline. *Eur J Cancer*. 2015; 51(17):2604–8.
- 19 Woo K-J, Bang SI, Mun G-H, Oh KS, Pyon J-K, Lim SY. Long-term outcomes of surgical treatment for dermatofibrosarcoma protuberans according to width of gross resection margin. *J Plast Reconstr Aesthet Surg*. 2016;69(3):395–401.
- 20 Miller SJ, Alam M, Andersen JS, Berg D, Bichakjian CK, Bowen GM, et al. Dermatofibrosarcoma protuberans. *J Natl Compr Canc Netw*. 2012;10(3):312–8.
- 21 Mendenhall WM, Zlotecki RA, Scarborough MT. Dermatofibrosarcoma protuberans. *Cancer*. 2004;101(11): 2503–8.