



TWO DIMENSIONAL VS THREE DIMENSIONAL VSP (VIRTUAL SURGICAL PLANNING) IN ORTHOGNATHIC SURGERY - A REVIEW

Dr. Ankita Chakraborty, BDS, Kalinga Institute of Dental Sciences, KIIT

Deemed-To-Be University, Bhubaneswar, Odisha 751024, India

Dr. Nivedita Sahoo, Professor, Department of Orthodontics and Dentofacial
Orthopaedics, Kalinga Institute of Dental Sciences, KIIT Deemed-To-Be University,
Bhubaneswar, Odisha 751024, India

Dr. Diksha Swaroop, BDS, Kalinga Institute of Dental Sciences, KIIT

Deemed-To-Be University, Bhubaneswar, Odisha 751024, India

Dr. Priti Kiran, Post-graduate trainee, Department of Orthodontics and Dentofacial
Orthopaedics, Kalinga Institute of Dental Sciences, KIIT Deemed-To-Be University,
Bhubaneswar, Odisha 751024, India

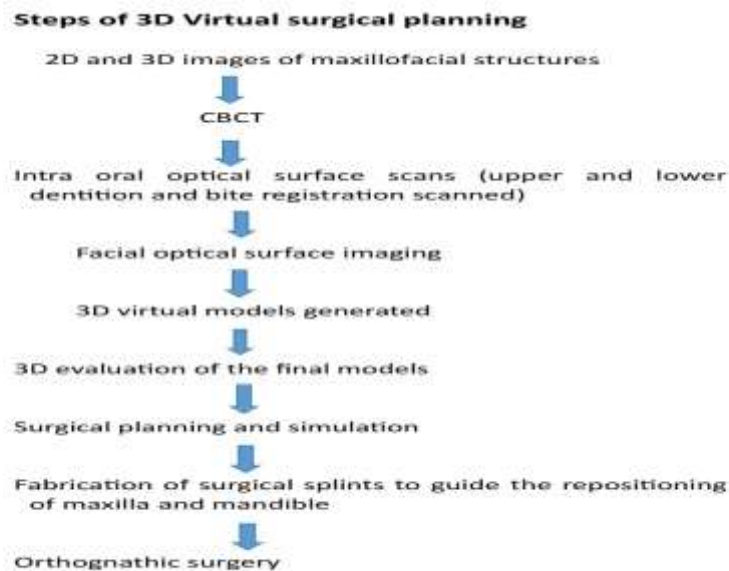
Dr. Yash Sinha, Post-graduate trainee, Department of conservative dentistry and
endodontics, Kalinga Institute of Dental Sciences, KIIT Deemed-To-Be University,
Bhubaneswar, Odisha 751024, India

Corresponding author: Dr. Nivedita Sahoo, Professor, Department of Orthodontics
and Dentofacial Orthopaedics, Kalinga Institute of Dental Sciences, KIIT
Deemed-To-Be University, Bhubaneswar, Odisha 751024, India

<p>Article History Received: 08 Oct 2023 Revised: 29 Nov 2023 Accepted: 02 Dec 2023</p>	<p>Abstract: Orthodontic treatment provides a solution for the improvement of teeth alignment, facial aesthetics, functional and periodontal problems. Deformities that cannot be corrected with orthodontic treatment alone are called dentofacial deformities. This is where growth modification or orthognathic surgery comes into play. It is carried out in adults having severe dentofacial deformities. In order to have a successful outcome in patients undergoing orthognathic surgery, a meticulous treatment planning is required. 2 dimensional analysis has been conventionally used for orthognathic surgery treatment planning and outcome prediction. 2D planning</p>
--	---

CCLicense CC-BY-NC-SA 4.0	consists of clinical examination, impressions, occlusal records, cephalometric analysis, face bow transfer, model surgery on plaster cast and fabrication of occlusal splints. But the attempt to recreate 3 dimensional structures through 2D tools is not extremely accurate, and has quite a few limitations, such as an ill fitting surgical splint. Hence over the years, 3 dimensional planning has been developed, in an attempt to make treatment prediction and outcomes for orthognathic surgery much more precise. Computer aided virtual surgical planning (VSP) offers an extremely accurate diagnosis, enhanced analysis of maxillofacial structures, and improved prectibability of post operative changes of hard and soft tissues. ¹
------------------------------	--

CBCT and application of CAD CAM and 3D printing have been the major tools to achieve 3D VSP.



Conventional 2d surgical planning

Pre-treatment procedures: Pre-treatment procedures include case history, esthetic evaluation and clinical assessment of the face.

Clinical measurements: Molar relation and canine relation are determined. Occlusal discrepancies and canting of occlusion are checked, if present.

Overjet, overbite, skeletal and dental midline harmony are measured.

Esthetic / Facial evaluation: Patient should be standing or seated comfortably. Frankfort's horizontal plane and interpupillary lines should be parallel to the floor³. Primarily, front facial esthetics is given more importance. Teeth should be in centric occlusion and lips relaxed.

In case of vertical maxillary excess and severely closed bite, evaluation should be done in open bite posture⁴.

Lateral ceph: Cephalometry is a routine diagnostic aid used for treatment planning and prediction of orthognathic surgery outcome. It helps in understanding and evaluating growth pattern and dentofacial deformities, creating the required treatment plan, to study changes during and after treatment, and to predict and evaluate the treatment results.

Cephalometric analysis are of two types - soft tissue analysis and hard tissue analysis.

COGS (Burstone) analysis consists of a coordinate system that is used to represent the shapes and sizes of the facial bones.

Postero anterior cephalometric evaluation: Apart from lateral ceph and OPG, PA (frontal) radiographs are a great source of information when it comes to diagnosis of skeletal deformities for orthognathic surgery planning.

Especially for the analysis of facial asymmetry cases, Grummon's analysis has been developed. It is more accurate and easy to perform in cases of skeletal asymmetry⁵. Together with lateral cephalometry, it makes surgical planning easier.

Panoramic radiograph: A preoperative panoramic radiograph provides a complete overview of the anatomy of the surgical site anatomy, which makes sure that the orthognathic surgery is carried out correctly and with precision.

Model analysis and development of visual treatment objective: Maxillary and mandibular stone casts are made and model analysis is carried out.

Decompensation should be done and followed by visual treatment objective.

Template Tracing and Prediction Tracing: It is the first step in the simulation of surgery.

The tracings are then moved.⁹

Facebow transfer and Articulation: The transfer of jaw relation records from the patient to the articulator is essential for accurate mounting of maxillary cast to the articulator, restoration of function, and ideal facial appearance. It establishes the relationship of the maxilla to the horizontal plane.

Model surgery: The models made out of dental stone are an accurate replica of the patient's jaws. Dental landmarks and reference points are made on the casts along with vertical or horizontal reference lines so as to determine the extent of skeletal changes needed⁷ and to approximate the amount of anteroposterior movement during surgery.

Model surgery forms the base for maxillofacial surgical planning. Maxillary and mandibular casts are separated, surgical cuts are made on the stone casts, and then remounted into the desired position following the treatment plan⁷.

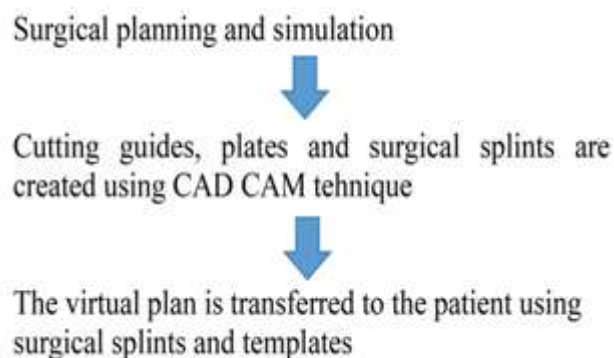
Acrylic Splint Fabrication: After reproduction of arch movement on the arch model, acrylic splint is fabricated while keeping the maxillary and mandibular casts in the ideal, planned position. Intermediate splints are fabricated in case of double jaw procedures.

Limitations of 2d: Although 2d has been used since the beginning of orthognathic surgical planning and has proven to be cost effective, does not require a lot of equipments and is still widely performed in a lot of clinical setups, it often does not prove to be extremely accurate. It is difficult to analyse all 3 dimensional structures on 2d casts, especially in cases of facial asymmetry or skeletal deformities¹. In cases of facial asymmetry, 2D cephalometric analysis does not offer accurate and in depth interpretation of saggital, coronal and horizontal planes required to diagnose the cause of asymmetry and treatment plan⁸. Replicating reference lines and performing model surgery through 2D tools are time consuming². Every step in the process leaves room for a lot of errors, that might lead to an altogether different, undesirable outcome at the end. It also requires very experienced set of hands, with thorough knowledge of the principles of orthodontics and maxillofacial surgery, besides being extremely tedious⁷.

Taking all these factors into consideration, two dimensional planning is gradually being replaced by 3D virtual surgical planning, which proves to be a better and more reliable alternative when it comes to achieving the most accurate results with significantly lesser time and manual skills.

3 dimensional virtual surgical planning - A boon: 3D VSP is a tool which brings together CAD (computer aided design) and CAM (computer aided manufacturing) for orthognathic surgical planning. Surgical manipulations to be done can be first performed virtually to obtain accurate predictions of surgical outcomes. This planning can be directly used at the time of the surgery¹⁰.

The most important advantage of 3d surgical planning has to be the elimination of manual model surgery. Even the most complex skeletal reconstructions can be planned simply with the help of maxillofacial CT scan records and digital data obtained by scanning the records.^{7,9}



Case studies

Case 1: Systematic review and meta analysis based on randomised control trials - by chen et al¹²

Randomised control trials were used to compare 3D virtual surgical planning (VSP) and traditional surgical planning (TSP). It was found that the surgical accuracy of VSP and TSP were similar in most cases, with a few exceptions. As an instance, VSP is better than TSP for soft tissue predictions. The study also showed that VSP resulted in more symmetrical outcome. The operative time is also highly reduced.

Case 2: comparison of time and cost between conventional surgical planning and virtual surgical planning in orthognathic surgery in korea - By Si-Yeon Park et al¹⁴

This was a retrospective study, conducted in South Korea, analysing the patients who underwent orthognathic surgery at Pusan National University Dental Hospital from December 2017 to August 2018.

It was found that VSP showed significant reduction in time, especially in the laboratory work. CSP leaves plenty of scope for manual errors, which reduces

significantly in VSP. However, VSP might not always be the preferred route in simple cases due to its higher cost. In complex cases, VSP proves to be highly time efficient, accurate and cost effective.

In conclusion, VSP is not always widely used because of the lack of advanced technology and cost. If the hospital is well equipped with advanced software to support VSP, it shall be preferred for more accuracy and less time consumption.

Conclusion: 3D VSP makes orthognathic surgical planning a lot faster.¹⁵ If more institutions start using advanced technologies and are financially well equipped, 3D VSP can become widespread in use and change orthognathic surgical planning for the better.

References

1. Ting-Yu Wu, Hsiu-Hsia Lin, Lun-Jou Lo, Cheng-Ting Ho, Postoperative outcomes of two- and three-dimensional planning in orthognathic surgery: A comparative study. *Journal of Plastic, Reconstructive & Aesthetic Surgery*.2017; 70(8), 2017,
2. Lin HH, Lonic D, Lo LJ. 3D printing in orthognathic surgery - A literature review. *J Formos Med Assoc*. 2018 Jul; 117(7):547-558. DOI : 10.1016/j.jfma.2018.01.008. Epub 2018 Feb 3. PMID:29398097
3. Reyneke, Johan P. (2010) *Essentials of Orthognathic Surgery* (2nd ed.). Quintessence books pub.
4. Epker, Bruce N; Fish, Leward C. (2008) *Dentofacial deformities : Integrated Orthodontic and Surgical Correction Vol. 1* . Mosby.
5. A Frontal Asymmetry Analysis VOLUME 21 : NUMBER 07 : PAGES (448-465) 1987 DUANE C. GRUMMONS, DDS, MSD MARTIN A. KAPPEYNE VAN DE COPPELLO - *journal of clinical orthodontics*
6. Alkhayer, A., Piffko, J., Lippold, . et al. Accuracy of virtual planning in orthognathic surgery: a ssemai review. *Head Fae Med* 16, 34 (2020).
7. Hammoudeh JA, Howell LK, Boutros S, Scott MA, Urata MM. Current status of surgical planning for orthognathic surgery : traditional methods vs 3D surgical planning. *Plast Reconstr Surg Glob Open*. 2015 Mar 6;3(2):e307 . doi : 10.1097/GOX.000000000000184. PMID: 25750846; PMID: PMC435031
8. Cephalometric Norms for East Indian Population using Burstone Legan Analysis Nivedita Sahoo¹ , Rajat Mohanty² , Pritam Mohanty¹ , Tushar Nayak³ , Smruti Bhushan Nanda³ , Anand Garabadu⁴

9. Virtual and traditional surgical planning in orthognathic surgery - systematic review and meta-analysis S. Alkaabi, Mevin Maningky, Marco N Helder, G. Alsabr
10. Computer-Aided Orthognathic Surgery Savannah Gelesko, DDSa , Michael R. Markiewicz, DDS, MPH, MDa , Katherine Weimer, MSb , R. Bryan Bell, DDS, MDa,c,d, *
11. Donaldson D, Manisali M, Naini FB. Three dimensional virtual surgical planning (3D-VSP) in orthognathic surgery: Advantages, disadvantages and pitfalls. J Orthod. 2021 Mar ; 48(1):52-63.doi:10.1177/1465312520954871. Epub 2020 Sep 28. PMID: 32988276.
12. Zhixing Chen, Shuixue Mo, Xuemin Fan, Yuting You, Guangrong Ye, Nuo Zhou, A Meta-analysis and Systematic Review Comparing the Effectiveness of Traditional and Virtual Surgical Planning for Orthognathic Surgery: Based on Randomized Clinical Trials, Journal of Oral and Maxillofacial Surgery, 2021; Volume 79, (Issue 2), S. Alkaabi, Melvin Maningky, Marco N Helder, G. Alsabri,
13. Virtual and traditional surgical planning in orthognathic surgery – systematic review and meta-analysis, British Journal of Oral and Maxillofacial Surgery, 2022, Volume 60 (Issue 9) ; Pages 1184-1191,
14. Comparison of time and cost between conventional surgical planning and virtual surgical planning in orthognathic surgery in Korea Si-Yeon Park , Dae-Seok Hwang , Jae-Min Song and Uk-Kyu Kim
15. Steinhuber, Thomas, Silvia Brunold, Catherina Gartner. Vincent Offermanns, Hanno Ulmer and Oliver Ploder. “Is virtual surgical planning in orthognathic surgery faster than conventional planning? A time and workflow analysis of an office based workflow for single and double jaw surgery.” Journal of Oral and Maxillofacial Surgery 76, no.2, 2018 : 397-407.