

MATUS, Iwona, BATOR, Kaja, MACHAJ, Weronika, KRZEMIENOWSKA-CEBULLA, Aleksandra, DOROCHOWICZ, Mateusz, SENAT, Hanna, KORBECKI, Adrian, SZUBA, Andrzej and RABCZYŃSKI, Maciej. Hematologic complications in vascular malformations: A case study of 2 patients. *Journal of Education, Health and Sport*. 2024;61:26-25. eISSN 2391-8306.  
<https://dx.doi.org/10.12775/JEHS.2024.61.002>  
<https://apcz.umk.pl/JEHS/article/view/48319>  
<https://zenodo.org/records/10672351>

The journal has had 40 points in Minister of Science and Higher Education of Poland parametric evaluation. Annex to the announcement of the Minister of Education and Science of 05.01.2024 No. 32318. Has a Journal's Unique Identifier: 201159. Scientific disciplines assigned: Physical culture sciences (Field of medical and health sciences); Health Sciences (Field of medical and health sciences). Punkty Ministerialne 40 punktów. Załącznik do komunikatu Ministra Nauki i Szkolnictwa Wyższego z dnia 05.01.2024 Lp. 32318. Posiada Unikatowy Identyfikator Czasopisma: 201159. Przypisane dyscypliny naukowe: Nauki o kulturze fizycznej (Dziedzina nauk medycznych i nauk o zdrowiu); Nauki o zdrowiu (Dziedzina nauk medycznych i nauk o zdrowiu).© The Authors 2024; This article is published with open access at License Open Journal Systems of Nicolaus Copernicus University in Torun, Poland Open Access. This article is distributed under the terms of the Creative Commons Attribution Noncommercial License which permits any noncommercial use, distribution, and reproduction in any medium, provided the original author (s) and source are credited. This is an open access article licensed under the terms of the Creative Commons Attribution Non commercial license Share alike. (<http://creativecommons.org/licenses/by-nc-sa/4.0/>) which permits unrestricted, non commercial use, distribution and reproduction in any medium, provided the work is properly cited. The authors declare that there is no conflict of interests regarding the publication of this paper. Received: 24.01.2023. Revised: 08.02.2024. Accepted: 16.02.2024. Published: 16.02.2024.

## Hematologic complications in vascular malformations: A case study of 2 patients

Iwona Matus<sup>1</sup>, Kaja Bator<sup>2</sup>, Weronika Machaj<sup>3</sup>, Aleksandra Krzemienowska-Cebulla<sup>4</sup>,  
Mateusz Dorochowicz<sup>5</sup>, Hanna Senat<sup>6</sup>, Adrian Korbecki<sup>7</sup>, Andrzej Szuba<sup>8</sup>, Maciej Rabczyński<sup>9</sup>

1. Faculty of Medicine, Wrocław Medical University, Wybrzeże L. Pasteura 1, 50-367 Wrocław, Poland; [iwona.matus4@gmail.com](mailto:iwona.matus4@gmail.com) ORCID ID: 0009-0008-5052-7202

2. Faculty of Medicine, Wrocław Medical University, Wybrzeże L. Pasteura 1, 50-367 Wrocław, Poland; [batorkaja@gmail.com](mailto:batorkaja@gmail.com) ORCID ID: 0009-0001-0288-0238

3. Division of General and Interventional Radiology and Neuroradiology, Wrocław Medical University, Borowska 213, 50-556 Wrocław, Poland; [wnmachaj@gmail.com](mailto:wnmachaj@gmail.com) ORCID ID: 0009-0004-7240-479X

4. Faculty of Medicine, Wrocław Medical University, Wybrzeże L. Pasteura 1, 50-367 Wrocław, Poland; [krzemienowskaa@gmail.com](mailto:krzemienowskaa@gmail.com) ORCID ID: 0000-0002-5440-7143

5. Faculty of Medicine, Wrocław Medical University, Wybrzeże L. Pasteura 1, 50-367 Wrocław, Poland; [m.dorochowicz@outlook.com](mailto:m.dorochowicz@outlook.com) ORCID ID: 0009-0000-0730-6123

6. Faculty of Medicine, Wrocław Medical University, Wybrzeże L. Pasteura 1, 50-367 Wrocław, Poland; [hannasenat1@gmail.com](mailto:hannasenat1@gmail.com) ORCID ID: 0009-0009-3862-5827

7. Division of General and Interventional Radiology and Neuroradiology, Wrocław Medical University, Borowska 213, 50-556 Wrocław, Poland; [lek.adriankorbecki@gmail.com](mailto:lek.adriankorbecki@gmail.com) ORCID ID: 0000-0003-0047-9819

8. Clinical Department of Angiology and Internal Diseases, Wrocław Medical University, Borowska 213, 50-556 Wrocław, Poland; [andrzej.szuba@umw.edu.pl](mailto:andrzej.szuba@umw.edu.pl) ORCID ID: 0000-0002-7555-6201

9. Clinical Department of Diabetology and Internal Diseases, Medical University, Borowska 213, 50-556 Wrocław, Poland; [maciejrabczynski@gmail.com](mailto:maciejrabczynski@gmail.com) ORCID ID: 0000-0001-5426-5475

## SUMMARY

We present two cases of patients treated at the Angiology, Arterial Hypertension and Diabetology Clinic of the Wrocław Medical University (UMW) due to vascular malformations, where LIC (localized intravascular coagulation), DIC (disseminated intravascular coagulation) and KMS (Kasabach-Merritt syndrome) occurred. The first case involves a 14-year-old boy admitted with a diagnosis of vascular malformation of the lower limb established at the age of 3. The patient was admitted for the initiation of Sirolimus therapy. The second patient is a 33-year-old man diagnosed with a malformation of the left lower limb involving the pelvis, abdominal cavity, and chest, currently admitted due to coagulation disorders, complicated by life-threatening Kasabach-Merritt syndrome (KMS). The phenomenon occurred after a limb injury.

Key words: vascular malformation, LIC, DIC, Kasabach-Merritt syndrome

## ABSTRACT

Vascular malformations are congenital vascular anomalies resulting from a disruption in the vasculogenesis process. (1) They are congenital changes that enlarge as the child develops and do not undergo spontaneous involution. They can be classified based on the type of vessels involved (capillary, arterial, venous, lymphatic, mixed) and the nature of the vascular flow (low-flow and high-flow). The clinical presentation of vascular malformations is highly diverse, and despite being congenital, they can remain asymptomatic for a long time, complicating the diagnostic process. (1,3)

The presence of malformations carries the risk of health-threatening complications. One such complication is Kasabach-Merritt syndrome, characterized by thrombocytopenia, microangiopathic hemolytic anemia, and consumptive coagulopathy in the presence of a rapidly enlarging vascular tumor. (4,5) Another threat is a coagulopathy limited to the vascular anomaly (LIC). It is characterized by elevated D-dimers and fibrin degradation products, low levels of fibrinogen, FV, FVIII, FXIII, and antithrombin, and sometimes mild to moderate thrombocytopenia. (6,7) Early implementation of anticoagulant therapy allows for the avoidance of health-threatening conditions and the development of disseminated intravascular coagulation syndrome (DIC). (8)

## CASE REPORTS

A 14-year-old boy was admitted to the Department of Angiology. After the child's birth, parents noticed a disproportion in the size of the infant's calves. Magnetic resonance imaging (MRI) was performed, revealing a nodular change affecting the soft tissues and to a lesser extent the bones of the left lower leg. At the age of 3, a diagnosis of vascular malformation of the left lower limb was made. Since then, the boy had been under the care of the pediatric surgery department, where the malformation was regularly monitored through MRI examinations. In 2019, there was a

limitation of mobility in the knee joint of the limb affected by the malformation. Arthroscopy with the use of low molecular weight heparin in a therapeutic dose was performed. In November 2021, the patient presented with pain in the left lower limb. At that time, elevated levels of D-dimers (16.29  $\mu\text{g/ml}$ ), prolonged thrombin time (TT) (17.7 s) and activated partial thromboplastin time (APTT) (41.7 s) were observed. Prothrombin time was at the upper limit of the norm (13 s), and fibrinogen activity was decreased (1.27 g/l). Additionally, the patient had microcytic anemia.

In January 2022, a pelvic MRI was performed, revealing an intramuscular vascular malformation on the posterior-medial surface of the left thigh supplied by internal iliac veins. The change extended throughout the length of the thigh in the examination range, mainly involving the adductor magnus muscle, adductors, and subcutaneous tissue of the perineum on the left side. Two months later, blood tests were repeated, and the persistent anemia and high D-dimer levels (18.43  $\mu\text{g}$ ) led to the diagnosis of LIC (limited intravascular coagulopathy) in the course of an extensive vascular malformation.

The scope of the MRI examination was extended to the area of the lower leg and left foot (fig.1). A comprehensive vascular malformation involving the muscle structures of the posterior group of the left lower leg along its entire length was visualized (with sparing of the greater part of the medial and lateral heads of the gastrocnemius muscle). There were small components penetrating intramuscularly and intermuscularly and involving the anterior and lateral compartments of the lower leg. After contrast agent administration, the malformation showed partial intense enhancement, increasing in subsequent phases of the examination. There was moderate dilatation of the venous vessels within the midshaft of the femur and tibia. In the distal part, along the end portions of the belly and the tendon of the long flexor of the big toe, the malformation extended to the level of the posterior ankle joint, occupying the upper part of Kager's fat pad and the ankle canal. The remaining soft tissues of the foot showed no signs of malformation. There was a trace of fluid in the posterior ankle joint, without structural damage. Mild patchy marrow edema of the bone structures of the foot within the norm for the age. Clear stress-related changes in the bipartite medial sesamoid of the big toe with signal reduction in both fragments, raising suspicion of necrosis. Flattening of tissue density in the subcutaneous tissue on the plantar side of the V metatarsal head, suggestive of stress-related changes.

It was decided to initiate treatment with enoxaparin at a dose of 40 mg/day – the boy’s weight was 49 kilograms. Consent for immunosuppressive treatment with sirolimus (rapamycin) was obtained from the patient and his guardians. Despite the therapy carrying the risk of adverse effects such as decreased fertility (9), improvement was achieved, and the patient was discharged from the hospital. The patient remains under outpatient follow-up.

A 33-year-old man was admitted to the department of angiology on an emergency basis due to pain and swelling in the left lower limb and signs of bleeding disorder. Symptoms appeared 2 months earlier after a traumatic injury. During the physical examination, the patient’s attention was drawn to the bluish-red discoloration and swelling of the left lower limb. Laboratory tests revealed severe normocytic anemia, thrombocytopenia (50 G/l), and life-threatening coagulation disorders – significant hypofibrinogenemia (0.5 g/l), prolonged TT, PT, and APTT, reduced levels of coagulation factors V and VIII, and a very high D-dimer concentration (>50 µg/ml).

Considering the results of laboratory tests, clinical presentation, and the recognized features of vascular malformation in the left lower limb diagnosed in 2016, a preliminary diagnosis of disseminated intravascular coagulation (DIC) was established. The patient underwent cryoprecipitate, red blood cell mass, and platelet substitution. A computed tomography (CT) scan revealed numerous soft tissue structures consistent with vascular changes located in the fat tissue of the thigh and abdomen, between the portal vein and inferior vena cava, in the splenic hilum, mesentery, and pelvic region, as well as the sacral area (fig. 2,3). Additionally, an enlarged thoracic duct, numerous well-defined bone structure rarifications in the left iliac, pubic, ischial, femoral, and tibial bones were visualized. Suspicions of a massive vascular tumor were raised, and a biopsy under CT guidance was recommended. Due to uncontrolled hemostasis, invasive testing was abandoned, and a positron emission tomography (PET) scan was decided upon. The PET scan did not reveal signs of a proliferative disease with high fluorodeoxyglucose metabolism. The diagnosis was narrowed down to LIC/KMS. Combined treatment with Sirolimus, prednisone, and low molecular weight heparin was initiated. There was an increase in fibrinogen concentration (1.18 g/l), platelet count (176 G/l), and normalization of coagulation parameters. A reduction in limb swelling and alleviation of pain were also observed. In the chronic treatment

plan, direct oral anticoagulants (Pradaxa 2 x 150 mg), Rapamune 2 x1 g, and Encorton 50 mg with a tapering recommendation to 20 mg were proposed. After 2 months, a follow-up examination showed the normalization of blood morphology parameters and regression of imaging findings. The existing treatment plan was maintained. Pregabalin and duloxetine were introduced, resulting in the complete relief of pain symptoms. Currently, the patient remains under the constant care of the Clinic of Angiology, and his condition is stable. After two years, a bone scintigraphy was performed, revealing increased tracer accumulation in the tibial bone of the left lower limb. This prompted further diagnostics, and an MRI of the lower leg and thigh on the left side was conducted.

## DISCUSSION

Venous malformation (VM), formerly known as “cavernous hemangioma”, is the most common congenital vascular anomaly characterized by slow blood flow. (10) It is a cluster of twisted and interconnected veins in soft tissue, caused by congenital anomalies in the development of the venous network. These malformations can occur anywhere in the body. (11,12,13) Vascular malformations, including VM, lymphovenous malformation, and capillary-venous malformation, which often present as diffuse and multifocal changes, may be complicated by limited intravascular coagulopathy (LIC). Coagulopathy is common in patients with slow-flow vascular malformations, and LIC occurs in approximately 58% of patients with VMs. LIC is characterized by elevated D-dimers and fibrin degradation products (14), low levels of fibrinogen, factors V, VIII, XIII, and antithrombin, and sometimes mild to moderate thrombocytopenia. (15) LIC rarely leads to serious bleeding or severe thrombosis. Surgical resection, sclerotherapy, embolization, trauma, infection, or medication influence can transform LIC into DIC, exacerbating pain and posing life-threatening risks. (16,17)

Another potentially life-threatening complication is Kasabach-Merritt syndrome, associated with congenital venous malformations. (18) This syndrome is very rare and usually develops in infants, on average at 5 weeks of age. Kasabach-Merritt syndrome (KMS) is most commonly associated with a large (>5 cm) solitary tumor characterized by rapid growth, located in the limbs, trunk, face, or neck. (19) Most tumors are subcutaneous or in deep structures and are locally malignant.

The skin over the tumor is reddish or purple with a surrounding ring of bleeding. The disease manifests with severe thrombocytopenia and microangiopathic hemolytic anemia in the presence of a rapidly growing vascular tumor. Mortality in treated cases is less than 10%, but in the presence of extraperitoneal tumors, it can increase to 60%. The overall mortality ranges from 12% to 50% and is associated with severe bleeding related to DIC, local invasion into vital organs, heart failure, multiorgan failure, and sepsis. (20,21)

The main imaging methods used for diagnosing vascular malformations are Doppler ultrasound (USG Doppler) and magnetic resonance imaging (MRI). (22,23) Doppler ultrasound is a useful, non-invasive imaging technique that should be used as the first method when investigating the presence of vascular malformations, especially in cases of superficial or limb lesions. (24,25) Other advantages include its widespread availability in clinical settings, low cost, and lack of ionizing radiation, which is crucial, especially in young patients. (26) The development of magnetic resonance imaging techniques has led to significant progress in non-invasive diagnostics of vascular malformations. Images of pathological changes and soft tissues are much clearer, especially compared to computed tomography (CT). (27) It also avoids exposure to ionizing radiation, and 3D reconstruction is superior to CT. (28) Contrast-enhanced MRI is therefore the preferred imaging method in preoperative diagnosis and postoperative evaluation of vascular malformations. Conventional magnetic resonance imaging has a sensitivity and specificity of 100% and 24% to 33%, respectively, in distinguishing VM from other lesions. (29,30)

The treatment we applied to both patients was effective in alleviating symptoms, reducing the risk of hematological complications, and aligns with current pharmacotherapy algorithms for patients with slow-flow vascular malformations.

## CONCLUSIONS

To avoid complications in the course of vascular malformations, it is crucial to monitor the morphology and coagulation parameters, especially hemoglobin, platelet count, D-dimers, and fibrinogen. Any deviation in these tests should prompt us to investigate for coagulopathy. Early intervention allows for the implementation of appropriate therapeutic measures before the development of conditions such as limited intravascular coagulopathy (LIC), disseminated

intravascular coagulation (DIC), or Kasabach-Merritt syndrome (KMS), thereby preventing life-threatening situations. (31)

## CONFLICT OF INTEREST

The authors declare no financial or personal relationships with other individuals or organizations that could negatively influence the content of the publication, and they assert the right to this publication.

## BIBLIOGRAPHY

1. Lee BB, Bergan J, Gloviczki P, et al. Diagnosis and treatment of venous malformations – Consensus Document of the International Union of Phlebology (IUP)-2009. *Int Angiol* 2009;28:434–51
2. Niwald, Anna, et al. “Rzadki Przypadek Malformacji Naczyniowej Umiejscowionej W Okolicy Okołoławkowej.” *Family Medicine & Primary Care Review*, [cejsh.icm.edu.pl/cejsh/element/bwmeta1.element.desklight-86bc8dea-3618-4de6-8f2b-7378b14dc3c2](http://cejsh.icm.edu.pl/cejsh/element/bwmeta1.element.desklight-86bc8dea-3618-4de6-8f2b-7378b14dc3c2).
3. Zheng JW, Zhou Q, yang XJ, et al. Treatment guideline for hemangiomas and vascular malformations of the head and neck. *Head Neck* 2010; 32(8): 1088–1098.
4. Lewis D, Vaidya R. Kasabach-Merritt Syndrome. 2023 Jul 17. In: *StatPearls. Treasure Island (FL): StatPearls Publishing; 2023 Jan–*. PMID: 30085595.
5. Gözdaşoğlu S. Kasabach-Merritt Syndrome in an Adult: A Comment. *Turk J Haematol*. 2019 Feb 07;36(1):52-53
6. Martin LK, Russell S, Wargon O. Chronic localized intravascular coagulation complicating multifocal venous malformations. *Australas J Dermatol* 2009; 50: 276–280.
7. Han Y-Y, Sun L-M, Yuan S-M. Localized intravascular coagulation in venous malformations: A system review. *Phlebology*. 2021;36(1):38-42.
8. Binet Q, Lambert C, Hermans C. Dabigatran etexilate in the treatment of localized intravascular coagulopathy associated with venous malformations. *Thromb Res* 2018; 168: 114–120.



9. [https://www.ema.europa.eu/en/documents/scientific-discussion/rapamune-epar-scientific-discussion\\_en.pdf](https://www.ema.europa.eu/en/documents/scientific-discussion/rapamune-epar-scientific-discussion_en.pdf)
10. Folkman J, D'Amore PA. Blood vessel formation: What is its molecular basis? *Cell* 1996;87:1153-5.
11. Mulliken JB, Burrows PE, Fishman SJ. *Mulliken and Young's vascular anomalies: hemangiomas and malformations*. Oxford, UK: Oxford University Press, 2013.
12. Mazoyer E, Enjolras O, Bisdorff A, et al. Coagulation disorders in patients with venous malformation of the limbs and trunk: A case series of 118 patients. *Arch Dermatol* 2008; 144: 861–867.
13. Enjolras O, Mulliken JB. Vascular tumors and vascular malformations (new issues). *Adv Dermatol* 1997;13375- 423
14. Budge EJ, Khalil Allam MA, Mechie I, Scully M, Agu O, Lim CS. Venous malformations: Coagulopathy control and treatment methods. *Phlebology*. 2021;36(5):361-374.
15. Mack JM, Richter GT, Crary SE. Effectiveness and safety of treatment with direct oral anticoagulant rivaroxaban in patients with slow-flow
16. Maruani A; Tavernier E; Boccara O; Mazereeuw-Hautier J; Leducq S; Bessis D; Guibaud L; Vabres P; Carmignac V; Mallet S; Barbarot S; Chiaverini C; Droitcourt C; Bursztejn AC; Lengellé C; Woillard JB; Herbreteau D; Le Touze A; Joly A; Léauté-Labrèze C; Powell J; Bourgoin H; Giss. “Sirolimus (Rapamycin) for Slow-Flow Malformations in Children: The Observational-Phase Randomized Clinical Performus Trial.” *JAMA Dermatology*, [pubmed.ncbi.nlm.nih.gov/34524406/](https://pubmed.ncbi.nlm.nih.gov/34524406/).
17. Mazereeuw Hautier J, Syed S, Leisner RI, et al. Extensive venous/lymphatic malformations causing life-threatening haematological complications. *Br J Dermatol* 2007; 157: 558–563.
18. Pavlyshyn, Halyna, and Nataliia Luchyshyn. “Kasabach-Merritt Syndrome in an Infant with Cavernous Haemangioma.” *Pediatrics Polska - Polish Journal of Paediatrics*, 31 Mar. 2020, [www.termedia.pl/Kasabach-Merritt-syndrom-in-aninfant-with-cavernous-haemangioma,127,40550,0,1.html](http://www.termedia.pl/Kasabach-Merritt-syndrom-in-aninfant-with-cavernous-haemangioma,127,40550,0,1.html).
19. Alaqeel, A. M., Alfurayh, N. A., Alhedyani, A. A., & Alajlan, S. M. (2016). Sirolimus for treatment of kaposiform hemangioendothelioma associated with Kasabach-Merritt phenomenon. *JAAD Case Reports*, 2(6), 457–461.

20. "Medycyna Praktyczna." *Zespół Kasabacha i Meritt - Małopłytkowości „obwodowe” Nieimmunologiczne - Małopłytkowości - Skazy Krwotoczne Płytkowe - Zaburzenia Hemostazy - Hematologia i Onkologia - Pediatria - Podręcznik Multimedialny Oparty Na Zasadach EBM - Medycyna Praktyczna,*
21. Maguiness, S., & Guenther, L. (2002). Kasabach-merritt syndrome. *Journal of Cutaneous Medicine and Surgery*, 6(4), 335–339
22. Dubois J, Patriquin HB, Garel L, et al. Soft-tissue hemangiomas in infants and children: diagnosis using Doppler sonography. *AJR* 1998; 171:247-252
23. Meyer JS, Hoffer FA, Barnes PD, Mulliken JB. Biological classification of soft-tissue vascular anomalies: MR correlation. *AJR* 1991; 157:559-564
24. Lee BB, Baumgartner I, Berlien P, et al. Diagnosis and Treatment of Venous Malformations. Consensus Document of the International Union of Phlebology (IUP): updated 2013. *Int Angiol* 2015;34:97-149.
25. Legiehn GM, Heran MK. A Step-by-Step Practical Approach to Imaging Diagnosis and Interventional Radiologic Therapy in Vascular Malformations. *Semin Intervent Radiol* 2010;27:209-31. 10.1055/s-0030-1253521
26. Legiehn G M, Heran M K. Classification, diagnosis, and interventional radiologic management of vascular malformations. *Orthop Clin North Am.* 2006;37(03):435–474, vii–viii.
27. Majewska NK, Stajgis P, Wykrętowicz M, Stajgis M, Oszkinis G, Katulska K. Peripheral vascular malformations - modern imaging. *Pol J Radiol.* 2018;83:e253–e259. doi: 10.5114/pjr.2018.75724.
28. Lowe L H, Marchant T C, Rivard D C, Scherbel A J. Vascular malformations: classification and terminology the radiologist needs to know. *Semin Roentgenol.* 2012;47(02):106–117.
29. Behraves S, Yakes W, Gupta N, Naidu S, Chong BW, Khademhosseini A, Oklu R. Venous malformations: clinical diagnosis and treatment. *Cardiovasc Diagn Ther.* 2016 Dec;6(6):557-569. doi: 10.21037/cdt.2016.11.10. PMID: 28123976; PMCID: PMC5220204.

30. van Rijswijk CS, van der Linden E, van der Woude HJ, et al. Value of dynamic contrast-enhanced MR imaging in diagnosing and classifying peripheral vascular malformations. *AJR Am J Roentgenol* 2002;178:1181-7. 10.2214/ajr.178.5.1781181
31. Osifo OD, Evbuomwan I. Hemangiomas in Children: Challenges and Outcome of Surgical Management in Benin City, Nigeria. *Iran J Pediatr* 2011; 21: 350-356.

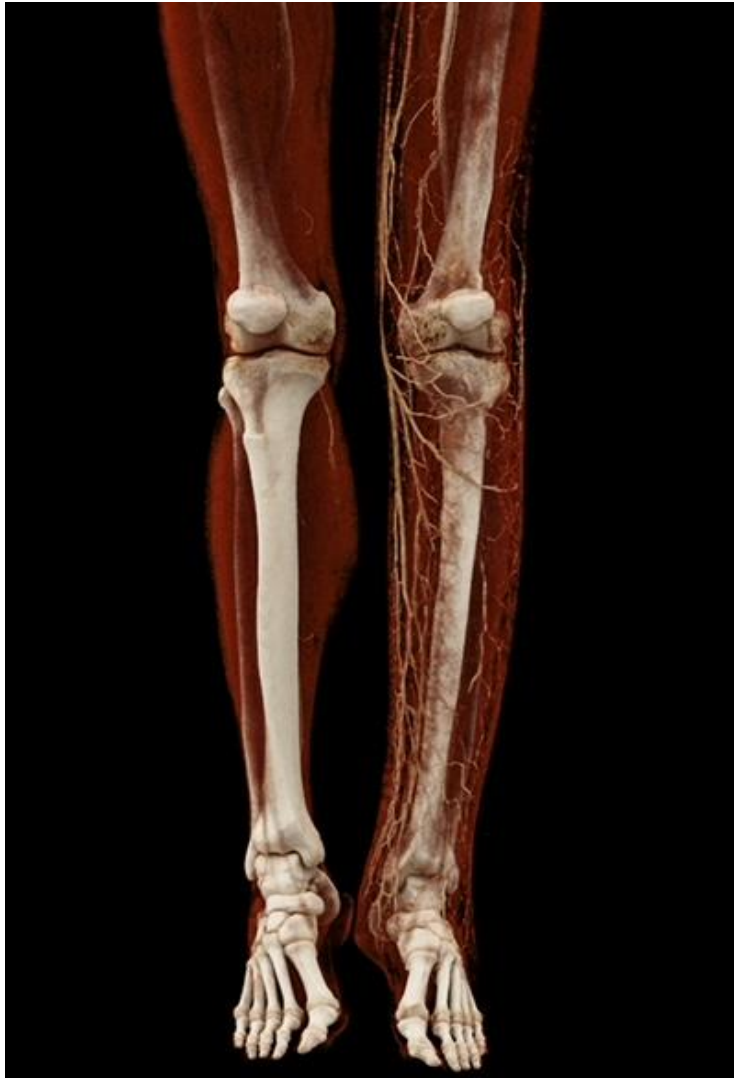

Figure 1. CT VR, numerous spreading vascular structures in the subcutaneous tissue of the left thigh and lower leg. Intensified vascular network in the midshaft of the left femur, tibia, and fibula. Generalized atrophy in the muscle structures of the left thigh and lower leg.

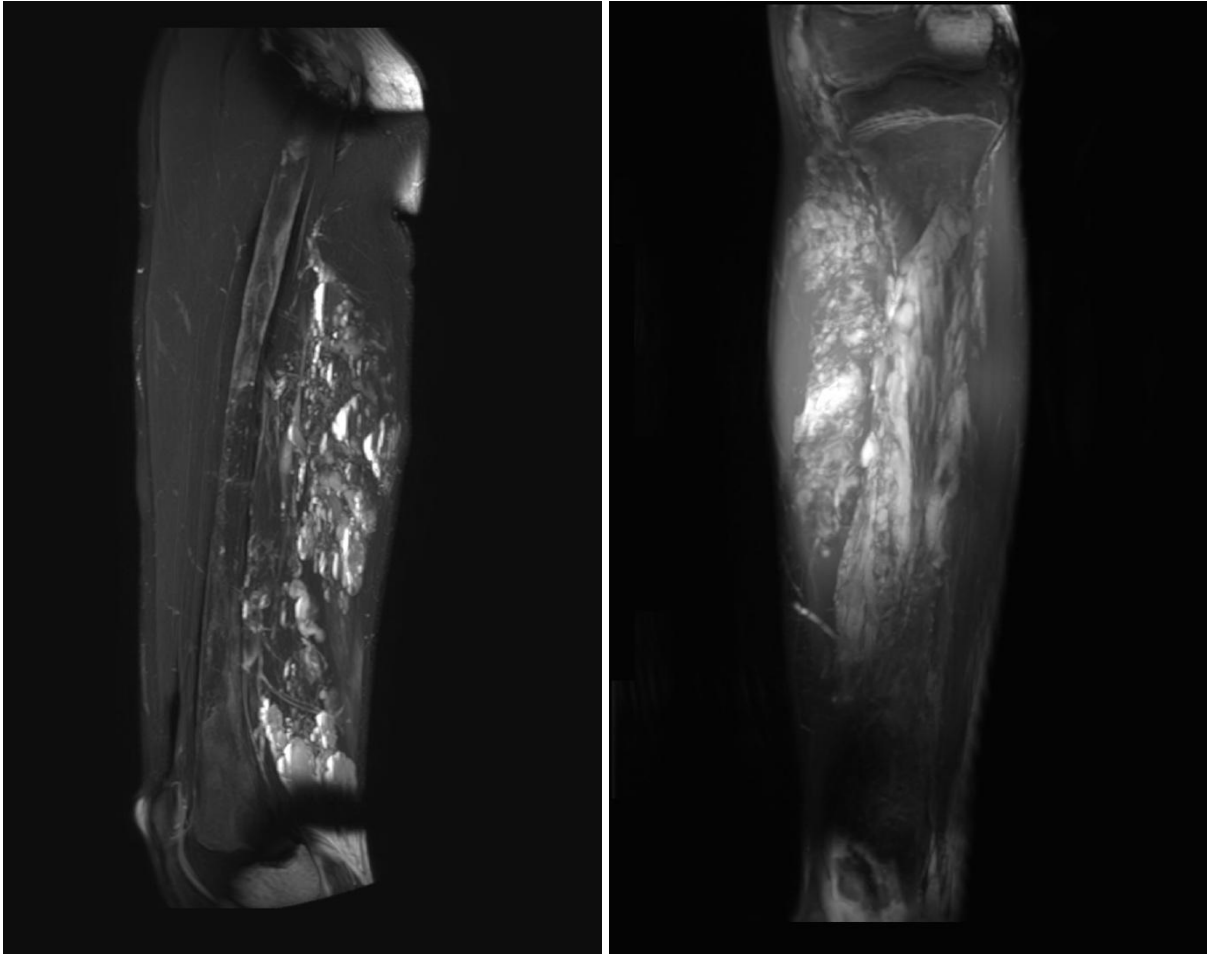


Fig. 2, Fig. 3. MRI T2W TSE, extensive low-flow intramuscular vascular malformation with the main component at the level of the lower extremity in the deep muscles of the posterior group and the soleus muscle, reaching downward to the upper limit of the tarsal tunnel.

Authors Contribution: Conceptualization, IM, KB and WM; methodology, MD and AK; check, AK-C and IM; formal analysis, WM; writing - rough preparation, IM, MD and AK-C; writing - review and editing, KB, HS; supervision, MR, AS; project administration, HS; receiving funding, AK. All authors have read and agreed with the published version of the manuscript.

Founding Statement: This study didn't acquire external funding.

Institutional Review Board Statement: Not applicable

Informed consent statement: Not applicable

Conflicts of Interest: The authors declare no conflict of interest.