



Review – Bladder Cancer

The Diagnostic Accuracy of Cystoscopy for Detecting Bladder Cancer in Adults Presenting with Haematuria: A Systematic Review from the European Association of Urology Guidelines Office

Wout Devlies^a, Joep J. de Jong^b, Fabian Hofmann^c, Harman Max Bruins^d, Tahlita C.M. Zuiverloon^e, Emma Jane Smith^f, Yuhong Yuan^g, Bas W.G. van Rhijn^h, Hugh Mostafidⁱ, Nancy Santesso^j, Phil Violette^{k,l}, Muhammad Imran Omar^{m,*}

^a Department of Urology, UZ Leuven, Leuven, Belgium; ^b Department of Urology, Erasmus University Medical Center, Rotterdam, The Netherlands; ^c Department of Urology, Umeå University, Luleå, Sweden; ^d Department of Urology, Zuyderland Medical Center, Sittard-Geleen/Heerlen, The Netherlands; ^e Department of Urology, Erasmus MC Cancer Institute, Rotterdam, The Netherlands; ^f EAU Guidelines Office, Arnhem, The Netherlands; ^g Department of Medicine, McMaster University, Hamilton, ON, Canada; ^h Department of Surgical Oncology (Urology), Netherlands Cancer Institute, Antoni van Leeuwenhoek Hospital, Amsterdam, The Netherlands; ⁱ Department of Urology, Royal Surrey Hospital, Guildford, UK; ^j Department of Health Research Methods Evidence and Impact, McMaster University, Hamilton, ON, Canada; ^k Department of Surgery, McMaster University, Hamilton, ON, Canada; ^l Department of Health Research Methods, Evidence and Impact, McMaster University, Hamilton, ON, Canada; ^m Academic Urology Unit, University of Aberdeen, Aberdeen, UK

Article info

Article history:

Accepted August 11, 2023

Available online 24 August 2023

Associate Editor: Christian Gratzke

Keywords:

Cystoscopy
Haematuria
Early detection
Accuracy
Systematic review

Abstract

Context: Haematuria can be macroscopic (visible haematuria [VH]) or microscopic (non-visible haematuria [NVH]), and may be caused by a number of underlying aetiologies. Currently, in case of haematuria, cystoscopy is the standard diagnostic tool to screen the entire bladder for malignancy.

Objective: The objective of this systematic review is to determine the diagnostic test accuracy of cystoscopy (compared with other tests, eg, computed tomography, urine biomarkers, and urine cytology) for detecting bladder cancer in adults.

Evidence acquisition: A systematic review of the literature was performed according to the *Cochrane Handbook for Systematic Reviews of Diagnostic Test Accuracy* and Preferred Reporting Items for Systematic Reviews and Meta-analyses (PRISMA) extension for diagnostic test accuracy studies' checklist. The MEDLINE, Embase, Cochrane CENTRAL, and Cochrane CDSR databases (via Ovid) were searched up to July 13, 2022. The population comprises patients presenting with either VH or NVH, without previous urological cancers. Two reviewers independently screened all articles, searched reference lists of retrieved articles, and performed data extraction. The risk of bias was assessed using Quality Assessment of Diagnostic Accuracy Studies (QUADAS-2).

Evidence synthesis: Overall, nine studies were included in the qualitative analysis. Seven out of nine included trials covered the use of cystoscopy in comparison with radiological imaging. Overall, sensitivity of cystoscopy ranged from 87% to 100%, specificity from 64% to 100%, positive predictive value from 79% to 98%, and negative predictive values between 98% and 100%. Two trials compared enhanced or air cystoscopy versus conventional cystoscopy. Overall sensitivity of conventional white light cystoscopy ranged from 47% to 100% and specificity from 93.4% to 100%.

* Corresponding author. Academic Urology Unit, Health Sciences Building, University of Aberdeen, Foresterhill, Aberdeen AB25 2ZD, UK. Tel.: +441224438126.
E-mail address: m.i.omar@abdn.ac.uk (M.I. Omar).

Conclusions: The true accuracy of cystoscopy for the detection of bladder cancer within the context of haematuria has not been studied extensively, resulting in inconsistent data regarding its performance for patients with haematuria. In comparison with imaging modalities, a few trials have prospectively assessed the diagnostic performance of cystoscopy, confirming very high accuracy for cystoscopy, exceeding the diagnostic value of any other imaging test.

Patient summary: Evidence of tests for detecting bladder cancer in adults presenting with haematuria (blood in urine) was reviewed. The most common test used was cystoscopy, which remains the current standard for diagnosing bladder cancer.

© 2023 The Author(s). Published by Elsevier B.V. on behalf of European Association of Urology. This is an open access article under the CC BY license (<http://creativecommons.org/licenses/by/4.0/>).

1. Introduction

Haematuria can be either visible (VH) or nonvisible (NVH), detectable only on urine analysis. This distinction is important as it determines the likelihood of finding urinary tract malignancy and can be suggestive for different underlying aetiologies [1]. Urothelial bladder cancer (UBC) is the most common urinary tract malignancy and the tenth most common malignancy and often presents with painless VH [1]. The estimated risk of UBC ranges from 1.6% in patients presenting with NVH up to 9% in VH [2].

Visualisation of the bladder by cystoscopy has been the cornerstone diagnostic tool to inspect the entire bladder for malignancy or other (benign) abnormalities in case of haematuria. As such, most guidelines advise performing a cystoscopy in case of VH [3,4]. For NVH, however, controversies exist regarding the additive value of a diagnostic cystoscopy, given the lower prevalence of UBC in this subpopulation [5,6]. Clinical practice guidelines differ on recommendations for which patients warrant further investigation in case of NVH. There are differences regarding age thresholds and patient characteristics. These controversies are partly due to the high prevalence of NVH in the general population and the relatively low risk of underlying urological malignancies [5].

Over the years, cystoscopy has evolved from rigid cystoscopy under general anaesthesia to flexible cystoscopy as an outpatient procedure using local anaesthesia. More recently, enhanced cystoscopic modalities, such as fluorescence/photodynamic cystoscopy, narrow band imaging, and/or confocal laser endomicroscopy, have become available. Although urinary biomarkers have been studied with the aim of reducing the number of cystoscopies, currently no urine-based markers other than cytology are used routinely in clinical practice.

Although cystoscopy is commonly used as a diagnostic tool for the detection of UBC in VH and NVH, data regarding the diagnostic accuracy of cystoscopy itself are limited. Moreover, cystoscopy is an invasive procedure associated with complications such as urinary tract infection, bleeding, bladder perforation, scar tissue formation, and urinary retention that is more common in men with pre-existing urination problems. The aim of this systematic review was to assess the diagnostic accuracy of cystoscopy for UBC in patients with NVH and VH.

2. Evidence acquisition

2.1. Review protocol and search strategy

The protocol of this study was a priori registered in PROSPERO, and the protocol is available online (CRD420202431). This systematic review was reported according to the Preferred Reporting Items for Systematic Reviews and Meta-analyses (PRISMA) for diagnostic test accuracy [7] and performed according to the Cochrane methods for systematic reviews of diagnostic test accuracy and the EAU Guidelines Office Methods Committee recommendations [8,9]. Studies that reported the use of cystoscopy for detecting bladder malignancies in adult patients with haematuria were identified. The full search strategy is included in the [Supplementary material](#). Databases searched included MEDLINE, Embase, Cochrane CENTRAL, and Cochrane CDSR databases (via Ovid), and the search was performed until July 13, 2022. Studies written in English and published from 1990 onwards were considered for inclusion.

2.2. Eligibility criteria

Only prospective studies were included in this systematic review. All other designs were excluded.

The population comprises patients presenting with either VH or NVH, without previous urological cancers. There is no uniform definition for NVH; thus, in this systematic review the authors' descriptive definition stated in each study was used. Studies in children, on urothelial malignancies before the start of the study, and on diagnosis of haemorrhagic cystitis were excluded.

2.3. Data collection

Two review authors independently extracted data (W.D. and J.d.J.). Any disagreements were resolved by discussion or by consulting a third review author (F.H. and M.B.). A standardised data extraction form was developed and piloted before its use. In case of incompletely reported data, manuscript authors were contacted and asked for additional information. Extracted data for inclusion within the "characteristics of included studies" table consisted of study design; countries and institutions where the data were

collected; patient characteristics, tumour characteristics, and the use of index and reference standard tests; losses and exclusions of participants, with reasons; and diagnostic 2×2 table with the four cells: the number of true positives, false negatives, false positives, and true negatives, and reported accuracies.

2.4. Data analysis

When investigating the actual performance of cystoscopy, one should be able to confirm the diagnosis using a gold standard examination that is histological confirmation. Therefore, positive cystoscopies were divided into true and false positives based upon pathological confirmation of malignant bladder tissue obtained via transurethral resection. In contrast, defining true and false negatives is more challenging in patients with a negative cystoscopy, as in most cases, no further examinations are planned or a standardised follow-up protocol is lacking. We therefore implemented a surrogate gold standard in cases with a negative cystoscopy, which was defined as either no malignancy at transurethral resection and/or absence of urothelial cancer within 12 mo after the initial negative cystoscopic evaluation.

In the prospective diagnostic studies identified, cystoscopy was mainly used as a comparator rather than as a follow-up strategy, thereby invalidating the 12 mo surrogate endpoint of cancer development. To overcome the lack of specified follow-up after a negative cystoscopy, we defined the alternative gold standard as negative on diagnostic imaging modalities and/or urine analyses.

We also assessed the sensitivity and specificity of alternative cystoscopic techniques (index) compared with conventional white light (WL) cystoscopy (comparator).

Performance metrics for outcomes included sensitivity, specificity, positive predictive value, negative predictive value, (surrogate) true negatives, true positives, (surrogate) false negatives, and false positives for cystoscopy. [Table 1](#) summarises the eligibility criteria of the studies that were included in this systematic review.

2.5. Risk of bias of studies and GRADE assessment of the body of evidence

The risk of bias (RoB) was determined using the 11 items from the Quality Assessment of Diagnostic Accuracy Studies

(QUADAS-2) tool as recommended by the Cochrane Collaboration [10]. The RoB of each study was assessed independently by two authors (W.D. and J.d.J.). Disagreements were resolved by consensus or consultation of a third review author (M.B./F.H.). Different criteria that were evaluated are the following: representative spectrum, acceptable reference standard, acceptable delay between tests, partial verification avoided, incorporation avoided, index test blinded, reference standard results blinded, relevant clinical information, uninterpretable results avoided, and withdrawals explained. RoB summary and graph figures were generated using the Cochrane Review Manager version 5.4.1 (RevMan; The Cochrane Centre, Copenhagen, Denmark). The overall RoB level was judged as “low”, “intermediate”, or “high”. The overall certainty of the body of evidence for the sensitivity and specificity of cystoscopy was assessed using the GRADE approach for test accuracy [9]. We considered the overall RoB across studies, inconsistency, imprecision, indirectness, and publication bias to judge the evidence as of high, moderate, low, or very low certainty.

3. Evidence synthesis

3.1. Study population

From the initial 1730 records screened, a total of nine studies were eligible for inclusion for a qualitative analysis ([Fig. 1](#)). This low number of eligible studies was caused by a lack of prospective trials that were primarily investigating the accuracy of cystoscopy. As such, most studies used cystoscopy as the gold standard, whereas we defined either pathological confirmation of malignant bladder tissue (positive reference) or no malignancy at transurethral resection and/or absence of urothelial cancer within 12 mo after the initial negative cystoscopic evaluation (negative reference) as the reference standard for this review. In this context, we found several studies that studied the follow-up after negative initial evaluation [11–14]. However, most of these studies did not report information on the number of false positive cystoscopies (ie, a suspicious lesion at cystoscopy with negative transurethral resection of a bladder tumour) and therefore were not included in this review. From the eligible studies, our results are represented in two parts: comparison of conventional cystoscopy with imaging and with other cystoscopic modalities. Demographic

Table 1 – Eligibility criteria

Study design	Only prospective studies were included in this systematic review. All other designs were excluded
Participants	Inclusion criteria: The population comprises patients presenting with either VH or NVH, without previous urological cancers. There is no uniform definition for NVH; thus, in this systematic review the authors' descriptive definition stated in each study was used Exclusion criteria: Case reports, studies in children, urothelial malignancies before the start of the study, and diagnosis of haemorrhagic cystitis
Index tests	Cystoscopy (conventional or enhanced) Enhanced may include fluorescence/photodynamic cystoscopy, narrow band imaging, confocal laser endomicroscopy
Comparator tests	Diagnostic tests other than index test, consisting of all cytology, investigational assays, or imaging
Reference standards	Positive reference: pathological examination of abnormal bladder tissue Negative reference: negative TURb or absence of urothelial cancer within 12 mo after negative cystoscopy, if TURb is not performed. This is assessed by the study investigators
Test accuracy measures	Any metric pertaining to diagnostic accuracy for cystoscopy, including sensitivity, specificity, negative/positive predictive value, and overall accuracy
NVH = nonvisible haematuria; TURb = transurethral bladder pathological examination; VH = visible haematuria.	

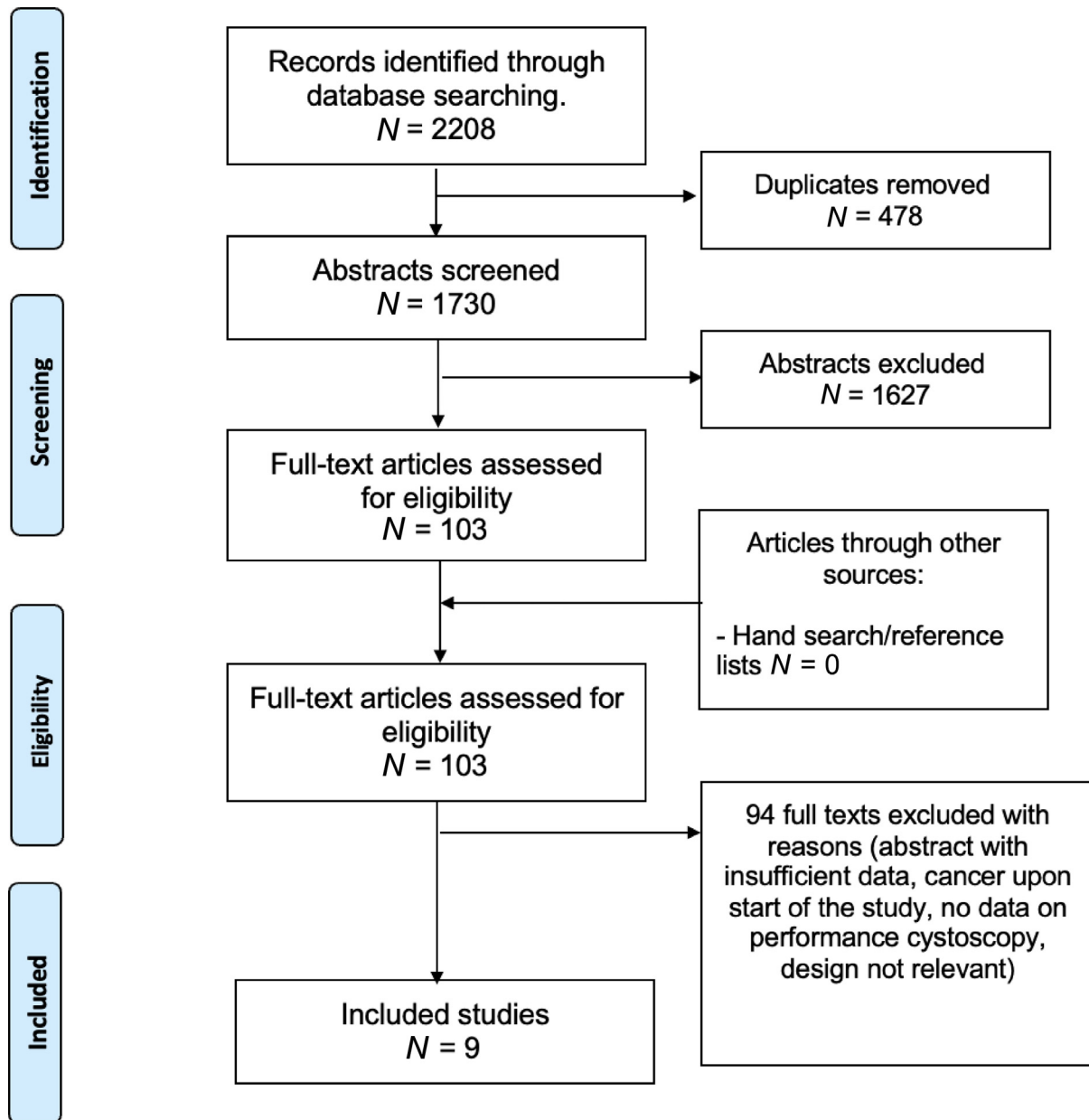


Fig. 1 – Flowchart of the study selection process. The nine selected studies consisted of studies comparing cystoscopy with both imaging (seven) and other cystoscopic modalities (two).

characteristics of the participants of the included studies are summarised in Table 2. We planned to perform a statistical analysis, but due to paucity of data and heterogeneity, we summarised the results. Using the QUADAS-2 tool, RoB was assessed and graphically represented in Figure 2. The aggregated RoB assessment (Fig. 3) showed a low RoB of the subdomains “patient selection”, “index test”, “reference standard”, and “flow and timing” in 78%, 33%, 56%, and 44%, respectively.

3.2. Conventional cystoscopy versus imaging

Seven out of nine included trials ($n = 5655$ participants) covered the use of cystoscopy in comparison with radiological imaging [15–23]. Sensitivity of cystoscopy ranged from

87% to 100%, specificity from 64% to 100%, positive predictive value from 79% to 98% and negative predictive values between 98% to 100% (Table 3). When considering the RoB of the included studies, two studies at a high RoB [19,21] found the lowest sensitivity and lowest specificity of cystoscopy. In the study by Tan et al. [15], flexible cystoscopy was compared with ultrasound and computed tomography (CT) imaging in the large, UK-based, multicentre DETECT 1 trial. This trial was originally designed to test the value of a methylation test on the diagnosis of non-muscle-invasive bladder cancer (NMIBC) and is the only trial including both VH and NVH. The study at the lowest RoB, by Dahmcke et al. [16], compared the use of DNA testing with flexible cystoscopy in 482 patients initially presenting with VH, and found 97% sensitivity and 96% specificity, which is

Table 2 – Demographic characteristics of the participants of the included studies

Study identification [reference no.]	Design	Country	Setting	Participants assessed for eligibility	Participants with haematuria	Age (yr), mean (SD) or median (range)
Tan (2018) [15]	Prospective study	UK	Hospital outpatient clinic	3556	3556	67.7 (55.6–75.7)
Dahmcke (2016) [16]	Prospective study	Denmark	Hospital outpatient clinic	519	482	69 (26–91) patients with urothelial carcinoma; 64 (18–91) patients with normal findings
Helenius (2015) [19]	Prospective study	Sweden	Hospital outpatient clinic	435	435	63 (16)
Gandrup (2015) [20]	Prospective study	Denmark	Hospital outpatient clinic	227	199	60 (25–91)
Blick (2012) [17]	Prospective study	UK	Hospital outpatient clinic	778	747	67.4 (36.7–97.5)
Ceylan (2010) [21,24]	Prospective study	Türkiye	Hospital outpatient clinic	59	36	60.4 (13.02)
Turney (2006) [18]	Prospective study	UK	Hospital outpatient clinic	200	200	Mean age 67 yr, median 68
Drejer (2017) [22]	Prospective study	Denmark	Hospital (assumed outpatient clinic)	955	483	67 (16–95)
Ciudin (2013) [23]	Prospective study	Spain	Hospital outpatient clinic	57	57	Not reported

SD = standard deviation.

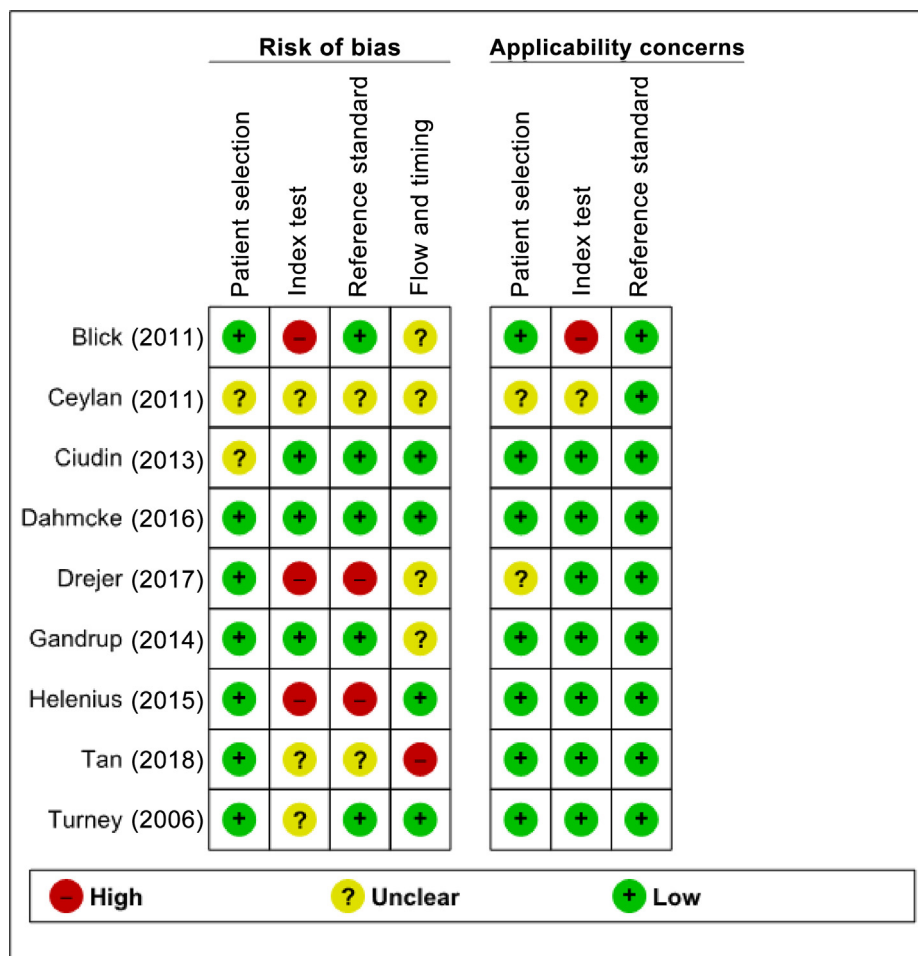


Fig. 2 – Risk of bias assessment of the includes studies.

consistent with the other studies with a low to intermediate RoB. In the study of Blick et al. [17], a UK-based study, patients with VH only received flexible cystoscopy, CT, and cytology to redefine the diagnostic strategy. The study by Turney et al. [18] was designed to assess the value of CT urogram (CTU) in patients with VH resulting in limited data on the performance of cystoscopy. The trial by Helenius et al. [19], a Swedish trial, compared the value of

cystoscopy and CTU in VH. Gandrup et al. [20] conducted a Danish trial comparing magnetic resonance imaging (MRI), CT, and cystoscopy in the diagnosis of VH patients. A Turkish trial by Ceylan et al. [21] compared cystoscopy with MRI in patients presenting with VH.

Based on the summary across studies, there is low certainty evidence that the sensitivity and specificity of cystoscopy in patients with VH are likely 97% and 96%,

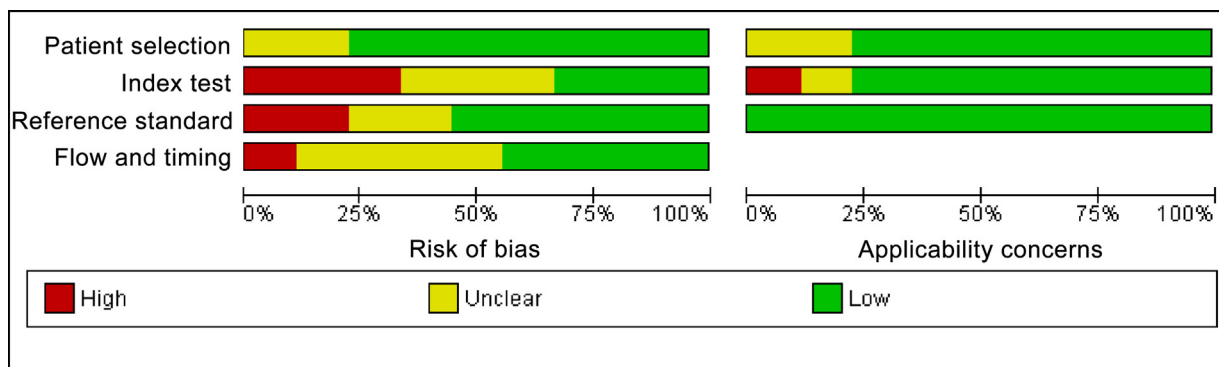


Fig. 3 – Bar charts of risk of bias and applicability concerns indicating the level of bias per subdomain among all studies.

Table 3 – Conventional cystoscopy (WL) versus imaging modalities

Study identification [reference no.]	Index test	Reference standard	Surrogate comparator for TN and FN	Haematuria	Patients	Accuracy	Sensitivity	Specificity	PPV	NPV
Tan (2018) [15]	Flexible	Histology	US and CTU	NVH + VH	3556	NR	NR	98	84	NR
Dahmcke (2016) [16]	Flexible	Histology	Urine DNA testing and imaging	VH	482	NR	97	96	87	99
Helenius (2015) [19]	Flexible	Histology	CTU	VH	435	NR	87	100	98	98
Gandrup (2015) [20]	Flexible	Histology	CTU and MRU	VH	199	41	NR	NR	NR	NR
Blick (2012) [17]	Flexible	Histology	CT	VH	747	NR	98	94	80	99
Ceylan (2010) (21)	Unclear	Histology	DW-MRI	VH	36	NR	100	64	79	100
Turney (2006) [18]	Flexible	Histology	CTU	VH	200	NR	98	98	NR	NR

CT = computed tomography; CTU = computerised tomography urogram; DW-MRI = diffusion-weighted magnetic resonance imaging; FN = false negative; MRU = magnetic resonance urography; NPV = negative predictive value; NR = not reported; NVH = nonvisible haematuria (or microscopic); PPV = positive predictive value; TN = true negative; US = ultrasound; VH = visible haematuria; WL = white light. Sensitivities and specificities are reported in %.

Table 4 – Comparison of conventional cystoscopy (WL) with alternative cystoscopy modalities

Study identification [reference no.]	Setting haematuria	Patients	Index	Sensitivity	Specificity	Comparator	Specificity	Comparator
Drejer (2017) [22]	Haematuria (unclear)	483	WL	100	95	NBI	NR	93
Ciudin (2013) [23]	Active haematuria	57	WL	47	100	Air	88	97

NBI = narrow band imaging; NR = not reported; WL = white light. Sensitivities and specificities are reported in %.

respectively. This means that in a population of 100 people with VH, cystoscopy would likely miss one urothelial bladder cancer and falsely identify three people as having cancer. It is uncertain whether this evidence applies to people with NVH.

3.3. Conventional cystoscopy versus enhanced or air cystoscopy

Two trials ($n = 540$ participants) compared enhanced or air cystoscopy versus conventional WL cystoscopy in people with haematuria [22,23]. Overall, the evidence was inconsistent for the sensitivity of WL cystoscopy, which ranged from 47% to 100%, but more consistent for specificity, which ranged from 93.4% to 100% (Table 4). Drejer et al. [22] reported in a multicentre Danish trial (DaBlaCa-7 study) a high RoB assessing the additional benefit of narrow band imaging (enhanced) cystoscopy versus WL cystoscopy in both NMIBC follow-up and haematuria evaluation. Ciudin et al. [23] in a Spanish trial investigated the additional benefit of air cystoscopy to WL cystoscopy in active haematuria

patients and reported an intermediate RoB. Given the total sample size, RoB, and inconsistency, the evidence is uncertain for the sensitivity and specificity of cystoscopy from studies where enhanced/air cystoscopy was used as the reference standard.

3.4. Risk of bias

RoB was assessed with the QUADAS-2 tool, and graphically represented in Figures 2 and 3.

3.5. Discussion

To our knowledge, this is the first systematic review of the diagnostic value of cystoscopy for the diagnosis of bladder cancer in patients with haematuria. Our search strategy was very comprehensive starting from 1990. During this period, technology has changed, and flexible cystoscopes have widely been available. Cystoscopic performance was generally well in the included studies. Conventional WL

cystoscopy outperforms imaging modalities, with sensitivities of cystoscopy ranging from 87% to 100% and specificity ranging from 64% to 100%. Two trials compared enhanced or air cystoscopy versus conventional cystoscopy. Overall sensitivity of conventional WL cystoscopy ranged from 47% to 100% and specificity from 93.4% to 100%.

Different challenges arise in the current literature to determine precise estimates of the performance of cystoscopy. First, most studies were retrospective and not included for the present review as per the inclusion criteria. Second, we noted that in the existing literature, cystoscopy is, despite the lack of evaluation, used as the gold standard test, with most studies comparing the diagnostic performance of alternative tests as an index test compared with cystoscopy. In case of a suspicious lesion with cystoscopy, transurethral resection is performed to confirm UBC (true positive) or rule out UBC (false positive). However, literature lacks a negative reference test to assess true negatives. Possibilities for a negative reference test include follow-up cystoscopies that are negative. Unfortunately, in case of a negative initial cystoscopy, no further examinations were planned, and if follow-up cystoscopy was planned, there is no standardised schedule. Lastly, this review was planned to evaluate the initial work-up setting in patients presenting with haematuria. In most studies, however, (commercial) modalities were tested in the follow-up setting, where sensitivity of cystoscopy is most likely lower and more easily enhanced by any additional diagnostic technique.

A number of studies that were screened investigated the risk of UBC after a full negative diagnostic assessment, using prospective studies with long follow-up. Again, these studies did not provide information on false positive results of cystoscopy and therefore could not be included in the present review. Nonetheless, bladder cancer incidence after a negative diagnostic work-up remained low in both VH and NVH. Namely, in case of persistent VH, Mishriki et al. [11] collected data of 1804 patients with visible haematuria. They found that 965/1804 (53.5%) patients had no pathology, 386 (21.4%) patients had a malignant urological condition, and the remaining patients had a benign condition including bladder stone (36 patients, 2%), urethral stricture (37 patients, 2.1%), cystitis/urinary tract infection (36 patients, 2%), enlarged bleeding prostate (242 patients, 13.4%), and renal/ureteral calculi/hydronephrosis (99 patients, 5.5%).

In case of asymptomatic NVH, Madeb et al. [12] used the state tumour registry to track the outcomes of 1575 male patients who were screened for microscopic haematuria (MH); 258 participants had MH. Urological cancer including bladder cancer was not found in 234 males; however, two were subsequently diagnosed with bladder cancer, one after 6.7 yr and the other at 11.4 yr. Jaffe et al. [13] performed an intravenous urography in 75 of the 212 NVH patients who had a negative initial evaluation. From these 75 patients, two were diagnosed with ureteral tumours and one was diagnosed with a renal pelvis tumour. In the study by Sells and Cox [14], 146 patients with NVH were followed without any bladder cancers missed at the initial diagnosis.

It is important that the patient should be informed about the possible complications before undergoing cystoscopy. The possible complications include pain and discomfort, haematuria, dysuria, and urinary tract infection.

Taken together, these studies highlight a low incidence of malignancies after an initial negative work-up. Nonetheless, these follow-up studies could not be used to assess complete diagnostic accuracy of cystoscopy, as data were limited to the subpopulation that had a negative initial diagnostic evaluation. Future trials should include methods to evaluate the true value of cystoscopy or use indirect measures of true negative findings, for example, using a standardised follow-up protocol.

4. Conclusions

The true accuracy of cystoscopy itself has not been studied extensively within the context of haematuria, resulting in inconsistent data regarding its performance within haematuria patients. In comparison with imaging modalities, a few trials have prospectively assessed the diagnostic performance of cystoscopy, confirming a very high accuracy for cystoscopy, exceeding the diagnostic value of any other imaging test.

The benefits of enhanced cystoscopic techniques in assessing haematuria have been proposed, although evidence is limited, and their additional clinical value still needs to be determined by conducting a robust clinical trial.

To improve the diagnostic pathway for our haematuria patients, it is important to include measures of the accuracy of cystoscopy in future prospective trials.

Author contributions: Muhammad Imran Omar had full access to all the data in the study and takes responsibility for the integrity of the data and the accuracy of the data analysis.

Study concept and design: Devlies, de Jong, Hofmann, Bruins, Zuiverloon, Yuan, van Rhijn, Mostafid, Santesso, Violette, Omar.

Acquisition of data: Devlies, de Jong, Omar, Smith, Yuan.

Analysis and interpretation of data: Devlies, de Jong, Omar.

Drafting of the manuscript: Devlies, de Jong, Omar.

Critical revision of the manuscript for important intellectual content: Devlies, de Jong, Hofmann, Bruins, Zuiverloon, Yuan, van Rhijn, Mostafid, Santesso, Violette, Omar.

Statistical analysis: None.

Obtaining funding: Smith.

Administrative, technical, or material support: Smith.

Supervision: Omar.

Other: None.

Financial disclosures: Muhammad Imran Omar certifies that all conflicts of interest, including specific financial interests and relationships and affiliations relevant to the subject matter or materials discussed in the manuscript (eg, employment/affiliation, grants or funding, consultancies, honoraria, stock ownership or options, expert testimony, royalties, or patents filed, received, or pending), are the following: None.

Funding/Support and role of the sponsor: This work was supported by the European Association of Urology Guidelines Office.

Appendix A. Supplementary data

Supplementary data to this article can be found online at <https://doi.org/10.1016/j.euf.2023.08.002>.

References

- [1] Sung H et al. Global cancer statistics 2020: GLOBOCAN estimates of incidence and mortality worldwide for 36 cancers in 185 countries. *CA Cancer J Clin* 2021;71:209–49.
- [2] Takeuchi M et al. Cancer prevalence and risk stratification in adults presenting with haematuria: a population-based cohort study. *Mayo Clin Proc Innov Qual Outcomes* 2021;5:308–19.
- [3] EAU. EAU guidelines. Presented at: The 37th Annual EAU Congress; July 1–4, 2022; Amsterdam.
- [4] Chang SS, Boorjian SA, Chou R, et al. Diagnosis and treatment of non-muscle invasive bladder cancer: AUA/SUO guideline. *J Urol* 2016;196:1021–9.
- [5] Jubber I et al. Non-visible haematuria for the detection of bladder, upper tract, and kidney cancer: an updated systematic review and meta-analysis. *Eur Urol* 2020;77:583–98.
- [6] Malmstrom PU et al. Progress towards a Nordic standard for the investigation of haematuria: 2019. *Scand J Urol* 2019;53:1–6.
- [7] McInnes MDF, Moher D, Thombs BD, et al. Preferred Reporting Items for a Systematic Review and Meta-analysis of diagnostic test accuracy studies: the PRISMA-DTA statement. *JAMA* 2018;319:388–96.
- [8] Bossuyt PM, Deeks JJ, Leeftang MM, Takwoingi Y, Flemyng E. Preface. Draft version (4 October 2022) for inclusion. In: Deeks JJ, Bossuyt PM, Leeftang MM, Takwoingi Y, editors. *Cochrane handbook for systematic reviews of diagnostic test accuracy*. Version 2. London, UK: Cochrane.
- [9] Knoll T et al. Key steps in conducting systematic reviews for underpinning clinical practice guidelines: methodology of the European Association of Urology. *Eur Urol* 2018;73:290–300.
- [10] Whiting PF et al. QUADAS-2: a revised tool for the quality assessment of diagnostic accuracy studies. *Ann Intern Med* 2011;155:529–36.
- [11] Mishriki SF, Vint R, Somani BK. Half of visible and half of recurrent visible haematuria cases have underlying pathology: Prospective large cohort study with long-term followup. *J Urol* 2012;187:1561–4.
- [12] Madeb R et al. Long-term outcome of patients with a negative work-up for asymptomatic microhaematuria. *Urology* 2010;75:20–5.
- [13] Jaffe JS et al. A new diagnostic algorithm for the evaluation of microscopic haematuria. *Urology* 2001;57:889–94.
- [14] Sells H, Cox R. Undiagnosed macroscopic haematuria revisited: a follow-up of 146 patients. *BJU Int* 2001;88:6–8.
- [15] Tan WS et al. Can renal and bladder ultrasound replace computerized tomography urogram in patients investigated for microscopic haematuria? *J Urol* 2018;200:973–80.
- [16] Dahmcke CM et al. A prospective blinded evaluation of urine-DNA testing for detection of urothelial bladder carcinoma in patients with gross haematuria. *Eur Urol* 2016;70:916–9.
- [17] Blick CGT et al. Evaluation of diagnostic strategies for bladder cancer using computed tomography (CT) urography, flexible cystoscopy and voided urine cytology: results for 778 patients from a hospital haematuria clinic. *BJU Int* 2012;110:84–94.
- [18] Turney BW et al. Computed tomography urography for diagnosing bladder cancer. *BJU Int* 2006;98:345–8.
- [19] Helenius M et al. Bladder cancer detection in patients with gross haematuria: computed tomography urography with enhancement-triggered scan versus flexible cystoscopy. *Scand J Urol* 2015;49:377–81.
- [20] Gandrup KL et al. Diagnosis of bladder tumours in patients with macroscopic haematuria: a prospective comparison of split-bolus computed tomography urography, magnetic resonance urography and flexible cystoscopy. *Scand J Urol* 2015;49:224–9.
- [21] Ceylan K et al. S156 Comparison of cystoscopy with diffusion weighted magnetic resonance images used in the diagnosis and follow-up of patients with bladder tumor. *Eur Urol Suppl* 2010;9:596–7.
- [22] Drejer D et al. Clinical relevance of narrow-band imaging in flexible cystoscopy: the DaBlaCa-7 study. *Scand J Urol* 2017;51:120–3.
- [23] Ciudin A, Diaconu MG, Gosalbez D, et al. Air cystoscopy is superior to water cystoscopy for the diagnosis of active hematuria. *J Urol* 2013;190:2097–101.
- [24] Ceylan K et al. Comparison of cystoscopy with diffusion-weighted magnetic resonance images used in the diagnosis and follow-up of patients with bladder tumors. *Asian Pacific J Cancer Prev* 2010;11:1001–104.