

# Association of Bone Shape and Alignment Analyzed Using Statistical Shape Modeling With Severity of First Metatarsophalangeal Joint Osteoarthritis

Andrew K. Buldt,<sup>1</sup>  Jenny S. Gregory,<sup>2</sup>  Shannon E. Munteanu,<sup>1</sup>  Jamie J. Allan,<sup>1</sup>  Jade M. Tan,<sup>3</sup>   
Maria Auhl,<sup>1</sup> Karl B. Landorf,<sup>1</sup>  Edward Roddy,<sup>4</sup>  Michelle Marshall,<sup>5</sup>  and Hylton B. Menz<sup>1</sup> 

**Objective.** We aimed to explore the relationship between bone shape and radiographic severity in individuals with first metatarsophalangeal joint osteoarthritis (first MTP joint OA).

**Methods.** Weightbearing lateral and dorsoplantar radiographs were obtained for the symptomatic foot of 185 participants (105 females, aged 22 to 85 years) with clinically diagnosed first MTP joint OA. Participants were classified into none/mild, moderate, or severe categories using a standardized atlas. An 80-point model for lateral radiographs and 77-point model for dorsoplantar radiographs was used to define independent modes of variation using statistical shape modeling software. Odds ratios adjusted for confounders were calculated using ordinal regression to determine the association between radiographic severity and mode scores.

**Results.** After assessment and grading of radiographs, 35 participants (18.9%) were included in the none/mild first MTP joint OA severity category, 69 (37.2%) in the moderate severity category, and 81 (43.7%) in the severe category. For lateral-view radiographs, 16 modes of variation were included, which collectively represented 83.2% of total shape variance. Of these, four modes were associated with radiographic severity. For dorsoplantar-view radiographs, 15 modes of variation were included, representing 82.6% of total shape variance. Of these, six modes were associated with radiographic severity.

**Conclusions.** Variations in the shape and alignment of the medial cuneiform, first metatarsal, and proximal and distal phalanx of the hallux are significantly associated with radiographic severity of first MTP joint OA. Prospective studies are required to determine whether bone shape characteristics are associated with the development and/or progression of this condition.

## INTRODUCTION

Osteoarthritis (OA) of the first metatarsophalangeal (MTP) joint is a common condition affecting 7.8% of people aged over 50 years.<sup>1,2</sup> Characteristics of first MTP joint OA include localized pain and stiffness in the affected joint.<sup>3</sup> Individuals with first MTP joint OA also report lower health-related quality of life, have greater difficulty performing weightbearing tasks, and perceive their feet to be in a poorer state compared with people without the condition.<sup>4</sup>

Greater radiographic severity of first MTP joint OA is associated with increased prevalence of pain and reduced range of

motion available in the joint, suggesting that it may be a progressive condition.<sup>3</sup> A recent population-based longitudinal cohort study demonstrated the progressive course of first MTP joint OA, with 28% of women recruited with radiographic first MTP joint OA at baseline displaying an increase in radiographic severity over a 19-year period.<sup>5</sup> This study also indicated a discordance in the symmetry of first MTP joint OA progression between left and right feet. For example, the characteristics of first MTP joint OA in left feet were more likely to include joint space narrowing, whereas the characteristics of first MTP joint OA in right feet displayed greater osteophyte formation. In hand, hip, and knee OA,

Supported by Arthritis Australia. Clinical trials associated with this research were supported by National Health and Medical Research Council (Australia) project grants (1105244 and 1049085).

<sup>1</sup>Andrew K. Buldt, PhD, Shannon E. Munteanu, PhD, Jamie J. Allan, MPodMed, Maria Auhl, BSc, Karl B. Landorf, PhD, Hylton B. Menz, PhD: La Trobe University, Melbourne, Victoria, Australia; <sup>2</sup>Jenny S. Gregory, PhD: University of Aberdeen, Aberdeen, UK; <sup>3</sup>Jade M. Tan, PhD: The University of Western Australia, Crawley, Perth, Western Australia, Australia; <sup>4</sup>Edward Roddy, DM: Keele University, Keele, Staffordshire, UK and Midlands Partnership

University NHS Foundation Trust, Haywood Hospital, Burslem, Staffordshire, UK; <sup>5</sup>Michelle Marshall, PhD: Keele University, Keele, Staffordshire, UK.

Author disclosures and graphical abstract are available at <https://onlinelibrary.wiley.com/doi/10.1002/acr.25237>.

Address correspondence via email to Hylton B. Menz, PhD, at [h.menz@latrobe.edu.au](mailto:h.menz@latrobe.edu.au).

Submitted for publication March 16, 2023; accepted in revised form September 14, 2023.

### SIGNIFICANCE & INNOVATIONS

- This is the first study to use statistical shape modeling to create a profile of bone shape linked to radiographic severity of first metatarsophalangeal (MTP) joint osteoarthritis (OA).
- Variations in the shape and alignment of the medial cuneiform, first metatarsal, and proximal and distal phalanx of the hallux are significantly associated with radiographic severity of first MTP joint OA.

it has also been suggested that discordance in progression, and in particular osteophyte formation, may be due to functional variability as opposed to constitutional or genetic factors.<sup>6</sup>

Variations from normal function including parameters such as range of motion and biomechanics are recognized as being a feature of first MTP joint OA. Indeed, range of motion testing (less than 64° dorsiflexion) forms part of the clinical definition of the condition,<sup>7</sup> and differences in gait-related biomechanical parameters, primarily pressure distribution, have been observed between individuals with and without first MTP joint OA.<sup>8,9</sup> Variations from normal function that are associated with first MTP joint OA may be influenced by characteristic changes in skeletal structure. Studies that have investigated skeletal foot structure have primarily focused on bone dimensions and joint angles, finding that individuals with greater severity of radiographic first MTP joint OA exhibit greater width of the first metatarsal and proximal hallux and increased hallux interphalangeal angle, hallux interphalangeal hyperextension, and hallux valgus angle.<sup>3,10</sup> However, the usefulness of these findings are limited because measures may be highly correlated with each other or with other factors such as body size and sex.<sup>11</sup>

Statistical shape modeling (SSM) is a statistical technique that can describe the shape and alignment of multiple bones beyond what can be provided by single geometric measurements.<sup>12</sup> Importantly, in joints for which SSM has been utilized, such as the hip, the analysis of bone shape has been shown to be a biomarker of OA progression.<sup>13–16</sup> The characteristic bone shape profile associated with hip OA can be used to identify and monitor early OA and can assist in the prediction of total hip replacement.<sup>17</sup> To date, there is only one study relating to foot OA to use SSM that explored differences among participants with hallux valgus and first MTP joint OA and controls without first MTP joint pathology.<sup>18</sup>

The aim of this cross-sectional study was to use SSM to model morphologic differences in individuals with differing severities of first MTP joint OA and explore the relationship among bone shape, alignment, and radiographic severity.

## METHODS

**Participants.** We recruited individuals from two clinical trials that evaluated nonsurgical interventions for first MTP

joint OA.<sup>19,20</sup> Ethical approval was granted by the La Trobe University Human Ethics Committee (HEC15-128 and HEC18-375). All participants had a clinically defined diagnosis of first MTP joint OA, which included the following: (i) aged at least 18 years, (ii) reported pain at the first MTP joint on most days for at least 12 weeks, (iii) reported pain rated at least 30 mm on a 100-mm visual analog scale in the previous week, (iv) described pain on palpation of the dorsal aspect of the first MTP joint, and (v) exhibited restricted dorsiflexion of the first MTP joint (<64° of dorsiflexion range of motion). Participants were excluded based on the following: (i) previous first MTP joint surgery; (ii) currently pregnant; (iii) significant first MTP joint deformity, such as hallux valgus (defined as a score of 2 or 3 using the Manchester scale)<sup>21</sup>; (iv) presence of any condition within the foot or ankle that confound pain and functional assessments of the first MTP joint, such as clinically important pain in a part of the musculoskeletal system other than the first MTP joint; and (v) the presence of systemic inflammatory conditions, such as gout or rheumatoid arthritis.

**Imaging.** All radiographic procedures were performed according to the National Health and Medical Research Council of Australia National Statement on Ethical Conduct in Human Research.<sup>22</sup> Weightbearing lateral and dorsoplantar radiographs of the foot were taken for all participants while standing in a relaxed weightbearing position. All radiographs were taken by the same medical imaging equipment. Each foot was radiographed separately. For lateral-view radiographs, the x-ray tube was positioned at an angle of 90° and centered at the base of the third metatarsal. For dorsoplantar-view radiographs, the x-ray tube was positioned at an angle of 15° cephalad and centered at the base of the third metatarsal. The film focus distance was 100 cm for both projections. If the participant had bilateral first MTP joint OA, radiographs were taken of the most symptomatic foot.

**Radiographic grading.** The La Trobe University radiographic atlas for foot OA was used to determine the severity of OA at the first MTP joint.<sup>23</sup> The atlas assesses osteophytes and joint space narrowing at the first MTP joint from lateral and dorsoplantar views. The atlas has been shown to have excellent reliability.<sup>23</sup> The presence of osteophytes was graded as absent (score = 0), small (score = 1), moderate (score = 2), or severe (score = 3). The presence of joint space narrowing was graded as absent (score = 0), definite (score = 1), moderate (score = 2), or joint fusion (score = 3). After grading of osteophytes and joint space narrowing, participants were assigned one of three radiographic severity categories: (i) no or mild OA (defined as one score of 1 or less and no score of 2 or greater for either osteophytes or joint space narrowing from either the dorsoplantar or lateral radiographs), (ii) moderate OA (defined as one score of at least 2 and no scores of 3), or (iii) severe OA (defined as one score of at least 3). Assessments were conducted by two raters who were involved in the development of the atlas (SEM and HBM).

**Statistical shape modeling.** SSM is a statistical technique used to identify and quantify variations in the shape of bones.<sup>24,25</sup> Custom-made SSM software (Shape, Aberdeen University, UK) was used to create a template of easily identifiable landmark points to define the entire shape of the medial cuneiform, first metatarsal, proximal phalanx, and distal phalanx. Separate templates were created for lateral-view radiographs, comprising 80 points, and dorsoplantar-view radiographs, comprising 77 points. Templates were created to include features that were consistently visible in all images, including osteophytes associated with the first MTP joint. Point locations for dorsoplantar and lateral radiographs are shown in Figure 1.

As is standard for this technique, the location of points was orientated to define the bone shape for all radiograph images by the same investigator (AKB). To remove the influence of size, point coordinates underwent Procrustes transformation to scale, rotate, and translate points to lie on the same scale and as closely aligned as possible. Variations in bone shape were then described with a series of independent orthogonal modes that were derived using principal components analysis. Mode scores for each image were expressed in units of SD to describe how each participant varied from the mean shape for the entire sample.

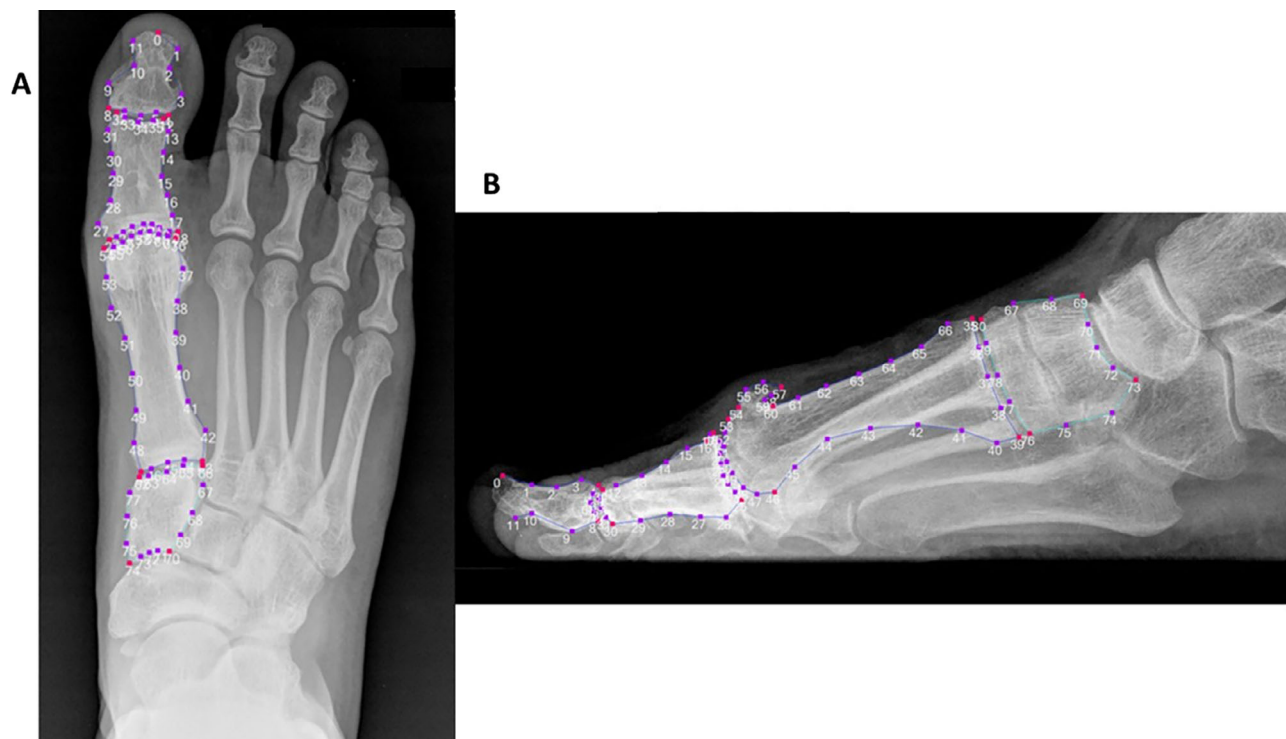
**Reproducibility.** Thirty lateral and 30 dorsoplantar images were randomly selected to assess intrarater reproducibility. Points were placed by the same investigator, who analyzed the

radiographs on two occasions at least 2 weeks apart. Mean point-to-point difference was measured in pixels (1 pixel = 0.8 mm). For lateral radiographs, the mean point-to-point difference was 2.6 pixels. For dorsoplantar radiographs, the mean point-to-point difference was 2.1 pixels. In SSM analysis, a mean point-to-point difference of 3 pixels or less is considered to represent acceptable reproducibility.<sup>26</sup>

**Statistical analysis.** All analyses were performed using IBM SPSS Statistics Release 24 for Windows (IBM Corp, Armonk, NY). Modes of variation were included for both lateral and dorsoplantar radiographs. Modes were required to represent at least 1% of the total variation of the sample to be included. Associations between mode score and first MTP joint OA severity were represented as odds ratios (ORs) with 95% confidence intervals (95% CIs), calculated via ordinal regression. Covariates were included in ordinal regression for variables considered to be confounders. Confounders were identified using one-way analysis of variance. Any significant differences ( $P$  values < 0.05) among severity categories indicated that the covariate was a confounder. In addition, Bonferroni adjustment for multiple comparison was applied to significant mode association findings ( $P$  < 0.05).

## RESULTS

**Participant characteristics.** A total of 185 participants were included in the study; their characteristics are shown in



**Figure 1.** Point placement for statistical shape modeling templates for (A) dorsoplantar-view radiographs and (B) lateral radiographs.

**Table 1.** Participant characteristics according to radiographic severity of first MTP joint OA\*

	None/mild (n = 35)	Moderate (n = 69)	Severe (n = 81)	P value
Age, years	55.0 ± 13.4	56.1 ± 10.8	59.9 ± 8.9	0.026 <sup>a,b</sup>
Female, n (%)	22 (62.9)	44 (63.7)	39 (48.1)	0.101
Height, cm	166.7 ± 8.5	165.2 ± 8.7	168.4 ± 8.3	0.574
Weight, kg	74.2 ± 13.2	76.3 ± 11.3	83.4 ± 13.7	<0.001 <sup>a,b</sup>
BMI, kg/m <sup>2</sup>	26.8 ± 4.5	28.0 ± 4.6	29.3 ± 4.6	0.017 <sup>a</sup>
Duration of symptoms, mo	35.8 ± 42.3	56.6 ± 66.6	86.5 ± 93.8	<0.001 <sup>a,b</sup>

\* Values shown represent mean ± SD unless otherwise stated. BMI, body mass index; MTP, metatarsophalangeal; OA, osteoarthritis.

<sup>a</sup> Significant difference between none/mild and severe.

<sup>b</sup> Significant difference between moderate and severe.

Table 1. After grading the severity of first MTP joint OA, 35 participants (18.9%) were classified as being in the none/mild severity category, 69 (37.2%) in the moderate severity category, and 81 (43.8%) in the severe category. Participants in the severe category were significantly older than those in the none/mild category (mean difference 4.9 years, 95% CI 0.7–9.1) and moderate (mean difference –3.8 years, 95% CI 0.5–7.2) categories. The participants in the severe category also exhibited significantly greater body mass index (BMI) compared with those in the none/mild category (mean difference 2.5 kg/m<sup>2</sup>, 95% CI 0.7–4.3) and significantly greater weight compared with those in both the none/mild (mean difference 9.1 kg, 95% CI 4.1–14.2) and the moderate (mean difference 7.0 kg, 95% CI 2.9–11.1) categories. Participants in the severe category also exhibited significantly greater self-reported duration of symptoms compared with those in the none/mild (mean difference 51.9 months, 95% CI 21.5–82.3) and moderate (mean difference 33.2 months, 95% CI 8.7–57.8) categories. No significant differences were seen for sex and height among the severity of first MTP joint OA categories. Accordingly, age, BMI, and duration of symptoms were entered as covariates in the ordinal regression models. Although weight was significantly different among severity

categories, it is strongly correlated with BMI and so was not entered as a covariate to avoid overcorrection.

**Lateral-view radiographs.** A total of 16 modes of variation were included because each represented at least 1% of the total variation of the sample. These modes collectively represented 83.2% of total shape variance (Table 2). Significant associations were identified between radiographic severity and six modes (modes 1, 2, 5, 6, 8, and 9). After adjustment for confounders, the number of significant associations with the application of Bonferroni adjustment reduced to four modes (modes 1, 2, 5, and 10). The strongest associations were for mode 1 (OR 2.77, 95% CI 1.91–4.02), and mode 5 (OR 0.44, 95% CI 0.32–0.61).

A representation of the four significant associations (after adjustment) between radiographic severity and mode scores is shown in Figure 2. For lateral mode 1, radiographic severity was positively associated with greater mode scores (+2 SDs from the mean represented by solid red line in Figure 1). Greater scores for lateral mode 1 were characterized by a more dorsiflexed first metatarsal, a larger first metatarsal head, a prominent dorsal osteophyte with a posteriorly orientated protuberance, narrower dorsal joint space, a more plantar orientation of the proximal

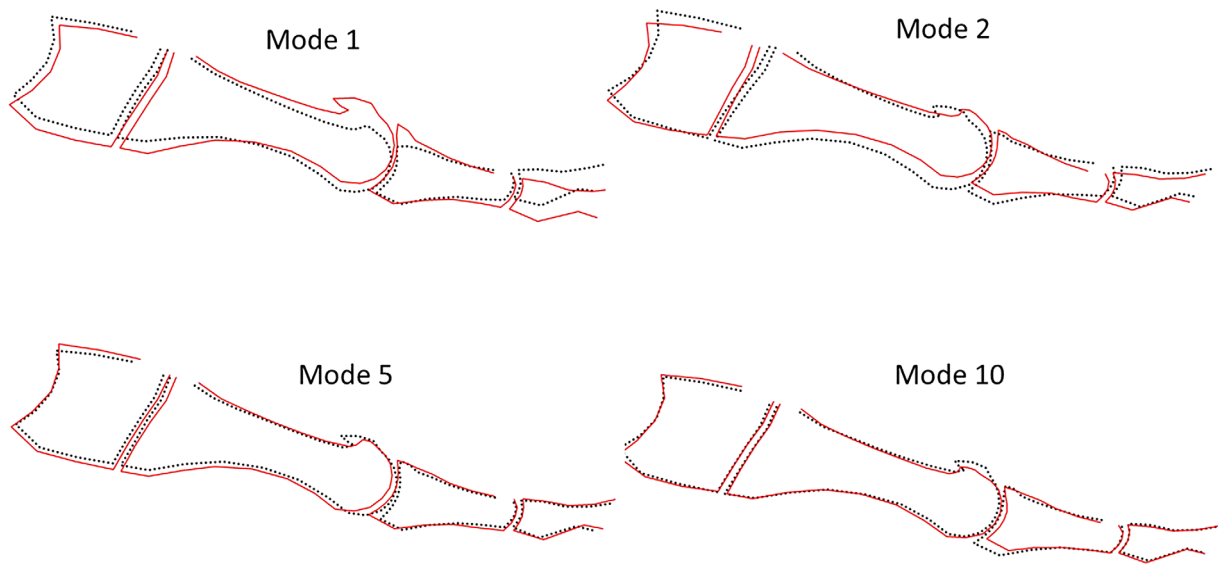
**Table 2.** Associations between radiographic severity and modes of variation from lateral-view radiographs\*

Mode	Variance explained (%)	Odds ratio (95% CI)	P value	Adjusted odds ratio (95% CI) <sup>a</sup>	P value
1	22.7	3.01 (2.11–4.31)	<0.001 <sup>b</sup>	2.77 (1.91–4.02)	<0.001 <sup>b</sup>
2	12.2	0.65 (0.49–0.87)	0.004 <sup>b</sup>	0.69 (0.50–0.92)	0.014 <sup>b</sup>
3	10.3	0.81 (0.61–1.06)	0.131	1.15 (0.86–1.52)	0.344
4	8.3	1.19 (0.91–1.57)	0.198	1.18 (0.88–1.58)	0.249
5	4.7	0.47 (0.34–0.64)	<0.001 <sup>b</sup>	0.44 (0.32–0.61)	<0.001 <sup>b</sup>
6	4.2	1.32 (1.00–1.72)	0.044 <sup>b</sup>	1.26 (0.94–1.68)	0.111
7	3.5	0.83 (0.63–1.09)	0.193	0.82 (0.61–1.08)	0.173
8	3.2	0.71 (0.54–0.93)	0.017 <sup>b</sup>	0.75 (0.56–1.00)	0.058
9	2.5	1.09 (0.83–1.43)	0.511	1.11 (0.84–1.47)	0.441
10	2.4	0.59 (0.44–0.80)	<0.001 <sup>b</sup>	0.60 (0.44–0.81)	0.001 <sup>b</sup>
11	2.1	0.85 (0.65–1.13)	0.281	0.79 (0.59–1.05)	0.106
12	1.8	1.21 (0.92–1.59)	0.170	1.19 (0.90–1.57)	0.216
13	1.5	1.05 (0.80–1.35)	0.696	1.00 (0.76–1.33)	0.948
14	1.3	1.08 (0.82–1.42)	0.566	1.00 (0.75–1.33)	0.975
15	1.2	0.88 (0.67–1.15)	0.374	0.84 (0.63–1.11)	0.232
16	1.1	0.97 (0.74–1.27)	0.833	1.03 (0.78–1.37)	0.799

\* BMI, body mass index; 95% CI, 95% confidence interval.

<sup>a</sup> Adjusted for age, duration of symptoms (months), and BMI.

<sup>b</sup> Significant at  $P < 0.05$ .



**Figure 2.** Modes from lateral-view radiographs with significant associations with radiographic severity (+2 SDs, red solid line; -2 SDs, black broken line). Color figure can be viewed in the online issue, which is available at <http://onlinelibrary.wiley.com/doi/10.1002/acr.25237/abstract>.

phalanx, and a dorsal osteophyte at the base of the proximal phalanx. For lateral mode 5, radiographic severity was negatively associated with larger mode scores. Smaller lateral mode 5 scores were characterized by a longer first metatarsal, presence of a sharp posteriorly orientated protuberance originating from the dorsal exostosis on the first metatarsal head, and a flatter base of the proximal phalanx of the hallux.

**Dorsoplantar-view radiographs.** There were 15 modes of variation selected because each represented at least 1% of the total variation of the sample, representing 82.6% of total shape variance (Table 3). Significant associations were identified between radiographic severity and seven modes

(modes 2, 3, 8, 9, 11, 14, and 15). After adjustment for confounders, the number of significant associations with the application of Bonferroni adjustment reduced to six modes (modes 2, 3, 8, 9, 11, and 14). The strongest associations were for dorsoplantar mode 11 (OR 1.77, 95% CI 0.77–2.42), dorsoplantar mode 2 (OR 1.58, 95% CI 1.17–2.14), and dorsoplantar mode 3 (OR 0.66, 95% CI 0.49–0.88).

A representation of the six significant associations (after adjustment) between radiographic severity and mode scores is shown in Figure 3. For dorsoplantar modes 11 and 2, radiographic severity was positively associated with greater mode scores. For dorsoplantar mode 11, increased mode scores were characterized by a narrower joint space and wider lateral margin at the base of the proximal phalanx. For dorsoplantar mode 2, increased

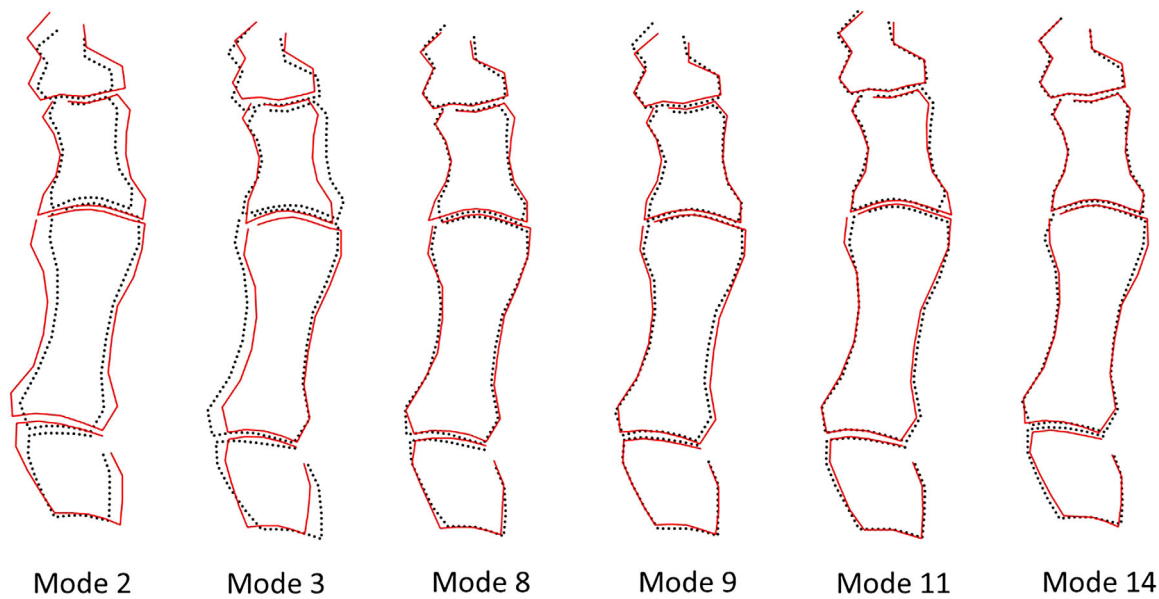
**Table 3.** Associations between radiographic severity and modes of variation from dorsoplantar-view radiographs\*

Mode	Variance explained (%)	Odds ratio (95% CI)	P value	Adjusted odds ratio (95% CI) <sup>a</sup>	P value
1	27.2	0.93 (0.71–1.22)	0.628	0.96 (0.72–1.27)	0.790
2	13.7	1.71 (1.26–2.30)	<0.001 <sup>b</sup>	1.58 (1.17–2.14)	0.003 <sup>b</sup>
3	10.7	0.68 (0.51–0.90)	0.007 <sup>b</sup>	0.66 (0.49–0.88)	0.006 <sup>b</sup>
4	5.7	1.09 (0.83–1.44)	0.496	1.08 (0.82–1.43)	0.578
5	4.9	1.01 (0.77–1.32)	0.951	0.88 (0.66–1.17)	0.382
6	3.7	1.24 (0.94–1.63)	0.129	1.12 (0.84–1.50)	0.413
7	3.0	1.09 (0.83–1.43)	0.528	1.01 (0.77–1.34)	0.901
8	2.7	1.32 (1.01–1.74)	0.045 <sup>b</sup>	1.33 (1.01–1.77)	0.043 <sup>b</sup>
9	2.2	1.42 (1.07–1.89)	0.014 <sup>b</sup>	1.47 (1.10–1.98)	0.009 <sup>b</sup>
10	1.9	1.15 (0.88–1.52)	0.297	1.12 (0.84–1.49)	0.416
11	1.6	1.75 (1.29–2.37)	<0.001 <sup>b</sup>	1.77 (0.77–2.42)	<0.001 <sup>b</sup>
12	1.5	0.93 (0.69–1.41)	0.610	1.04 (0.78–1.37)	0.802
13	1.3	0.91 (0.69–1.19)	0.138	0.94 (0.71–1.24)	0.451
14	1.2	0.71 (0.54–0.95)	0.021 <sup>b</sup>	0.70 (0.52–1.06)	0.019 <sup>b</sup>
15	1.1	1.38 (1.04–1.82)	0.022 <sup>b</sup>	1.32 (0.99–1.76)	0.084

\* BMI, body mass index; 95% CI, 95% confidence interval.

<sup>a</sup> Adjusted for age, duration of symptoms (months), and BMI.

<sup>b</sup> Significant at  $P < 0.05$ .



**Figure 3.** Modes from dorsoplantar-view radiographs with significant associations with radiographic severity (+2 SD, red solid line; -2 SDs, black broken line). Color figure can be viewed in the online issue, which is available at <http://onlinelibrary.wiley.com/doi/10.1002/acr.25237/abstract>.

mode scores were characterized by narrower joint space; wider medial cuneiform; wider base, shaft, and head of the first metatarsal; wider proximal phalanx; and wider and longer distal phalanx. For dorsoplantar mode 3, radiographic severity was negatively associated with greater mode scores. Smaller mode scores were characterized by an overall wider first metatarsal and proximal phalanx and a wider joint surface of the first MTP joint.

## DISCUSSION

This is the first study to use SSM to create a profile of bone shape linked to radiographic severity of first MTP joint OA. We utilized both lateral- and dorsoplantar-view radiographs to identify modes of variation for the bony anatomy of the medial cuneiform, first metatarsal, and proximal and distal phalanx that were associated with severity determined using the La Trobe University radiographic foot atlas. Because there is no standardized reference for bone shape of the first MTP joint or adjacent bones using SSM, modes that were associated with radiographic severity can only be differentiated through qualitative assessment of variation. Most of the variation in significant modes can be summarized by the shape of the first MTP joint and the size and alignment of the first metatarsal and proximal phalanx. The only similar study by Milliken et al investigated the association between bone shape and foot pathology.<sup>18</sup> Although there were similarities in the model design, there were differences in study design because Milliken et al included the whole foot, not just the first MTP joint. Furthermore, their study included participants with hallux valgus, which dominated the earlier modes of the resulting shape model, precluding direct comparisons to our findings.

Analysis of lateral-view radiographs identified four modes of variation that were significantly associated with radiographic severity of first MTP joint OA after adjustment for confounders. The variation identified in lateral modes 1 and 2 was contrasting and may suggest differing courses of progression of first MTP joint OA. Lateral mode 1 explained the greatest amount of total shape variance (22.7%) and had the strongest association with radiographic severity. The most distinctive and unique features of mode 1 were the shape of the first MTP joint and sagittal plane alignment of the first metatarsal. Higher mode scores for lateral mode 1 were reflected by focal joint space narrowing in the dorsal aspect of the first MTP joint and relative dorsiflexion of the first metatarsal. In contrast to lateral mode 1, lower scores for lateral mode 2 were associated with radiographic severity. Lateral mode 2 explained the second most amount of total shape variance (12.2%), and greater radiographic severity of first MTP joint OA was characterized by relative dorsiflexion of the first metatarsal and uniformly distributed joint space narrowing.

There are two mechanical considerations that stem from the variations identified in lateral modes 1 and 2. First, lateral mode 1 aligns with previous studies that have reported a significantly greater dorsiflexion of the first metatarsal in individuals with first MTP joint OA compared with individuals without.<sup>27,28</sup> Second, in regard to the distribution of joint space narrowing across the first MTP joint, the reduced joint space in the dorsal aspect of the joint associated with higher scores for lateral mode 1 suggests that, as is the case in the knee,<sup>29</sup> osteoarthritic change can occur unevenly across the joint surface and may be influenced by mechanical loading. This is also consistent with the surgical literature that has described the distribution of joint degeneration

concentrated in the dorsal margins of the joint.<sup>30</sup> The variation identified by lateral modes 1 and 2 suggests a link between sagittal plane alignment of the first metatarsal and distribution of joint space narrowing in individuals with first MTP joint OA. Because the cross-sectional nature of this study does not allow temporal relationships to be examined, the interplay between first metatarsal sagittal plane alignment and progression of first MTP joint OA should be a focus of future prospective studies using SSM.

The four modes from lateral radiographs that were significantly associated with radiographic severity after adjustment (lateral modes 1, 2, 5, and 10) collectively explained 42% of total shape variance. Although there were differences in the features of variation identified, in all modes, greater radiographic severity of first MTP joint OA was associated with an overall larger osteophyte and the presence of a characteristic posteriorly orientated 'spike' of bone emanating from the main body of the osteophyte. This is an expected finding because the atlas used to classify severity in this study incorporates the assessment of osteophytes.

The functional and clinical importance of osteophytes associated with OA is unique to the joint in which they are located.<sup>31</sup> Osteophytes located at the dorsal margin of the first metatarsal are considered a defining clinical characteristic of first MTP joint OA.<sup>20</sup> Osteophytes associated with first MTP joint OA are unique in that they elicit pain on direct palpation.<sup>7</sup> Although all participants in this study exhibited an osteophyte, SSM analysis has provided an in-depth analysis of the characteristic size and shape of the osteophyte across a range of different severities.<sup>23</sup> Future SSM research should address the role of osteophyte formation in the development of first MTP joint OA and its association with symptoms.

For dorsoplantar-view radiographs, there were six modes of variation that were significantly associated with radiographic severity, collectively explaining 32.1% of total shape variance. A common feature of significant modes was the association between greater radiographic severity and an increased overall width of the first metatarsal and proximal phalanx. This observation is consistent with previous studies using the same dataset of radiographs that that used simple geometric measures.<sup>10</sup> Overall, the features of the six significant modes confirms that there is a wider base, shaft, and head of the first metatarsal and overall wider proximal phalanx. However, each mode characterized a different and unique variation of bone width.

A previous study examining bone dimensions on radiographs, not using SSM, found that comparatively greater width of the first metatarsal, but without excessive length, results in a comparatively squarer first MTP joint surface that will be predisposed to the development of first MTP joint OA.<sup>32</sup> Although features of dorsoplantar modes 2, 3, 9, and 14 indicate that the width of the bone and first MTP joint surface may be related to the severity of first MTP joint OA, dorsoplantar modes 8 and 11 indicate that greater joint width can occur independent

of bone width. Although our study provides some evidence for the association between greater first metatarsal width and the development of first MTP joint OA, further studies are required to determine the link between the overall morphology of the first metatarsal shaft and head and the development of the condition.

Four limitations must be considered with our study. First, the study was cross-sectional, so it is not known whether the variations in bone shape are a causative factor for the development of first MTP joint OA or whether variations are a consequence of first MTP joint OA progression. Second, the study used 2D radiographs to analyze bone shape and did not capture the 3D form of relevant bones and the first MTP joint. Third, there are likely to be factors other than bone shape and alignment that may contribute to the development and progression of first MTP joint OA such as previous trauma, work/occupation, footwear, and genetics.<sup>33</sup> Last, because this study excluded participants with hallux valgus, inferences cannot be made for individuals with hallux valgus or similar studies that included individuals with both first MTP joint OA and hallux valgus.

In summary, variations in shape and alignment of the medial cuneiform, first metatarsal, and proximal and distal phalanx of the hallux are associated with radiographic severity of first MTP joint OA. The outcomes of this study provide insights into the potential influence of mechanical factors in the development of first MTP joint OA. However, it is possible that other factors, such as genetic or lifestyle factors may also contribute to the development of the condition. Prospective studies are required to determine whether these bone shape characteristics are associated with the development and progression of first MTP joint OA.

## ACKNOWLEDGMENTS

Open access publishing facilitated by La Trobe University, as part of the Wiley - La Trobe University agreement via the Council of Australian University Librarians.

## AUTHOR CONTRIBUTIONS

All authors were involved in drafting the article or revising it critically for important intellectual content, and all authors approved the final version to be published. Dr. Menz had full access to all of the data in the study and takes responsibility for the integrity of the data and the accuracy of the data analysis.

**Study conception and design.** Buldt, Gregory, Munteanu, Marshall, Menz.

**Acquisition of data.** Buldt, Gregory, Munteanu, Allan, Tan, Auhl, Landorf, Marshall, Menz.

**Analysis and interpretation of data.** Buldt, Gregory, Munteanu, Allan, Tan, Auhl, Landorf, Roddy, Marshall, Menz.

## REFERENCES

1. Roddy E, Thomas MJ, Marshall M, et al. The population prevalence of symptomatic radiographic foot osteoarthritis in community-dwelling older adults: cross-sectional findings from the Clinical Assessment Study of the Foot. *Ann Rheum Dis* 2015;74:156–163.

2. Peat G, Rathod-Mistry T, Paskins Z, et al. Relative prevalence and distribution of knee, hand and foot symptomatic osteoarthritis subtypes in an English population. *Musculoskeletal Care*. 2020;18:219–224.
3. Menz HB, Roddy E, Marshall M, et al. Demographic and clinical factors associated with radiographic severity of first metatarsophalangeal joint osteoarthritis: cross-sectional findings from the Clinical Assessment Study of the Foot. *Osteoarthritis Cartilage* 2015;23:77–82.
4. Bergin SM, Munteanu SE, Zammit GV, et al. Impact of first metatarsophalangeal joint osteoarthritis on health-related quality of life. *Arthritis Care Res (Hoboken)* 2012;64:1691–1698.
5. Bowen C, Gates L, McQueen P, et al. The natural history of radiographic first metatarsophalangeal joint osteoarthritis: a nineteen-year population based cohort study. *Arthritis Care Res (Hoboken)* 2020; 72:1224–1230.
6. Neame R, Zhang W, Deighton C, et al. Distribution of radiographic osteoarthritis between the right and left hands, hips, and knees. *Arthritis Rheum* 2004;50:1487–1494.
7. Zammit GV, Munteanu SE, Menz HB. Development of a diagnostic rule for identifying radiographic osteoarthritis in people with first metatarsophalangeal joint pain. *Osteoarthritis Cartilage* 2011;19:939–945.
8. Zammit GV, Menz HB, Munteanu SE, et al. Plantar pressure distribution in older people with osteoarthritis of the first metatarsophalangeal joint (hallux limitus/rigidus). *J Orthop Res* 2008;26:1665–1669.
9. Menz HB, Auhl M, Tan JM, et al. Centre of pressure characteristics during walking in individuals with and without first metatarsophalangeal joint osteoarthritis. *Gait Posture* 2018;63:91–96.
10. Buldt AK, Munteanu SE, Allan JJ, et al. Structural characteristics associated with radiographic severity of first metatarsophalangeal joint osteoarthritis. *Arthritis Care Res (Hoboken)* 2021;73:1023–1030.
11. Gregory JS, Aspden RM. Femoral geometry as a risk factor for osteoporotic hip fracture in men and women [review]. *Med Eng Phys* 2008; 30:1275–1286.
12. Frysz M, Gregory JS, Aspden RM, et al. Describing the application of statistical shape modelling to DXA images to quantify the shape of the proximal femur at ages 14 and 18 years in the Avon Longitudinal Study of Parents and Children. *Wellcome Open Res* 2019;4:24.
13. Gregory JS, Waarsing JH, Day J, et al. Early identification of radiographic osteoarthritis of the hip using an active shape model to quantify changes in bone morphometric features: can hip shape tell us anything about the progression of osteoarthritis? *Arthritis Rheum* 2007;56:3634–3643.
14. Barr RJ, Gregory JS, Reid DM, et al. Predicting OA progression to total hip replacement: can we do better than risk factors alone using active shape modelling as an imaging biomarker? *Rheumatology (Oxford)* 2012;51:562–570.
15. Ahedi HG, Aspden RM, Blizzard LC, et al. Hip shape as a predictor of osteoarthritis progression in a prospective population cohort. *Arthritis Care Res (Hoboken)* 2017;69:1566–1573.
16. Gregory JS, Barr RJ, Yoshida K, et al. Statistical shape modelling provides a responsive measure of morphological change in knee osteoarthritis over 12 months. *Rheumatology (Oxford)* 2020;59: 2419–2426.
17. Agricola R, Reijman M, Bierma-Zeinstra S, et al. Total hip replacement but not clinical osteoarthritis can be predicted by the shape of the hip: a prospective cohort study (CHECK). *Osteoarthritis Cartilage* 2013; 21:559–564.
18. Milliken N, Menz H, Roddy E, et al. Foot morphology in osteoarthritis and hallux valgus. *Osteoarthritis Cartilage* 2014;22(Supplement): S302.
19. Menz HB, Levinger P, Tan JM, et al. Rocker-sole footwear versus pre-fabricated foot orthoses for the treatment of pain associated with first metatarsophalangeal joint osteoarthritis: study protocol for a randomised trial. *BMC Musculoskeletal Disord* 2014;15:86.
20. Munteanu SE, Landorf KB, McClelland JA, et al. Shoe-stiffening inserts for first metatarsophalangeal joint osteoarthritis (the SIMPLE trial): study protocol for a randomised controlled trial. *Trials* 2017; 18:198.
21. Garrow AP, Papageorgiou A, Silman AJ, et al. The grading of hallux valgus: the Manchester Scale. *J Am Podiatr Med Assoc* 2001;91: 74–78.
22. National Health and Medical Research Council. National Statement on Ethical Conduct in Human Research. Canberra: Australian Government; 2007 (updated 2018).
23. Menz HB, Munteanu SE, Landorf KB, et al. Radiographic classification of osteoarthritis in commonly affected joints of the foot. *Osteoarthritis Cartilage* 2007;15:1333–1338.
24. Cootes TF, Hill A, Taylor CJ, et al. Use of active shape models for locating structures in medical images. *Image Vision Comput* 1994; 12:355–365.
25. Gregory J, Stewart A, Reid DM, et al. Repeatability of active shape modelling of the proximal femur for radiographs and DXA scans. *J Bone Miner Res* 2005;20:1306.
26. Faber BG, Baird D, Gregson CL, et al. DXA-derived hip shape is related to osteoarthritis: findings from in the MrOS cohort. *Osteoarthritis Cartilage* 2017;25:2031–2038.
27. Bryant A, Mahoney B, Tinley P. Lateral intermetatarsal angle: a useful measurement of metatarsus primus elevatus? *J Am Podiatr Med Assoc* 2001;91:251–254.
28. Horton GA, Park YW, Myerson MS. Role of metatarsus primus elevatus in the pathogenesis of hallux rigidus. *Foot Ankle Int* 1999;20: 777–780.
29. Williams TG, Holmes AP, Waterton JC, et al. Anatomically corresponded regional analysis of cartilage in asymptomatic and osteoarthritic knees by statistical shape modelling of the bone. *IEEE Trans Med Imaging* 2010;29:1541–1559.
30. Shereff MJ, Baumhauer JF. Current concepts review - hallux rigidus and osteoarthrosis of the first metatarsophalangeal joint. *J Bone Joint Surg* 1998;80:898–908.
31. Van der Kraan PM, van den Berg WB. Osteophytes: relevance and biology [review]. *Osteoarthritis Cartilage* 2007;15:237–244.
32. Munuera PV, Dominguez G, Castillo JM. Radiographic study of the size of the first metatarso-digital segment in feet with incipient hallux limitus. *J Am Podiatr Med Assoc* 2007;97:460–468.
33. Roddy E, Menz HB. Foot osteoarthritis: latest evidence and developments [review]. *Ther Adv Musculoskelet Dis* 2018;10:91–103.