

ORIGINAL ARTICLE / ARTÍCULO ORIGINAL

LIVER HISTOPATHOLOGY OF *ECHINOCOCCUS GRANULOSUS* INFECTION IN *SUS SCROFA* FROM BRAZIL

HISTOPATOLOGÍA DEL HÍGADO CAUSADA POR LA INFECCIÓN POR *ECHINOCOCCUS GRANULOSUS* EN *SUS SCROFA* PROCEDENTE DE BRASIL

Fernanda Almeida B^{1,3}, Magda Oliveira S¹, Renata Neves H¹, Jessica Santos A¹, Albanita Oliveira V², José Roberto Machado-Silva³, & Rosângela Rodrigues-Silva^{1*}

¹ Laboratório de Helmintos Parasitos de Vertebrados, Instituto Oswaldo Cruz, Fundação Oswaldo Cruz, Avenida Brasil 4365, Manguinhos, Rio de Janeiro, 21040-900, RJ, Brasil.

² Disciplina de Anatomia Patológica, Departamento de Patologia e Laboratórios, Faculdade de Ciências Médicas, Universidade do Estado do Rio de Janeiro (UERJ), Rio de Janeiro, Brasil.

³ Laboratório Romero Lascasas Porto, Departamento de Microbiologia, Imunologia e Parasitologia, Faculdade de Ciências Médicas, Universidade do Estado do Rio de Janeiro, Rio de Janeiro, Rua Prof. Manoel de Abreu 444/5º andar, Vila Isabel, Rio de Janeiro, 20511-070, Brasil.

Suggested citation: Almeida, B.F., Oliveira, S.M., Neves, H.R., Santos, A.J., Oliveira, V.A., Machado-Silva, J.R. & Rodriguez-Silva, R. 2011. Liver histopathology of *Echinococcus granulosus* infection in *Sus scrofa* from Brazil. Neotropical Helminthology, vol. 5, n° 1, pp.24 -30.

Abstract

Museum specimens represent a valuable resource for helminthological research. We examined formalin-fixed livers preserved for periods in excess of 50 years from naturally infected pigs in archival material from the Helminthological Collection of the Oswaldo Cruz Institute (CHIOC), Oswaldo Cruz Foundation (FIOCRUZ). Microscopic examination revealed evidence of parasites in unilocular cystic structures containing a bladder worm vesicle lined with a thin laminated membrane. The inner germinal layer contained parasite debris and a proteinaceous hydatid-like fluid. The hepatic parenchyma showed a dense inflammatory infiltrate near the cyst, thick-walled arterial vessels, and occasionally necrosis. The adjacent hepatic parenchyma showed inter- and intra-lobular thin fibrosis, inflammatory cell infiltration and occasionally necrosis. Other histo-pathological sections showed a thick laminated wall cystic structure with brood capsules in the germinal layer containing small round projections with central internal vesicles on the inner surface, suggesting the presence of protoscolices. Given that *Echinococcus multilocularis* does not occur in Brazil, our histological findings were identified as *Echinococcus granulosus* in origin. In conclusion, the protocol presented in this study highlights the possibility of achieving remarkably high quality histological results in archival formalin-fixed and paraffin-embedded tissues retrieved from museum specimens that have been preserved for many years.

Key words: Brazil - *Echinococcus granulosus* - histopathology - liver - *Sus scrofa*.

Resumen

Los especímenes de museo representan un recurso valioso para la investigación helmintológica. Hemos examinado los hígados fijados en formalina conservados por períodos de más de 50 años a partir de cerdos infectados naturalmente en el material de archivo de la Colección Helmintológica del Instituto Oswaldo Cruz (CHIOC), Fundación Oswaldo Cruz (FIOCRUZ). El examen microscópico reveló evidencia de parásitos en estructuras quísticas uniloculares que contienen una vesícula de la membrana del parásito recubierto con una lámina delgada. La capa interna germinal contiene los restos del parásito y un líquido proteico como hidatídico. El parénquima hepático mostró un denso infiltrado inflamatorio cerca del quiste, los vasos arteriales de paredes gruesas y necrosis de vez en cuando. El parénquima hepático adyacente mostró fibrosis delgada inter e intralobular, la infiltración de células

inflamatorias y necrosis de vez en cuando. Otros cortes histológicos mostraron una estructura de pared gruesa laminada quística con cápsulas de cría en la capa germinal que contienen proyecciones pequeñas y redondas con el centro de las vesículas internas en la superficie interna, lo que sugiere la presencia de protoescólices. Teniendo en cuenta que *Echinococcus multilocularis* no ocurre en Brasil, nuestros hallazgos histológicos fueron identificados como *Echinococcus granulosus* de origen. En conclusión, el protocolo que se presenta en este estudio pone de relieve la posibilidad de lograr resultados histológicos de muy alta calidad en archivos fijados en formalina y parafina de tejidos embebidos recuperados de especímenes de museo que se han conservado durante muchos años.

Palabras clave: Brasil - *Echinococcus granulosus* - hígado - histopatología - *Sus scrofa*.

INTRODUCTION

Pig-rearing practices expose pigs to parasitic infection, mainly, those of tapeworm origin. Taeniid tapeworms in their larval stage remain a significant medical and veterinary public health concern (Thompson, 2008) and cause significant losses to livestock and human productivity (Jenkins *et al.*, 2005; Eddi *et al.*, 2006; Scala *et al.*, 2006). Some species are sustained by a predator-prey cycle in which carnivore definitive hosts harbor adult worms in the small intestine, whereas herbivore intermediate hosts develop the metacestode stage in organs (Thompson & McManus, 2002). In South America, cystic echinococcosis disease caused by *Echinococcus granulosus* (Batsch, 1786) and characterized by unilocular hydatid cyst occurs in the sheep-rearing rural areas of southern Brazil, Uruguay, Argentina, Chile and Bolivia (Kamenetzky *et al.*, 2002).

Previous studies on the helminth faunae of *Sus scrofa* (Linnaeus, 1758) raised in outdoor conditions have reported *Taenia hydatigena* (Pallas, 1766) larva (*Cysticercus tenuicollis*) (Solaymani-Mohammadi *et al.*, 2003), *Cysticercus tenuicollis* and *Cysticercus cellulosae* (Jarvis *et al.*, 2007). Epidemiological studies have revealed *C. cellulosae* (Phiri *et al.*, 2003) and *E. granulosus* hydatidosis in swine from home slaughtering (Bružinskaite *et al.*, 2009) and slaughterhouses (Lidetul & Hutchinson, 2007; Acosta-Jamett *et al.*, 2010). Furthermore, molecular studies highlight the occurrence of host-adapted *E. granulosus* strains in infected pigs (Kamenetzky *et al.*, 2002; Breyer *et al.*, 2004; Daniel-Mwambete *et al.*, 2004; Haag *et al.*, 2004; Cruz-Reyes *et al.*, 2007; Badaraco *et al.*, 2008; Schneider *et al.*, 2010). A few reports have been published on parasite histopathology in pigs: unilocular hydatid cysts

were distributed in the liver and lungs (Lidetul & Hutchinson, 2007) or in the thoracic and abdominal cavities (Martin-Hernando *et al.*, 2008). Histopathological examination showed a typical laminated membrane (Lidetul & Hutchinson, 2007) and a fibrous capsule composed of collagenous connective tissue with sporadic calcification in mature cysts, whereas immature cysts were surrounded by inflammatory infiltrate (Martin-Hernando *et al.*, 2008). Experimentally *E. multilocularis* (Leuckart, 1863) -infected pigs showed the largest lesions (3–8 mm in diameter), pronounced central necrosis and dystrophic calcifications. In contrast, most of the smallest lesions (usually <1.5 mm in diameter) had small compact fibrotic areas and blurred borders with obvious fibrous infiltrations into interlobular tissues (Deplazes *et al.*, 2005). A few reports have been published on parasite histopathology in European and Australian pigs (Lidetul & Hutchinson, 2007). Although molecular studies have been performed for taxonomic analyses, there is no information on the histopathology of *E. granulosus* in Brazilian pigs (*S. scrofa*). We examined formalin-fixed livers from naturally infected pigs in archival material from Brazil. Museum specimens are a valuable resource for helminthological research (Santos & Moravec, 2009).

MATERIALS AND METHODS

We studied formalin-fixed livers from two *S. scrofa* held in the state of Rio de Janeiro (22°54'S43°10'W), Brazil and deposited in the Helminthological Collection of the Oswaldo Cruz Institute (CHIOC) by Travassos (Fig. 1). Following paraffin embedding, 5 µm thick sections were

stained with conventional hematoxylin and eosin and examined. Histopathological analysis and photomicrography were obtained under a conventional Eclipse E200 Nikon light microscope.

RESULTS

Microscopic examination revealed evidence of parasites in unilocular cystic structures. The structures contained a bladder worm vesicle lined with a thin-laminated membrane and an inner germinal layer with parasite debris and a proteinaceous hydatid-like fluid (Fig. 2a-b). Other histological sections showed a thick-laminated wall cystic structure with brood capsules (germinal layer) containing small round projections with central internal vesicles on the inner surface, suggesting the presence of protoscolices and their hooks (Fig. 2b-c).

The cyst wall was attached to the nontrabeculae hepatic parenchyma, showing a dense inflammatory infiltrate nearest to the cyst (Fig. 2d-3a), thick-walled arterial vessels and occasionally necrosis, which is consistent with vasculitis (Fig. 3b-d). The adjacent hepatic parenchyma showed inter- and intralobular thin fibrosis, consistent with regenerative nodules. Both the septa and bile canaliculi showed perivascular inflammatory infiltrate, whereas the fibrosis surrounding the cyst presented arterial vessels with acidophilic necrosis. The histological findings were identified as *Echinococcus* in origin.

DISCUSSION

The liver is the predicted site for metacestodes of some species of tapeworms in wild boar (Oberg & Valenzuela, 1977; Pfister *et al.*, 1993; Aluja *et al.*, 1998; Blažek *et al.*, 1985; de-la-Muela *et al.*, 2001; Phiri *et al.*, 2003; Solaymani-Mohammadi *et al.*, 2003; Rodriguez *et al.*, 2006; Jarvis *et al.*, 2007; Lidetul & Hutchinson, 2007; Martin-Hernando *et al.*, 2008; Bružinskaite *et al.*, 2009).

Although cystic echinococcosis disease is a significant veterinary public health concern in southern Brazil (de La Rue *et al.*, 2006; Moro & Schantz, 2009), records of swine infection are limited.

In this study, we provided evidence of *Echinococcus* infection in *S. scrofa* by means of liver histopathology. To this end, we visited CHIOC and identified formalin-fixed liver hydatid cysts. Furthermore, records demonstrated that the liver was isolated from *S. scrofa* in Santa Cruz (Rio de Janeiro). This finding raises the following question: given that Rio de Janeiro is not known to be an endemic area for *E. granulosus*, what was the origin of the infected pigs? According to historical records, Santa Cruz harbored an important abattoir in the last century, providing meat for consumption in Rio de Janeiro City (Ecomuseu, 2010). In addition, an early historical report highlighted the presence of *Echinococcifer echinococcus* in the livers of swine derived from other regions (Travassos & Silva, 1915). At that time, however, a characterization of parasite histopathology was not performed. Animal trade represents a potential source of zoonotic pathogens, as exemplified by *E. granulosus* (Haag *et al.*, 2004; Pavlin *et al.*, 2009). Previous studies also reported the occurrence of hydatid cysts in pigs from abattoirs in Spain (Daniel-Mwambete *et al.*, 2004), Australia (Lidetul & Hutchinson, 2007) and Chile (Acosta-Jamett *et al.*, 2010).

Paraffin-embedded archival material is a valuable resource for cysticercosis (Ogunremi *et al.*, 2004) and hydatidosis retrospective studies (Schneider *et al.*, 2008). Species of *Echinococcus* are characterized by a hydatid type of bladder worm (Pfister *et al.*, 1993; Lidetul & Hutchinson, 2007; Bružinskaite *et al.*, 2009). In this study, histological examination revealed a laminated layer that gave rise to brood capsules and protoscolices consistent with *Echinococcus* infection (Lidetul & Hutchinson, 2007; Martin-Hernando *et al.*, 2008). Studies demonstrate that brood capsules are not observed in unfavorable hosts (Pfister *et al.*, 1993); therefore, pigs may be considered permissive hosts for *E. granulosus*. The adjacent hepatic parenchyma showed inter- and intralobular thin fibrosis, inflammatory cell infiltration and occasionally necrosis. The pathological changes observed were similar to those described in wild boar naturally infected with *E. multilocularis* (Boucher *et al.*, 2005). Given that *E. multilocularis* does not occur in Brazil, our histological finding confirmed the diagnosis of *E. granulosus*.

The quality of histological material may be affected by many factors including the age of the specimen, type and length of fixation/preservation and storage conditions. The protocol presented in this study highlights the possibility of achieving remarkably high quality histological results in archival formalin-fixed and paraffin-embedded tissues retrieved from museum specimens that have been preserved for many years. In conclusion, our study histologically demonstrated the occurrence of *E. granulosus* in swine and also confirms that specimens in museums represent a valuable resource for helminthological research.

ACKNOWLEDGEMENTS

The authors would like to thank Rodrigo Méxas from the Laboratório de Produção e Processamento de Imagem Científica, IOC - Fiocruz for preparing the images.

I. O. C. COLEÇÃO HELMINTOLÓGICA	N. 2658	
	Nome <i>E. chinococcoides</i>	
	Hosp. <i>Sus scrofa dom.</i>	
	Local. Fígado	
	Prov. Paraíba - Rio	
	Meio cons. Parafina	
	Col. por Trassau	Dat. 2-11-92
	Det. por Trassau	Dat. 11-92
	Preparação de	Dat.
	Aut. n.	Obs.

Figure 1. Card files of the Helminthological Collection of the Oswaldo Cruz Institute (CHIOC).

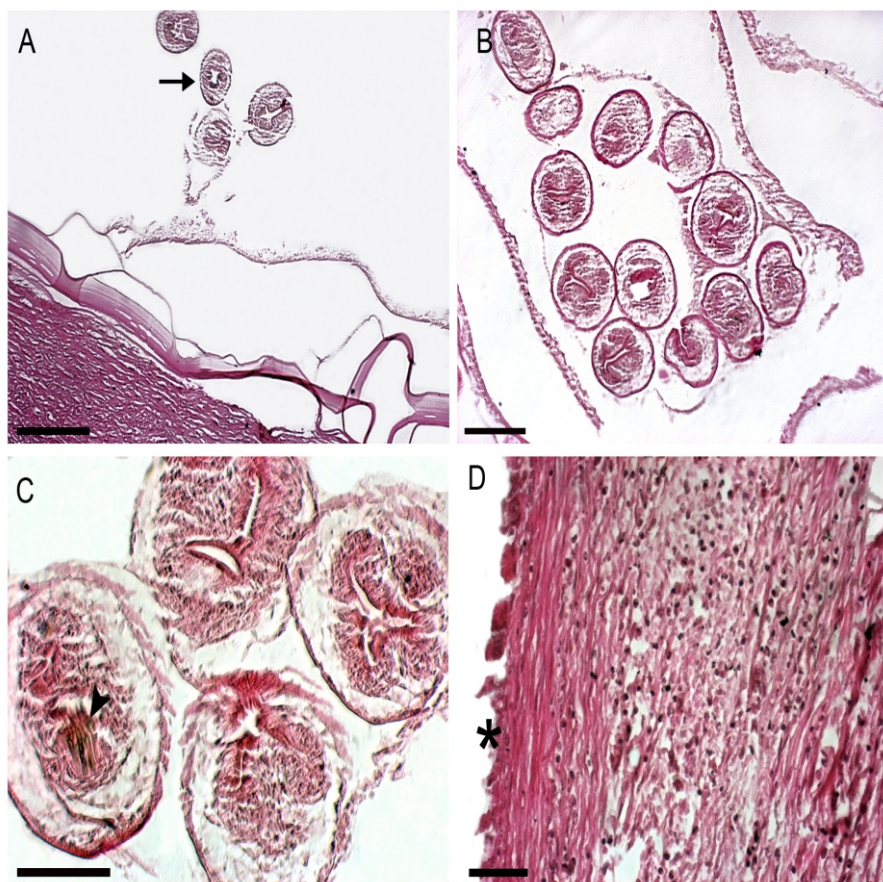


Figure 2. Histopathological aspects of hydatid cysts in natural infection of *Sus scrofa* with *Echinococcus granulosus*. **a** Unilocular cystic structure containing a bladder worm vesicle lined by a thin laminated membrane and an inner germinal layer with parasite debris (arrow) and a proteinaceous hydatid-like fluid, bar 0.02 mm; **b** Brood capsules (germinal layer) containing protoscolices, bar 0.01 mm; **c** Protoscolices and their hooks (arrowhead), bar 0.05 mm; **d** Cyst wall (*) in hepatic parenchyma showing a dense inflammatory infiltrate nearest to the cyst, bar 0.05 mm.

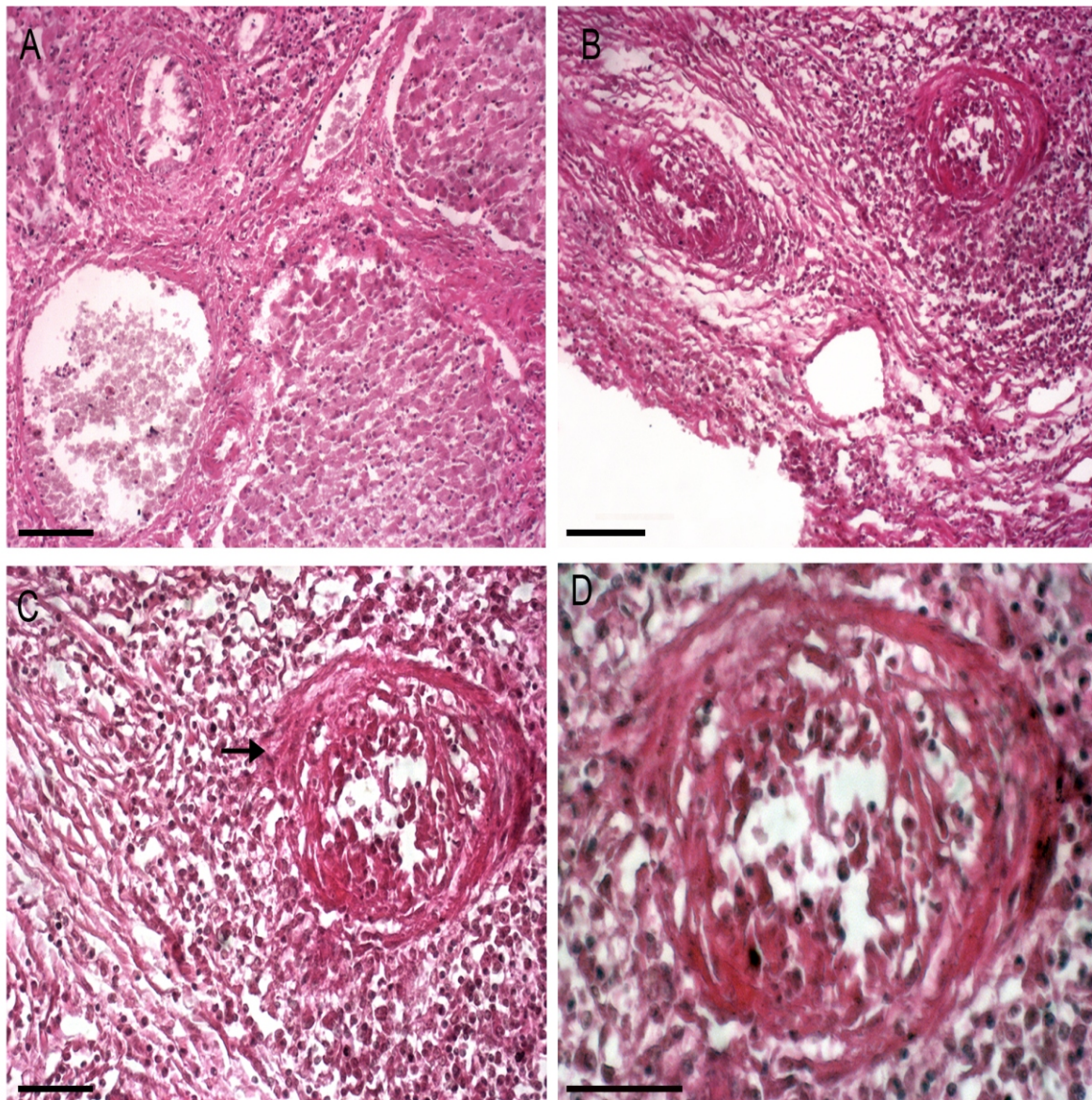


Figure 3. Histopathological aspects of hepatic tissues in natural infection of *Sus scrofa* with *Echinococcus granulosus*. **a** Hepatic parenchyma showing a dense inflammatory infiltrate in interlobular and intralobular septa with hepatocyte necrosis, bar 0.01 mm; **b** Cyst wall exhibiting on its inner surface wall vessels permeated by inflammatory cells and necrosis, bar 0.01 mm; **c** Detail of the cyst wall and necrotizing vasculitis (arrow), bar 0.05 mm; **d** detail of necrotizing vasculitis, bar 0.05 mm.

BIBLIOGRAPHIC REFERENCES

- Acosta-Jamett, G, Cleaveland, S, Cunningham, AA, Bronsvort, BM & Craig, PS. 2010. *Echinococcus granulosus* infection in humans and livestock in the Coquimbo region, north-central Chile. *Veterinary Parasitology*, vol.169, pp.102-110.
- Aluja, AS, Martinez, MJJ & Villalobos, AN. 1998. *Taenia solium* cysticercosis in young pigs: age at first infection and histological characteristics. *Veterinary Parasitology*, vol.76, pp.71-79.

- Badaraco, JL, Ayala, FJ, Bart, JM, Gottstein, B & Haag, KL. 2008. *Using mitochondrial and nuclear markers to evaluate the degree of genetic cohesion among Echinococcus populations*. *Experimental Parasitology*, vol.119, pp.453-459.
- Blazek, K, Schramlová, J & Hulínská, D. 1985. *Pathology of the migration phase of Taenia hydatigena (Pallas, 1766) larvae*. *Folia Parasitologica*, vol.32, pp.127-137.
- Boucher, JM, Hanosset, R, Augot, D, Bart, JM, Morand, M, Piarroux, R, Pozet-Bouhier, F, Losson, B & Cliquet, F. 2005. *Detection of Echinococcus multilocularis in wild boars in France using PCR techniques against larval form*. *Veterinary Parasitology*, vol.129, pp. 259-266.
- Breyer, I, Georgieva, D, Kurdova, R & Gottstein, B. 2004. *Echinococcus granulosus strain typing in Bulgaria: the G1 genotype is predominant in intermediate and definitive wild hosts*. *Parasitology Research*, vol.93, pp.127-130.
- Bruzinskaite, R, Sarkūnas, M, Torgerson, PR, Mathis, A & Deplazes, P. 2009. *Echinococcosis in pigs and intestinal infection with Echinococcus spp. in dogs in southwestern Lithuania*. *Veterinary Parasitology*, vol.160, pp.237-241.
- Cruz-Reyes, A, Constantine, CC, Boxell, AC, Hobbs, RP & Thompson, RC. 2007. *Echinococcus granulosus from Mexican pigs is the same strain as that in Polish pigs*. *Journal of Helminthology*, vol.81, pp.287-292.
- Daniel-Mwambete, K, Ponce-Gordo, F & Cuesta-Bandera, C. 2004. *Genetic identification and host range of the Spanish strains of Echinococcus granulosus*. *Acta Tropica*, vol.91, pp.87-93.
- de-la-Muela, N, Hernández-de-Luján, S & Ferre, I. 2001. *Helminths of wild boar in Spain*. *Journal of Wildlife Diseases*, vol.37, pp.840-843.
- de La Rue, ML, Dinkel, A, Mackenstedt, U & Romig, T. 2006. *New data on Echinococcus spp. in Southern Brazil*. *Revista do Instituto de Medicina Tropical de São Paulo*, vol.48, pp.103-104.
- Deplazes, P, Grimm, F, Sydler, T, Tanner, I & Kapel, CM. 2005. *Experimental alveolar echinococcosis in pigs, lesion development and serological follow up*. *Veterinary Parasitology*, vol.130, pp. 213-222.
- Ecomuseu. 2010. *Quarteirão Cultural do mata-douro* accessed <http://www.quarteirão.com.br> (January,10,2011).
- Eddi, C, Katalin, B, Juan, L, William, A, Andrew, S, Daniela, B & Joseph, D. 2006. *Veterinary public health activities at FAO: cysticercosis and echinococcosis*. *Parasitology International*, vol.55, pp.305-308.
- Haag, KL, Alves-Junior, L, Zaha, A & Ayala, FJ. 2004. *Contingent, non-neutral evolution in a multicellular parasite: natural selection and gene conversion in the Echinococcus granulosus antigen B gene family*. *Gene*, vol.333, pp.157-167.
- Järvis, T, Kapel, CH, Moks, E, Talvik, H & Mägi, E. 2007. *Helminths of wild boar in the isolated population close to the northern border of its habitat area*. *Veterinary Parasitology*, vol.150, pp.366-369.
- Jenkins, DJ, Romig, T & Thompson, RC. 2005. *Emergence/re-emergence of Echinococcus spp. a global update*. *International Journal for Parasitology*, vol.35, pp.1205-1219.
- Kamenetzky, L, Gutierrez, AM, Canova, SG, Haag, KL, Guarnera, EA, Parra, A, García, GE & Rosenzvit, MC. 2002. *Several strains of Echinococcus granulosus infect livestock and humans in Argentina*. *Infection, Genetics and Evolution*, vol.2, pp.129-136.
- Lidetul, D & Hutchinson, GW. 2007. *The prevalence, organ distribution and fertility of cystic echinococcosis in feral pigs in Tropical North Queensland, Australia*. *Onderstepoort Journal of Veterinary Research*, vol.74, pp.73-79.
- Martín-Hernando, MP, González, LM, Ruiz-Fons, F, Garate, T & Gortazar, C. 2008. *Massive presence of Echinococcus granulosus (Cestoda, Taeniidae) cysts in a wild boar (Sus scrofa) from Spain*. *Parasitology Research*, vol.103, pp.705-707.

- Moro, P & Schantz, PM. 2009. *Echinococcosis: a review*. International Journal of Infectious Diseases, vol.13, pp.125-133.
- Oberg, C & Valenzuela, G. 1977. *Cysticercus tenuicollis (Taenia hydatigena, Pallas, 1766) in swine from Valdivia Province, Chile*. Boletín Chileno de Parasitología, vol.32, pp. 44-45.
- Ogunremi, O, MacDonald, G, Geerts, S & Brandt, J. 2004. *Diagnosis of Taenia saginata cysticercosis by immunohistochemical test on formalin-fixed and paraffin-embedded bovine lesions*. Journal of Veterinary Diagnostic Investigation, vol.16, pp.438-441.
- Pavlin, BI, Schloegel, LM & Daszak, P. 2009. *Risk of importing zoonotic diseases through wildlife trade, United States*. Emerging Infectious Diseases, vol.11, pp.1721-1726.
- Pfister, T, Schad, V, Schelling, U, Lucius, R & Frank, W. 1993. *Incomplete development of larval Echinococcus multilocularis (Cestoda: Taeniidae) in spontaneously infected wild boars*. Parasitology Research, vol.79, pp.617-618.
- Phiri, IK, Ngowi, H, Afonso, S, Matenga, E, Boa, M, Mukaratirwa, S, Githigia, S, Saimo, M, Sikasunge, C, Maingi, N, Lubega, GW, Kassuku, A, Michael, L, Siziya, S, Kreczek, RC, Noormahomed, E, Vilhena, M, Dorny, P & Willingham, AL. 2003. *The emergence of Taenia solium cysticercosis in Eastern and Southern Africa as a serious agricultural problem and public health risk*. Acta Tropica, vol.87, pp.13-23.
- Rodríguez, ML, Rodríguez, S, Gonzalez, AE, Verastegui, M, Bernal, T, Jiménez, JA & Garcia, H. 2006. *Can Taenia solium latent post-oncospherical stages be found in muscle tissue of Cysticercosis-infected pigs (Sus scrofa)?* The Journal of Parasitology, vol. 92, pp.199-201.
- Santos, CP & Moravec, F. 2009. *Camallanus tridentatus (Drasche) (Nematoda: Camallanidae): new taxonomically important morphological data*. Memórias do Instituto Oswaldo Cruz, vol.104, pp.93-99.
- Scala, A, Garippa, G, Varcasia, A, Tranquillo, VM & Genchi, C. 2006. *Cystic echinococcosis in slaughtered sheep in Sardinia (Italy)*. Veterinary Parasitology, vol.135, pp.33-38.
- Schneider, R, Gollackner, B, Edel, B, Schmid, K, Wrba, F, Tucek, G, Walochnik, J & Auer, H. 2008. *Development of a new PCR protocol for the detection of species and genotypes (strains) of Echinococcus in formalin-fixed, paraffin-embedded tissues*. International Journal for Parasitology, vol.38, pp.1065-1071.
- Schneider, R, Gollackner, B, Schindl, M, Tucek G & Auer, H. 2010. *Echinococcus canadensis G7 (pig strain): an underestimated cause of cystic echinococcosis in Austria*. American Journal of Tropical Medicine and Hygiene, vol.82, pp.871-874.
- Solaymani-Mohammadi, S, Mobedi, I, Rezaian, M, Massoud, J, Mohebali, M, Hooshyar, H, Ashrafi, K & Rokni, MB. 2003. *Helminth parasites of the wild boar, Sus scrofa, in Luristan province, western Iran and their public health significance*. Journal of Helminthology, vol.77, pp.263-267.
- Thompson, RC. 2008. *The taxonomy, phylogeny and transmission of Echinococcus*. Experimental Parasitology, vol.119, pp.439-446.
- Thompson, RC & McManus, DP. 2002. *Towards a taxonomic revision of the genus Echinococcus*. Trends in Parasitology, vol.18, pp.452-457.
- Travassos, LP & Silva, OD. 1915. *Da presença do cisto hydatico no Rio de Janeiro*. Brazil Médico, vol.29, pp.97.

Received January 19, 2011.

Accepted April 26, 2011.

*Author for Correspondence / Autor para correspondencia:

Rosângela Rodrigues-Silva
Laboratório de Helmintos Parasitos de Vertebrados,
Instituto Oswaldo Cruz, Fundação Oswaldo Cruz, Avenida
Brasil 4365, Manguinhos, Rio de Janeiro, 21040-900, RJ,
Brasil. Phone: +55-021-25621485. Fax: +55-021-
25621511.

E-mail/correo electrónico:
rsilva@ioc.fiocruz.br