

Application of the Acral Coactivation Therapy Method in the Treatment of a Student Diagnosed with Idiopathic Adolescent Scoliosis

Jan VAGNER ¹

Elena BENDÍKOVÁ ²

¹ ReAktiv active physiotherapy Olomouc, outpatient physiotherapy, non-state medical facility, Czech Republic, ACT centrum s.r.o., postgraduate education centre, establishment accredited by the Ministry of Health of the Czech Republic, Praha, Čelákovice, Czech Republic, bendikova.elena@gmail.com

² Department of Physical Education and Sports, Faculty of Education, CU Ružomberok, Slovakia, bendikova.elena@gmail.com

Abstract: *Background and Aim of Study:* The aetiology of idiopathic scoliosis is still an unsolved problem. It is a three-dimensional spinal deformity that comprehensively impacts the musculoskeletal and cardiorespiratory systems. The aim of this pilot study was to find out how adolescent idiopathic scoliosis (AIS) can be treated by means of the Acral Coactivation Therapy (ACT) method. *Material and Methods:* The study was conducted on a 16-year-old student who had a body weight of 56 kg and a body height of 166 cm and was in his second year of high school. The student was diagnosed with AIS. We acquired data by means of standard medical-therapeutic methods and procedures applied in patients with AIS. Radiographic parameters, such as the Cobb angle as well as the Anterior and Posterior Trunk Symmetry Indexes (ATSI/POTSI), including the SCODIAC programme, were used to monitor the student's progress. *Results:* In 2022, the student underwent a five-month exercise programme based on the ACT method, which was evaluated using clinical case study methods. The results showed a positive effect of the ACT method on the student's spine curvature and body posture. There was an improvement of 21° in the thoracic curve and 20° in the curvature of his lumbar spine. In addition, the ATSI/POTSI improved from 36 to 7 (with a difference (*r*) of 29). *Conclusions:* The acquired qualitative data show a positive effect of the ACT method when it comes to correction of the curvature in a student diagnosed with adolescent idiopathic scoliosis. The stated finding also points to the importance of regular physical activity in the student's movement regime.

Keywords: *adolescent idiopathic scoliosis, acral coactivation therapy, student.*

How to cite: Vagner, J., & Bendikova, E. (2023). Application of the acral coactivation therapy method in the treatment of a student diagnosed with idiopathic adolescent scoliosis. *BRAIN. Broad Research in Artificial Intelligence and Neuroscience*, 14(4), 551-562. <https://doi.org/10.18662/brain/14.4/520>

Introduction

During the process of growth as well as in adulthood, various postural disorders may arise, most commonly among pre-school and school-age children. Our posture is influenced by both external and internal factors, to which our bodies are increasingly struggling to adapt owing to the contemporary lifestyle (Bendíková, 2017).

The modern lifestyle might be characterised by reduced physical activity, immersion in the world of virtual reality and an increasing distance from physical activities that used to be common in the past. This modern way of life undoubtedly impacts children and adolescents, who often lack adequate physical activities that would shape their physiological postural as well as psychosocial development (Gaetano, 2016; Nemček, 2016). On the other hand, inadequate physical activities, such as asymmetric load sports taken up at an early age without compensation by means of other physical activities or overall overloading of an adolescent body with inadequate physical activities (weightlifting in the gym, etc.) may also result in the maladaptation of the body to strain, which can manifest in pathological patterns of a child (Nemček & Ladecká, 2020). Both the aforementioned factors lead to postural disorders in children and adolescents. These disorders of muscle co-activation, which result in poor body posture, can be effectively addressed by means of targeted physiotherapy, exercise programmes and lifestyle measures applied at home and at school as well (Bendíková, 2020; Lenková, 2021; Bendíková & Balkó, 2022). If functional development leads to structural changes in the spine, conventional therapy methods might not be sufficient to restore physiological patterns (Addai et al., 2020; Kuznia et al, 2020).

Adolescent idiopathic scoliosis (AIS) is a three-dimensional deformity of the spine and the rib cage. The etiopathogenesis of AIS is still a debated issue and remains somewhat unexplored. According to Addai et al. (2020), in addition to external factors influencing an adolescent organism, genetics, increased calmodulin levels in platelets, vitamin D deficiency, low levels of estrogen and growth hormone deficiency play a significant role as well. The primary goal of AIS rehabilitation treatment is to improve or contain the curve progression. In addition, it aims to prevent secondary problems, such as postural asymmetry, which can result in an uneven distribution of body weight on the lower limbs that can lead to arthritic changes in the joints. Last but not least, rehabilitation is aimed at compensation for cosmetic trunk deformities and asymmetrical pelvic

posture. Postural decompensation can have a significant psychosocial impact in adolescence.

Rehabilitation procedures are commonly used to treat moderate scoliosis (the Cobb angle in the range between 20 and 40/45 degrees). Curve progression can be tackled more effectively by supplementing the rehabilitation therapy with trunk orthoses, which ensure mechanical resistance against the progressing direction, thereby aiding in the correction of the spine and ideally achieving a proper posture. Rehabilitation and health-focused exercises based on motor learning are aimed at the development of effective postural patterns that will allow individuals to maintain compensated body posture through automation of movement patterns and behavioural changes (Gozde & Yavuz, 2019; Kuznia et al., 2020).

Various exercise procedures and movement programmes are commonly used to treat, stabilise and prevent AIS. They are focused on auto-correction that requires individual exercise composition according to the shape, location and size of the curve. Scientists most often employ the SEAS method, Schroth exercises, DoboMed and side-shift therapy. These methods utilise muscle activity for targeted three-dimensional correction of the curve. Nevertheless, general rehabilitation procedures (for example, exercises aimed at strengthening the deep spine stabilising system – so-called CORE training, Pilates, yoga, etc.). These procedures can be regarded as stabilisation and body conditioning exercises. It is impossible to say which conventional ASI treatment and prevention method is the most effective (Gozde & Yavuz, 2019; Negrini, et al., 2015). That is why it is important to note that there is currently an increasing number of students who are exempted from physical and sports education classes, mainly due to various health problems related to their postural health. These problems are the most common reasons why students do not perform curriculum-based physical activities at school. A controlled and targeted intervention within this subject might be a starting point for the prevention of posture problems as well as for their treatment and stabilisation.

The goal of this pilot study was to determine whether the acral co-activation therapy method can contain or improve the curve progression in a student diagnosed with adolescent idiopathic scoliosis within the ADL movement mode.

Material and Methods

Participants

In this study, we monitored one subject, a 16-year-old student (n=1) with a body weight of 56 kg and a body height of 166 cm, who was studying the second year at one vocational high school. The subject was diagnosed with adolescent idiopathic scoliosis in April 2021. Since then, he has undergone repeated rehabilitation programmes (mainly stretching and static stabilisation exercises used for the treatment of poor posture).

Measurements and Procedure

Based on the worsening of the spinal curve detected by an X-ray examination, surgical treatment was recommended. Due to his medical history (the subject underwent two esophageal surgeries from his birth to two years old), the student refused surgical treatment and opted for conventional therapy aimed at correcting his curvature. Based on the acral coactivation diagnosis (ACD), a workout programme was developed following the acral coactivation therapy (ACT). It is a physiotherapeutic method developed by Dr. Palašćáková Špringrová based on the Roswitha Brunkow method (Palašćáková Špringrová, 2011). Acral coactivation therapy is a physiotherapeutic method that utilises motor development positions and has a neurophysiological basis. It mainly involves press exercises against acral parts of the limbs, which leads to the coactivation of muscle chains (Palašćáková Špringrová, 2016). The main goal of the ACT method is the spine straightening by means of motor learning.

The study was conducted from the beginning of January 2022 (the first physiotherapy session and photo documentation) until the end of May 2022 (the last visit to the physiotherapist after the X-ray examination and photo documentation).

A five-month exercise programme based on the ACT methods was divided into three compact parts A, B, C, which were carried out by the student within the ADL (Active Daily Life) movement mode.

A. During the first three months, the student exercised for 20 minutes twice a day, with a total of 180 repetitions. The exercises were as follows:

- Four-point kneeling with right upper limb extension (10 repetitions).
- Four-point kneeling with right lower limb extension (10 repetitions).
- Four-point kneeling with left upper limb extension (10 repetitions).
- Four-point kneeling with left lower limb extension (10 repetitions).
- Side bend to the left/right (15/15 repetitions).

Automobilisation of the thoracic spine in a prone position (5 repetitions on the left, 15 repetitions on the right).

B. In the 4th month, the student exercised 6 times per week, twice a day for 25 minutes, with a total of 220 repetitions.

Four-point kneeling with right upper and left lower limbs extension (10 repetitions).

Four-point kneeling with left upper and right lower limbs extension (10 repetitions).

Four-point with knee lift (10 repetitions).

Side bend to the left/right (10/10 repetitions).

Dynamic transition from a prone to a four-kneeling position through a side bend to the left/right (10/10 repetitions).

Low oblique sit-up exercise to the left/right (10/10 repetitions).

Automobilisation of the thoracic spine in a prone position (5 repetitions on the left, 15 repetitions on the right).

C. In the 5th month, the subject worked out 5 times per week, twice a day for 30 minutes with a total of 310 repetitions.

Four-point kneeling with right upper and left lower limbs extension (10 repetitions).

Four-point kneeling with left upper and right lower limbs extension (10 repetitions).

Four-point kneeling with right upper and left lower limbs extension (10 repetitions).

Four-point kneeling with left upper and right lower limbs extension (10 repetitions).

Four-point with knee lift (10 repetitions).

Side bend to the left/right (10/10 repetitions).

Dynamic transition from a prone to a four-kneeling position through a side bend to the left/right (10/10 repetitions).

Low oblique sit-up exercise to the left/right (10/10 repetitions).

High oblique sit-up exercise to the left/right (10/10 repetitions).

Automobilisation of the thoracic spine in a prone position (10 repetitions on the left, 15 repetitions on the right).

During the five-month period, the student underwent five guided 60-minute therapy sessions focused on the correct execution of exercises, which he then carried out at home as part of the ADL mode. After each therapy session, a video recording was made to serve as a visual reference

for the student during his self-therapy and also to enhance the quality of individual exercises.

Statistical analyses

The data we acquired were processed by means of the clinical case analysis. The effectiveness of the therapy was also assessed by means of two X-ray pictures we used to provide standard evaluation of the spine curvature according to the Cobb angle. Both the first and the control X-ray images had the same parameters: static AP (anteroposterior projection) images of the spine in an upright position. The ScoDiac programme (ATSI/POTSI sub-programme: index evaluating anterior or posterior trunk asymmetry) was used as an auxiliary method for assessment of trunk asymmetry based on the photographs taken of the student.

Results

The results, which were further monitored, are presented based on the parameters that we monitored. These results cannot be generalised and they should be understood in general terms, taking the student's medical history into consideration. We selected the diagnostic data that were relevant for the goal of our study. It is important to view these results in a broader context.

Clinical diagnosis

Anamnestic data

A male born on: 2004.

OA: at birth, the patient underwent a surgery for esophageal atresia and, in 2006, a surgery for esophageal stenosis.

NO: since April 2021, he has been treated for adolescent idiopathic scoliosis (conventional therapy without effect), he feels no pain (only after sitting for 4-5 hours). Otherwise, he feels healthy.

RA: his mother has scoliosis (conventionally treated in adolescence), no other hereditary diseases.

SA: a student in the second year of a vocational high school.

SpA: he has never done any sports competitively or regularly, only seasonal activities (cycling, skiing, swimming), now he walks his dog 1-2 times per week (his orthopaedist prohibited him from doing dynamic and impact sports; he has been excused from physical and sports education classes since April 2021).

Ab: he does not smoke or drink alcohol and he does not use any addictive substances either.

Note: OA – personal medical history, NO – current illnesses, RA – family medical history, SA- social anamnesis, SpA- sports anamnesis, Ab- substance abuse.

Objective examination

The examination (rear view) revealed an apparent asymmetrical thoracic posture (decompensation), with the right shoulder higher than the left one and a pelvic shift to the left. The student was not able to straighten his spine in the sagittal plane (when asked by the physiotherapist to do so. However, he did not do it spontaneously in a free-standing position).

Photographs were taken of the patient's back in order to evaluate the trunk asymmetry index using ScoDiac (ATSI/POTSI) = 36 (figure 1).

Adam's test: positive.

Thomayer's test: - 5 cm.

The functional movement patterns were assessed according to ACD: the patient did not straighten his spine in a four-kneeling position (static/dynamic) but the mobility of his pelvis was not limited. The subject did not straighten his spine when bending lower limbs to the right/left in a four-kneeling position (static/dynamic), limited mobility of the pelvis. During verticalisation from a supine position, he preferred flexion movement strategies (he lifted himself through a sit-up move to a sitting position and then to a free-standing position without straightening his spine at all). X-ray examination: thoracic curvature of 43°, lumbar curvature of 38° (Figure 2).

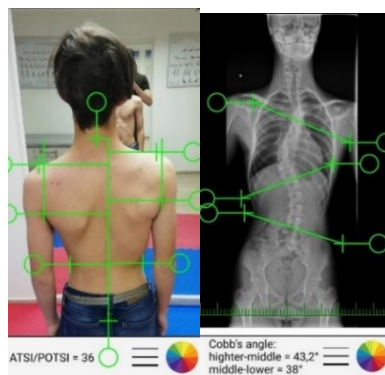


Figure 1 Assessment of the spinal curvature in ScoDiac ATSI/POTSI programme

Figure 2 X-ray image showing the Cobb angle – ScoDiac programme

We used the standard Cobb angle measurement method to assess the student's spinal curvature. For the sake of clarity, we marked the Cobb angle using the ScoDiac programme. The results from the ScoDiac programme were consistent with the radiologist's X-ray images.

After a five-month exercise programme based on the ACT method, there was an improvement in the curvature of both the thoracic and lumbar spine (Figure 3a, b). There was also an improvement in the ATSI/POTSI parameter measured in the ScoDiac programme (Figures 4a, b). Table 1 presents the difference between the input (V) and the control (C) periods.

Table 1. Initial and control results of the student’s curvature assessment

Examination/Assessment	Initial (V)	Control (C)	Difference (r)
X-ray of thoracic curvature	43°	22°	21°
X-ray of lumbar curvature	38°	18°	20°
ATSI/POTSI	36	7	29

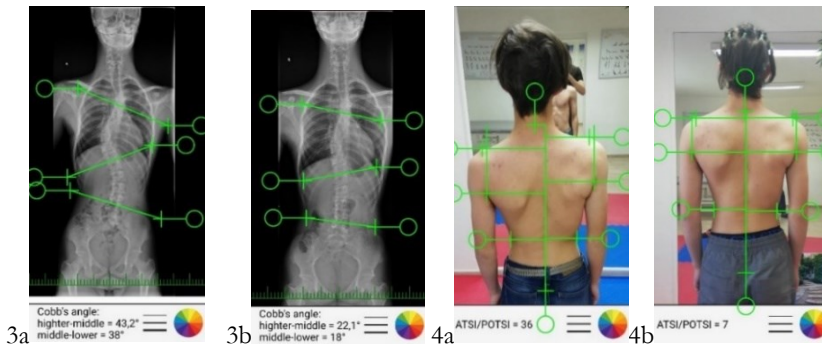


Figure 3a, b Comparison of the initial X-ray image (on the left) and the control X-ray image (on the right)

Figure 4a, b Comparison of initial and control photographs according to the ScoDiac ATSI/POTSI programme

Discussion

In our pilot study, we opted for the Acral Coactivation Therapy (ACT) method as the conventional therapy approach. The tailor-made exercise programmes based on diagnosis and the subsequent therapy doses bring benefits from both aforementioned approaches, namely the correction of the curvature in all three dimensions and the body conditioning training.

This pilot study proves that specific exercises, the ACT method focused on the curve correction in patients diagnosed with AIS, lead to a reduction in the Cobb angle and improve the symmetry of the body posture according to the ATSI/POTSI index. Since this is a clinical case, we cannot claim that the ACT method will work in all patients with AIS. Nevertheless,

it could be included among conventional therapeutic methods used in treatment of decompensated unfixed scoliosis.

Negrini et al. (2015) and Schreiber et al. (2017) agree that rehabilitation exercises focused on the correction of spinal curvature in combination with a trunk orthosis present an effective conventional therapy in patients with AIS and moderate curvature. In our case, the patient was not offered a trunk orthosis even though his curve met the criteria for its application. It is likely that in combination with exercises done according to the ACT method, we could have reached more significant results.

One of the disadvantages of exercises focused on the curve correction (the SEAS method, Schroth exercises, or DoboMed), as viewed by Kuru et al. (2015), is the necessity to visit a physiotherapist several times per week so that the exercises are carried out adequately and have a significant impact on the curve correction. In our case, this disadvantage is eliminated because our patient visited a physiotherapist “only” five times during the monitoring period. Once the patient understands the principles of the ACT method, he can easily perform it at home within his ADL mode, particularly in combination with video recordings that were made after each visit.

One crucial parameter of exercises focused on the curve correction should be suitable dosing of individual exercises. Exercise programmes and procedures used in the AIS therapy use motor learning with the aim to correct the spinal curvature in all three levels by means of physiological activity in individual muscle chains. If there is no improvement in fitness at the same time, patients will not maintain the corrected patterns and the possibility of structural correction of the spinal curvature will be reduced. Then significance of adequate therapy doses was emphasized in the study conducted by Gozde & Yavuz (2019). They compared the effectiveness of specific curve correction exercises with standard CORE training (both groups also wore trunk orthoses). The results showed that if specific curve correction exercises and CORE training are applied with the same intensity, the resulting effects of both treatment methods are similar in patients with moderate AIS.

Doctors often prohibit patients diagnosed with AIS from performing physical activities that are not corrected, for example by a physiotherapist. However, well-intended prohibition of physical activities that could worsen the spinal curvature can also result in reduced fitness, coordination and postural reactivity, which are important for development of the proper body posture. We agree with Jandric (2015), Negrini et al. (2022) and Segreto et al. (2019), who claim that patients with AIS should perform regular physical activities in combination with specific exercise programmes aimed at the correction of the body posture and the spinal

curvature. Only physical activities that demonstrably worsen the curvature in terms of trunk and pelvis decompensation should be prohibited.

What is important and what not to forget. Effective physical activity treatment of the deformity and prevention of its long-term consequences should therefore be started immediately after the disease is recognized (Choudhry et al., 2016).

From our point of view, it is not desirable to generalise sports activities, such as ball games or impact sports, as unsuitable physical activities. The selection of these inadequate physical activities should be individual and based on anamnestic data, clinical symptoms and postural reactivity of patients (Monticone et al., 2014; Lehman et al, 2015; McMaster et al., 2015; Thompson et al., 2019; Bendíková et al., 2020).

Conclusion

We consider the obtained results to be important for clinical and educational practice. Within a short period of time, it was possible to correct the curvature in the thoracic region by 21° and in the lumbar region by 20°. In addition, the exercise programme yielded an improvement in the student's asymmetrical body posture, which we assessed by means of the ScoDiac programme (ATSI/POTSI), from 36 to 7. The results of the clinical study suggest that the properly selected and dosed coactivation exercises and the health-oriented movement programme within the ADL mode improve postural patterns and the overall body posture, which will also reflect in common activities. The improvement in postural parameters (condition, reactivity) led to the correction of the curvature in the observed student diagnosed with decompensated non-fixed scoliosis.

The results suggest that the ACT method could be used as an alternative physiotherapy method for curvature correction in patients diagnosed with AIS, who are exempted from physical and sports education classes. The ACT method is one of the suitable forms of selecting adequate movement patterns based on ACD diagnosis. The results can be used as a guide for setting up a movement plan for students diagnosed with AIS, considering especially the conditioning and correction nature of the therapy supplemented by appropriate physical activities and measures related to a daily routine and a lifestyle.

Acknowledgment

The listed study is the part of research project VEGA 1/0427/22 Prevention of pupils' postural health by physical activity.

Conflicts of interest

The authors declare no conflict of interest.

References

- Addai, D., Zarkos., J. & Bowey, A. J. (2020). Current concepts in the diagnosis and management of adolescent idiopathic scoliosis. *Child's Nervous System*, 36(1), 1111-1119.
- Bendíková, E. (2017). *Theory of health, movement and lifestyle of humanbeings*. Debrecen: University of Debrecen.
- Bendíková, E. (2020). Diversification of the physical and sport education syllabi and its effects on the musculoskeletal system in young female students. *Trends in Sport Science*, 27(3), 149-155. doi: 10.23829/TSS.2020.27.3-5
- Bendíková, E. & Balkó, I. (2022). Acral Coactivation Therapy method in terms of improving the musculoskeletal system in pupils in physical and sport education. *Trends in Sport Sciences*, 29(3), 107-114.
- Bendíková, E., Novotná, B., Rozim, R., Tomková, Š., Fyodorov, A. & Palaščáková Špringrová, I. (2020). Analysis of physical activity status and functional posture in Slovakia's young school-aged children with different body weight. *Zdravotnícke listy*, 8(2), 71-81.
- Choudhry, M. N., Ahmad, Z. & Verma, R. (2016). Adolescent idiopathic scoliosis. *Open Orthop. J.*, 10, 143-154.
- individuals. *Journal of Physical Education and Sport*, 16(2), 1084-1088. doi:[10.7752/jpes.2016.s2173](https://doi.org/10.7752/jpes.2016.s2173)
- Gaetamo, A. (2016). Relationship between physical inactivity and effects on individual health status. *Journal of Physical Education and Sport*, 16(S2), 1069-1074.
- Gozde, Y. & Yavuz, Y. (2019). Core stabilization exercises versus scoliosis-specific exercises in moderate idiopathic scoliosis treatment. *Prosthetics and Orthotics International*, 43(3), 301-308.
- Jandric, S. D. (2015). Scoliosis and sport. *Sportlogia*, 11(1), 1-10.
- Kuru, T. Yeldan, I., Dereli, E. E. et al. (2015). The efficacy of three-dimensional Schroth exercises in adolescent idiopathic scoliosis: a randomised controlled clinical trial. *Clinical Rehabilitation*. 30(2), 181-190.
- Kuznia, A. L., Hernandez, A. K. & Lee, L. U. (2020). Adolescent idiopathic scoliosis: common questions and answers. *American Family Physician*, 101(1), 19-23.
- Lehman, R. A., Kang. D. G., Lenke, D. L. et al. (2015). Return to sports after surgery to correct adolescent idiopathic scoliosis: a survey of the spinal deformity study group. *The Spine Journal*, 15(5), 951-958.

- Lenková, R. (2021). Health benefits of balance exercises in sport. *Sport mont*, 19(S2), 201-206.
- McMaster, M. E., Lee, A. J., & Burwell, R. G. (2015). Physical activities of patients with adolescent idiopathic scoliosis (AIS): preliminary longitudinal case-control study historical evaluation of possible risk factors. *Scoliosis and Spinal Disorders*, 10(6), doi: 10.1186/s13013-015-0029-8. eCollection 2015.
- Monticone, M., Ambrosini, E., Cazaniga, D., Rocca, B. & Ferrante, S. (2014). Active self-correction and task-oriented exercises reduce spinal deformity and improve quality of life in subjects with mild adolescent idiopathic scoliosis. Results of a randomized controlled trial. *Eur Spine J.*, 23(6), 1204-1214.
- Negrini A., Negrini, M. G., Donzelli, S. et al. (2015). Scoliosis-specific exercises can reduce the progression of severe curves in adult idiopathic scoliosis: a long-term cohort study. *Scoliosis and Spinal Disorders*, 10(1), 20.
- Negrini, A., Poggio M., Donzelli, S. et al. (2022). Sport improved medium-term results in a prospective cohort of 785 adolescents with idiopathic scoliosis braced full time. SOSORT 2018 Award Winner. *European Spine Journal*, 31(11), 2994-2999.
- Nemček, D. (2016). Life satisfaction of people with disabilities: a comparison between active and sedentary
- Nemček, D. & Ladecká, P. (2020). The level of subjective well-being of high school students with musculoskeletal disorders. *Zdravotnícke listy*, 8(2), 16-21.
- Palašćáková Špringrová, I. (2011). *The acral coactivation therapy* (ACT®). Čelákovice: Rehaspring.
- Palašćáková Špringrová, I. (2016). *Straight back in athletes with acral dynamic-support exercises*. Čelákovice: ACT centrum s.r.o.
- Segreto, F. A., Messina, J. C., Doran, J. P. et al. (2019). Noncontact sports participation in adolescent idiopathic scoliosis: effects on parent-reported and patient-reported outcomes. *Journal of Pediatric Orthopaedics B*, 24(4), 356-361.
- Schreiber, S., Parent, E. C., Hill, D. L. et al. (2017). Schroth physiotherapeutic scoliosis-specific exercises for adolescent idiopathic scoliosis: how many patients require treatment to prevent one deterioration? – results from a randomized controlled trial (SOSORT 2017 Award Winner). *Scoliosis and Spinal Disorders*, 12(26), 1-8.
- Thompson, J. Y., Williamson, E. M. & Williams, M. A. et al. (2019). Effectiveness of scoliosis-specific exercises for adolescent idiopathic scoliosis compared with other non-surgical interventions: a systematic review and meta-analysis. *Physiotherapy*, 105(2), 214-234.