



## LJMU Research Online

**Kerstens, TP, van Everdingen, WM, Udink ten Cate, FEA and Thijssen, DHJ**

**Left ventricular strain-volume loops and myocardial fibrosis in pediatric patients with Duchenne muscular dystrophy**

<http://researchonline.ljmu.ac.uk/id/eprint/23004/>

### Article

**Citation** (please note it is advisable to refer to the publisher's version if you intend to cite from this work)

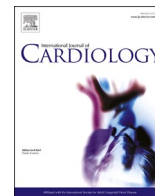
**Kerstens, TP, van Everdingen, WM, Udink ten Cate, FEA and Thijssen, DHJ (2023) Left ventricular strain-volume loops and myocardial fibrosis in pediatric patients with Duchenne muscular dystrophy. International Journal of Cardiology. 395. pp. 1-5. ISSN 0167-5273**

LJMU has developed **LJMU Research Online** for users to access the research output of the University more effectively. Copyright © and Moral Rights for the papers on this site are retained by the individual authors and/or other copyright owners. Users may download and/or print one copy of any article(s) in LJMU Research Online to facilitate their private study or for non-commercial research. You may not engage in further distribution of the material or use it for any profit-making activities or any commercial gain.

The version presented here may differ from the published version or from the version of the record. Please see the repository URL above for details on accessing the published version and note that access may require a subscription.

For more information please contact [researchonline@ljmu.ac.uk](mailto:researchonline@ljmu.ac.uk)

<http://researchonline.ljmu.ac.uk/>



Short communication

## Left ventricular strain-volume loops and myocardial fibrosis in pediatric patients with Duchenne muscular dystrophy

Thijs P. Kerstens<sup>a,1</sup>, Wouter M. van Everdingen<sup>b,c,1</sup>, Floris E.A. Udink ten Cate<sup>d,1</sup>,  
Dick H.J. Thijssen<sup>a,e,1,\*</sup>

<sup>a</sup> Department of Medical BioSciences, Radboud University Medical Center, Geert Grooteplein Zuid 10, 6525 GA Nijmegen, the Netherlands

<sup>b</sup> Department of Radiology, Nuclear Medicine and Anatomy, Radboud University Medical Center, Geert Grooteplein Zuid 10, 6525 GA Nijmegen, the Netherlands

<sup>c</sup> Department of Radiology and Nuclear Medicine, Rijnstate Hospital, Wagnerlaan 55, 6815 AD Arnhem, the Netherlands

<sup>d</sup> Academic Center for Congenital Heart Disease (ACAHA), Department of Pediatric Cardiology, Amalia Children's Hospital, Radboud University Medical Center, Geert Grooteplein Zuid 10, 6525 GA Nijmegen, the Netherlands

<sup>e</sup> Research Institute for Sport and Exercise Sciences, Liverpool John Moores University, Liverpool L3 5UX, United Kingdom



### ARTICLE INFO

#### Keywords:

Duchenne muscular dystrophy  
Strain – volume loop  
CMR  
Myocardial fibrosis

### ABSTRACT

**Background:** The left ventricular strain–volume loop (SVL) combines changes in global longitudinal strain (GLS) and LV volume across a cardiac cycle, providing insight into cardiac dynamics. This study explored the association between left ventricular SVL and presence of fibrosis, assessed with late gadolinium enhancement, in patients with Duchenne muscular dystrophy (DMD).

**Methods and results:** 34 pediatric patients with DMD were included. Feature tracking analysis was used to assess endocardial GLS and volumetric measurements to construct the SVL. Mean age at the time of assessment was  $14 \pm 3$  and  $11 \pm 2$  years old ( $p < 0.01$ ) in the group with ( $n = 18$ ) versus without fibrosis ( $n = 16$ ), respectively. Left ventricular ejection fraction was not significantly different between groups (fibrosis:  $56.4 \pm 3.8\%$  versus without fibrosis:  $54.0 \pm 6.3\%$ ,  $p = 0.18$ ). After adjusting for age, the late diastolic slope of the SVL was significantly associated with presence of fibrosis (OR 0.39 [95% CI 0.18–0.85]; area under the receiver operating characteristic curve: 0.83 [95% CI 0.70–0.97]). No significant association was observed for peak strain and fibrosis (OR 1.15 [95% CI 0.86–1.546]).

**Conclusion:** A lower late diastolic slope of the left ventricular SVL, related to the interplay between longitudinal deformation and volume changes late in diastole, is associated with presence of myocardial fibrosis in pediatric patients with DMD.

## 1. Introduction

Duchenne muscular dystrophy (DMD) is an X-linked recessive disorder affecting up to 1:5000 live male births [1]. Patients present with progressive muscle weakness leading to loss of ambulation around the age of 12 years. Additional cardiac complications occur, such as heart failure, and eventually death, the latter mostly occurring in the second or third decade of life [2–4]. Cardiac dysfunction and fibrosis occur due to progressive cardiomyocyte damage [2], leading to primary dilated cardiomyopathy that will be present in 90% of DMD patients around the age of 18 years [2,5]. Periodic imaging is necessary to evaluate cardiac function for the early detection of abnormalities, allowing timely

treatment, currently mainly aimed to delay the progression of cardiac dysfunction [6].

Currently, cardiovascular magnetic resonance (CMR) with late gadolinium enhancement (LGE) is used to assess cardiac function and fibrosis, requiring intravenous access and additional scanning duration. Interestingly, less invasive alternatives, such as global systolic peak strain, may also detect systolic dysfunction in patients with fibrosis, before any changes occur in left ventricular ejection fraction (LVEF) [7]. Since fibrosis is likely to alter diastolic function [8], an integrated evaluation of both systolic and diastolic function may be valuable in early detection of cardiac dysfunction. Recent work showed that combining strain and volume in the strain-volume loop (SVL) may

\* Corresponding author at: Department of Medical BioSciences (928), Radboud University Medical Center, P.O. Box 9101, 6500 HB Nijmegen, the Netherlands.  
E-mail address: [Dick.Thijssen@radboudumc.nl](mailto:Dick.Thijssen@radboudumc.nl) (D.H.J. Thijssen).

<sup>1</sup> This author takes responsibility for all aspects of the reliability and freedom from bias of the data presented and their discussed interpretation.

provide additional information to traditional measures of cardiac function (e.g. LVEF, peak strain) to discriminate between pathologies, detect cardiac remodeling, and is associated with long-term survival [9–12]. Therefore, the aim of this study was to explore the association and discriminative value of LV-SVL characteristics in DMD with the presence of fibrosis. We hypothesized that lower slopes and higher uncoupling of the LV-SVL, are associated with LV fibrosis, reflecting altered cardiac mechanics.

## 2. Methods

### 2.1. Study design and population

DMD patients aged  $\leq 18$  years with CMR imaging with LGE series between June 2017 and November 2021 were included at the Radboud University Medical Center, Nijmegen, The Netherlands as described in detail elsewhere [13]. Exclusion criteria were structural congenital heart defects and low quality CMR exams. The study was approved by the local institutional review board and was performed according to the local code of research conduct and data protection rules.

### 2.2. CMR acquisition

CMR imaging was part of usual care and performed on a Siemens Avanto 1.5 T scanner system (Siemens, Erlangen, Germany) according to a standardized protocol without sedation. Images were electrocardiogram-triggered and acquired during breath-hold. Biventricular dimensions and function were assessed from short-axis views. Left atrial volume was calculated using the biplane area-length method. Volumetric data were indexed to body surface area (BSA, Dubois & Dubois). The contrast agent ‘Dotarem’ (Guerbet, France) was administered (0.3 mL/kg) intravenously. LGE series were acquired approximately 15–30 min thereafter. LGE was assessed by a cardiovascular radiologist (W.E.) as previously described [13].

### 2.3. Strain-volume loop

Offline CMR-FT analyses were performed using QStrain (Medis Medical Imaging, Leiden, The Netherlands) assessing endocardial GLS and volume per frame, derived from two-, three-, and four-chamber

views. All analyses were performed by one researcher (T.K.) and supervised by a cardiovascular radiologist (W.E.). SVL was constructed using in-house developed software (MATLAB, The MathWorks Inc., version 2019a, Massachusetts, USA) as described elsewhere (Fig. 2) [14]. The SVL was assessed using systolic and diastolic characteristics as described in Fig. 1, i.e., early systolic slope (ES slope), systolic slope (S Slope), end-systolic longitudinal strain (Peak strain), early diastolic slope (ED slope), late diastolic slope (LD slope), and average difference of longitudinal strain (uncoupling) in systole compared to diastole (i.e. average of systolic – diastolic strain).

### 2.4. Statistical analysis

Statistical analyses were performed using R version 4.0.4 [15]. Normality was checked using histograms and Shapiro-Wilk test. Continuous variables were reported as mean  $\pm$  standard deviation (SD) or median [interquartile range] and categorical variables as number and proportion (n(%)). Characteristics were compared using a *t*-test or non-parametric equivalent. Proportions were tested using chi-squared tests or Fisher’s exact tests. Intra-observer variability was assessed using an intraclass correlation coefficient (ICC) using a two-way mixed model for absolute agreement. Logistic regression was used to assess the association of SVL characteristics and presence of fibrosis. Variables were selected based on univariable logistic regression ( $P < 0.1$ ) and adjusted for age in multivariable analysis. Assumptions were checked using Box-Tidwell tests and variance inflation factors (multicollinearity). To explore the discriminative value, Receiver Operating Characteristic (ROC) curves were used to assess the performance of SVL characteristics in a multivariable model. Optimal cut-off was determined using the Youden-index.  $P < 0.05$  was considered significant.

## 3. Results

Thirty-four patients were included for final analysis. Based on LGE images, 18 (52%) patients had fibrosis and 16 (48%) showed no fibrosis. Mean age at the time of CMR was  $14.1 \pm 2.7$  and  $11.9 \pm 2.0$  years ( $p = 0.009$ ) in the group with versus without fibrosis, respectively. Z-scores for height and weight were not significantly different between groups. No difference between groups in LVEF and left atrial volume was observed (Table 1).

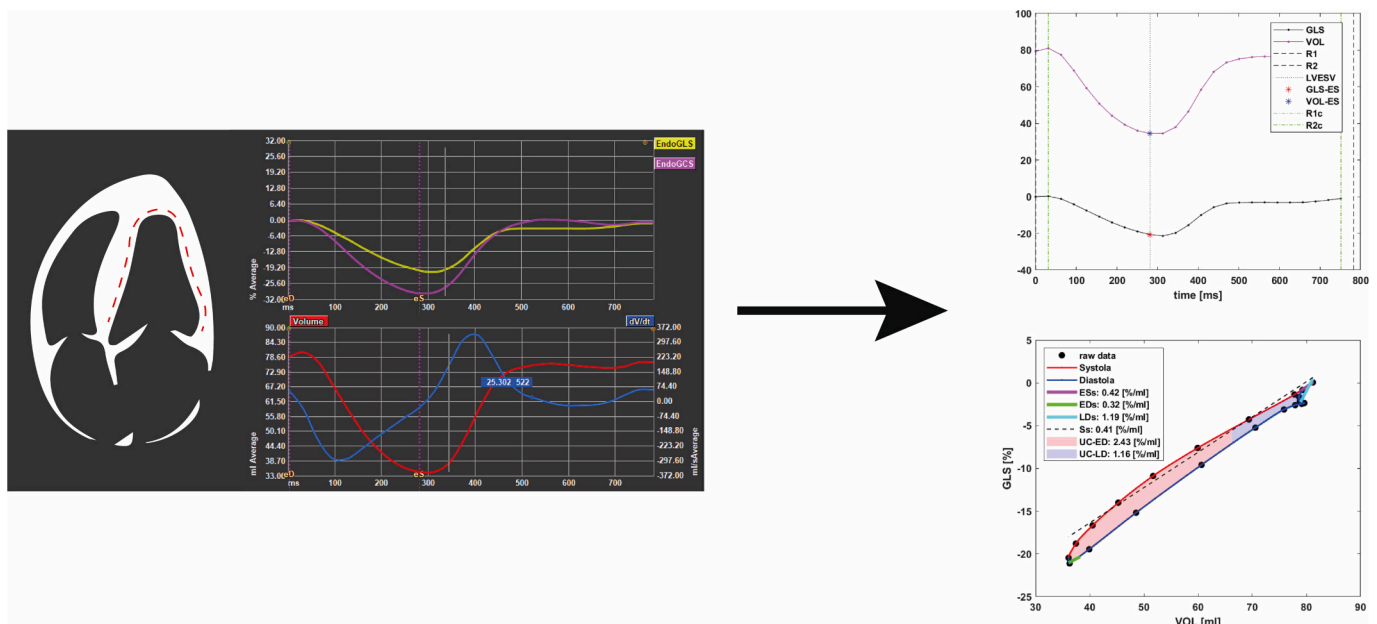


Fig. 2. Representation of the acquisition of strain and volumetric data and the resulting strain-volume loop based on this data.



**Table 1**  
Characteristics of the study population.

	Overall (N = 34)	No Fibrosis (N = 16)	Fibrosis (N = 18)	P-value
Age, years	13.1 ± 2.6	11.9 ± 2.0	14.1 ± 2.7	0.009
Weight, kg	52 [42–76]	45 [39–58]	62 [50–82]	0.067
Weight, z-score	0.88 ± 1.27	0.73 ± 1.29	1.01 ± 1.27	0.530
Height, cm	150 [138–166]	143 ± 15	158 ± 16	0.008
Height, z-score	−0.63 ± 1.41	−0.87 ± 1.39	−0.41 ± 1.43	0.340
BMI, z score	1.21 ± 1.17	1.27 ± 1.02	1.17 ± 1.32	0.810
Heart rate, bpm	98 ± 16	101 ± 18	95 ± 15	0.357
SBP, mmHg	108 ± 13	106 ± 14	109 ± 11	0.468
Missing, n (%)	1 (2.9%)	0 (0%)	1 (5.6%)	
DBP, mmHg	63 ± 8	63 ± 10	63 ± 7	0.916
Missing, n (%)	1 (2.9%)	0 (0%)	1 (5.6%)	
Duration glucocorticoids treatment, years	6.5 ± 3.6	5.1 ± 2.7	7.8 ± 3.9	0.027
Missing, n (%)	1 (2.9%)	0 (0%)	1 (5.6%)	
ACE-inhibitor, n(%)	6 (17.6%)	3 (18.8%)	3 (16.7%)	1.000
<b>CMR measurements</b>				
LAVI, ml/m <sup>2</sup>	33.4 ± 11.3	32.8 ± 10.5	33.8 ± 12.2	0.805
Left atrial peak strain, %	36.7 ± 8.8	36.4 ± 6.5	37.1 ± 10.6	0.814
LVEDV indexed, ml/m <sup>2</sup>	66.8 ± 11.3	64.4 ± 10.1	68.9 ± 12.2	0.253
LVESV indexed, ml/m <sup>2</sup>	55.1 ± 5.3	28.3 ± 6.1	31.7 ± 6.9	0.144
LVEF, %	55.1 ± 5.3	56.4 ± 3.8	54.0 ± 6.3	0.181
IVSd, mm	6.0 ± 1.3	5.8 ± 1.0	6.2 ± 1.5	0.290
PWd, mm	5.0 [5.0–6.0]	5.0 [5.0–5.3]	6.0 [5.0–6.0]	0.070
LV diastolic longitudinal strain rate, s <sup>−1</sup>	1.6 ± 0.4	1.7 ± 0.4	1.5 ± 0.3	0.140
RVEDV indexed, ml/m <sup>2</sup>	58.4 ± 10.0	58.5 ± 10.0	58.4 ± 10.3	0.969
RSESV indexed, ml/m <sup>2</sup>	24.5 ± 5.9	24.3 ± 6.6	24.7 ± 5.3	0.822
RVEF, %	58.1 ± 6.8	58.9 ± 6.4	57.3 ± 7.2	0.499

Data reported as mean ± SD, median [interquartile range], or n (%). BMI, body mass index; SBP, systolic blood pressure; DBP, diastolic blood pressure; ACE, angiotensin-converting enzyme; CMR, cardiovascular magnetic resonance; LAVI, left atrial volume index; LVEDV, left ventricular end diastolic volume; LVESV, left ventricular end systolic volume; LVEF, left ventricular ejection fraction; IVSd, interventricular septum thickness; PWd, posterior wall thickness; RVEDV, right ventricular end diastolic volume; RVESV, right ventricular end systolic volume; RVEF, right ventricular ejection fraction. Z-scores calculated using reference data from Centers for Disease Control and Prevention.

**Table 2**

Odds ratios and 95% confidence intervals for the logistic regression assessing the association SVL characteristics and presence of fibrosis.

	Univariable Analysis		Multivariable Analysis	
	OR (95% CI)	P-value	OR (95% CI)	P-value
ES slope*	0.96 (0.69–1.34)	0.708		
S slope*	0.32 (0.12–0.84)	0.020	0.46 (0.15–1.37)	0.161
Peak strain	1.15 (0.86–1.56)	0.344		
ED slope*	0.81 (0.63–1.04)	0.105		
LD slope*	0.35 (0.17–0.73)	0.005	0.39 (0.18–0.85)	0.018
Uncoupling	0.88 (0.49–1.56)	0.657		
Uncoupling ED	1.00 (0.61–1.62)	0.986		
Uncoupling LD	0.62 (0.32–1.22)	0.165		

Odds ratios were adjusted for age when p < 0.1 in univariable analysis. All ORs are per unit increase for the corresponding variable, except for those marked with \*, per 0.1 unit increase. ES, early systolic; S, systolic; ED, early diastolic; LD, late diastolic.

observations suggest that measures of systolic function seem comparable, even in the presence of myocardial fibrosis. Our findings regarding diastolic characteristics may relate to changes in diastolic function.

Diastolic function assessment is commonly divided into early diastolic relaxation and late diastolic myocardial stiffness [18]. The lower LD-slope in those with fibrosis, suggests that less longitudinal deformation is observed relative to the final 5% of LV filling. Less longitudinal deformation, despite ventricular filling, may be related to alterations in myocardial stiffness. However, this remains speculative since no indices of myocardial stiffness were available [19].

**Limitations.** The small cohort size possibly affected the ability to detect the association between other SVL characteristics and fibrosis. Due to the small cohort limited number of confounders could be considered in multivariable analysis and our cohort could not be split for validation of the discriminative capacity. This is therefore likely an overestimation. Finally, since LGE might not detect diffuse fibrosis and tissue characterization (e.g., T1/T2-mapping) was not performed [20], structural and possibly functional alterations might already be present in our fibrosis group and not truly represent a group without structural alterations.

## Conclusion

This study observed an association of the late diastolic slope of the strain-volume loop and LV myocardial fibrosis in pediatric patients with Duchenne muscular dystrophy, whilst no other analyzed indices of diastolic function were different between groups. Diastolic characteristics of the SVL might be a marker for fibrosis with possibly high specificity. Our exploratory analysis supports performance of larger prospective studies to further investigate this observation and compare findings with conventional parameters.

## Author contributions

All authors were involved in the conception, design, analysis, and interpretation of the results. TK, WE, and DT drafted the manuscript. All authors reviewed the results, revised it, approved the final version, and agree to be accountable for all aspects of the work.

## Declaration of Competing Interest

None to declare.

## Acknowledgements

TK was supported by a personally obtained grant from the Radboudumc.

## References

- [1] D.J. Birnkrant, K. Bushby, C.M. Bann, S.D. Apkon, A. Blackwell, D. Brumbaugh, et al., Diagnosis and management of Duchenne muscular dystrophy, part 1: diagnosis, and neuromuscular, rehabilitation, endocrine, and gastrointestinal and nutritional management, *Lancet Neurol.* 17 (3) (2018) 251–267.
- [2] F. Kamdar, D.J. Garry, Dystrophin-deficient cardiomyopathy, *J. Am. Coll. Cardiol.* 67 (21) (2016) 2533–2546.
- [3] A.E. Emery, The muscular dystrophies, *Lancet* 359 (9307) (2002) 687–695.
- [4] M. Eagle, S.V. Baudouin, C. Chandler, D.R. Giddings, R. Bullock, K. Bushby, Survival in Duchenne muscular dystrophy: improvements in life expectancy since 1967 and the impact of home nocturnal ventilation, *Neuromuscul. Disord.* 12 (10) (2002) 926–929.
- [5] G. Nigro, L.I. Comi, L. Politano, R.J. Bain, The incidence and evolution of cardiomyopathy in Duchenne muscular dystrophy, *Int. J. Cardiol.* 26 (3) (1990) 271–277.
- [6] D.J. Birnkrant, K. Bushby, C.M. Bann, B.A. Alman, S.D. Apkon, A. Blackwell, et al., Diagnosis and management of Duchenne muscular dystrophy, part 2: respiratory, cardiac, bone health, and orthopaedic management, *Lancet Neurol.* 17 (4) (2018) 347–361.
- [7] M. Shehta, M.M. Rayan, N.A. Fahmy, A. Onsy, I. Bastawy, Global longitudinal strain detects subtle left ventricular systolic dysfunction in Duchenne muscular dystrophy patients and carriers, *Egypt Heart J.* 73 (1) (2021) 91.
- [8] B.S. Burlew, K.T. Weber, Cardiac fibrosis as a cause of diastolic dysfunction, *Herz.* 27 (2) (2002) 92–98.
- [9] H.G. Hulshof, F. van Oorschot, A.P. van Dijk, M.T.E. Hopman, K.P. George, D. L. Oxborough, et al., Changes in dynamic left ventricular function, assessed by the

- strain-volume loop, relate to reverse remodeling after aortic valve replacement, *J. Appl. Physiol.* (1985) 127 (2) (2019) 415–422.
- [10] H.G. Hulshof, A.P. van Dijk, M.T.E. Hopman, H. Heesakkers, K.P. George, D. L. Oxborough, et al., 5-year prognostic value of the right ventricular strain-area loop in patients with pulmonary hypertension, *Eur. Heart J. Cardiovasc. Imaging* 22 (2) (2021) 188–195.
- [11] E. Pagourelis, A. Antoniadis, A. Boulmpou, A. Tsarouchas, D. Mouselimis, C. Bakogiannis, et al., Three-dimensional volume-strain loops may reflect fibrosis in hypertrophic cardiomyopathy, *Eur. Heart J.* 41 (Supplement\_2) (2020).
- [12] T.P. Kerstens, J. Weerts, A.P.J. van Dijk, G. Weijers, C. Knackstedt, T.M. H. Eijvogels, et al., Association of left ventricular strain-volume loop characteristics with adverse events in patients with heart failure with preserved ejection fraction, *Eur Heart J Cardiovasc Imaging.* 24 (9) (2023) 1168–1176.
- [13] T.P. Kerstens, W.M. van Everdingen, J. Habets, A.P.J. van Dijk, W.A. Helbing, D.H. J. Thijssen, et al., Left ventricular deformation and myocardial fibrosis in pediatric patients with Duchenne muscular dystrophy, *Int. J. Cardiol.* 131162 (2023).
- [14] T.P. Kerstens, J. Weerts, A.P.J. van Dijk, G. Weijers, C. Knackstedt, T.M. H. Eijvogels, et al., Left ventricular strain-volume loops and diastolic dysfunction in suspected heart failure with preserved ejection fraction, *Int. J. Cardiol.* 378 (2023) 144–150.
- [15] R Development Core Team, R: A Language and Environment for Statistical Computing, R Foundation for Statistical Computing, Vienna, Austria, 2021.
- [16] H.G. Hulshof, A.P. van Dijk, K.P. George, M.T.E. Hopman, D.H.J. Thijssen, D. L. Oxborough, Exploratory assessment of left ventricular strain-volume loops in severe aortic valve diseases, *J. Physiol.* 595 (12) (2017) 3961–3971.
- [17] T.R. Eijgenraam, H.H.W. Silljé, R.A. de Boer, Current understanding of fibrosis in genetic cardiomyopathies, *Trends Cardiovasc. Med.* 30 (6) (2020) 353–361.
- [18] S.F. Nagueh, Left Ventricular Diastolic Function, *JACC Cardiovasc. Imaging* 13 (1\_Part 2) (2020) 228–244.
- [19] J.C. Villalobos Lizardi, J. Baranger, M.B. Nguyen, A. Asnacios, A. Malik, J. Lumens, et al., A guide for assessment of myocardial stiffness in health and disease, *Nature Cardiovascular Research.* 1 (1) (2022) 8–22.
- [20] P. Haaf, P. Garg, D.R. Messroghli, D.A. Broadbent, J.P. Greenwood, S. Plein, Cardiac T1 mapping and extracellular volume (ECV) in clinical practice: a comprehensive review, *J. Cardiovasc. Magn. Reson.* 18 (1) (2016) 89.