

REFERENCES

- García E, Albarrán A, Heredia-Mantrana J, Guerrero-Pinedo F, Rodríguez J, Hernández-Antolín R, et al. Implantación transfemoral de prótesis valvular aórtica en pacientes portadores de prótesis mitral mecánica. *Rev Esp Cardiol*. 2011;64:1052-5.
- Bruschi G, De Marco F, Oreglia J, Colombo P, Fratto P, Lullo F, et al. Percutaneous implantation of CoreValve aortic prostheses in patients with a mechanical mitral valve. *Ann Thorac Surg*. 2009;88:e50-2.
- Drewe T, Pasic M, Buz S, Unbehaun A, Dreyse S, Kukucka M, et al. Transapical aortic valve implantation after previous mitral valve surgery. *J Thorac Cardiovasc Surg*. 2011;142:84-8.
- Soon JL, Ye J, Lichtenstein SV, Wood D, Webb JG, Cheung A. Transapical transcatheter aortic valve implantation in the presence of a mitral prosthesis. *J Am Coll Cardiol*. 2011;58:715-21.
- Avanzas P, Muñoz-García AJ, Segura J, Pan M, Alonso-Brales JH, Lozano I, et al. Implante percutáneo de la prótesis valvular aórtica autoexpandible CoreValve® en pacientes con estenosis aórtica severa: experiencia inicial en España. *Rev Esp Cardiol*. 2010;63:141-8.

doi:10.1016/j.rec.2011.12.019

Inappropriate Left Ventricular Mass in a Young Population

Masa ventricular izquierda inapropiada en una población de adultos jóvenes

To the Editor,

The concept of inappropriate left ventricular mass (iLVM)¹ was introduced to distinguish between compensatory increases in LVM and clinically relevant, maladaptive changes.² iLVM is that which exceeds the expected value for a given individual based on sex, body size, and stroke work, and it is associated with an increased cardiovascular risk.^{3,4}

We determined the prevalence of iLVM and assessed its relationship with left ventricular function (LVF) in 411 students (265 women; mean [SD] age, 20.62 [0.07] years) from the *Facultad de Ciencias Médicas* at the *Universidad Nacional de La Plata* in Argentina. A sample size of 174 individuals was calculated as sufficient to detect a prevalence of 6% with a 95% confidence level and a precision of 3%; group sizes of 25 to 50 were calculated as sufficient to detect minimal differences in parameters associated with LVF with an α risk of 0.05 and a β risk of 0.20. We analyzed family history of cardiovascular risk factors (RF), weight, height, waist and hip circumference, and blood pressure in all participants. Doppler flow and tissue Doppler echocardiography were used to characterize left ventricular structure and LVF. LVM was calculated according to Devereux et al.⁵ and the LVM index (LVMI) was calculated by dividing the LVM by the individual's height in meters to the power 2.7; LVMI >47 g/m^{2.7} in women and >50 g/m^{2.7} in men is indicative of left ventricular hypertrophy. iLVM was calculated according to De Simone²; our cutoff was set at the 95th percentile (117%) according to the mass expected for the population with weight and blood pressure in the normal range. Systolic function was assessed by determination of the

mean velocity of fiber shortening corrected for stress at peak systole (Vcf) and the peak systolic mitral annular velocity (S'); diastolic function was determined from the ratio of peak early mitral inflow velocity (E) and peak early mitral annular velocity (e') (E/e'). Continuous variables were expressed as means (SD) and categorical variables as percentages. Differences between continuous variables were analyzed by *t* test and the χ^2 test was used to compare categorical variables. Analysis of covariance was used to adjust the values of iLVM for body surface area, ratio of waist to hip circumference, and systolic blood pressure, and univariate analysis was used to assess the correlation between stroke work ratio and LVM. Data were analyzed using SPSS version 15.0. In all cases a cutoff of $P < .05$ was used to determine statistical significance.

The prevalence of iLVM in our students was 6% (95% confidence interval, 3.7%-8.2%). There were no significant differences in age, weight, height, sex, blood pressure, or family history of cardiovascular RF in those with appropriate (aLVM) and iLVM. Adjustment for covariables in students with iLVM (Fig. 1) did not alter the excess LVM of 36.7 (2.15) g observed in that group. The LVM at a given stroke work was greater in students with iLVM (Fig. 2; $P < .01$). The LVMI (29.09 [0.30] g/m^{2.7} in students with aLVM; 40.39 [1.91] g/m^{2.7} in students with iLVM; $P < .01$), prevalence of LVH (0.5% in students with aLVM; 8% in students with iLVM; $P < .01$), wall thickness (8.50 [0.05] mm in students with aLVM; 10.13 [0.23] mm in students with iLVM; $P < .01$), and relative wall thickness (0.37 [0.002] in students with aLVM; 0.44 [0.01] in students with iLVM; $P < .01$) were all greater in students with iLVM. There was also a reduction in S' (24.69 [0.41] cm/s in students with aLVM; 21.15 [1.65] cm/s in students with iLVM; $P < .03$) and Vcf (101.59% [0.9%] in students with aLVM; 91.94% [4.71%] in students with iLVM; $P < .01$), as well as an increase in E/e' (2.76 [0.05] in students with aLVM; 3.27 [0.30] in students with iLVM; $P < .01$) compared with students who had an aLVM.

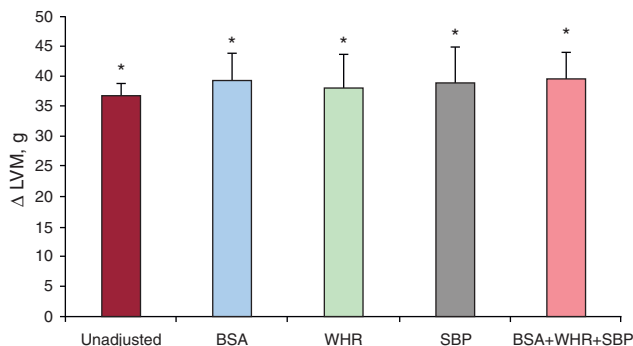


Figure 1. Differences in left ventricular mass in young adults with appropriate and inappropriate left ventricular mass with and without adjustment. BSA, body surface area; LVM, left ventricular mass; SBP, systolic blood pressure; WHR, waist-to-hip ratio. * $P < .05$.

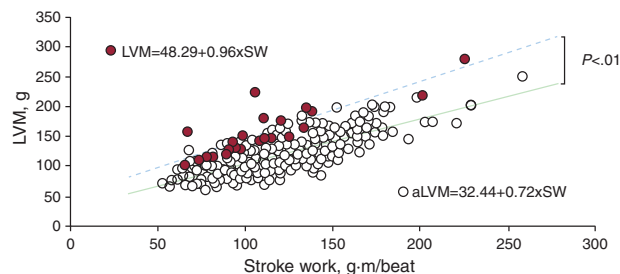


Figure 2. Relationship between stroke work (horizontal axis) and left ventricular mass. Filled circles correspond to young adults with inappropriate left ventricular mass. aLVM, appropriate left ventricular mass; LVM, left ventricular mass; SW, stroke work.

The main findings of this study indicate that 6% of students with no apparent cardiovascular disease had iLVM with shortening of the circumferential and longitudinal fibers as an expression of the deterioration in systolic function, and an increase in left ventricular diastolic pressure as an expression of diastolic dysfunction. These findings were independent of family history of cardiovascular RF, blood pressure, or anthropometric variables. The persistence of increased LVM in the group with iLVM when adjustments were made for different covariables indicates an inadequate response. The reduction in S' and Vcf in young people with iLVM is an important indication of a general abnormality of the myocardial fibers and is associated with lower afterload following similar preload when compared with the group with aLVM. This finding is indicative of inotropism. Although the absolute values of E/e' in our study are within the normal range, the increase observed in individuals with iLVM would suggest a slight increase in ventricular filling pressure as an expression of early changes in diastolic function. Although the cross-sectional nature of the study makes it impossible to determine the risk of cardiovascular events in the population studied, the emerging phenotype of the individuals with iLVM is similar to that previously shown in adults, where it was associated with increased risk.^{3,4} These findings support the concept of an inadequate response in the development of iLVM, described here for the first time in young adults. Longitudinal studies are now required to assess the prognostic impact of this subclinical marker of compromised cardiac function in similar populations.

Eduardo M. Escudero,* Oscar A. Pinilla, and Irene L. Ennis

Centro de Investigaciones Cardiovasculares, Facultad de Ciencias Médicas, Universidad Nacional de La Plata, La Plata, Buenos Aires, Argentina

*Corresponding author:

E-mail address: emescu@gmail.com (E.M. Escudero).

Available online 23 May 2012

REFERENCES

1. De Simone G, Pasanisi F, Contaldo F. Link of nonhemodynamic factors to hemodynamic determinants of left ventricular hypertrophy. *Hypertension*. 2001;38:13-8.
2. Koren MJ, Devereux RB, Casale PN, Savage DD, Laragh JH. Relation of left ventricular mass and geometry to morbidity and mortality in uncomplicated essential hypertension. *Ann Intern Med*. 1991;114:345-52.
3. Muiesan ML, Salvetti M, Painsi A, Monteduro C, Galbassini G, Bonzi B, et al. Inappropriate left ventricular mass changes during treatment adversely affects cardiovascular prognosis in hypertensive patients. *Hypertension*. 2007;49:1077-83.
4. Celentano A, Palmieri V, Esposito ND, Pietropaolo I, Crivaro M, Mureddu GF, et al. Inappropriate left ventricular mass in normotensive and hypertensive patients. *Am J Cardiol*. 2001;87:361-3.
5. Devereux RB, Alonso DR, Lutas EM, Gottlieb GJ, Campo E, Sachs I, et al. Echocardiographic assessment of left ventricular hypertrophy: comparison to necropsy findings. *Am J Cardiol*. 1986;57:450-8.

doi:10.1016/j.rec.2012.01.014

Brugada Electrocardiogram Pattern Induced by Cannabis

Patrón electrocardiográfico de Brugada inducido por cannabis

To the Editor,

We describe a 42-year-old man with repeated use of cannabis as the only history of interest. He had come to the emergency room twice in 3 months for palpitations immediately after using moderate doses of the drug. An electrocardiogram (ECG) was performed at both visits. On the first occasion, no abnormalities were described; however, on the second, the ECG showed type I Brugada ECG pattern (BEP) (Figs. 1 and 2) and frequent premature ventricular beats (right ventricular outflow tract morphology). The presence of fever or other situations or substances that could induce BEP was excluded. The patient was advised to cease using the drug and was referred to our clinic. The patient, remaining abstinent, presented a normal ECG in the clinic. When the V₁ and V₂ leads were placed in the second intercostal space, type III BEP was observed (Fig. 2). The previous emergency room ECGs were reviewed, and type I BEP was found on the first occasion. The echocardiogram and Holter recording were normal.

We reviewed the literature to search for any relationship between cannabis and Brugada syndrome.^{1,2} We found only 1 case study which described the appearance of BEP after acute cannabis-induced intoxication in a young patient but concluded that the case did not exhibit a true Brugada pattern, as procainamide testing was negative. For this reason, we decided to carry out a flecainide test to exclude that our case was similar.

In the flecainide test, the patient presented type III BEP at baseline. The infusion was prematurely stopped when type I BEP

appeared. Therefore, it was concluded that the patient presented asymptomatic BEP (in the absence of syncope, family history of sudden death, or other risk criteria), and that the BEP does not appear spontaneously, but only after cannabis exposure, hence he was a low-risk patient.

The cannabis prohibition was maintained, and at the subsequent follow-up visit, the patient had remained abstinent. There were no clinical manifestations. At a total of 4 visits following cannabis cessation, the patient showed no type I BEP (normal ECG on 2 occasions; type III pattern on 2 occasions).

Our case raises the issue of a possible interaction between cannabis and manifestations of Brugada syndrome.

It could be argued that the patient had intermittent type I BEP and that the relationship between the appearance of this pattern and prior cannabis use was fortuitous, although this is rather unlikely. Hypothetically, reproducibility of the ECG abnormalities could be confirmed by controlled exposure of the patient to cannabis. Because the drug is illegal and potentially addictive, however, the test would raise ethical and legal problems. Moreover, there is a lack of experience with the performance and interpretation of this type of experiment (necessary dose, safety, sensitivity, specificity).

An additional argument is that the literature contains no similar descriptions and the mechanisms of the interaction are unclear. A late vagotonic effect after cannabis exposure has been described, and vagal tone is one of the situations that can unmask BEP.^{3,4} Cannabinoids have also been reported to block Kv1.5 cardiac potassium channels,⁵ although this effect does not appear to explain the appearance of BEP.

In light of the results described and until new evidence is available, we considered prudent to add cannabis to other drugs and toxic substances that should be avoided by patients with BEP at our hospital.