



## SPONTANEOUSLY ARISING DISEASE

# Ileal Ganglioneuromatosis in a Piglet: Histopathological and Immunohistochemical Studies

**M. A. Quiroga, M. I. Lozada, G. Madariaga, J. A. Cappuccio,  
M. A. Machuca, H. Barrales, E. M. Pérez and C. J. Perfumo**

*Department of Veterinary Pathology, Faculty of Veterinary Science, La Plata National University, cc 296, B1900AVW,  
La Plata, Buenos Aires, Argentina*

## Summary

Ganglioneuromatosis (GNM) is a rare condition characterized by the benign proliferation of ganglion cells, nerve fibres and supporting cells of the enteric nervous system. Necropsy examination of a female piglet weighing 4 kg revealed a well-demarcated 20 cm segment of terminal ileum with thickening of the wall. Microscopically, the lamina propria was infiltrated by enteric glial cells and large ganglion cells. Within the submucosal and muscular layers, aggregates of neurons were interlaced by Schwann cells and enteric glial cells arranged in concentric rings. Immunohistochemically, the neurons were weakly labelled for S-100 and neuron-specific enolase, Schwann cells expressed S-100 and vimentin and enteric glial cells expressed glial fibrillary acidic protein and S-100. Pathological and immunohistochemical findings supported the diagnosis of ileal GNM.

© 2014 Elsevier Ltd. All rights reserved.

*Keywords:* ganglioneuromatosis; histopathology; immunohistochemistry; pig

Neoplastic lesions are rare in farmed pigs, especially tumours originating from nervous tissues (Diessler *et al.*, 2002; Head *et al.*, 2002; Brown *et al.*, 2007). Tumours derived from autonomic ganglia include neuroblastoma, ganglioneuroma (GN) and ganglioneuroblastoma (Porter *et al.*, 2007). GN is a solitary, well-demarcated neoplasm that shows limited local invasiveness and low metastatic potential (Head *et al.*, 2002; Jass, 2007). In pigs, solitary (Murakami *et al.*, 2011) and multiple GNs (Une *et al.*, 1984) derived from the intramural plexus of the small intestine have been reported. In contrast, hyperplastic growth can arise from the enteric nervous system and is classified as ganglioneuromatosis (GNM) (D'Amore *et al.*, 1991; Hazell *et al.*, 2011). GNM is a rare condition characterized by the benign proliferation of ganglion cells, nerve fibres

and spindle-shaped neural cells of probable Schwann cell origin (Puig *et al.*, 2009). This neural hyperplasia can either involve all layers of the intestinal wall or predominantly affect the myenteric plexus or the mucosal plexus (D'Amore *et al.*, 1991; Head *et al.*, 2002; Porter *et al.*, 2007; Bemelmans *et al.*, 2011). Both conditions are composed of well-differentiated ganglion cells, nerve fibres, Schwann cells and enteric glial cells (Head *et al.*, 2002; Porter *et al.*, 2007; Hazell *et al.*, 2011). Single cases of GNM have been reported in a dog (Hazell *et al.*, 2011; Paris *et al.*, 2013), a steer (Cole *et al.*, 1990) and a horse (Porter *et al.*, 2007). The purpose of this report is to describe the first case of intestinal GNM in a piglet.

A live 4-week-old female piglet of 4 kg body weight was submitted from a group of 34 pigs of different ages delivered from an intensive farm with a presumptive diagnosis of low weight and retarded growth. At necropsy examination, a

Correspondence to: M. A. Quiroga (e-mail: [mquiroga@fcv.unlp.edu.ar](mailto:mquiroga@fcv.unlp.edu.ar)).

well-demarcated 20 cm segment of terminal ileum was seen to have a thickened wall with partial stenosis of the lumen (Fig. 1). The wall of the affected segment was 0.7–0.9 cm thick, compared with 0.3 cm thick for the remainder of the intestine. The thickened segment included the mucosa, submucosa and muscular layers. The mucosal surface was markedly folded and congested. There were no other gross findings. Samples of ileum, stomach, liver, spleen, kidney and lung were fixed in buffered 10% neutral buffered formalin, processed routinely and embedded in paraffin wax. Sections were stained with haematoxylin and eosin (HE), Van Giesson (VG) stain and Holmes' silver stain (HS) for nerve fibres.

Serial sections were subjected to immunohistochemistry (IHC) using a streptavidin–biotin–immunoperoxidase method (LSAB<sup>®</sup> + System-HRP K0679; Dako, Carpinteria, California, USA). Primary antibodies were specific for S-100 protein (rabbit polyclonal anti-S100, ready to use [RTU]; Novocastra Laboratories, Newcastle, UK), glial fibrillary acidic protein (GFAP; rabbit polyclonal anti-bovine GFAP, RTU, Dako), vimentin (VIM; mouse monoclonal anti-human vimentin, clone V-9, 1 in 100 dilution, BioGenex Laboratories, San Ramon, California, USA), neuron-specific enolase (NSE; monoclonal mouse anti-human NSE, Clone BBS/NC/VI-H14, Dako) and *Lawsonia intracellularis* (pig polyclonal antibody, dilution 1 in 3,000; Roberto Guedes, Universidade Federal de Minas Gerais, Belo Horizonte, Brazil). A normal intestinal sample was used as positive control and normal rabbit serum was substituted for the primary antibodies for a negative control.

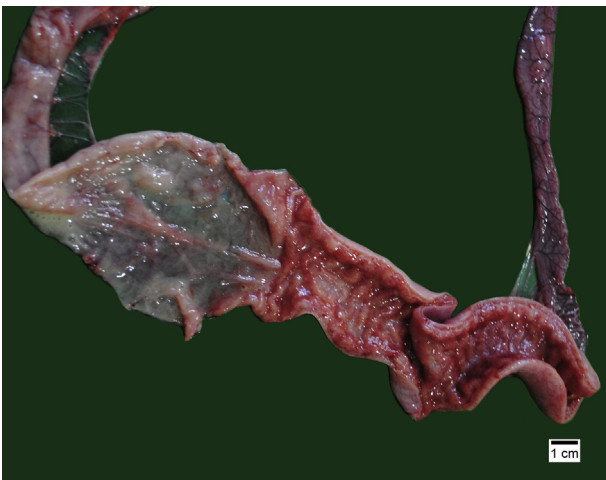


Fig. 1. Ileum showing a thickened segment with congested and folded mucosa (right) clearly demarcated from the adjacent normal segment (left).

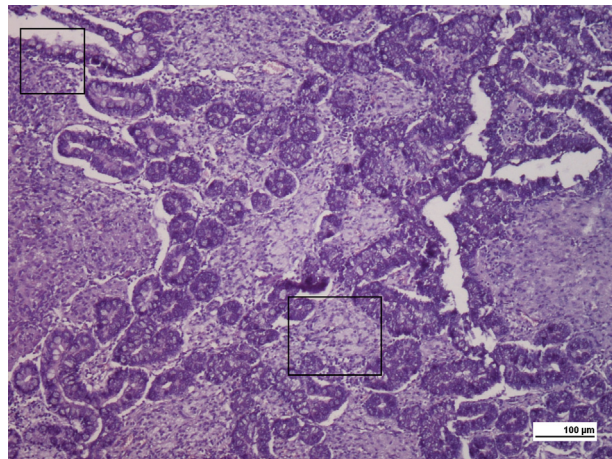


Fig. 2. Thickened ileal lamina propria infiltrated by sheets and bundles of enteric glial cells and neurons (boxed areas are magnified in Figs. 3 and 4). HE.

Microscopically, the lamina propria of the ileum was infiltrated by sheets and bundles of enteric glial cells and ganglion cells (Fig. 2). In the submucosal layer, several aggregates of neurons were interlaced with nerve fibres. Neurons were pyramidal or elongated, with large round nuclei and only a few of them showed Nissl substance. Neither atypia nor mitotic figures were seen. The muscle layers were infiltrated by single or aggregated ganglion cells, surrounded by Schwann cells and enteric glial cells arranged in whorls and tracts that ran parallel to, and at different angles from, the direction of muscle fibres. Neural proliferation was more abundant at the junction of the internal and external muscle fibres.

Immunohistochemically, the nucleus and cytoplasm of neurons expressed NSE and weakly expressed S-100 (Fig. 3). Schwann cells were S-100

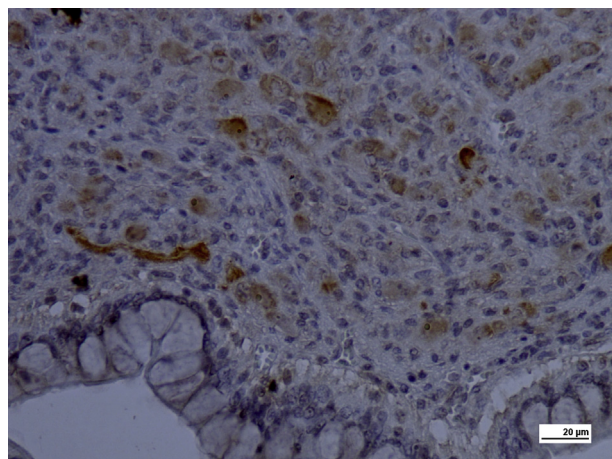


Fig. 3. NSE-positive neuronal bodies in the thickened lamina propria of ileum. IHC.

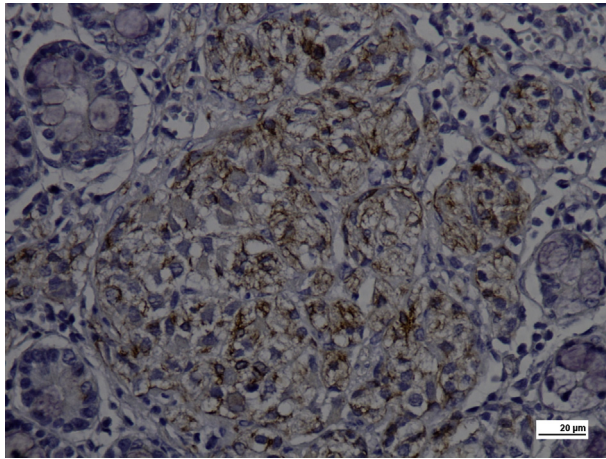


Fig. 4. Ileal lamina propria with whorls of infiltrating cells highlighting GFAP-positive enteric glial cells. IHC.

and VIM positive, while enteric glial cells were GFAP and S-100 positive (Fig. 4). IHC against *L. intracellularis* was negative.

Differences between GN and GNM are limited to the gross aspect. GN is a well-defined single or multiple mass-like tumour, while GNM is a diffuse and poorly demarcated lesion (Cole *et al.*, 1990; Porter *et al.*, 2007; Murakami *et al.*, 2011). In the present case, microscopical and immunohistochemical studies revealed hyperplasia of all cells of the enteric ganglia, in agreement with previous reports (Cole *et al.*, 1990; Head *et al.*, 2002; Hazell *et al.*, 2011; Paris *et al.*, 2013). In man, GNM is classified further as either mucosal or transmural. Mucosal GNM involves neural hyperplasia of the mucosa, while transmural GNM comprises neuronal hyperplasia of the myenteric plexus (Aubercach's plexus) (D'Amore *et al.*, 1991; Porter *et al.*, 2007; Hazell *et al.*, 2011). This differentiation may reflect differences in prognosis, because transmural GNM is associated with the development of multiple endocrine neoplasia type 2b (MEN 2b), a hereditary disorder that occurs in infancy and precedes the development of endocrine tumours (D'Amore *et al.*, 1991; Puig *et al.*, 2009; Bemelmans *et al.*, 2011; Hazell *et al.*, 2011). In the present case, since gross or microscopical changes were not observed elsewhere, the changes were assumed to be confined to the intestine. The pathogenesis of the formation of GNM is unknown, but is believed to result either from a mutation in the *Ret* proto-oncogene that influences the hyperplasia of several neuroendocrine lineages (Cole *et al.*, 1990; D'Amore *et al.*, 1991; Bemelmans *et al.*, 2011; Hazell *et al.*, 2011) or from deletion of *P TEN* (phosphatase and tensin homolog deleted on

chromosome 10), a suppressor gene that regulates cell size and cell proliferation (Puig *et al.*, 2009; Paris *et al.*, 2013).

This particular case of GNM differs from those reported in other animal species with respect to the segment of intestine affected, the age of the animal and the type of GNM (Cole *et al.*, 1990; Porter *et al.*, 2007; Hazell *et al.*, 2011; Paris *et al.*, 2013). Taking the above into consideration, it appears that GNM in the piglet resembles that reported in a dog by Hazell *et al.* (2011). In conclusion, this is the first report of ileal GNM in the pig.

### Acknowledgements

We thank C. Aralda for technical assistance. This work was supported by grants from Agencia Nacional de Promoción Científica y Tecnológica PICT 2010-0961 and Secretaría de Ciencia y Técnica, Universidad Nacional de La Plata, subsidio 11/V218, Argentina.

### References

- Bemelmans I, Küry S, Albaric O, Hordeaux J, Bertrand L *et al.* (2011) Colorectal hamartomatous polyposis and ganglioneuromatosis in a dog. *Veterinary Pathology*, **48**, 1012–1015.
- Brown CC, Baker DC, Barker IK (2007) Alimentary system. In: *Pathology of Domestic Animals*, 5th Edit., Vol. 2, MG Maxie, Ed., Saunders Elsevier, Philadelphia, pp. 1–296.
- Cole DE, Migaki G, Leipold HW (1990) Colonic ganglioneuromatosis in a steer. *Veterinary Pathology*, **27**, 461–462.
- D'Amore ES, Manivel JC, Pettinato G, Niehans GA, Snover DC (1991) Intestinal ganglioneuromatosis: mucosal and transmural types. A clinicopathologic and immunohistochemical study of six cases. *Human Pathology*, **22**, 276–286.
- Diessler ME, Idiart JR, Massone AR, Machuca MA, Perfumo CJ (2002) Peripheral neuroblastoma in a newborn piglet. *Journal of Veterinary Medicine Series A*, **49**, 445–447.
- Hazell KLA, Reeves MP, Swift IM (2011) Small intestinal ganglioneuromatosis in a dog. *Australian Veterinary Journal*, **89**, 15–18.
- Head KW, Else RW, Dubielzig RR (2002) Tumors of the alimentary tract. In: *Tumors in Domestic Animals*, 4th Edit., DJ Meuten, Ed., Iowa State Press, Ames, pp. 401–481.
- Jass JR (2007) Tumors of the small and large intestines. In: *Diagnostic Histopathology of Tumors*, C Fletcher, Ed., Churchill Livingstone Elsevier, St Louis, pp. 379–416.
- Murakami M, Sakai H, Mizutami K, Yanai T (2011) Ganglioneuroma in the small intestine of a juvenile pig. *Journal of Veterinary Medical Science*, **73**, 1501–1504.

- Paris JK, McCandlish IAP, Schwartz T, Simpson JW (2013) Small intestinal ganglioneuromatosis in a dog. *Journal of Comparative Pathology*, **148**, 323–328.
- Porter BF, Storts RW, Payne HR, Edwards JF (2007) Colonic ganglioneuromatosis in a horse. *Veterinary Pathology*, **44**, 207–210.
- Puig I, Champeval D, De Santa Barbara P, Jaubert F, Lyonnet S *et al.* (2009) Deletion of *Pten* in the mouse enteric nervous system induces ganglioneuromatosis and mimics intestinal pseudoobstruction. *Journal of Clinical Investigation*, **119**, 3586–3596.
- Une Y, Iwama K, Yoshida H, Shirota K, Nomura Y *et al.* (1984) Multiple ganglioneuroma derived from intramural plexus of jejunum in a sow. *Japanese Journal of Veterinary Science*, **46**, 247–250.

[ Received, February 18th, 2014 ]  
 [ Accepted, September 1st, 2014 ]