

A comprehensive MRI investigation to identify potential biomarkers of Osgood Schlatter disease in adolescents: A cross sectional study comparing Osgood Schlatter disease with controls

L. B. Sørensen¹ | S. Holden^{1,2,3}  | E. H. G. Oei⁴ | S. P. Magnusson^{5,6} | J. L. Olesen⁷ | B. J. F. Dean⁸ | M. Hever⁹ | K. Lyng^{1,7}  | M. S. Rathleff^{1,7,10} 

¹Department of Health Science and Technology, Aalborg University, Aalborg, Denmark

²School of Public Health, Physiotherapy and Sports Science, University College Dublin, Dublin, Ireland

³Institute for Sport and Health, University College Dublin, Dublin, Ireland

⁴Department of Radiology and Nuclear Medicine, Erasmus MC, University Medical Center, Rotterdam, The Netherlands

⁵Department of Orthopaedic Surgery M, Institute of Sports Medicine, Copenhagen, Denmark

⁶Department of Physical Therapy, Bispebjerg Hospital, Copenhagen, Denmark

⁷Center for General Practice at Aalborg University, Aalborg, Denmark

⁸Nuffield Department of Orthopaedics, Rheumatology and Musculoskeletal Science (NDORMS), Botnar Research Centre, University of Oxford, Oxford, UK

⁹Department of Radiology, Aalborg University, Aalborg, Denmark

¹⁰Department of Occupational Therapy and Physiotherapy, Aalborg University Hospital, Aalborg, Denmark

Abstract

Background: Osgood–Schlatter disease (OSD) is the most common knee pain complaint among adolescents playing sports. Despite this, there remains controversy over the pathophysiology and whether specific anatomical characteristics are associated with OSD.

Purpose: This study aimed to systematically and comprehensively characterize adolescents with OSD using magnetic resonance imaging (MRI) compared to pain-free controls, including both tissue abnormalities that may be associated with OSD, as well as anatomical characteristics. A secondary objective was to identify potential imaging biomarkers associated with pain.

Study Design: Cross-sectional study.

Methods: Adolescents with OSD and controls were recruited from 2020 to 2022. Following a clinical exam, demographics, pain, sports participation, and Tanner stage were collected. Knee MRI was conducted on the participants' most symptomatic knee (OSD) or the dominant leg (controls).

Results: Sixty-seven adolescents (46 with OSD and 30 controls) were included. 80% of participants with OSD had at least one tissue alteration compared to 54% of controls. Compared to controls, OSD had 36.3 (95%CI 4.5 to 289.7) higher odds of bony oedema at the tibial tuberosity, and 32.7 (95%CI 4.1 to 260.6) and 5.3 (95%CI 0.6 to 46.2) higher odds of bony oedema at the tibial epiphysis and metaphysis respectively. Participants with OSD also had higher odds of fluid/oedema at the patellar tendon (12.3 95%CI 3.3 to 46.6), and superficial infrapatellar bursitis (7.2). Participants with OSD had a more proximal tendon attachment (mean tibial attachment portion difference, -0.05 , 95% CI: -0.1 to 0.0 , $p=0.02$), tendon thickness (proximal mean difference, -0.09 , 95% CI: -0.4 to 0.2 , $p=0.04$; distal mean difference, -0.6 , 95% CI: -0.9 to -0.2 , $p=0.01$). Those with bony/tendon

L. B. Sørensen and S. Holden shared first authorship and contributed equally.

This is an open access article under the terms of the [Creative Commons Attribution-NonCommercial-NoDerivs](https://creativecommons.org/licenses/by-nc-nd/4.0/) License, which permits use and distribution in any medium, provided the original work is properly cited, the use is non-commercial and no modifications or adaptations are made.

© 2024 The Authors. *Scandinavian Journal of Medicine & Science In Sports* published by John Wiley & Sons Ltd.

Correspondence

M. S. Rathleff, Department of Health Science and Technology, Aalborg University, Aalborg East, Denmark.
Email: misr@hst.aau.dk

Funding information

Gigtforeningen; Sundhed og Sygdom, Det Frie Forskningsråd

oedema had 1.8 points (95% CI: 0.3 to 3.2) higher pain on palpation than those without ($t = -2.5$, $df = 26.6$, $p = 0.019$), but there was no difference between these groups in a functional single leg pain provocation.

Conclusion: Adolescents with OSD present with tissue and structural abnormalities on MRI that differed from age-matched controls. The majority had findings in the patellar tendon and bone, which often co-occurred. However, a small proportion of OSD also presents without alterations. It appears these findings may be associated with clinical OSD-related pain on palpation of the tibial tuberosity.

Clinical Relevance: Our highlight the pathophysiology on imaging, which has implications for understanding the mechanism and treatment of OSD.

KEYWORDS

apophysis, growth, MR imaging, tibial tuberosity

1 | INTRODUCTION

Adolescence is a period of life marked by rapid growth and physiological, and sexual maturation accompanied by increases in muscle strength, bone length, and physical properties of the tissue.^{1,2} Adolescent growth and biological maturation have been linked to the development of musculoskeletal injuries and pain. Osgood–Schlatter disease (OSD) is considered a growth-related overuse knee pain that affects approximately 10% of adolescents,³ occurring around puberty (8–12 years in girls, and 12 and 15 years in boys^{4,5}). Pain is presents localized at the tibial tuberosity where the patella tendon attaches to the tibial bone^{6,7} and is usually exacerbated by activities like running and jumping. However, the pathophysiology is still unclear³ and debate remains regarding the structural involvement.^{4,5,8–10} There are currently few studies that use MRI to investigate OSD,^{7–9} and while Hirano et al. conducted a longitudinal investigation, there was no inclusion of controls.¹⁰ This makes it difficult to discern which characteristics are associated with OSD, and which are part of normal maturation. One of the problems is that OSD has commonly been considered self-limiting, but recent evidence contradicts this and indicates many adolescents suffer for years with impact on sport.^{11,12}

Considering the potential longer term consequences, there is a need to better understand OSD, and its pathology. A recent systematic review showed that many imaging studies are limited by small samples and a lack of proper comparisons (e.g., no controls) or are based on a small number of cases.⁹ These studies rarely account for the normal changes associated with growth which makes it impossible to disentangle tissue changes associated with growth versus the specific pathology of OSD. The current exploratory study aimed to investigate the tissue characteristics and morphometric features related to OSD using

MRI in adolescents with OSD compared to healthy age-matched controls. A secondary objective was to examine the association between key OSD-related imaging findings and self-report pain in participants with OSD.

2 | METHODS

2.1 | Study design

This study was designed as a cross-sectional study and consisted of one session held at Aalborg University Hospital and included adolescents with OSD and matched pain-free controls. The session included a clinical examination, self-reported questionnaires, and an MRI scan of the knee. All participants received written, and verbal information about the study, and a parental consent form was signed before study participation. The study was performed in accordance with the Declaration of Helsinki¹³ and approved by the North Denmark Region Committee on Health Research Ethics (N-20200001). All data collected during the procedures were stored and processed in alignment with the General Data Protection Regulation (GDPR) guidelines. All data were collected and managed through REDcap (Research Electronic Data Capture) hosted at Aalborg University.^{14,15} REDcap is a secure, web-based software platform that supports data capture for research studies.

2.2 | Participants

The participants were recruited through local sports clubs, social media, and advertisements at local physiotherapy and medical clinics and through our professional network from August 2020 to June 2022. Potentially

eligible adolescents with knee pain were initially screened by telephone. They were included if they were between 8 and 18 of age and diagnosed with OSD, based on a clinical examination conducted by one of two physiotherapists with experience working with OSD. An experienced rheumatologist with a special interest in sports medicine was available for consultation to confirm the diagnosis if needed. The criteria for diagnosing OSD were in line with previous literature^{3,16} and included localized pain at the tibial tuberosity provoked by palpation, and isometric knee extension, and knee-loading activities such as running and jumping. Exclusion criteria were other types of knee pain (e.g., patellofemoral pain, patella tendinopathy, iliotibial band syndrome, and Sinding–Larsen syndrome), knee surgery, habitual patella subluxations, or meniscal injuries, concomitant injury, pain from hip or back, or fear of MR imaging. The inclusion criteria for the controls were no self-reported musculoskeletal pain, previous knee pain, or other chronic neurologic or medical conditions, and fear of MR imaging. Furthermore, any contraindications to MRI were exclusion criteria.

2.3 | Experimental procedures

At the beginning of the session, all participants underwent a clinical examination, including brief patient history, and pain provocations (all scored on a numeric pain rating scale, NRS, ranging from 0 no pain, to 10 worst pain imaginable). Provocations included pain on palpation of the tibial tuberosity (this was done at the most prominent point of the tuberosity, where the examiner attempted to apply a standardized pressure for 2 s duration), pain with resisted knee extension (with participants seated on the edge of a plinth, their knee in about 90 degrees of flexion, the examiner placed their hand around the ankle and asked the participant to push as hard as possible for a 5 s duration) and on hopping (participants performed three repeated hops on their most symptomatic knee). Additionally, it was documented if participants had swelling at the tibial tuberosity as determined by visual evaluation of the tuberosity and pain on kneeling (yes/no in response to the question “Have you experienced pain while sitting in a kneeling position?”). Following this, participants completed the Anterior Knee Pain Provocation test.¹⁷ This consisted of participants preformed a single limb squat to 60° of knee flexion on their (most) symptomatic knee and holding the position for 45 s. Pain intensity was recorded during the end of the test using NRS. Participants completed questionnaires on self-reported symptoms and sports participation. Adolescents with OSD reported the duration and frequency of pain, as well as their worst knee pain in the past week on a visual analog scale (VAS), anchored at 0

(“no pain”) and 10 (“worst pain”). Self-reported knee function and health-related quality of life were assessed by all participants using the Knee Injury Osteoarthritis Outcome Score for children (KOOS-child)^{18,19} and the youth version of the EuroQol five dimensions questionnaire, 3-level version (EQ-5D-3L).¹⁹ The Tanner Rating Scale was used for self-ratings of physical maturation in children and adolescents.²⁰

2.4 | Magnetic resonance imaging

MR imaging of the symptomatic knee or the most symptomatic knee in cases of bilateral pain (adolescents with OSD) or the knee of the dominant leg (controls). Dominancy was assessed as the response to “which leg would you use to kick a ball as far as possible.” MRI was performed on all participants at the Department of Radiology, Aalborg University Hospital, by an experienced radiographer using a 1.5 Tesla MRI System (scanner name, GE Healthcare, Milwaukee, WI, USA) and a flexible 16 channel wrap-around surface coil (GEM flex, GE Healthcare, Milwaukee, WI, USA). The imaging protocol was based on a standard clinical knee imaging protocol and was further developed by the research group and piloted before the first participant inclusion. The MR imaging protocol was composed of proton density (PD) weighted fast spin-echo (FSE) sequences and T2-weighted FSE sequences with fat suppression in all three planes, a PD weighted FSE sequence with fat suppression in the sagittal and coronal planes, a T1-weighted FSE sequence in the sagittal plane, and a 3D fast imaging employing steady-state acquisition (FIESTA) sequence acquired in the sagittal plane with the possibility of multiplanar reconstructions in the coronal and axial planes. The picture archiving and communication system (PACS) was used to store all images, and the assessments and measurements were performed in the same system.

Participants were in a supine position with the knee coil placed over the knee. The scans lasted about 20 s and up to 4 min for the individual sequences, with approximately 30 min to complete the full knee imaging protocol per participant. Only three adolescents with OSD had bilateral MRIs taken; therefore, these images are not included in the analysis.

An experienced musculoskeletal radiologist initially reviewed all MRI scans according to current clinical guidelines to rule out disorders other than OSD and screen for incidental findings. The MRI scans were all scored by a trained researcher (LBS) with limited experience in rating MRI scans. The researcher was trained by two experienced radiologist (MH and EO) for 20 h. During this period multiple scans were scored by both

the experienced radiologist and the researcher to establish reliability and ensure scoring was done appropriately. The scoring of MRI scans were done to identify any changes in the tissues, including the examination of the patella tendon, bursae, bone marrow edema, and partial avulsions of the tibia tuberosity, and morphological measurements (patella height and morphology, patellar tendon attachment and thickness). All scans were rated using a novel semi-quantitative scoring system for MRI developed by the research group (Sørensen et al.,²¹ in preparation), which was shown to have good reliability for all features. The full scoring can be seen in supplementary appendix including further details related to categories (Appendix S1). All included items had good inter and intra rater reliability (with ICC/Cohens Kappa values >0.5). Most measures had good to very good (0.6–8.0) reliability, with some having excellent (e.g., tendon thickness ICC >0.9). Items with intra or inter reliability <0.5 were not included (this pertained to one item only on patellar morphology which was excluded). The items were based on outcomes from our recent systematic review of imaging findings in OSD patients.⁹

2.5 | Sample size

Based on imaging in OSD compared to controls,^{7,22} we expected that a sample of 50 OSD and 30 controls would be enough for the cross-sectional comparisons between the groups. These sample size calculations were done under a range of different scenarios based on assumptions about the SMDs across the different imaging features while

appreciating the variability within groups were expected to be larger among adolescents with OSD compared to controls. These estimations were expected to be best estimates as there is limited to data to base strong sample-size calculations on.

3 | STATISTICAL ANALYSIS

Unless otherwise stated, all data are presented as mean \pm SD or median, interquartile range (IQR) in text and figures. Data were initially checked for normality within groups by visual inspection of Q–Q plots and the Shapiro–Wilk test and analyzed by appropriate statistical tests i.e., parametric or non-parametric tests which are subsequently outlined in detail for each independent variable. The statistical analyses were performed in SPSS for windows (IBM, version 28), and a significance level was accepted at $p \leq 0.05$. Descriptive statistics describe participant and clinical characteristics for both OSD and controls. To evaluate differences in the proportions of tissue characteristics between the OSD and control, Fischer's exact test was used, and logistic regression was used to calculate Odds Ratio's and 95% Confidence Intervals. Differences in morphometric features between OSD and controls assessed on MRI were compared between groups using independent samples *t*-tests. Oedema at the tibial tuberosity and the patellar tendon (PT) were the most strongly associated with OSD, and therefore selected to identify the relationship between OSD-related pain and imaging findings. An independent samples *t*-test was used to compare those with oedema at the TT and/or PT (as these rarely occurred in isolation) to those with no

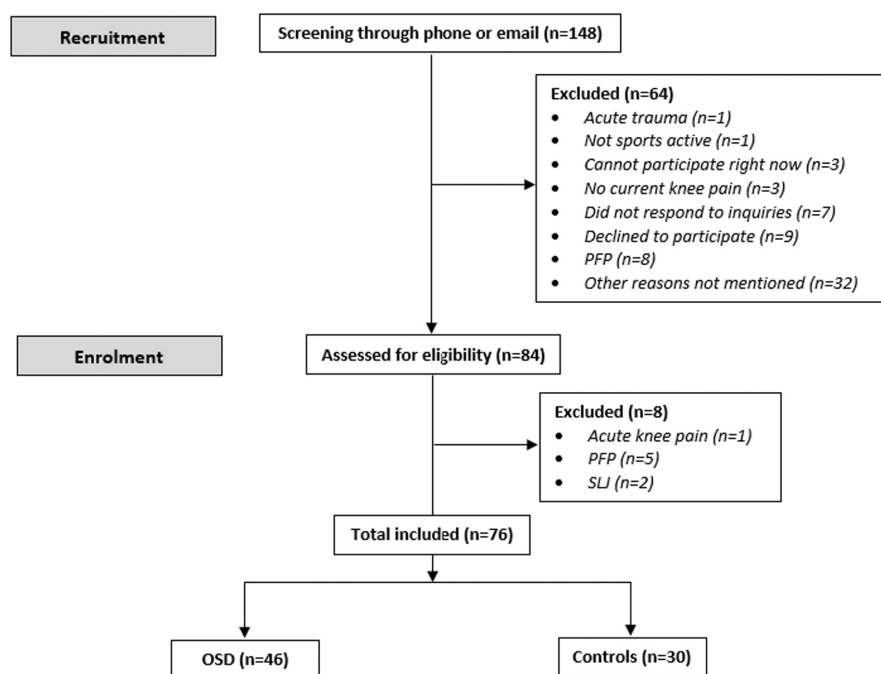


FIGURE 1 Flowchart. OSD, Osgood Schlatter disease; PFP, patellofemoral; SLJ, Sinfing Larsen Johansson.

findings at the TT or PT. The dependent variables of interest were pain on palpation of the TT, as localized pain at the tibial tuberosity is the cardinal symptom of OSD, and pain during the AKPP test as a functional loading test. It was decided a priori if any differences were found between groups, separate bivariate correlations would be run to determine the association between degree (mild, moderate, severe) of findings at each site (TT and PT) and pain intensity using Spearman's rank correlation coefficient.

4 | RESULTS

A total of 84 adolescents were assessed for eligibility, and 46 OSD (13.1±1.3 years, 45% females) and 30 matched controls (13.0±1.4 years, 50% females) were included in the study (Figure 1 “flowchart”). The OSD and controls were comparable regarding age, BMI, hours of sleep, and sports participation. The OSD had fewer adolescents in Tanner stage 2 (23% vs. 30%) and more in Tanner stage 3 (39% vs. 23%) compared to the controls. Additionally, no OSD was Tanner stage 5. Several sports were included, with most participants playing soccer as their primary sport in both groups (Table 1 “participants characteristics”). The clinical characteristics of participants with OSD are displayed in Table 2.

4.1 | Imaging findings

4.1.1 | Tissue characteristics

Compared to controls, a greater proportion of OSD presented with signal intensity at the TT (55.6% vs. 3.3; Odds ratio 36.3 (95% CI: 4.5 to 289.7, $p \leq 0.001$)), indicating the presence of bone oedema. For the OSD, the signal was non-homogenous and, in most cases, rated as moderate (56%; 14/25).

Compared to controls, a higher proportion of OSD presented with signal in the tibial epiphysis (51.1%, 95% CI: 35.8–66.3 vs. 0%, 95% CI: 0.0–11.6) and tibial metaphysis (13.3%, 95% CI: 5.1–26.8 vs. 0%, 95% CI: 0.0–11.6, Table 3). In all cases, the signal intensity was non-homogenous, and for the tibial epiphysis, it was rated as either mild (16/23) or moderate (7/23). The signal intensity at the tibial metaphysis was rated as mild (4/6) and moderate (2/6). A free ossicle (increased signal intensity in separate bone) was observed between the proximal to the distal patellar tendon attachment site (Field I) in 4 OSD and between the articular surface of the tibial bone and the proximal patella tendon attachment site (Field II) in one OSD (11.1% 95% CI: 0.1–11.8). No free ossicle was observed in any controls (0%, 95% CI: 0.0–4.8).

A Higher proportion of OSD had a non-homogeneous signal intensity in the patellar tendon compared to controls 57.8% vs. 10%; odds ratio 12.3 (95% CI: 3.3 to 46.6, $p \leq 0.00$). This was rated as mild (13/26) or moderate intensity (13/26) in OSD compared with mild only in controls (3/3). Superficial infrapatellar bursitis was observed in OSD, and no controls (17.8% vs. 0%). Deep infrapatellar bursitis was observed in both OSD and controls (62.2% vs. 50.0%; OR = 1.6, 95% CI: 0.65 to 4.2, $p = 0.26$). Further details are presented in Table 3 (“tissue characteristics”).

TABLE 1 Participant descriptive.

Participant characteristics	OSD (n = 46)	Control (n = 30)
Age (years)	13.1 ± 1.3	13.0 ± 1.4
Sex (male, female)	(25, 21%)	(15, 15%)
Maturation (Tanner scale), n (%)		
I	3 (6.5%)	2 (6.7%)
II	11 (23.9%)	9 (30.0%)
III	18 (39.1%)	7 (23.3%)
IV	14 (30.4%)	10 (33.3%)
V	0 (0%)	2 (6.7%)
Menstruation, n (%) female)	11 (52.4%)	9 (60%)
Body mass index (kg/m ²)	18.9 ± 3.2	18.2 ± 2.4
Sleep (h) ^a	9.0 (8.0–9.5)	9.0 (8.0–9.0)
Leg dominance (right %)	88.2%	89.6%
Sports participation (h/week) ^a	2.0 (1.0–3.0)	3.0 (2.0–4.0)
Sports participation (times/week) ^a	4.0 (2.0–5.0)	4.0 (3.0–5.3)
Reduced sports activity due to knee pain, n (%) ^b	26 (74.2%)	–
Primary sports, n (%)		
Soccer	26 (56.5%)	15 (50%)
Handball	11 (23.9%)	7 (23.3%)
Badminton	2 (4.3%)	3 (10.0%)
Floorball	2 (4.3%)	–
Ice hockey	2 (4.3%)	–
Karate	1 (2.2%)	3 (10.0%)
Swimming	–	1 (3.3%)
Gymnastics	–	1 (3.3%)
Rope skipping	1 (2.2%)	–
Participation in multiple sports	10 (21.7%)	11 (36.7%)

Note: Data are presented as mean ± SD or n (%) unless otherwise denoted.

^aMedian (inter-quartile range).

^bMissing data from 11 participants.

TABLE 2 Clinical characteristics.

Clinical characteristics	OSD (n = 46)	Control (n = 30)
Worst pain past week (0–100)	55.2 ± 24.2	NA
Pain duration (month)	16.7 ± 12.9	NA
Pain frequency (%)		
Rarely	3 (6.7%)	NA
Monthly	2 (4.4%)	
Weekly	7 (15.6%)	
Several times per week	19 (42.2)	
Almost daily	14 (31.1%)	
Pain on TT (0–10)*	4.0 (2.0–5.0)	NA
Pain on isometric contraction (0–10)*	3.0 (0.7–5.0)	NA
Pain on single-leg squat (0–10)*	4.0 (2.0–6.0)	NA
Pain on hopping (0–10)*	3.0 (0.0–4.3)	NA
Swelling on TT, n (%)	28 (60.7%)	NA
Pain on kneeling, n (%)	34 (73.9%)	NA
Affected knee (%)		
Right	10 (21.7%)	NA
Left	13 (28.3%)	
Both	23 (50.0%)	
KOOS-child pain	68.4 ± 15.2	93.8 ± 7.3
KOOS-child symptom	72.1 ± 13.9	91.6 ± 7.7
KOOS-child ADL	82.8 ± 13.1	97.9 ± 3.6
KOOS-Child sport/rec	59.3 ± 16.7	93.4 ± 8.9
KOOS-child QoL	55.8 ± 14.0	94.0 ± 9.7
Baseline AKPP score (0–10)*	6.0 (3.5–8.0)	0.0 (0.0–2.5)

Note: Data are presented as mean ± SD or n (%) unless otherwise denoted. Abbreviations: *AKPP, anterior knee pain provocation; KOOS, knee injury Osteoarthritis Outcome Score; TT, tibial tuberosity.

4.1.2 | Morphometric features

For the morphometric features, there was no difference between the OSD and controls for the patella IS ratio, Grelsamer morphology, free patella proportion (FPTP), and patellar tendon thickness at the mid-portion site of the tendon ($p \geq 0.05$, Table 4 “morphometric features”). In contrast, the tibia attachment proportion (TAP) was larger in OSD than in controls (mean difference, -0.05 , 95% CI: -0.1 to 0.0 , $p = 0.02$), indicating the tibial attachment was more proximal in the OSD group. The patellar tendon thickness (anterior–posterior mm) was significantly increased at the proximal (mean difference, -0.09 mm, 95% CI: -0.4 to 0.2 , $p = 0.04$) and distal site attachment site (mean difference, -0.6 , 95% CI: -0.9 to -0.2 , $p = 0.01$) in OSD compared to controls (Table 4 “morphometric features”).

4.2 | Extent of tissue involvement

The majority of OSD (80%) had at least one abnormal finding, compared to 54% of controls (Figure 2). One tissue alteration defined as the involvement of either the patellar tendon or soft tissue (infrapatellar bursae) or bone alterations. Further details on each of these individual groupings and in combination are demonstrated in Table 5 “Number of findings on MRI.”

4.3 | Extent of MRI findings across maturation status

Tanner grouped into pre-early pubertal (Tanner 1–3) and late—post pubertal (Tanner 4–5) stages. Twenty-six percentage OSD in the pre/early pubertal and twenty-one percentage OSD in the late post pubertal stages had one tissue alterations (Figure 3, green charts). Nearly half the pre/early pubertal (48%) and a third of the OSD in late/post pubertal (36%) had up to four tissue alterations (blue charts). None of the control groups presented with concomitant patellar tendon, soft tissue, and bone alterations. Most of the controls had either null tissue alterations (Tanner 1–3, 61% and Tanner 4–5, 25%, striped charts) or one tissue alteration (Tanner 1–3, 33% and Tanner 4–5, 67%, gray charts, Figure 3).

4.4 | Association between MR findings and pain

In the OSD group, there was a significant difference in pain on palpation of the tibial tuberosity between those with bony and/or tendon oedema. Those with bony/tendon oedema had 1.8 points (95% CI 0.3 to 3.2) higher pain on palpation than those without ($t = -2.5$, $df = 26.6$, p -value = 0.019; Figure 4A). There were no differences between these groups in AKPP score ($t = -1.34$, $df = 25.8$, p -value = 0.179; Figure 4B). Based on the relation between oedema and pain at the tibial tuberosity, post hoc correlations for severity revealed a moderate positive correlation between TT pain degree of signal intensity at the tibial tuberosity ($R = 0.42$; $p = 0.046$; Figure 5) and at the patellar tendon ($R = 0.37$; $p = 0.013$).

5 | DISCUSSION

This cross-sectional study used blinded assessments and an age-matched control group to comprehensively explore OSD related findings and anatomical characteristics. The majority of OSD (80%) had at least one tissue alteration,

TABLE 3 Tissue characteristics for OSD ($n = 45$) and controls ($n = 30$).

Soft tissue		OSD ($n = 45$) ^a	Control ($n = 30$)	OR (95% CI)	<i>p</i> -value		
Tissue structure	MRI plane/sequence						
Patellar tendon							
Fluid/edema	Sagittal/PDFS	Signal intensity Homogeneity	Present, <i>n</i> (%) Homogenous	26 (57.8%, 95% CI: 42.2–72.3) –	3 (10%, 95% CI: 2.1–26.5) 1 (3.3%, 95% CI: 0.1–17.2)	12.3 (3.3 to 46.6)	≤ 0.001
	Degree	Non-homogenous Mild Moderate Severe	–	26 (57.8%, 95% CI: 42.2–72.3) 13 (28.9%, 95% CI: 16.4–44.3) 13 (28.9%, 95% CI: 16.4–44.3) –	2 (6.7%, 95% CI: 0.8–22.1) 3 (10%, 95% CI: 2.1–26.5) – –		
Superficial infrapatellar bursa							
Fluid/bursitis	Sagittal/PDFS	Signal intensity Homogeneity	Present, <i>n</i> (%) Homogenous	8 (17.8%, 95% CI: 8.0–32.1) 5 (11.1%, 95% CI: 3.7–24.1)	0 (0%, 95% CI: 0.0–11.6) NA	7.2 (0.9 to 60.9)	< 0.05
	Degree	Non-homogenous Mild Moderate Severe	–	3 (6.7%, 95% CI: 1.4–18.3) 6 (13.3%, 95% CI: 5.1–26.8) 2 (4.4%, 95% CI: 0.5–15.1) –	NA NA NA NA		
Deep infrapatellar bursa							
Fluid/bursitis	Sagittal/PDFS	Signal intensity Homogeneity	Present, <i>n</i> (%) Homogenous	28 (62.2%, 95% CI: 46.5–76.2) 10 (22.2%, 95% CI: 11.2–37.1)	15 (50.0%, 95% CI: 31.3–68.7) 13 (43.3%, 95% CI: 25.5–62.6)	1.6 (0.65 to 4.2)	0.35
	Degree	Non-homogenous Mild Moderate Severe	–	18 (40.0%, 95% CI: 25.7–55.7) 17 (37.8%, 95% CI: 23.8–53.5) 9 (20%, 95% CI: 9.6–34.6) 2 (4.4%, 95% CI: 0.5–15.1)	2 (6.7%, 95% CI: 0.8–22.1) 15 (50%, 95% CI: 31.3–68.7) – –		
Cartilage and bone							
The tibial epiphysis (level of TT)							
Bone edema	Sagittal/PDFS	Signal intensity Homogeneity	Present, <i>n</i> (%) Homogenous	23 (51.1%, 95% CI: 35.8–66.3) –	0 (0%, 95% CI: 0.0–11.6) NA	32.7 (4.1 to 260.6)	< 0.001
	Degree	Non-homogenous Mild Moderate Severe	–	23 (51.1%, 95% CI: 35.8–66.3) 16 (35.6%, 95% CI: 21.9–51.2) 7 (15.6%, 95% CI: 6.5–29.5) –	NA NA NA NA		
The tibial metaphysis (level of TT)							

(Continues)

TABLE 3 (Continued)

Cartilage and bone								
Bone edema	Sagittal/PDFS	Signal intensity	Present, <i>n</i> (%)	6 (13.3%, 95% CI: 5.1–26.8)	0 (0%, 95% CI: 0.0–11.6)	5.4 (0.6 to 46.2)	0.13	
		Homogeneity	Homogenous	-	NA			
		Degree	Non-homogenous	6 (13.3%, 95% CI: 5.1–26.8)	NA			
			Mild	4 (8.9%, 95% CI: 2.5–21.2)	NA			
			Moderate	2 (4.4%, 95% CI: 0.5–15.1)	NA			
			Severe	-	NA			
The tibia tuberosity								
Bone edema	Sagittal/PDFS	Signal intensity	Present, <i>n</i> (%)	25 (55.6%, 95% CI: 40.0–70.4)	1 (3.3%, 95% CI: 0.1–17.2)	36.3 (4.5 to 289.7)	≤0.001	
		Homogeneity	Homogenous	-	-			
			Non-homogenous	25 (55.6%, 95% CI: 40.0–70.4)	1 (3.3%, 95% CI: 0.1–17.2)			
		Degree	Mild	7 (15.6%, 95% CI: 6.5–29.5)	-			
			Moderate	14 (31.1%, 95% CI: 18.2–46.6)	1 (3.3%, 95% CI: 0.1–17.2)			
			Severe	4 (8.9%, 95% CI: 2.5–11.6)	-			
Ossicles/free fragment	Sagittal/PDFS	Signal intensity	Present, <i>n</i> (%)	5 (11.1%, 95% CI: 3.7–24.1)	0 (0%, 95% CI: 0.0–4.8)	4.4 (0.5 to 38.1)	0.23	
		Homogeneity	Homogenous	1 (2.2%, 95% CI: 0.1–11.8)	NA			
			Non-homogenous	4 (8.9%, CI: 2.5–21.2)	NA			
		Degree	Mild	5 (11.1%, 95% CI: 3.7–24.1)	NA			
			Moderate	-	NA			
			Severe	-	NA			
Location	Sagittal/PDFS		Field I	4	NA			
			Field II	1	NA			
			Field III	-	NA			
			Field IV	-	NA			
			Field V	-	NA			

Note: Data are presented as *n*, (%), 95% confidence interval, CI), and odds ratio (OR, 95% confidence interval, CI). Bold values indicate statistical significant ($p < 0.05$) based on Fisher's Exact test for differences in proportions. The location of ossicles by predefined fields of the patellar tendon is defined in Engel et al.²³

Abbreviations: MRI, magnetic resonance imaging; NA, not applicable; OSD, Osgood Schlatter disease; PDFS, proton density fat saturation; TT, tibia tuberosity.

^a1 OSD did not complete the MRI.

TABLE 4 Morphometric features for OSD ($n=45$) and controls ($n=30$).

Morphometric features		MRI plane/sequence	OSD ($n=45$) ^a	Control ($n=30$)	Mean difference (95% CI)	<i>p</i>
Measure						
Patella height						
Insall-Salvati index (IS)		Sagittal/Tw1	1.06±0.20	1.13±0.14	0.1 (-0.0 to 0.2)	0.39
Patellar tendon attachment						
Free patella proportion (FPTP)		Sagittal/ Tw1	0.80±0.04	0.81±0.03	0.01 (0.0 to 0.0)	0.16
Tibial attachment proportion (TAP)		TAP ratio	0.35±0.08	0.30±0.05	-0.05 (-0.1 to 0.0)	0.02
Patellar tendon thickness						
Proximal site (distal to the patellar insertion)		Axial/FIESTA 3D	4.54±0.71	4.45±0.48	-0.09 (-0.4 to 0.2)	0.04
Mid portion site		Axial/FIESTA 3D	4.65±0.78	4.52±0.58	-0.1 (-0.5 to 0.2)	0.50
Distal site (proximal to the tibial insertion)		Axial/FIESTA 3D	5.14±0.96	4.58±0.56	-0.6 (-0.9 to -0.2)	0.01
The widest part of the patella tendon		Axial/FIESTA 3D	31.23±2.87	29.50±2.78	-1.7 (-3.1 to -0.4)	0.89

Note: Data are presented as mean SD and mean difference (95% confidence interval, CI). Bold values indicate statistical significance ($p < 0.05$).

Abbreviations: FIESTA, fast imaging employing steady-state acquisition; mm, millimeters; MRI, magnetic resonance imaging; OSD, Osgood Schlatter disease; Tw1, T1-weighted image.

^aOne OSD did not complete the MRI.

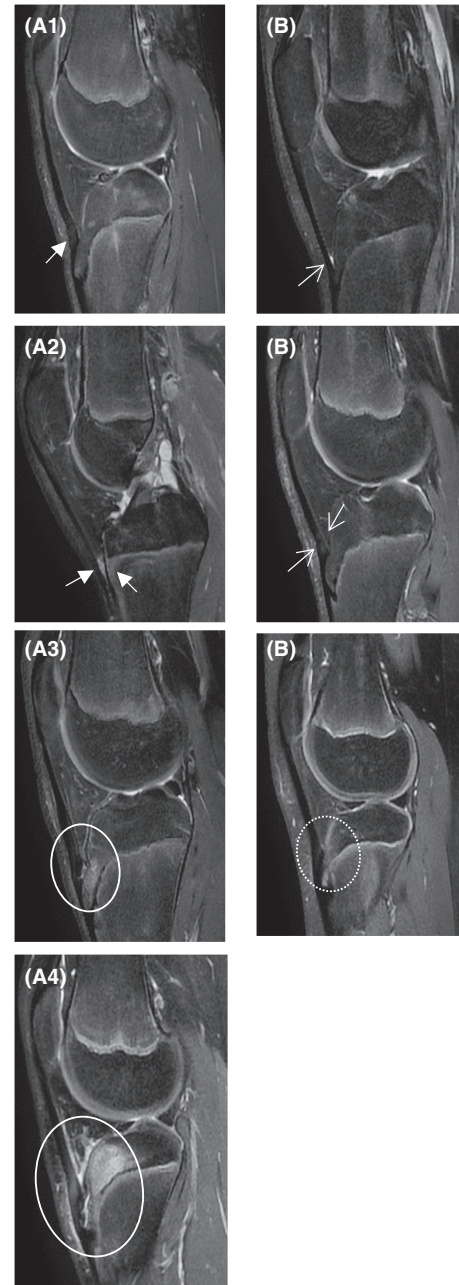


FIGURE 2 Number of MRI findings (1–4) on exemplary scans of OSD (A) and control (B). (A1) Involvement of the patellar tendon (closed arrow), (B2) involvement of the deep infrapatellar bursa (open arrow). (A2) Involvement of deep bursa and tibial tuberosity (closed arrows), (B2) involvement of patellar tendon and bursa (not visible on same sequence, open arrows). (A–B3) Patellar tendon and bursa involvement with tibial tuberosity oedema (open and closed circles), (A4) Involvement of patellar tendon, bursa, and bone edema (closed circle).

with over half of the OSD participants having alterations in both soft tissue and bone irrespective of sexual maturation assessed by Tanner stages. Findings in controls related primarily to mild signal intensity in the bursa, with few other findings. Adolescents with OSD were characterized by bony changes the tibial tuberosity (odds ratio

TABLE 5 Extent of findings on MRI in OSD (total: $n = 45$) and controls (total: $n = 30$).

Number of findings on MRI (tissue involvement)	Description	OSD ($n = 45$) ^a	Control ($n = 30$)
0 tissue alterations	Normal MRI	9 (20%)	14 (46.6%)
1 tissue alteration		11 (24.4%)	14 (45.6%)
Patellar tendon	Presence of signal intensity in the patella tendon only with no bone alterations	8.9%	3.3%
Bursitis	Presence of fluid in the infrapatellar bursa (deep) only with no bone alterations	15.6%	43.3%
Bony only	Bony changes in the TT and/or metaphysis/epiphysis	2.2	0%
2 tissue alterations		2 (4.4%)	1 (3.3%)
Patellar tendon and bursitis	Presence of signal intensity in the patellar tendon and fluid within the infrapatellar bursae with no bony alterations	0%	3.3%
Bursitis and bone	Presence of fluid within the infrapatellar bursa and bone edema (TT only)	2.2	0%
Patellar tendon and bone	Presence of signal intensity in the patellar tendon only with bone changes (tibial tuberosity and/or metaphysis/epiphysis)	2.2%	0%
Bursitis and bone	Presence of fluid within the infrapatellar bursa only with changes (tibial tuberosity and/or metaphysis/epiphysis)	2.2%	0%
Three tissue alterations			
Patellar tendon, bone and bursitis	Presence of signal intensity in the patellar tendon and fluid within the infrapatellar bursa with bone changes (tibial tuberosity and/or metaphysis/epiphysis)	46.6%	3.3%
Total (tissue alterations >1)		25 (56%)	2 (6.7%)

Note: Data are presented as n (%).

Abbreviation: OSD, Osgood–Schlatter disease.

^aOne OSD did not complete the MRI.

36) and tibial epiphysis, indicating bone edema and patellar tendon changes (OR 12.3). Further, 10% of adolescents with OSD presented with an ossicle, which was not seen in any controls. Findings in controls related almost solely to signal intensity in the deep infra patellar bursa indicating bursitis, which was not significantly different from OSD. Quantitative findings underscored the involvement of the patellar tendon, with an increase in tendon thickness proximally and distally compared to controls, and a more proximal tendon attachment. This knowledge has clear implications for the pathophysiology of OSD and characterization of this common MSK disorder.

5.1 | Relationship between pathophysiological findings and symptoms

In the current study, those with bony oedema at the TT and/or PT changes had higher pain on palpation of the tibial tuberosity. Further the degree (mild, moderate severe) was also associated with pain during palpation. However, we did not find a clear differences in pain between these subgroups of findings for the outcome of a functional pain

provocation, although there was a small difference indicating that we might have been slightly underpowered for this comparison. Previously, Saily et al.²² found that the presence of doppler signal on ultrasound was associated with higher pain on palpation and isometric extension in participants with OSD. Lee et al.⁷ also found that patellar tendon attachment measures were associated with higher pain scores and postulated this was due to increased stress on the tibial tuberosity.

A small portion (20%) of participants with OSD had no findings on the knee MRI. This finding aligns with a previous MRI study from Hirano et al.^{10,24} who found that nine participants (30% of their sample) presented with localized pain at the tuberosity but had a normal MRI. Further research is warranted to determine the prognostic utility of imaging findings, and whether our identified features can be used as a surrogate biomarkers for prognosis or to guide treatment decisions. One exploratory study²⁴ found that those without imaging findings were less likely to have pain at follow-up, while another found that the presence of ossicles was associated with delayed return to sport.²⁵ Our findings build on this exploratory research by using a strong study design and blinding and underscore the relevance of

FIGURE 3 Percentage of findings on MRI in OSD and controls across Tanner stages. OSD, Tanner 1–3 ($n=31$), OSD, Tanner 4–5 ($n=14$), control, Tanner 1–3 ($n=18$), control, Tanner 4–5 ($n=12$).

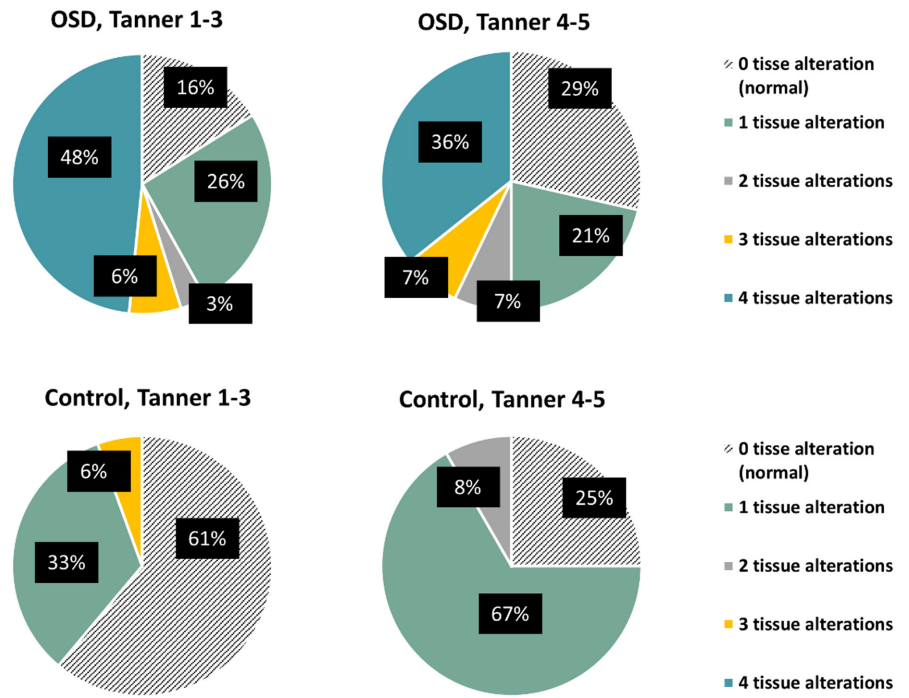


FIGURE 4 Pain on tibial tuberosity palpation (left panel, A) and pain during anterior knee pain provocation for those with and without patellar tendon (PT) and/or tibial tuberosity (TT) oedema (right panel, B).

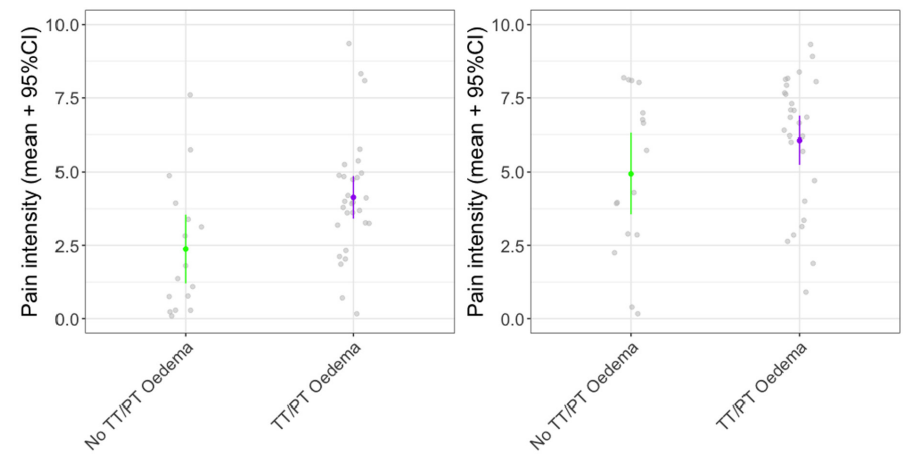
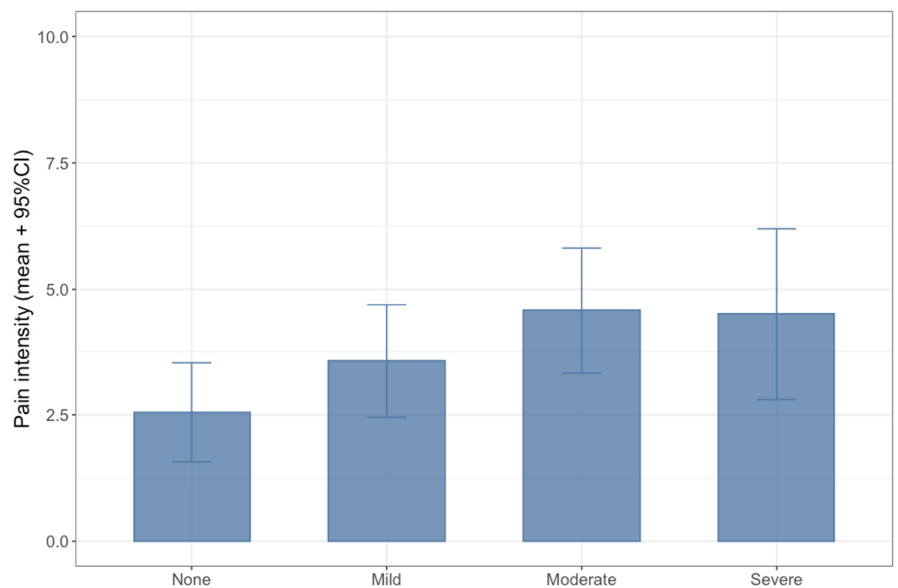


FIGURE 5 Association between imaging findings (graded based on signal intensity) at the tibial tuberosity and pain intensity.



potential surrogate biomarkers in the pathophysiology of OSD. However, many other factors may be involved in the relation between structural findings and pain severity and may modulate the adolescent's pain experience (e.g., physical activity). The interplay between these factors has not been investigated in this population.

5.2 | Clinical implications and future research

Adolescents with OSD have previously been considered as a single group suffering from pain on the tibial tuberosity, but this cross-sectional study opens for new research questions regarding the potential significance of the imaging findings. The data confirm previous studies which highlight the involvement of the distal patellar tendon.^{7,26–28} In the current study, we found a small increase in thickness in OSD participants distally. The magnitude of the difference was smaller than has previously reported in other studies using MRI in OSD.⁷ Tendinopathy is characterized by proximal tendon pain and thickening in isolation, indicating a local issue.²⁹ Recent systematic reviews have found that tendinopathy occurs in adolescents and increases up to the age of 18.³⁰ Interestingly, we also found a small significant increase in proximal thickness, but the magnitude of this was smaller than what was found distally.

It is unclear if the specific subgroups may need different treatment approaches. Previous studies have identified “stages” based primarily on the type of tissue involvement²⁷ and/or the extent of tissue involvement/number imaging findings.^{10,25} But there is no consistent way of determining OSD pathology. At present, it is unclear if the clinical presentation and or course differs between such subgroups, or severity based on imaging.

6 | STRENGTH AND LIMITATIONS

A recent systematic review of the imaging findings associated with OSD demonstrated a lack of blinded analyses, too small sample sizes, and a lack of matched control groups, which likely threatens its conclusions. We tried to address these shortcomings in the literature by using blinded assessment by two raters (experienced and novice rater), a larger sample size (although challenged by COVID-19), and a matched control group. A low sample size hampers our analysis of the effect of self-reported maturation in some of the specific subgroups and hence hampers strong conclusions. We used Tanner stages and not maturation of the TT based on MRI scans. We used a broad recruitment strategy and captured a broad sample from different

sports and a wide range of symptoms. Future studies may need to target a specific age group or duration of symptoms to gain deeper insights into the development trajectory of OSD symptoms from early onset toward larger impact and disability.

7 | PERSPECTIVES

This study demonstrates that many adolescents with OSD show abnormalities in MR, including tissue alterations (primarily in the distal patella tendon and bone) and morphometric differences compared to controls in the patellar tendon attachment. There is also a group of OSD presenting with a normal knee scan. Interestingly, the most common findings (at the tendon and tibial tuberosity which almost always occurred together) were associated with a greater pain severity on palpation of the tuberosity, the cardinal symptom of OSD. Hence, future research needs to explore the relevance of such subgroups, and whether this information can be used clinically to identify those at risk or worse prognosis or requiring different treatment approaches.

FUNDING INFORMATION

The study is supported by the Danish Rheumatism Association (Gigtforeningen grant ID R168-A5697) and the Independent Research Foundation Denmark (IRFD Grant ID 9039-00238B).

CONFLICT OF INTEREST STATEMENT

The authors have no conflict to declare.

DATA AVAILABILITY STATEMENT

Data are available in anonymised form by reasonable request by contacting the corresponding author.

ORCID

S. Holden  <https://orcid.org/0000-0002-7314-2152>

K. Lyng  <https://orcid.org/0000-0001-8668-691X>

M. S. Rathleff  <https://orcid.org/0000-0003-1173-0335>

REFERENCES

- Swain M, Kamper SJ, Maher CG, Broderick C, McKay D, Henschke N. Relationship between growth, maturation and musculoskeletal conditions in adolescents: a systematic review. *Br J Sports Med.* 2018;52:1246-1252.
- Patton GC, Viner R. Pubertal transitions in health. *Lancet.* 2007;369:1130-1169.
- Gholve P, Scher D, Khakharia S, Widmann R, Green D. Osgood Schlatter syndrome. *Curr Opin Pediatr.* 2007;19:44-45.
- Flowers M, Bhadreshwar DR. Tibial tuberosity excision for symptomatic Osgood-Schlatter disease. *J Pediatr Orthop.* 1995;15:292-297.

5. Ehrenborg G, Lagergren C. Roentgenologic changes in the Osgood-Schlatter lesion. *Acta Chir Scand*. 1961;121:315-327.
6. Blankstein A, Cohen I, Heim M, et al. Ultrasonography as a diagnostic modality in Osgood-Schlatter disease a clinical study and review of the literature. *Arch Orthop Trauma Surg*. 2001;121(9):536-539.
7. Lee DW, Kim MJ, Kim WJ, Ha JK, Kim JG. Correlation between magnetic resonance imaging characteristics of the patellar tendon and clinical scores in Osgood-Schlatter disease. *Knee Surg Relat Res*. 2016;28:62-67.
8. Rosenberg ZS, Kawelblum M, Cheung YY, Beltran J, Lehman WB, Grant AD. Osgood-Schlatter lesion: fracture or tendinitis? Scintigraphic, CT, and MR imaging features. *Radiology*. 1992;185:853-858.
9. Sørensen LB, Rathleff MS, Dean BJJ, et al. A systematic review of imaging findings in patients with Osgood-Schlatter disease. *Transl Sports Med*. 2021;4:772-787.
10. Hirano A, Fukubayashi T, Ishii T, Ochiai N. Magnetic resonance imaging of Osgood-Schlatter disease: the course of the disease. *Skeletal Radiol*. 2002;31:334-342.
11. Holden S, Rathleff MS. Separating the myths from facts: time to take another look at Osgood-Schlatter 'disease'. *Br J Sports Med*. 2020;54:824-825.
12. Gaulrapp H, Nührenbörger C. The Osgood-Schlatter disease: a large clinical series with evaluation of risk factors, natural course, and outcomes. *Int Orthop*. 2022;46:197-204.
13. World Medical Association. World Medical Association Declaration of Helsinki: ethical principles for medical research involving human subjects. *JAMA*. 2013;310:2191-2194.
14. Harris PA, Taylor R, Minor BL, et al. The REDCap consortium: building an international community of software platform partners. *J Biomed Inform*. 2019;95:103208.
15. Harris PA, Taylor R, Thielke R, Payne J, Gonzalez N, Conde JG. Research electronic data capture (REDCap)—a metadata-driven methodology and workflow process for providing translational research informatics support. *J Biomed Inform*. 2009;42:377-381.
16. Ross MD, Villard D. Disability levels of college-aged men with a history of Osgood-Schlatter disease. *J Strength Cond Res*. 2003;17:659-663.
17. Rathleff MS, Holden S, Krommes K, et al. The 45-second anterior knee pain provocation test: a quick test of knee pain and sporting function in 10–14-year-old adolescents with patellofemoral pain. *Phys Ther Sport*. 2022;53:28-33.
18. Roos EM, Roos HP, Lohmander LS, Ekdahl C, Beynnon BD. Knee Injury and Osteoarthritis Outcome Score (KOOS)—development of a self-administered outcome measure. *J Orthop Sports Phys Ther*. 1998;28(2):88-96.
19. Wille N, Badia X, Bonsel G, et al. Development of the EQ-5D-Y: a child-friendly version of the EQ-5D. *Qual Life Res*. 2010;19:875-886.
20. Marshall WA, Tanner JM. Variations in pattern of pubertal changes in girls. *Arch Dis Child*. 1969;44:291.
21. Sørensen LB, Hever M, Wielopolski P, et al. Development and Evaluation of a New Semi-Quantitative Scoring System for Magnetic Resonance Imaging in Adolescents with Osgood Schlatter Disease. 2021.
22. Saily M, Whiteley R, Johnson A. Doppler ultrasound and tibial tuberosity maturation status predicts pain in adolescent male athletes with Osgood-Schlatter's disease: a case series with comparison group and clinical interpretation. *Br J Sports Med*. 2013;47:93-97.
23. Engel A, Windhager R. Der Stellenwert des Ossikels und der Therapie bei M. Osgood-Schlatter. *Sportverletz Sportschaden*. 1987;1:100-108.
24. Holden S, Olesen JL, Winiarski LM, et al. Is the prognosis of Osgood Schlatter- poorer than anticipated? A prospective cohort study with 24-month follow-up. *Orthop J Sports Med*. 2021;9(8):232596712110222. doi:10.1177/23259671211022239
25. Duperron L, Haquin A, Berthiller J, Chotel F, Pialat JB, Luciani JF. Étude d'une cohorte de 30 patients immobilisés avec une résine cruro-malléolaire pour une maladie d'Osgood-Schlatter. *Sci Sports*. 2016;31:323-335.
26. Kujala U, Kvist M, Heinonen O. Osgood-Schlatter's disease in adolescent athletes. Retrospective study of incidence and duration. *Am J Sports Med*. 1985;13(239):236-241.
27. de Flaviis L, Nessi R, Scaglione P, Balconi G, Albisetti W, Derchi LE. Ultrasonic diagnosis of Osgood-Schlatter and Sinding-Larsen-Johansson diseases of the knee. *Skeletal Radiol*. 1989;18:193-197.
28. Kaya DO, Toprak U, Baltaci G, Yosmaoglu B, Ozer H. Long-term functional and sonographic outcomes in Osgood-Schlatter disease. *Knee Surg Sports Traumatol Arthrosc*. 2013;21:1131-1139.
29. Warden SJ, Kiss ZS, Malara FA, Ooi ABT, Cook JL, Crossley KM. Comparative accuracy of magnetic resonance imaging and ultrasonography in confirming clinically diagnosed patellar tendinopathy. *Am J Sports Med*. 2007;35:427-436.
30. Simpson M, Rio E, Cook J. At what age do children and adolescents develop lower limb tendon pathology or tendinopathy? A systematic review and meta-analysis. *Sports Med*. 2016;46:545-557.

SUPPORTING INFORMATION

Additional supporting information can be found online in the Supporting Information section at the end of this article.

How to cite this article: Sørensen LB, Holden S, Oei EHG, et al. A comprehensive MRI investigation to identify potential biomarkers of Osgood Schlatter disease in adolescents: A cross sectional study comparing Osgood Schlatter disease with controls. *Scand J Med Sci Sports*. 2024;34:e14634. doi:10.1111/sms.14634