


**Please cite the Published Version**

Farid, Farzaneh, Haider, Julfikar , Shahab, Marjan Sadeghpour and Rezaeikalantari, Nika (2024) Selecting drill size for post space preparation based on final endodontic radiographs: An in vitro study. *Technology and Health Care*. pp. 1-9. ISSN 0928-7329

**DOI:** <https://doi.org/10.3233/thc-231410>

**Publisher:** IOS Press

**Version:** Accepted Version

**Downloaded from:** <https://e-space.mmu.ac.uk/634449/>

**Usage rights:**  In Copyright

**Additional Information:** This is an author accepted manuscript of an article published in *Technology and Health Care*, by IOS Press.

**Enquiries:**

If you have questions about this document, contact [openresearch@mmu.ac.uk](mailto:openresearch@mmu.ac.uk). Please include the URL of the record in e-space. If you believe that your, or a third party's rights have been compromised through this document please see our Take Down policy (available from <https://www.mmu.ac.uk/library/using-the-library/policies-and-guidelines>)

# Selecting Drill Size for Post Space Preparation Based on Final Endodontic Radiographs: An In Vitro Study

**Running Title: Drill Selection for Post Space Preparation**

**Farzaneh Farid<sup>1</sup>, Julfikar Haider<sup>2</sup>, Marjan Sadeghpour Shahab<sup>3</sup> and Nika Rezaeikalantari<sup>4,5,\*</sup>**

<sup>1</sup>Department of Prosthodontics, School of Dentistry, Tehran University of Medical Sciences, Tehran, Iran. Email: f.farid@yahoo.com

<sup>2</sup>Department of Engineering, Manchester Metropolitan University, Manchester M1 5GD, UK. email: j.haider@mmu.ac.uk

<sup>3</sup>Research Center, School of Dentistry, Tehran University of Medical Sciences, Tehran, Iran. Email: marjan\_psh@yahoo.com

<sup>4</sup>Faculty of Dentistry, Tehran University of Medical Sciences, Tehran, Iran. Email: nika\_rk10@yahoo.com

<sup>5</sup>Dental Research Center, Mazandaran University of Medical Sciences, Sari, Iran

**\*Corresponding author:**

Nika Rezaeikalantari

Email Address: nika\_rk10@yahoo.com

Mailing Address: Bldg No 1, Rahimzadeh Samari Alley, Basiri St, Dr. Shariati Ave, Tehran, Iran

Postal Code: 1949645175

Cellphone: +98 9129218768

**Declarations of competing interest: None**

## **Abstract**

**Background:** For placement of intraradicular posts the intracanal filling material has to be removed. If drills are employed for this purpose, extra widening of the canal, incomplete cracks or root perforation are probable when inappropriate size of drill is used.

**Objective:** This in vitro study assessed the efficacy of radiographs taken after completion of root canal therapy in selecting the appropriate-sized Peeso reamer for post space preparation.

**Methods:** Canals of 53 extracted maxillary and mandibular teeth of different types were cleaned and shaped. Then with acrylic resin 3-dimensional model of the intracanal space of each tooth was fabricated. Next, all canals were filled with gutta-percha and teeth were radiographed buccolingually. Based on these radiographs two observers selected a Peeso reamer that best matched each canal's diameter. The diameter of the selected Peeso reamer was compared to the diameter of the corresponding resin model of each canal by two independent observers and the difference was measured. The data were analyzed by paired sample t-test using SPSS version 22. **Results:** The diameter of the selected Peeso reamers ranged from 0.21mm smaller to 0.12mm larger than the diameter of intracanal spaces. The difference between reamer and resin model was less than 0.1mm in 75% of the cases. **Conclusion:** The result of this study suggests that post-operation endodontic radiographs are reliable means for selecting a size of Peeso reamer that does not encroach on dentinal wall during removal of intracanal filling material and post space preparation.

**Keywords:** Root Canal Therapy; Periapical Radiographs; Peeso Reamer; Post Space Preparation.

## 1. Introduction

Different options are available for restoring endodontically treated teeth from direct restorations<sup>1</sup> to indirect restorations like onlays<sup>2,3</sup>, endocrowns<sup>4</sup> and conventional crowns with or without intracanal posts<sup>5</sup>. Although still there is controversy over the best approach<sup>5,6</sup>, it is generally acknowledged that the capability of the restored root filled tooth to withstand occlusal forces depends on the thickness of the remaining dentin, both coronal<sup>6</sup> and radicular<sup>7</sup>. Also, there is consensus on the placement of intraradicular posts for retaining final restorations in teeth with substantial loss of coronal structure<sup>1-8</sup>.

In order to place post inside a canal, it is necessary to remove the filling material from the intracanal space using heated instruments, chemical solvents, or mechanical instruments that are quickest<sup>9,10</sup>. Rotary instruments should be used carefully because excessive enlargement of the canal could result in weakening, perforation or even fracture of the roots in a tooth that already has lost major part of its coronal structure<sup>11</sup>. Studies have attributed vertical root fracture in endodontically treated teeth to excessive force during obturation of canal or post cementation, wedging effect of spreaders, decrease in dentin thickness and post space preparation<sup>12</sup>. The higher prevalence of vertical root fracture in canals that have received post<sup>13</sup> might be caused by oversized space preparation, damage to root dentin and formation of incomplete cracks or craze lines that develop to vertical fractures under functional loads<sup>9,13</sup>.

To prevent the aforementioned complications, it is highly recommended that no additional dentin should be removed in order to facilitate post placement<sup>14</sup>, the diameter of the prepared post space be one-third of the root diameter at most, and the thickness of residual dentin at apical third not be less than 1 mm<sup>9,11</sup>. Preserving remaining dentin and preventing unwanted events are so important that special drills have been designed for safely removing gutta percha from intracanal space<sup>10,15</sup>. Nonetheless, a drill with a larger diameter than the canal could remove dentin

beyond the safe zone specially at proximal notches or concavities present on the roots<sup>16,17</sup>. Therefore, the selection of an appropriate drill size is very helpful to the survival of the tooth and the success of the treatment<sup>18</sup>.

There are guidelines and recommendations for determining the suitable length and diameter of the intracanal post<sup>11,18,19</sup>. But to the knowledge of authors there is no recommendation in the literature for selecting the size of the drill that is used for the post space preparation. In the clinical practice, one approach is to select the drill according to the average diameter of the canals of each type of the tooth<sup>15</sup> that mandates having all the measurements in mind. Since the diameter of all canals do not exactly match the average value and may change during cleaning and shaping of the canals or retreatments, this method is not completely reliable. Even when prefabricated posts are used, selecting the appropriate size of post and accompanying drill is critical for conservative post space preparation.

The selection might be based on the recommended diameter of post for each root. However, the recommendations of different researchers are not exactly the same<sup>18,20</sup>. For example, Tilk et al studied mandibular and maxillary root widths<sup>18</sup> and used 95% confidence interval to determine minimum and maximum post size for the apical third of post space of each root to recommend optimal diameter of the post. For maxillary central incisors, they indicated a 0.9 to 1.4mm post diameter with 1.1mm to be the optimal size. Yet, Shillingburg et al suggested a post with 1.5mm diameter for the same tooth<sup>20</sup>. The question is which dimension should be adopted and whether one size is applicable for all maxillary central incisors.

It is also advocated to start post space preparation with the smallest drill size and sequentially continue to the largest size that tooth will accept<sup>21</sup>. However, it is not clear up to which size of drill the preparation has to be continued.

Some clinicians always use one or two drill sizes for preparing all canals in any kind of tooth. In these circumstances, if the drill is larger than the actual canal diameter, it

endangers the dentinal wall and if the it is smaller, it would not completely remove the gutta percha from the walls.

During preparation of endodontically treated teeth for restoration, the thickness of coronal dentin can be directly measured or estimated, but the only means for measuring the thickness of radicular dentin and intracanal space is through radiographs. To determine the length to which the reamer will be inserted into the canal, Shillingburg suggested that the largest Peeso reamer that will fit in the obturated canal be measured against a radiograph of the tooth being restored<sup>20</sup>. Similarly, radiographic image can be used for choosing appropriate drill diameter for post space preparation in custom made post/core technique or for the selection of the prefabricated post size as well. Although radiographs only show mesiodistal dimension of the root and its canal, at the cervical and mid root areas most of the canals are either round or oval shaped with larger diameter oriented buccolingually<sup>15, 18</sup>. Only palatal roots of maxillary molars are oval and the largest diameter is in mesiodistal direction<sup>15,18</sup>. Therefore, if a drill fits mesiodistal dimension of a canal on the radiographic image, in round canals it has almost the same breadth and in oval canals it is somehow smaller than the canal. With this approach only gutta percha is removed with minimal amount of dentin. Since the drill remains in confines of the canal, the risk of propagation of cracks initiated during cleaning and shaping of canals is reduced<sup>22</sup>. In cases that prefabricated posts are going to be inserted, this technique helps to have an estimation of the remaining dentin thickness.

The aim of current study was to examine the reliability of radiographic images of endodontically treated teeth for selecting Peeso reamers with the same diameter as intracanal space.

## **2. Materials and Methods**

### ***2.1. Sample collection and preparation***

This study was designed to compare the dimension of a drill selected based on radiographic image of a canal to the resin model of intracanal space. Since Peeso reamers with or without non-cutting tips are one of the most used drills for removing gutta percha<sup>15</sup>, this kind of drills was used in this study and because canals are larger at the cervical third than mid or apical third, the selection was made based on the dimension of middle third specially at the most apical part of post space preparation.

Assuming  $\alpha=0.05$ ,  $\beta=0.2$  and 80% study power, a total of 53 canals in different maxillary and mandibular teeth were examined. The number of each type of tooth was not a variable in this study because comparison was only made between intracanal space and the drill diameter.

Extracted caries free teeth without previous endodontic treatment, internal resorption, morphological disorders or curvature at middle of the root confirmed with radiography, were collected from different clinics in Tehran with agreements from the patients for their use in academic research. The teeth were carefully washed and kept in 0.5% chloramine-T solution for two days. Then, the external debris on the surface of the teeth was removed by ultrasonic scaler and they were stored in normal saline solution for later use.

For ease of handling and taking radiographs, each tooth was embedded up to cemento-enamel junction in a block of acrylic resin. At the next step, the working length of each canal was determined radiographically using the incisal edge of anterior teeth or cusp tip of posterior teeth as coronal reference point. The apical reference was 1mm short of radiographic apex. Standard cleaning and shaping procedures were performed for all the teeth but they remained unobturated.

## ***2.2. Making resin models of intracanal spaces***

In order to measure the diameter of each canal, a resin model was made from intracanal space. For this purpose, a prefabricated polycarbonate dowel (Pinjet, Angelus Indústria de Produtos Odontológicos S/A, Brazil) was placed inside the canal 4 mm short of the determined working length since generally posts do not extend more toward the apex. Next, the dowels were relined with an auto-polymerizing resin (Duralay, Reliance Dental Manufacturing LLC, IL, United States) to take the intracanal form (Fig. 1). In multirooted teeth the same procedure was carried out for the palatal canal of maxillary molars and first premolars, and for the distal canal of mandibular molars.

After completion of this step, the canals were filled with gutta percha (Ariadent, Iran) and AH26 sealer (Dentsply Maillefer, Canada) by lateral condensation technique. Buccolingual post-operation radiographs were taken of all root filled teeth.

### ***2.3. Selection of Peeso reamer***

Two observers (a graduation student of dentistry, and a specialist academic staff) put different sizes of Peeso reamer (Dentsply, Maillefer, Tulsa, Oklahoma, USA) on the post-operation radiograph of each tooth and selected one that best fitted the canal diameter (Fig. 2). next, one of the observers measured the diameter of corresponding resin model of a canal with a vernier (Shinwa Sokutei, Japan) and then with a digital caliper (Guanglu Measuring Instruments Co., Ltd, China) with 0.01mm accuracy (Fig.3). Later the second observer made all measurements with digital caliper. The measurement was made specially near the tip of the model that generally is the narrowest part of the prepared post space. The average of three measurements was determined and was compared to the diameter of selected Peeso reamer. The difference between two values was calculated.

### ***2.4. Statistical analysis***

The data were analyzed using SPSS version 22. The differences between two selected sizes of Peeso reamers were compared using paired sample t test. P values less than 0.05 were considered as significant. The inter-observer and intra-observer agreement were calculated.

## **3. Results**

Both observers chose same size of Peeso reamer for the examined canals. The diameter of the selected Peeso reamers ranged from 0.21 mm smaller to 0.12 mm larger than the corresponding resin model (Fig. 4). The difference was less than 0.1 mm in 75% of the measurements. The maximum difference was 0.21 mm and the minimum difference was 0.00, in six samples. Peeso reamers #1, #2 and #3 were selected for 17 (32%), 29 (54.7%) and 7 teeth (13.2%), respectively (Table 1). The difference between measuring with vernier and digital caliper in 92.45% of samples was less than 0.08mm. The interclass correlation coefficient test showed that with 95% confidence the results of two measurements were very close to each other. The



inter-observer agreement was 96% and their measurements differed around 0.2 mm at most that was not statistically significant ( $p=0.874$ ).

#### **4. Discussion**

In dental practice including endodontic therapy, radiographs perform essential functions in diagnosis, treatment and recall steps<sup>10,23</sup>.

Post space preparation without compromising the structural integrity of root is challenging since the canals are filled and it is not possible to use magnifying devices to see the intracanal space. In this situation, high quality radiographs of filled canals can be very helpful in determining the length and width of the preparation. This study found the endodontic post-operation radiographs efficient and reliable in the selecting a drill size that removes least amount of dentin during post space preparation. As custom-made posts are formed to the shape and dimension of the canal, generally no more enlargement is needed. However, since canals should be shaped according to the form and diameter of prefabricated posts, using special drills, the wear of dentin is inevitable and it is just a matter of quantity. The technique suggested in this study helps to select a prefabricated post that needs less removal of dentin and consequently lower the risk of complications.

Regarding the accuracy of periapical radiographic images, according to Kuyk and Walton the radiographic diameter of canals is a good estimate of their actual diameter<sup>24</sup>. They compared the diameter of canals on radiographic images with their histological diameter and found that in 41% of the samples the radiographic measurement was larger than the histological measurement, identical in 5% and smaller in 54% of the samples<sup>24</sup>. On the other hand, Tilk et al. believe radiographic images could be deceptive since the true mesiodistal dimension of the root cannot be measured if there are concavity on the root wall or superimposition of roots on each other<sup>18</sup>. Raiden et al reported that radiographs show the thickness of residual root dentin around prepared post spaces greater than their actual size<sup>25</sup>. Also, Bunn et al evaluated the accuracy of cone-beam computed tomography 3-dimensional images

and reported an overestimation of the radicular dentin thickness although it was clinically acceptable<sup>26</sup>.

In the present study, the criterion for drill selection was size because regardless of the shape of canal, drills have round cross section. Using a drill larger than the smaller diameter of an oval shaped canal converts it to a more round one. This may help to have a better fit between prefabricated post and canal, however, the dentinal wall becomes thinner.

Selection of a drill size that fits into confines of the canal, follows the philosophy of conservationists in post space preparation<sup>11</sup> by avoiding unnecessary removal of dentin. Although Tilk et al suggested post diameter for each root based on the proportionist philosophy (the width of the post be one third of the width of the root), the selected sizes of drills in the present study were very close to their recommendations, however, smaller than what Shillingburg et al. have recommended<sup>15, 20</sup>. A reason for using larger posts is the strength since larger posts are stronger<sup>11</sup>. It is worth to mention that few manufacturers produce small sizes of prefabricated posts like 0.7mm that is suggested for mandibular incisors by Shillingburg and Tilk et al<sup>15,18,20</sup>. As already mentioned using larger drills in these circumstances increases the risk of stress concentration at the contact site between drill and dentinal wall<sup>9</sup>, leading to incomplete cracks or craze lines that may develop into vertical root fracture. In these circumstances the clinician might decide to use custom made rather than prefabricated posts for restoring the tooth.

Since the purpose of this study was to compare the dimension of selected drills with the dimension of intracanal space, the cross sectioning of roots was neither necessary nor beneficial. With making resin pattern of intracanal space, the drills could be compared to the 3-dimensional model of canal at any point, not just the sectioned areas.

This study was carried out on periapical conventional radiographs because they have good resolution and the Peeso reamers could be easily placed on them. However, it might be considered as a limitation since in recent years the use of

digital radiographs is becoming more and more common among the dentists. The digital technique is faster with no need for processing<sup>27</sup>. There is less radiation to the patient and the images are editable<sup>27</sup>. The suggested method can be used with digital systems if they are properly calibrated. Just the diameter of the canal at any desired point is measured by the ruler option of the equipment and the proper size of the Peeso reamer is selected accordingly.

Although this study was performed on the extracted teeth and the direction of radiation was vertical, and this a limitation for the study, the method can be conveniently utilized in the clinical situations specially when radiographs are taken with parallel technique.

Since the preservation of coronal and radicular dentin has major effect on the survival of the endodontically treated teeth<sup>30</sup>, the presented technique will be very helpful in success of restorations. It is simple, user-friendly and does not cost patients or dentists extra charges or efforts, and is useful for both novices and experienced clinicians.

In future, further studies will be carried out with CT scanned images for obtaining better results.

## **5. Conclusion**

Based on the results of this study, periapical (PA) radiographs taken after completion of root canal therapy can be reliably used to select a Peeso reamer size that conservatively prepares post space and preserves dentin thickness.

## **Declarations**

### **Ethics approval and consent to participate**

Not applicable

All methods were carried out in accordance with relevant guidelines and regulations.

### **Consent for publication**

Identified images or other personal or clinical details of participants are not presented in this manuscript.

### **Availability of data and material**

The experimental data used to support the findings of this study are available from the corresponding author upon request.

### **Competing interests**

The authors declare that they have no competing interests.

### **Funding**

The research did not receive funding from any sources.

### **Acknowledgement**

Not applicable

### **Supplement material**

Data related to impression measurement and drill selection are presented in Supplement.


### **References:**

1. Bhuvva B, Giovarruscio M, Rahim N, Bitter K, Mannocci F. The restoration of root filled teeth: a review of the clinical literature. *Int Endod J*. 2021;54(4):509-35.
2. Carvalho AB, Andrade GS, Tribst JP, Grassi EDA, Ausiello P, Saavedra GS, Bressane A, Melo RM, Borges AL. Mechanical behavior of different restorative materials and onlay preparation designs in endodontically treated molars. *Materials (Basel)*. 2021 Apr 12;14(8):1923.
3. Saratti CM, Rocca GT, Durual S, Lohbauer U, Ferracane JL, Scherrer SS. Fractography of clinical failures of indirect resin composite endocrown and overlay restorations. *Dent Mater*. 2021 Jun;37(6):e341-59.
4. Govare N, Contrepolis M. Endocrowns: A systematic review. *J Prosthet Dent*. 2020 Mar;123(3):411-418.e9.
5. Trushkowsky R. Restoration of endodontically treated teeth: criteria and technique consideration. *Quintessence International*. 2014;45(7):557-67.
6. Ferrari M, Cagidiaco EF, Pontorierco DI, Ercoli C, Chochlidakis K. Survival rates of endodontically treated posterior teeth restored with all-ceramic partial-coverage crowns: When systematic review fails. *Int J Environ Res Public Health*. 2022 Feb 10;19(4):1971.


7. Souza JC, Soares C, Fernandes V, Carvalho O, Silva F, Özcan M, Henriques B. Intraradicular diameter, remnant dentin thickness, and endodontic post to dentin distance: CBCT and microscopic analyses. *Biomed Mater Devices*. 2023, DOI: 10.1007/s44174-023-00088-7
8. Andrade GS, Saavedra GS, Augusto MG, Leon GA, Brandão HC, Tribst JP, Dal Piva AM. Post-endodontic restorative treatments and their mechanical behavior: A narrative review. *Dent Rev*. 2023, 100067.
9. Zuli TA, Guedes OA, Gonçalves GF, da Silva Júnior AR, Borges AH, Aranha AM. Effect of post space preparation drills on the incidence of root dentin defects. *Restor Dent Endod*. 2020 Nov;45(4):e53.
10. Torabinejad M, Walton RE. *Endodontics: principles and practice*. 4<sup>th</sup> ed. China: Saunders, 2009.
11. Lloyd PM, Palik JF. The philosophies of dowel diameter preparation: a literature review. *The Journal of prosthetic dentistry*. 1993;69(1):32-36.
12. Murgel CAF, Walton RE. Vertical root fracture and dentin deformation in curved roots: the influence of spreader design. *Endod Dent Traumatol*. 1990 Dec;6(6):273-8.
13. Rathke A, Frehse H, Hrusa B. Vertical root fracture resistance and crack formation of root canal-treated teeth restored with different post-luting systems. *Odontol*. 2022; 110:719–25.
14. Mannocci F, Bhuva B, Roig M, Zarow M, Bitter K. European society of endodontology position statement: the restoration of root filled teeth. *Int Endod J*. 2021;54:1974-81.
15. Rosenstiel SF, Land MF, Walter RD. *contemporary fixed prosthodontics*. 6<sup>th</sup> ed. India: Elsevier; 2023.
16. Raiden G, Costa L, Koss S, Hernández JL, Aceñolaza V. Residual thickness of root in first maxillary premolars with post space preparation. *J Endod*. 1999;25(7):502-5.
17. Katz A, Wasenstein-Kohn S, Tamse A, Zuckerman O. Residual dentin thickness in bifurcated maxillary premolars after root canal and dowel space preparation. *J Endod*. 2006;32(3):202-5.
18. Tilk MA, Lommel TJ, Gerstein H. A study of mandibular and maxillary root widths to determine dowel size. *J Endod*. 1979;5(3):79-82.
19. Standlee JP, Caputo AA, Hanson EC. Retention of endodontic dowels: Effects of cement, dowel length, diameter, and design. *J Prosthet Dent*. 1978;39(4):401-5.
20. Shillingburg HT, Sather DA, Cain JR, Mitchell DL, Blanco LJ, Kessler JC. *Fundamentals of fixed prosthodontics*. 4<sup>th</sup> ed. USA: Quintessence publishing Co; 2012.

21. Shillingburg HT, Fisher DW, Dewhirst RB. Restoration of endodontically treated posterior teeth. *J Prosthet Dent.* 1970;24(4):401-9.
22. Capar ID, Uysal B, Ok E, Aralan H. Effect of the size of the apical enlargement with rotary instruments, single-cone filling, post space preparation with drills, fiber post removal, and root canal filling removal on apical crack initiation and propagation. *J Endod.* 2015;41:253–6.
23. Boreak N, Hakami A, Hakami S, Nahari H, Alhakami M, Al Dira M, Mahdali H, Kariri, Sultana F. A systematic review of traditional radiology: conservative therapy in endodontics. *Saudi J Oral Dent Res.* 2022 Dec;7(12):317-23.
24. Kuyk JK, Walton RE. Comparison of the radiographic appearance of root canal size to its actual diameter. *J Endod.* 1990;16(11):528-33.A,
25. Raiden G, Koss S, Costa L, Hernández JL. Radiographic measurement of residual root thickness in premolars with post preparation. *J Endod.* 2001;27(4):296-8.
26. Bunn DL, Corrêa M, Dutra KL, Schimd TF, da Silveira Teixeira C, da Fonseca Roberti Garcia L, Bortoluzzi EA. Accuracy of cone-beam computed tomography in measuring the thickness of radicular dentin. *Brazilian Dent J.* 2020;31(5):516-22.
27. Kawamoto Junior LT, Kawamoto WO, Formigoni A, Rodrigues EF, de Arruda Campos IP, Rodrigues SC. Quality comparison of analog and digital x-ray equipment and materials in a dental clinic. *Key Eng Mater.* 2015;660:330-4.
28. Ajmal M, Elshinawy MI. Subjective image quality comparison between two digital dental radiographic systems and conventional dental film. *Saudi Dent J.* 2014;26: 145–50.
29. Butt A, Mahoney M, Savage NW. The impact of computer display performance on the quality of digital radiographs: a review. *Aust Dent J.* 2012;57:(1 Suppl): 16–23.
30. Baba NZ, Goodacre CJ. Restoration of endodontically treated teeth: contemporary concepts and future perspectives. *Endod Topics.* 2014;31:68–83.


## Figures



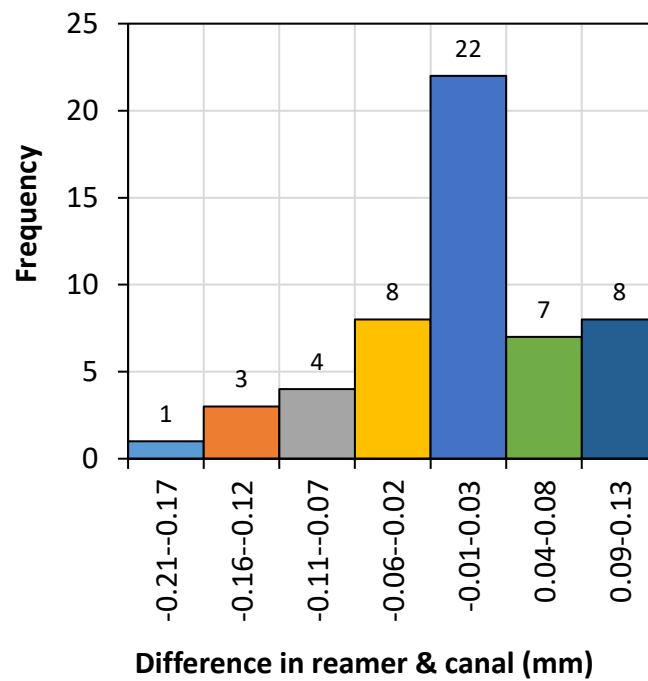
**Fig. 1.** A) determining the working length; B) making a resin impression of intracanal space; and C) filling the root canal.



**Fig. 2.** Superimposing Peeso reamers on the radiograph (A) size #1-just fits (B) size #2-oversized (C) size #3-oversized. Size #1 was selected as the size #2 and #3 surpassed the dentinal wall.



**Fig. 3.** Measuring the diameter of the intracanal resin impression.



**Fig. 4.** Error frequency in difference between the impression and drill diameters.



**Table 1.** Selected Peeso reamer for different teeth.

<b>Tooth type</b>	<b>Upper jaw</b>			<b>Lower jaw</b>		
	Peeso Reamer spec. #1	Peeso Reamer spec. #2	Peeso Reamer spec. #3	Peeso Reamer spec. #1	Peeso Reamer spec. #2	Peeso Reamer spec. #3
Central	1	4	-	2	-	-
Lateral	-	1	-	5	1	-
Canine	1	3	2	1	3	-
Premolar	4	1	-	-	1	1
Molar	2	8	4	1	7	-