

Central Lancashire Online Knowledge (CLoK)

Title	Systematic Analysis of Lower Second Molar Periodontal Health after Autogenous Dentine Graft from Wisdom Tooth Extraction
Type	Article
URL	https://clock.uclan.ac.uk/51301/
DOI	##doi##
Date	2024
Citation	Beaven, Andrew Phillip Richard, Dyer, Peter, Krysmann, Marta orcid iconORCID: 0000-0002-8036-4925, Cook, Neil orcid iconORCID: 0000-0001-9738-9582, Bhatia, Manoj, Ahmed, Waqar orcid iconORCID: 0000-0003-4152-5172 and Barrak, Fadi N orcid iconORCID: 0000-0002-3906-9174 (2024) Systematic Analysis of Lower Second Molar Periodontal Health after Autogenous Dentine Graft from Wisdom Tooth Extraction. <i>Journal of Clinical & Medical Surgery</i> , 4 . ISSN 2833-5465
Creators	Beaven, Andrew Phillip Richard, Dyer, Peter, Krysmann, Marta, Cook, Neil, Bhatia, Manoj, Ahmed, Waqar and Barrak, Fadi N

It is advisable to refer to the publisher's version if you intend to cite from the work. ##doi##

For information about Research at UCLan please go to <http://www.uclan.ac.uk/research/>

All outputs in CLoK are protected by Intellectual Property Rights law, including Copyright law. Copyright, IPR and Moral Rights for the works on this site are retained by the individual authors and/or other copyright owners. Terms and conditions for use of this material are defined in the <http://clock.uclan.ac.uk/policies/>

Research Article

Systematic Analysis of Lower Second Molar Periodontal Health after Autogenous Dentine Graft from Wisdom Tooth Extraction

Andrew Phillip Richard Beaven; Peter Dyer; Marta Krysmann; Neil Cook; Manoj Bhatia; Waqar Ahmed; Fadi Barrak*
School of Medicine and Dentistry, University of Central Lancashire, UK.

*Corresponding Author: **Fadi Barrak**

School of Medicine and Dentistry, University of Central Lancashire, UK.

Email: fnbarrak@uclan.ac.uk

Article Information

Received: Feb 12, 2024

Accepted: Mar 11, 2024

Published: Mar 18, 2024

Archived: www.jclinmedsurgery.com

Copyright: © Barrak F (2024).

Abstract

Introduction: Postoperative complications stemming from lower wisdom tooth extractions are often overshadowed by the immediate need to address pain and existing disease. Nevertheless, an emerging body of evidence suggests the importance of preventing potential periodontal damage to the adjacent second molar resulting from the extraction surgery. To avert periodontal complications involves promoting bone formation within the extracted socket defect. Allogenic and artificial bone, as well as the patient's bone, have conventionally filled the osseous void post-surgery. These approaches are costly and may extend the patient's recovery. An Autogenous Dentine Graft (ADG), derived from the recently extracted wisdom tooth, presents, as a particulate with osteoconductive and osteoinductive properties, is ideal for preserving bone integrity. This review assesses the available evidence supporting the use of ADG in safeguarding against periodontal morbidity resulting from the surgical extraction of a lower third molar.

Materials and methods: A systematic review of the literature was conducted, focusing on the periodontal health of the second molar and the bone height of the osseous defect post-wisdom tooth extraction. Out of 76 identified articles, four studies were selected for the review.

Results: Three months post-surgery, the mean periodontal probing depth distal to the second molar was 4.7mm in control sites and 2.83mm in sites treated with ADG. Over 12 months, the mean bone height exhibited a negative loss of 1.25mm in control sites and a positive gain of 0.9mm in sites treated with ADG.

Conclusion: Presently, there is insufficient evidence to unequivocally support the use of an autogenous dentine graft following the surgical extraction of a wisdom tooth. However, early results are promising, and given the biocompatibility of a material derived from the patient, ADG is considered a safe option for patients at high risk of an osseous defect. Further research is needed to substantiate these findings and guide clinical decision-making.

Keywords: Autogenous dentine graft; Tooth extraction; Periodontal; Wisdom tooth.

Citation: Beaven APR, Dyer P, Krysmann M, Barrak F, et al. Systematic Analysis of Lower Second Molar Periodontal Health after Autogenous Dentine Graft from Wisdom Tooth Extraction. *J Clin Med Surgery*. 2024; 4(1): 1142.

Introduction

The impaction of mandibular third molars (M3) affects a significant portion of the European population, with a prevalence of 58% [1]. Surgical removal of the M3 ranks among the most common procedures in oral surgery, due to factors such as pericoronitis, caries, periodontitis, neoplastic changes, planned orthognathic surgery, and resorption of the adjacent second molar (M2) [2].

To facilitate M3 extraction, bone removal is often necessary, depending on factors such as tooth position, angulation, operator skill, and patient anatomy. However, this procedure can leave a significant bony defect within the mandible, posing a potential threat to the periodontal and bony support of the second molar. Found that in 43.3% of cases [3], the Periodontal Pocket Depth (PPD) at the distal portion of the M2 exceeded 7mm after M3 extraction. Subsequent research by [4] highlighted a 44.4% chance of Intrabony Defects (IBDs) greater than 4mm in individuals over 25 years old.

Early surgical intervention can prevent alveolar bone loss. However, current UK NICE guidelines on wisdom teeth removal adopt a reactive approach, aiming to reduce referrals for asymptomatic impacted wisdom teeth due to funding constraints [5]. This strategy, though seemingly logical, may lead to compromised M2 conditions, yet the financial implications remain unquantified.

Addressing complications associated with M2 post-M3 extraction, studies advocate for using patient-derived bone substitutes, emphasizing the superiority of autogenous grafts over animal or synthetic sources [6]. Despite the disadvantage of requiring a second procedure, autogenous bone grafts, commonly harvested from the mandible or iliac crest, have been a conventional choice. The focus has recently shifted to dentine due to its molecular properties resembling bone, particularly its organic component consisting of 90% type I collagen and non-collagen proteins stimulating mesenchymal stem cells [7].

The Autogenous Dentine Graft (ADG) utilises the recently extracted tooth, eliminating the need for a second procedure. However, its efficacy is limited by the condition of the extracted tooth [8]. Cost-effective and less technique-sensitive, dentine grafts could be applied in both primary and secondary care, potentially reducing post-operative complications for both patients and healthcare providers.

This review aims to assess current literature to answer the research question: Can the periodontal health of a second molar be improved by placing an autogenous dentine graft following the surgical removal of a wisdom tooth? By addressing this question, the review seeks to contribute valuable insights to future guidelines on mandibular third molar extractions.

Material and methods

The methodology of this review adheres to the Preferred Reporting Items for Systematic Reviews and Meta-Analyses (PRISMA) guidelines, as outlined by [9].

To structure the review, a protocol employing the PICO system was devised to address the research question: Can the periodontal health of a second molar be improved following

the surgical removal of a wisdom tooth by the placement of an autogenous dentine graft?

Population (P): Individuals requiring the surgical removal of third molars

Intervention (I): Placement of an Autogenous Dentine Graft (ADG)

Comparison (C): Conventional healing

Outcome (O): Periodontal Probing Depths (PPD) distal of the second molar and the capacity of ADG to stimulate bone formation

To identify relevant literature, an electronic search was conducted using the keywords "Autogenous Dentine Graft". The search was limited to the dentistry category, and four key databases, namely MEDLINE, Dentistry & Oral Sciences, Academic Search Complete, and Cumulative Index of Nursing & Allied Health Literature (CINAHL) Ultimate, were selected through the EBSCO platform.

The research question was deconstructed into five concepts: Mandible, Third molar, Extraction, Dentine graft, and Periodontal. These concepts were linked using Boolean operators, and wildcards were employed for variations in spelling and word truncations.

The literature search included publications in the English language from the last 5 years, encompassing randomized/non-randomized control trials, cohort studies, and case-control studies, aligning with the top half of the evidence pyramid hierarchy [10].

Inclusion criteria encompassed studies where ADG was chair-side produced, uncontaminated bone substitution material, and reported outcomes at least 6 months postoperatively. Exclusion criteria comprised studies involving wisdom teeth removal for tumour resection, use of allogeneic or synthetic grafts, absence of radiological or periodontal findings, and articles with vague or unclear design/methodology.

Outcome variables were defined as Periodontal Probing Depth (PPD) and bone height measured from the cement enamel junction of the second molar. Research titles underwent screening, and abstracts were analysed for patient population and study characteristics, leading to the identification of 4 relevant papers.

Data extraction involved gathering general information, eligibility, population and setting, method, participant characteristics, surgical method, intervention characteristics, control measures, outcome measurement, results, and study quality. A meta-analysis was precluded due to heterogeneous data, small sample sizes, and variations in radiological imaging among studies.

To assess bias, the revised Cochrane risk-of-bias tool for randomised trials (RoB 2) was applied, categorizing studies into "low risk of bias," "some concerns," or "high risk of bias" across five domains. Additionally, the 2011 Oxford Centre for Evidence-Based Medicine (OCEBM) table was utilized to rank literature by study design.

Mean and Standard Deviation (SD) figures from all studies were compiled in a database. For studies lacking SD, the formula ($SE=SD/\sqrt{n}$) was applied, where n represents the sample size. When studies measured bone height from multiple points, the data was amalgamated into a single mean, allowing the calculation of a pooled SD using Cohen's formula. Raw data from studies presenting only means were calculated for both mean and SD and are presented in this review.

Results

A comprehensive search across four databases - MEDLINE (32 titles), Dentistry & Oral Sciences (25 titles), Academic Search Complete (8 titles), and CINAHL Ultimate (11 titles) - yielded a total of 76 titles. Following the elimination of duplicates, 42 unique records underwent screening of titles and abstracts. This screening resulted in the removal of 33 papers, leaving nine papers identified for full retrieval and examination.

Upon thorough examination, five manuscripts failed to meet the selection criteria, resulting in a final inclusion of four papers for this review. The entire search process and outcomes are visually presented in the flow chart depicted in Figure 1. This systematic approach ensures a robust selection of literature aligning with the review's objectives.

A total of four articles were included in this review, exclusively comprising randomized control trials. The selected studies uniformly adopted a split-mouth design, wherein both lower wisdom teeth necessitated extraction. One socket was designated for the intervention, while the other served as the comparison or control. Notably, [11] introduced an additional dimension to their study by incorporating two patients requiring the removal of only one wisdom tooth, thereby diversifying the demographic pool.

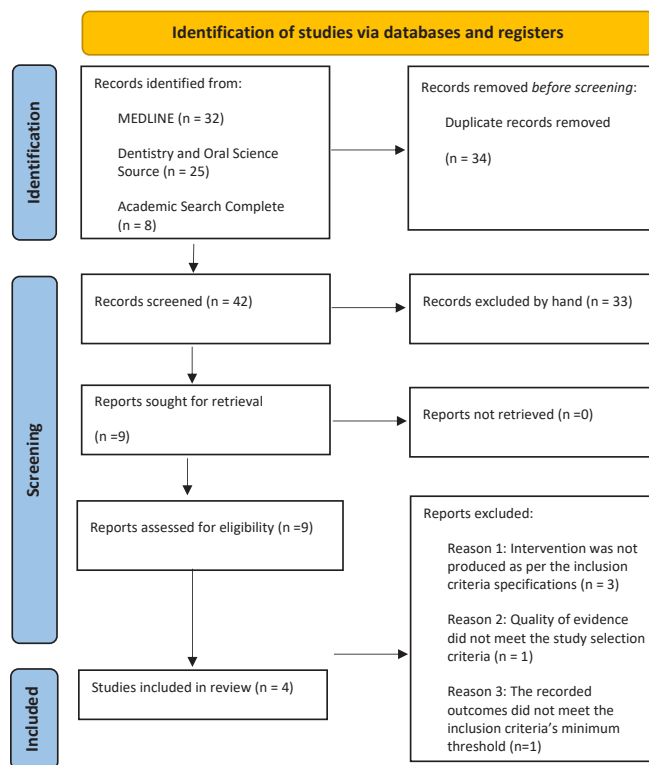


Figure 1: PRISMA flow chart detailing the search process.

These selected articles spanned publication dates from 2020 to 2022 and collectively encompassed 84 extractions. For a succinct overview of the studies (Table 1). This focused inclusion strategy ensures the incorporation of high-quality evidence from randomized control trials, contributing to the robustness of the review's findings.

Table 1: Summary of four articles reviewed.

Author	Year	Study design	OCEBM level of evidence	No. of participants	No. of extractions	Split mouth / unilateral	Manufacture of tooth grinder
Kuperschlag et al. [11]	2020	RCT	2	13	24	Both	-
Mazzucchi et al. [12]	2022	RCT	2	10	20	Split mouth	Smart Dentin Grinder™
Sánchez et al.	2020	RCT	2	15	30	Split mouth	Smart Dentin Grinder™
Wushou et al. [13]	2022	RCT	3	5	10	Split mouth	BonMaker®
Total				43	84		
Mean				10.75	21		

All the studies incorporated a full thickness flap design for their surgical access, ensuring a standardized approach across the board. Noteworthy differences emerged in the size of particulate materials used, with studies employing the Smart Dentin Grinder generally yielding smaller particles compared to those using the BonMaker.

In terms of postoperative care, all reviewed trials routinely administered antibiotics after the extraction, except for the study conducted by Sánchez et al. This practice contrasts with the current guidelines of the National Institute for Health and Care Excellence (NICE) in the UK, which advises against routine antibiotic use post-extraction. The existing evidence suggests that such a regimen has minimal impact on bone remodelling and may pose a greater risk of adverse reactions, such as anaphylaxis [14].

One notable departure from the common practice was observed in the study by Kuperschlag et al (2020) [11], where a chlorhexidine mouth rinse was administered before surgery. While there is some evidence supporting its potential to reduce the occurrence of alveolar osteitis, its efficacy in promoting bone healing remains inconclusive [15].

For a comprehensive overview of the surgical specifications of each study, refer to Table 2, while Table 3 provides details regarding the duration of the procedures and the assessment of outcomes. These nuanced variations in procedural approaches underscore the importance of understanding the diverse methodologies employed across the studies included in this review.

Table 2: Summary of surgical considerations.

Author	Presurgical rinse	Mucoperiosteal flap design	Size of particulate	Additional materials used	Antibiotics
Kuperschlag et al 2020 [11]	Yes – 0.2% Chlorohexidine	Full thickness -Triangular		Yes - gelatine sponge	Antibiotics given amoxicillin for 5 days
Mazzucchi et al 2022 [12]	No	Full thickness -Triangular	300 –1200 µm	No	Antibiotics given co-amoxiclav for 6 days
Sánchez et al 2020	No	Full thickness - Envelope	300 –1200 µm	Yes - gelatine sponge	Antibiotics not routinely given
Wushou et al 2022 [13]	No	Full thickness -Triangular	425 –1500 µm	Rubber drainage strip	Antibiotics given

Table 3: Measurement of Outcomes and Duration of Each Trial.

Author	Kuperschlag et al. [11]	Mazzucchi et al. [12]	Sánchez et al.	Wushou et al. [13]
Start date	-	-	September 2018	May 2021
End date	-	-	September 2019	-
Duration of participation	12 months	6 months	6 Months	6 months
Periodontal pocketing of the lower 2 nd molar	Probing depths taken pre-op, 3 and 12 months after surgery and measured in millimetres.	Probing depths taken pre-op, 3 and 6 months after surgery and measured in millimetres. Measurements taken from three pocket locations: Disto-buccal, Mid-distal, Disto-lingual	Probing depths taken pre-op, 3 and 6 months after surgery and measured in millimetres. Measurements taken from three pocket locations: Disto-buccal, Mid-distal, Disto-lingual	Probing depths taken pre-op and 6 months after surgery and measured in millimetres.
Radiographic interpretations	Pre op OPG 12 months Post op OPG Bone loss in millimetres.	Pre op PA 6 Month post op PA Bone loss in millimetres. Measurement from CEJ to the bone peak.	Cone beam computed tomography used at 6 months to compare both sites. Measurement from IAN to bone crest.	Pre and post op OPG

Table 4: Risk of Bias Tool Version 2 for Periodontal Probing Depth

	D1	D2	D3	D4	D5	Overall
Kuperschlag et al 2020 [11]						
Mazzucchi et al 2022 [12]						
Sánchez et al 2020						
Wushou et al 2022 [13]						
	Low risk		Some concerns		High risk	

To ensure a comprehensive assessment of potential bias, the second iteration of the ‘Risk of Bias’ tool from the Cochrane Collaboration was employed to scrutinize all four papers, focusing on both reviewed outcomes.

This assessment considers five key domains:

Domain 1. Randomisation process

Domain 2. Deviations from the intended interventions

Domain 3. Missing outcome data

Domain 4. Measurement of the outcome

Domain 5. Selection of the reported result

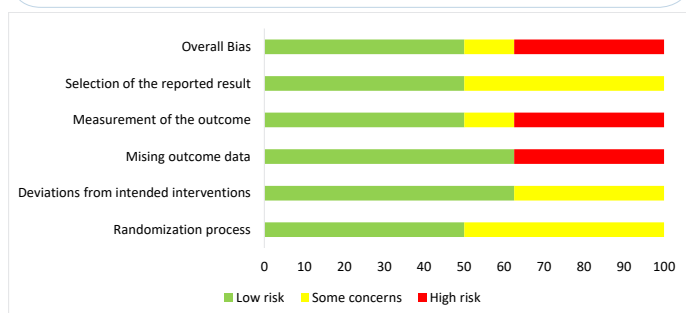
Regarding the evaluation of bias in measuring the periodontal probing depth outcome, the results varied across the studies. Two studies were classified as having a ‘low risk’ of bias, one displayed ‘some concerns,’ and one was deemed ‘high risk,’ as delineated in Table 4.

Specifically, Mazzucchi et al (2022) [12] and Sánchez et al (2020) exhibited a ‘low risk’ across all domains, indicating a ro-

Table 5: Picture summary of risk of bias tool version 2 for bone height.

Authors	D1	D2	D3	D4	D5	Overall
Kuperschlag et al 2020 [11]	!	+	+	!	+	!
Mazzucchi et al 2022 [12]	+	+	+	!	+	!
Sánchez et al 2020	+	+	+	+	+	+
Wushou et al 2022 [13]	!	!	-	-	!	-
	+ Low risk		! Some concerns		- High risk	

Table 6: Bar Graph of Risk of Bias Tool Version 2 for all Assessed Outcomes.



bust methodological approach. Conversely, Wushou et al demonstrated ‘some concerns’ or ‘high risk’ in all domains, signifying potential limitations in the study design and implementation. These insights into bias considerations enhance the interpretability of the findings and reinforce the importance of critically appraising the methodological quality of the included studies.

To comprehensively evaluate potential bias in the assessment of bone height distal to the second molar, the Cochrane ‘Risk of Bias’ tool was applied. The findings are summarized in Table 5 and provide insights into the methodological robustness of the included studies. The assessment encompasses the same five domains as mentioned earlier.

Among the studies reviewed, one was classified as having a ‘low risk’ of bias, two exhibited ‘some concerns,’ and one was categorized as ‘high risk.’ Notably, Sánchez et al (2020) emerged as the sole study demonstrating ‘low risk’ across all domains, indicating a robust methodological approach. Conversely, Wushou et al (2022) [13] exhibited concerns or ‘high risk’ in all domains, suggesting potential limitations in the study design and execution. These insights into bias considerations add depth to the interpretation of outcomes, emphasizing the importance of critically appraising the methodological quality of studies assessing bone height distal to the second molar.

The studies reviewed had an overall low risk in 50% of the domains. In the domain of missing outcome and measurement of the outcome, 37.5% of the papers reviewed were of high risk. A summary of all domains is portrayed in table 6.

All included studies employed a split-mouth design, where each patient received both the interventional and control treatments through the extraction of lower left and right third molars. This methodological approach, while acknowledging the inherent variability in each extraction, effectively controlled external and internal environmental factors that could potentially influence the results. Despite the individualized nature of each extraction, this design enhances the internal validity of the studies.

Limited evidence in this field can be attributed to the recent development of Autogenous Dentine Graft (ADG) techniques. Consequently, high-quality evidence in the form of robust studies is constrained. This limitation underscores the need for cautious interpretation of positive results, urging clinicians to await larger trials before considering the widespread adoption of tooth grinding machines in their practices.

Across all four studies, a consensus emerged that periodontal probing depths were reduced when ADG was employed. However, the magnitude of the difference between the test and control groups varied significantly between studies. Notably, Kuperschlag et al (2020) [11] achieved the most pronounced intervention success, with periodontal pockets differing by an average of 3.3mm between the two groups at the one-year review. In contrast, Mazzucchi et al (2022) [12] reported positive results, but the difference was only 0.6mm after 6 months. A statistical analysis by Mazzucchi et al revealed significance only at the 3-month review, unlike the other studies, which identified a statistically significant difference in favour of ADG in every review period.

Table 7 provides a comprehensive summary of the results for all studies, depicting the periodontal probing depths of the second molar. The mean periodontal probing depth distal to the M2 was 2.83mm when using ADG compared to 4.7mm at the control site, indicating a 66% reduction in the periodontal pocket on average at the 3-month review.

Between 6 to 12 months, the control site exhibited an average reduction of 0.07mm, while the intervention site saw a further reduction of 0.03mm in the periodontal pocket. This suggests that most of the healing occurs within the initial three months for both ADG and control sites. These nuanced findings contribute valuable insights into the temporal dynamics of periodontal healing post-ADG intervention.

Table 7: Periodontal probing depth results summary.

	Kuperschlag et al 2020 [11]		Mazzucchi et al 2022 [12]		Sánchez et al 2020		Wushou wt al 2022 [13]	
	Control	Test	Control	Test	Control	Test	Control	Test
Pre surgery mean (SD)	-	-	4.60mm (1.67)	4.53mm (1.13)	5.92mm	5.97mm	3.50mm	3.16mm
3 month mean (SD)	4.00mm (0.853)	1.31mm (0.751)	4.20mm (1.03)	3.06mm (1.08)	6.00mm	4.12mm	-	-
6 month mean (SD)	-	-	3.76mm (1.04)	3.16mm (0.98)	5.68mm	4.10mm	-	-
12 month mean (SD)	4.45mm (0.954)	1.15mm (0.801)	-	-	-	-	-	-
Statistical significance	Yes: P<0.001		No: Pre surgery P=0.368 6 months P=0.065 Yes: 3 months P<0.033		Yes: P=0.038		-	

Table 8: Radiographic results for bone height.

	Kuperschlag et al 2020 [11]		Mazzucchi et al 2022 [12]		Sánchez et al 2020		Wushou wt al 2022 [13]	
	Control	Test	Control	Test	Control	Test	Control	Test
Pre surgery mean (SD)	-	-	-2.09mm (0.43)	-2.03mm (0.56)	-	-	-	-
6 months mean (SD)	-	-	-0.96mm (0.33)	-0.62mm (0.58)	-	-	-	-
12 months mean (SD)	-4.20mm (1.2)	-1.05mm (0.91)	-	-	-	-	-	-
Bone gain	-	-	1.13mm (0.41)	1.41mm (0.87)	-0.68mm	0.54mm	-	-
Bone density at 6 months	-	-	-	-	1122.26 HU	1538.93 HU	-	-
Statistical significance	Yes: P<0.001		No: Pre surgery P=0.368 6 months P=0.065 Yes: 3 months P<0.033		Yes: P=0.038		-	

Across all four studies, both Autogenous Dentine Graft (ADG) and conventional healing were associated with an increase in bone height. However, the gain in bone height was consistently greater in sites treated with ADG. Statistical significance in favour of the intervention was observed in two papers, while the other two suggested that ADG might be beneficial for bone formation.

The combined mean results revealed a positive gain of 0.9mm of bone in sites treated with ADG up to 12 months, whereas sites undergoing conventional healing experienced a subsequent loss of 1.25mm of bone. This significant difference of 2.15mm corresponds to an additional 16% of bony coverage when utilizing ADG, relative to the average length of a distal root of the second molar (13.35mm).

Sánchez et al (2020) and Mazzucchi et al (2022) [12] reported a positive crestal bone height gain exceeding 0mm. This suggests that the removal of the wisdom tooth improved bone height to a level superior to that before the surgery. This observation can be attributed to the common mesial or horizontal impaction of wisdom teeth, potentially influencing pre-surgery bone height, as bone does not adhere to enamel surfaces of a crown.

While bone density data was recorded in only one study, it yielded a statistically significant result (P<0.001). The Hounsfield (HU) range for average bone density typically varies between 300 to 3000 [16]. As detailed in Table 8, Sánchez et al (2020) reported a notable 37% increase in bone density when using ADG, compared to conventional healing, at the 6-month

review. This finding provides valuable insights into the potential benefits of ADG in enhancing bone density, complementing the radiographic evidence of increased bone height.

Discussion

This systematic review critically evaluated the efficacy of Autogenous Dentine Grafts (ADG) in promoting bone regeneration following the extraction of mandibular third molars (M3). Traditionally, extracted teeth were regarded as biomedical by-products and often discarded as clinical waste. However, advancing insights into bone remodelling have led to the recognition of extracted teeth as potential sources for generating bone. Notably, bone mineral density is crucial for periodontal health, suggesting a potential connection between bone and periodontium health. The American Association of Oral and Maxillofacial Surgeons recommends bone grafts for patients at an increased risk of osseous defects post-extraction. In contrast, current UK guidelines lack explicit recommendations for graft placement following M3 extraction, possibly due to historical cost constraints associated with synthetic or animal-derived grafts. Further research may position ADG as a routine post-extraction step, addressing postoperative periodontal complications and future-proofing bone for potential implant procedures.

Traditional autogenous grafts sourced from the patient typically involve a second procedure or an extended post-operative healing process. Utilizing components from extracted teeth circumvents the need for a second procedure and proves to be cost-effective compared to alternative grafts.

The positive outcomes observed across all reviewed articles align with the theme of ADG demonstrating efficacy in both observed outcomes. The limited evidence available raises the possibility of publication bias, where studies indicating detrimental effects of the intervention may not be publicized, potentially influenced by manufacturers of tooth grinding machines.

Notably, power calculations were lacking in most studies, except in Sánchez et al (2020), who recommended a minimum of 10 patients for both the intervention and control groups to generate statistically relevant evidence. The absence of power calculations increases the risk of type I and type II errors within a study. Nevertheless, three out of four studies in this review adhered to Sánchez et al's proposed number of patients.

Given that significant bone dimensional changes occur within the first three months post-standard extraction, extending the observation period to a minimum of 12 months in future studies would provide a more comprehensive understanding of the long-term effects of ADG on bone remodelling.

The split-mouth design employed in the reviewed studies, while minimizing external factors affecting results, revealed individual variations in tooth characteristics. While three articles assessed the difficulty of wisdom tooth extraction, they did not explore how surgical bone removal might impact the body's ability to undergo osteogenesis in severe bone defects. Random assignment of the intervention may have mitigated this confounding factor, but the importance of bone regeneration in severe defects was not emphasized in the reviewed papers.

Combining results demonstrated a mean periodontal probing depth distal to the second molar of 2.83mm with ADG, indicating healthy periodontal tissue per British Society of Periodontology standards. In contrast, the control group exhibited mean periodontal probing depths exceeding 4.7mm, indicative of a compromised periodontium requiring professional intervention. The nearly 2mm average difference equates to a remarkable 66% improvement in periodontal pocket depth with ADG.

Additionally, the combined evidence suggested a positive gain of 0.9mm of bone within the osseous defect with ADG, compared to a negative loss of 1.25mm at the control site. This indicates that ADG enhanced the area beyond its pre-surgery state. The 2.15mm average difference, corresponding to 16% of the distal root surface of the second molar, could potentially impact the staging and grading of a patient's periodontal condition according to the British Society of Periodontology classification system. This potential reclassification may offer the opportunity for more effective hygienic therapy.

Dental Cone Beam Computer Tomography (CBCT) was underutilized in the literature, with most studies relying on two-dimensional methods. Future trials assessing ADG could benefit from three-dimensional analysis to ensure more accurate recording of bone formation and minimize measurement bias.

Considering the potential influence of ethnicity on bone structure and density, the lack of participant ethnicity data in the reviewed studies raises concerns about limited representation and potential statistical distortions. Additionally, the geographic bias in publications, predominantly from Europe, may further impact the generalizability of results.

Given the nature of the intervention, ensuring both patients and researchers remain unaware of the treated socket presents

challenges. The additional time required for ADG procedures may influence patient confidence in identifying the treated socket, potentially introducing the Hawthorne effect where patient behaviour changes due to observation, impacting the success or failure of the intervention.

As consumer awareness grows, the origin and development of materials used in medical procedures, including dentistry, become significant considerations for patients. ADG offers an alternative to allografts and xenografts, avoiding foreign body interactions and poor biocompatibility associated with certain bone substitutes. The historical use of bovine bone substitutes like Bio-Oss highlighted issues of poor integration and disrupted healing, emphasizing the potential advantages of ADG in augmenting osseous defects, protecting soft bone, and aiding wound healing without compromising patients or practitioners financially.

Conclusion

Autogenous dentine grafts emerge as a potential solution in scenarios where the periodontal health of the second molar (M2) is at risk following the surgical extraction of the mandibular third molar (M3). High-risk cases, such as severely impacted M3s or instances requiring excessive bone removal, may particularly benefit from ADG. While early studies on ADG show promise, the current limitations in available evidence warrant further research with larger participant cohorts to establish the justification for integrating ADG into primary care settings.

Given the existing constraints, future studies should extend their observations over a standard bone remodeling timespan, ideally 12 months, to ensure a more comprehensive understanding of the long-term effects of ADG. Additionally, the potential for increased measurement accuracy of bone gain could be realized by employing Cone Beam Computed Tomography (CBCT) over traditional two-dimensional imagery. This technological advancement could enhance the precision of assessing bone regeneration and contribute to the overall reliability of study findings.

In conclusion, while the initial findings are encouraging, the application of autogenous dentine grafts in routine clinical practice requires further substantiation through extensive research and a meticulous evaluation of long-term outcomes.

References

1. Carter K, Worthington S. Predictors of third molar impaction: a systematic review and meta-analysis. *Journal of dental research*. 2016; 95(3): 267-276.
2. Passarelli PC, Pasquantonio G, D'Addona A. Management of surgical third lower molar extraction and postoperative progress in patients with factor VII deficiency: A clinical protocol and focus on this rare pathologic entity. *Journal of Oral and Maxillofacial Surgery*. 2017; 75(10): 2070-e1.
3. Kugelberg CF, Ahlström U, Ericson S, Hugoson A. Periodontal healing after impacted lower third molar surgery: a retrospective study. *International journal of oral surgery*. 1985; 14(1): 29-40.
4. Kugelberg CF. Periodontal healing two and four years after impacted lower third molar surgery: A comparative retrospective study. *International journal of oral and maxillofacial surgery*. 1990; 19(6): 341-345.
5. Gadiwalla Y, Moore R, Palmer N, Renton T. Where is the 'wisdom' in wisdom tooth surgery? A review of national and international third molar surgery guidelines. *International Journal*

-
- of Oral and Maxillofacial Surgery. 2021; 50(5): 691-698.
6. Serafini G, Lollobrigida M, Fortunato L, Mazzucchi G, Lamazza L, et al. Postextractive alveolar ridge preservation using L-PRF: Clinical and histological evaluation. *Case reports in dentistry*. 2020.
 7. Sampath TK, Reddi AH. Discovery of bone morphogenetic proteins—A historical perspective. *Bone*. 2020; 140: 115548.
 8. Gual-Vaqués P, Polis-Yanes C, Estrugo-Devesa A, Ayuso-Montero R, Marí-Roig A, et al. Autogenous teeth used for bone grafting: A systematic review. *Medicina oral, patologia oral y cirugía buccal*. 2018; 23(1): e112.
 9. Page, M.J, Moher, D, Bossuyt, P.M, Boutron, I, Hoffmann, T.C, Mulrow, C.D, Shamseer, L, Tetzlaff, J.M, Akl, E.A, Brennan, S.E. and Chou, R, (2021). PRISMA 2020 explanation and elaboration: updated guidance and exemplars for reporting systematic reviews. *bmj*, 372.
 10. Trombelli, L, Farina, R, Marzola, A, Bozzi, L, Liljenberg, B. and Lindhe, J, (2008). Modeling and remodeling of human extraction sockets. *Journal of clinical periodontology*. 2008; 35(7): pp.630-639.
 11. Kuperschlag A, Keršytė G, Kurtzman GM, Horowitz RA. Autogenous Dentin Grafting of Osseous Defects Distal to Mandibular Second Molars After Extraction of Impacted Third Molars. *Compendium of Continuing Education in Dentistry (Jamesburg, NJ: 1995)*. 2020; 41(2): 76-82.
 12. Mazzucchi G, Lollobrigida M, Lamazza L, Serafini G, Di Nardo D, et al. Autologous Dentin Graft after Impacted Mandibular Third Molar Extraction to Prevent Periodontal Pocket Formation-A Split-Mouth Pilot Study. *Materials*. 2022; 15(4): 1431.
 13. Wushou A, Zheng Y, Han Y, Yang ZC, Han FK. The use of autogenous tooth bone graft powder in the treatment of osseous defects after impacted mandibular third molar extraction: a prospective split-mouth clinical pilot study. *BMC Oral Health*. 2022; 22(1): 1-6.
 14. Lodi G, Azzi L, Varoni EM, Pentenero M, Del Fabbro M, et al. Antibiotics to prevent complications following tooth extractions. *Cochrane Database of Systematic Reviews*. 2021; 2.
 15. Brunello G, Becker K, Scotti L, Drescher D, Becker J, et al. The effects of three chlorhexidine-based mouthwashes on human osteoblast-like SaOS-2 cells. An in vitro study. *International Journal of Molecular Sciences*. 2021; 22(18): 9986.
 16. Kim KJ, Kim DH, Lee JI, Choi BK, Han IH, et al. Hounsfield units on lumbar computed tomography for predicting regional bone mineral density. *Open medicine*. 2019; 14(1): 545-551.