

Central Lancashire Online Knowledge (CLoK)

Title	Pathogenesis and A Practical Guide to the Management of Steven-Johnson Syndrome & Toxic Epidermal Necrolysis
Type	Article
URL	https://clock.uclan.ac.uk/50790/
DOI	##doi##
Date	2024
Citation	Al Abadie, Mohammed, Sharara, Zinah, Tukmatchy, Hussain, Al-Rubaye, Mohammed, Al Abadie, Sami and Kubba, Faris (2024) Pathogenesis and A Practical Guide to the Management of Steven-Johnson Syndrome & Toxic Epidermal Necrolysis. Medical & Clinical Research . ISSN 2577-8005
Creators	Al Abadie, Mohammed, Sharara, Zinah, Tukmatchy, Hussain, Al-Rubaye, Mohammed, Al Abadie, Sami and Kubba, Faris

It is advisable to refer to the publisher's version if you intend to cite from the work. ##doi##

For information about Research at UCLan please go to <http://www.uclan.ac.uk/research/>

All outputs in CLoK are protected by Intellectual Property Rights law, including Copyright law. Copyright, IPR and Moral Rights for the works on this site are retained by the individual authors and/or other copyright owners. Terms and conditions for use of this material are defined in the <http://clock.uclan.ac.uk/policies/>

Pathogenesis and A Practical Guide to the Management of Steven-Johnson Syndrome & Toxic Epidermal Necrolysis

Mohammed Al Abadie¹, Zinah Sharara², Hussain Tukmatchy², Mohammed Al-Rubaye², Sami Al Abadie³, Faris Kubba⁴

¹North Cumbria Integrated Care NHS Foundation Trust, Clinical Director & Consultant Dermatologist.

²National Health Service (NHS), Community Dermatology Clinics (Health Harmonie), United Kingdom.

³Royal School of Wolverhampton, United Kingdom.

⁴Department of Pathology, Ealing Hospital, London North West University Healthcare NHS Trust.

*Corresponding Author

Professor Mohammed Al Abadie PhD, FRCP, Department of Dermatology, North Cumbria Integrated NHS Care Foundation and UCLAN Medical School, United Kingdom.

Submitted: 23 Dec 2023; Accepted: 10 Jan 2024; Published: 09 Feb 2024

Citation: Al Abadie M, Sharara Z, Tukmatchy H, Al-Rubaye M, Al Abadie S, Kubba F (2024). Pathogenesis and A Practical Guide to the Management of Steven-Johnson Syndrome & Toxic Epidermal Necrolysis. *Medical & Clinical Research*, 9(2), 01-03.

Keywords: Toxic Epidermal Necrolysis, Steven Johnson Syndrome, Secondary Infections, Cytotoxic T Cells, HLA Alleles

Introduction

Steven Johnson Syndrome (SJS) and Toxic Epidermal necrolysis are rare dermatological emergencies that are associated with a high degree of morbidity and mortality [1]. They are considered to be severe blistering conditions that portray an image of diffuse epidermal necrolysis in association with sloughing of the skin. SJS and TEN are effectively the same disease with the main difference being the percentage of body surface area involved. It is widely accepted that SJS belongs to the below 10% body surface area category and TEN to the more than 30% category. A Steven Johnson syndrome and Toxic Epidermal Necrolysis overlap exists when the body surface area affected is between 10 percent and 30 percent [2]. The causes of both conditions within this spectrum are most likely drug related, however certain infections can also trigger SJS/TEN but this is less likely. In a substantial number of cases the cause is idiopathic [3]. The main grading system is the SCORTEN criteria, which can also provide more information regarding prognosis and mortality [4]. Management of this condition is highly controversial with no clear guidelines but there is a wide agreement that patients should be managed in a burns unit with intravenous fluids and protection from secondary infections. Stopping all medications and investigating for the cause is important unless there is clear benefit from any single medication.

Pathogenesis

Solid evidence suggests that SJS/TEN is associated with defective capacity to eliminate drug metabolites, when an immune response can initiate the cellular events after reacting with these

drug metabolites [5]. There is also drug related HLA alleles that was identified as major susceptibility and high risk genes for development of SJS/TEN [6,7]. Moreover drug specific cytotoxic T cells are seen early in the development of cutaneous lesions, as well as IL -6, TNF- α , Interferon γ , IL-8 and Fas ligand (FasL) [8], and their presence can contribute to the constitutional symptoms [9].

Clinical Features and Diagnosis

As previously mentioned, Steven Johnson syndrome and Toxic Epidermal necrolysis are more or less the same spectrum but differentiated through the percentage of body surface area involved. The majority of cases present with a prodromal phase that includes fever, fatigue, malaise and generally feeling unwell [10]. This then progresses rapidly to widespread erythematous areas with pale dusky appearances, purpura and blistering associated with areas of epidermal detachment. The mucosal surfaces are almost always affected and this is an important diagnostic clue to guide the clinician [11]. Diagnosis can be confirmed with skin biopsy and this is helpful in excluding other blistering conditions such as staphylococcal scalded skin syndrome and pemphigus vulgaris. The epithelium and epidermis show spongiosis and various degrees of necrosis, frequent apoptotic keratinocytes, subepidermal clefting and basal hydropic degeneration. The dermis shows superficial perivascular lymphocytic infiltrate, superficial odema and sometimes eosinophilic infiltrate (Figure 1).

Once the diagnosis is confirmed it is important to calculate the

SCORTEN criteria, as this will be helpful in establishing the likelihood of survival and the severity of the condition. There are 7 elements that determine the SCORTEN criteria and these are as follows:

1. Age more than or equal to 40 years (1 point)
2. Associated malignancy (1 point)
3. Heart rate more than or equal to 120 beats per minute (1 point)
4. Percentage of body surface area detachment (epidermal detachment) >10% (1 point)
5. Serum bicarbonate 14 mmol/L (1 point)
6. Serum Urea >10 mmol/L (1 point)
7. Serum Urea >10 mmol/L (1 point)

Risk factors	Associated mortalities
0-1	3.2%
2	12.1%
3	35.35%
4	58.3%
5	>90%

Table 1: The mortality increases with higher scores of SCORTEN criteria.

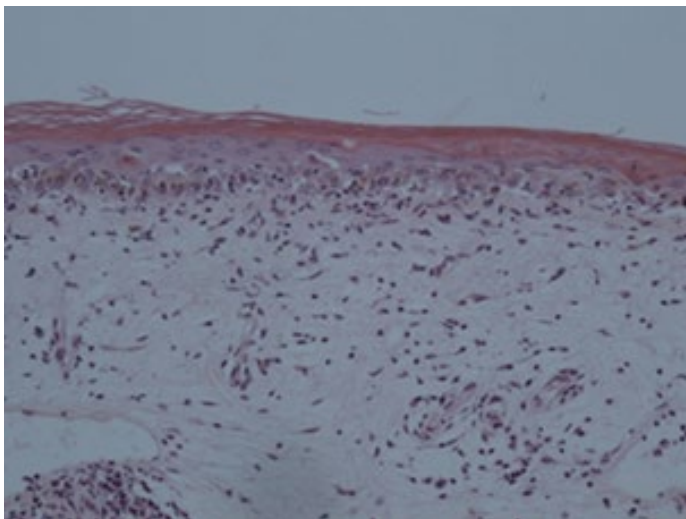


Figure 1: Erythema multiforme showing apoptotic keratinocytes and hydropic degeneration of the stratum basale.

Management

The majority of cases of SJS/TEN are induced by drugs therefore a thorough investigation into the medication history is paramount. The most common culprits are antibiotics (especially beta-lactam antibiotics), allopurinol, Nevirapine, anti-epileptics, Non-steroidal anti-inflammatory drugs and biological agents like Nivolumab [5]. The cause is not found or idiopathic in a substantial number of cases and in a small minority an infectious disease can be a trigger with the most common being Mycoplasma Pneumonia [3,5]. There are no clear guidelines for the management of this spectrum of severe blistering disease but it is widely accepted to manage the patient in a burns unit or an intensive therapy unit if the former is not available with. Strict fluid and electrolyte management

and stopping the culprit medication if found. Non-adherent dressings are helpful and the room should be kept warm to avoid hypothermia. Preventing secondary infections is pivotal and if present prompt treatment with antibiotics is necessary. Enteral or Parenteral feeding should be started with intravenous fluids. There has been variable success with combinations of corticosteroids, intravenous immunoglobulin, cyclosporine and tumour necrosis factor alpha receptor inhibitors but clear management guidelines and evidence based approaches are lacking [12].

Acknowledgement

Hannah Evans, thank you for preparation of Manuscript.

References

1. Hsu DY, Brieva J, Silverberg NB, Silverberg JI (2016) Morbidity and mortality of Stevens-Johnson syndrome and toxic epidermal necrolysis in United States adults. *J Investigative Dermatol* 136(7):1387-1397.
2. Bastuji-Garin S, Rzany B, Stern RS, Shear NH, Naldi L, et al. (1993) Clinical classification of cases of toxic epidermal necrolysis, Stevens-Johnson syndrome, and erythema multiforme. *Archives of Dermatol* 129(1):92-96.
3. Schneider JA, Cohen PR (2017) Stevens-Johnson Syndrome and Toxic Epidermal Necrolysis: A Concise Review with a Comprehensive Summary of Therapeutic Interventions Emphasizing Supportive Measures. *Adv Ther* 34:1235-1244.
4. Torres-Navarro I, Briz-Redón Á, Botella-Estrada R (2020) Accuracy of SCORTEN to predict the prognosis of Stevens-Johnson syndrome/toxic epidermal necrolysis: a systematic review and meta-analysis. *Journal of the European Academy of Dermatology and Venereol* 34(9):2066-2077.
5. Revuz J, Penso D, Roujeau JC, Guillaume JC, Payne CR, et al. (1987) Toxic epidermal necrolysis: clinical findings and prognosis factors in 87 patients. *Archives of Dermatol* 123(9):1160-1165.
6. Chung WH, Hung SI, Chen YT (2007) Human leukocyte antigens and drug hypersensitivity. *Current Opinion in Allergy and Clinical Immunol* 7(4):317-323.
7. Chung WH, Hung SI, Hong HS, Hsieh MS, Yang LC, et al. (2004) A marker for Stevens-Johnson syndrome. *Nature* 428(6982):486.
8. Nassif A, Moslehi H, Le Gouvello S, Bagot M, Lyonnet L, et al. (2004) Evaluation of the potential role of cytokines in toxic epidermal necrolysis. *Journal of Investigative Dermatol* 123(5):850-855.
9. Le Cleach L, Delaire S, Boumsell L, Bagot M, Bourgault-Villada I, et al. (2000) Blister fluid T lymphocytes during toxic epidermal necrolysis are functional cytotoxic cells which express human natural killer (NK) inhibitory receptors. *Clinical & Experimental Immunol* 119(1):225-230.
10. Charlton OA, Harris V, Phan K, Mewton E, Jackson C, et al. (2020) Toxic epidermal necrolysis and Steven-Johnson syndrome: a comprehensive review. *Advances in wound care* 9(7):426-439.
11. Paulmann M, Mockenhaupt M (2019) Severe skin reactions:

clinical picture, epidemiology, etiology, pathogenesis, and treatment. *Allergo Journal Int* 28(8):311-326.

12. Wang R, Zhong S, Tu P, Li R, Wang M (2019) Rapid remission of Stevens–Johnson syndrome by combination therapy using etanercept and intravenous immunoglobulin and a review of the literature. *Dermatologic Therapy* 32(4):e12832.

Copyright: ©2024 Mohammed Al Abadie, et al. This is an open-access article distributed under the terms of the Creative Commons Attribution License, which permits unrestricted use, distribution, and reproduction in any medium, provided the original authors and source are credited.