



## Sectional axillary artery reparation through the use of an autologous graft from the mayor saphenous vein

### Reparación de sección de arteria axilar mediante el uso de un injerto autólogo de vena safena mayor

#### Citation:

Nieto Muñoz S, Puertas Saurez LS, Calderon Marin S, Castillo Ramirez S, Caceres Niño VR. Sectional Axillary Artery Reparation Through the Use of An Autologous Graft from the Mayor Saphenous Vein. Revdosdic [Internet]. 2024 [cited: access date];7(1): e469 [approx. 4 p.]. Available from: <https://revdosdic.sld.cu/index.php/revdosdic/article/view/469>

Santiago Nieto Muñoz <sup>1</sup> , Laura Sofia Puertas Saurez <sup>1</sup> , Sarah Calderón Marín <sup>2</sup> , Steven Castillo Ramirez <sup>2</sup> , Victor Raul Caceres Niño <sup>1</sup> .

<sup>1</sup>Caldas University, Faculty of Health Sciences, Manizales, Colombia. SECIN Surgery Research Seedbed, Universidad de Caldas, Manizales Colombia.


<sup>2</sup>Manizales University, Faculty of Health Sciences, Manizales, Colombia. SECIN Surgery Research Seedbed, Universidad de Caldas, Manizales Colombia.



#### Mail to:

Santiago Nieto Muñoz  
[santiago.521825772@ucaldas.edu.co](mailto:santiago.521825772@ucaldas.edu.co)


#### Reviewed by:

Claudia Amalia   
Cuevas Rodríguez  
Universidad de Ciencias  
Médicas de Granma

Annier Jesús   
Fajardo Quesada

Universidad de Ciencias  
Médicas de Granma

#### Proofreader editor:

MSc. Ismara   
Zamora León  
Universidad de Ciencias  
Médicas de Granma

#### Key words:

Axillary Artery; Fracture;  
Graft; Saphenous Vein;  
Vascular Trauma.

#### Palabras clave:

Arteria Axillar; Injerto;  
Fractura; Trauma Vascular;  
Vena Safena.

Received: 2023/11/09

Accepted: 2024/01/23

Published: 2024/02/13

## ABSTRACT

**Introduction:** traumatic fractures of the humerus are common in the emergency department, accounting for 4% to 5% of all fractures, and 45% of surgical humeral neck fractures, 85% of which are nondisplaced. **Clinical case:** shoulder arthroplasty is a complex procedure that demands careful evaluation and rapid intervention, as injuries in this area can affect the functionality of the arm and the patient's quality of life. Vascular complications can occur in up to 3% of cases, and vascular repair is usually performed by open surgery, preferring autologous grafts because of their lower risk of infection and thrombosis. **Discussion:** shoulder arthroplasty is a complex procedure that requires careful evaluation and prompt intervention. Injuries in this area can affect the functionality of the arm and the patient's life, so it is vital to identify them early through physical examination and imaging. Complications, such as vascular lesions, can occur in up to 3% of cases. Vascular repair is usually performed by open surgery, preferring autologous grafts because of their lower risk of infection and thrombosis. **Conclusions:** vascular injuries of the axillary vessels are rare, and their treatment requires a multidisciplinary team with adequate surgical skills and a thorough knowledge of shoulder anatomy. Autologous greater saphenous vein grafting is considered a reliable therapeutic alternative for the management of these injuries.

## RESUMEN

**Introducción:** las fracturas traumáticas del húmero son comunes en el departamento de emergencias, representando entre el 4% y el 5% de todas las fracturas, y el 45% de las fracturas quirúrgicas del cuello del húmero, de las cuales el 85% son no desplazadas. **Caso clínico:** este informe de caso presenta a una mujer de 57 años con una fractura completa del cuello quirúrgico del húmero, que se manifiesta con dolor, movilidad funcional limitada y pérdida de rango de movimiento. Durante la artroplastia de hombro, la paciente experimenta una complicación intraoperatoria con un desgarro marginal de 1 cm de la arteria axilar, lo que provoca un sangrado profuso. Esto requiere la intervención de cirugía vascular, que decide colocar un injerto autólogo de la vena safena mayor. **Discusión:** la artroplastia de hombro es un procedimiento complejo que demanda una evaluación cuidadosa y una intervención rápida, ya que las lesiones en esta área pueden afectar la funcionalidad del brazo y la calidad de vida del paciente. Las complicaciones vasculares pueden ocurrir en hasta un 3% de los casos, y la reparación vascular se realiza generalmente mediante cirugía abierta, prefiriendo injertos autólogos por su menor riesgo de infección y trombosis. **Conclusiones:** las lesiones vasculares de los vasos axilares son raras, y su tratamiento requiere un equipo multidisciplinario con habilidades quirúrgicas adecuadas y un conocimiento exhaustivo de la anatomía del hombro. El injerto autólogo de la vena safena mayor se considera una alternativa terapéutica confiable para el manejo de estas lesiones.



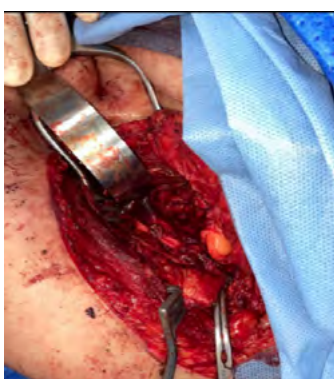## INTRODUCTION

A traumatic humeral fracture is a clinical entity that presents with relative frequency in emergency services. It is estimated that its incidence is between 4% to 5% of all fractures, 45% of surgical neck of the humerus and additionally 85% of these are non-displaced. <sup>(1)</sup> Complications that may occur during surgical correction of a humeral fracture include vascular and neurological lesions, with vascular lesions being the most common. <sup>(2,3)</sup> Vascular trauma can have various consequences, including, compromise of the patient's life and loss of limbs. <sup>(4,5)</sup> The close proximity of the axillary vasculature to the head of the humerus increases the risk of vascular lesion during a fracture or an anterior luxation of the shoulder (6%-15%). <sup>(2)</sup> The injury of axillary or subclavian vasculature has an associated mortality of 5% and 30% respectively and a significantly high morbidity. <sup>(6,7,8)</sup>

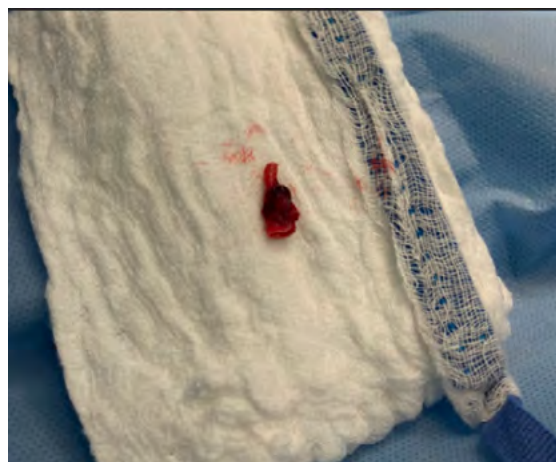While the injuries that most frequently occur and, at the same time, are more conspicuous are those affecting neurological structures such as the brachial plexus, they are more closely related to mortality and morbidity rates. <sup>(2)</sup> In accordance with the aforementioned, it is imperative to consider the anatomical relationship these morphological structures bear due to the likelihood of causing injuries within the thoracic cavity. This, in turn, increases the possibility of the patient experiencing a pneumothorax or haemothorax, which have an incidence of up to 29% in such injuries. Additionally, injuries to the aerodigestive tract, sympathetic chain, and other structures of the nervous system may occur at a rate of 3%. <sup>(8)</sup>

## CASE DESCRIPTION

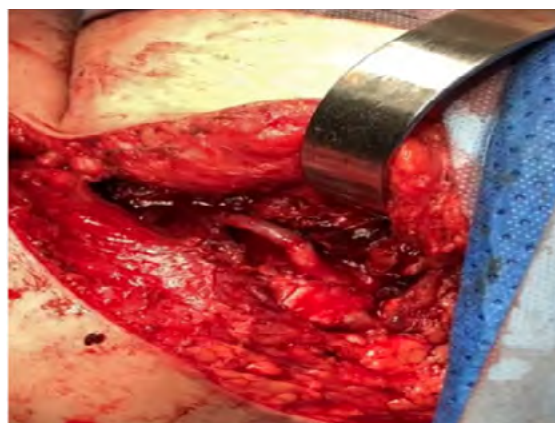
Patient is a 57-year-old female patient with a history of physical assault fifteen days prior to presenting to the emergency department. Upon admission, she reported functional limitations, pain, and a loss of range of motion in her left upper limb. An ante-posterior shoulder X-ray revealed a complete fracture of the surgical neck of the humerus. She underwent shoulder arthroplasty, and during the closure of the tuberosities over the prosthesis, an intraoperative complication occurred, involving a 1 cm marginal tear of the axillary artery, resulting in profuse bleeding. Intraoperative assessment by vascular surgery was required, leading to successful anastomosis with an autologous graft of the greater saphenous vein. The patient experienced a satisfactory postoperative recovery (Figure 1, 2, 3).



**Figure 1.** Injury of the Axillary Artery.



**Figure 2.** A segment of the axillary artery was excised to facilitate a proper anastomosis with the autologous graft of the greater saphenous vein.



**Figure 3.** Axillary artery repaired with an autologous graft of the greater saphenous vein.

## DISCUSSION

Shoulder arthroplasty is one of the most demanding current joint replacement procedures from a technical standpoint. <sup>(9)</sup> The management of such injuries, regardless of their etiology, requires comprehensive evaluation and timely intervention by a multidisciplinary team with the correct training to address these injuries due to their complexity. Given the numerous osteo muscular, vascular, and nervous structures in this anatomical region, any injury here can compromise both the functionality of the limb and the patient's life. <sup>(2,10)</sup> To promptly identify such injuries, a detailed physical examination is crucial, supported by diagnostic imaging that can guide appropriate therapeutic management. <sup>(10)</sup>

Despite the success represented by the performance of shoulder arthroplasties, complications such as intraoperative vascular injuries may occur, with a rate of occurrence of up to 3%. Therefore, it is important to be familiar with the telltale signs of vascular trauma, such as active bleeding, expansive hematoma, loss of distal pulses, and evidence of decreased irrigation. These signs

exhibit high specificity for vascular trauma and can orient the team towards an accurate diagnosis and treatment. However, it is essential to note that the absence of these signs does not rule out the possibility of such injuries, due to the fact that in non-severe cases these signs may not be evident, and collateral circulation systems may continue to perfuse these tissues, as seen in the collateral vascular network irrigating this anatomical region. <sup>(2,11,9)</sup>

Considering that vascular repair in this type of injuries favors open surgery as the first line of treatment over vascular surgery management, it is important to recognize the type of trauma being addressed. Primary suture repair or primary anastomosis are preferred for focal and pinpoint lesions. In contrast, complete dissections of the vascular pathway will be candidates for repair with grafts, whether autologous or prosthetic. <sup>(4,5)</sup>

When the dissection is secondary to trauma or intraoperative injury, as in the presented case, there is a greater loss of the vascular segment. Therefore, a decision must be made between the use of autologous and prosthetic grafts, with a preference for autologous grafts. Prosthetic grafts have shown a higher rate of infection and thrombotic processes, increasing the risk of postoperative complications and re-interventions. In contrast, autologous grafts have demonstrated better performance, a lower incidence of infection and rejection, thereby reducing complications such as compartmental syndrome and even limb loss. <sup>(4,11,9)</sup>

The autologous graft of the greater saphenous vein is an excellent resource for this type of vascular repair due to its length and location, which is easily accessible and widely available. <sup>(11)</sup> In terms of its structural characteristics, it is stronger and more resistant than any other vein that can be used as a graft. Its wall thickness and diameter are similar to those of medium-caliber arteries, such as the axillary artery. <sup>(7,1,10)</sup> Additionally, it exhibits histological features that make it the ideal vein for vascular repairs of this kind, including the presence of endothelial cells on its luminal surface and elastic properties comparable to those found in arteries. <sup>(13)</sup>

While autologous grafts have proven to be more efficient than prosthetic grafts in vascular trauma, as in this case where the patient achieved full recovery of upper limb functionality, there is still insufficient evidence to assert that the use of autologous grafts is the preferred technique in all cases.

## CONCLUSIONS

Vascular injuries to the axillary vessels in shoulder arthroplasties are infrequent. Their management requires a multidisciplinary team with the relevant surgical skills to provide a successful solution to the injury, along with a comprehensive understanding of shoulder anatomy and meticulous surgical technique to reduce the occurrence of such injuries. It should be noted that the manifestations, management, and reconstruction of these injuries vary, making it challenging to standardize a singular management method. Therefore, it is important to consider the autologous graft of the greater saphenous vein as a reliable therapeutic alternative within the emerging measures for managing such vascular injuries.

## STATEMENT OF FUNDING SOURCES

This research did not receive any specific grant from funding agencies in the public, commercial, or not-for-profit sectors.

## CONFLICT OF INTEREST STATEMENT

The authors declare that they have not conflicts of interest.

## AUTHORS' CONTRIBUTION

SNM: Resources, Methodology, Conceptualization, Revision and Edition.

LSPS: Administration of the Project, Conceptualization Resource and Revision.

SCM: Software, Drafting, Edition and translation, Revision and Edition.

SCR: Resources, Methodology and Supervision.

VRCN: Resources, Supervision and Revision.



**BIBLIOGRAPHIC REFERENCES**

1. Egol KA, Koval KJ, Zuckerman JD. Handbook of fractures. 5th ed. Philadelphia: Wolters Kluwer; 2015.
2. McCready RA, Procter CD, Hyde GL. Subclavian-axillary vascular trauma. J Vasc Surg. 1986 [cited March 13, 2022];3(1):24–31. Available from: [https://www.jvascsurg.org/article/0741-5214\(86\)90065-0/fulltext](https://www.jvascsurg.org/article/0741-5214(86)90065-0/fulltext)
3. Medigraphic.com. [cited March 13, 2022]. Available from: <https://www.medigraphic.com/pdfs/trauma/tm-2003/tm032d.pdf>
4. Gill H, Jenkins W, Edu S, Bekker W, Nicol AJ, Navsaria PH. Civilian penetrating axillary artery injuries. World J Surg. 2011;35(5):962–6. Available from: <http://dx.doi.org/10.1007/s00268-011-1008-8>
5. Cristián Salas D. Trauma vascular, visión del cirujano vascular. Rev médica Clín Las Condes. 2011;22(5):686–95. Available from: <https://www.sciencedirect.com/science/article/pii/S0716864011704813>
6. Castelli P, Caronno R, Piffaretti G, Tozzi M, Laganà D, Carrafiello G, et al. Endovascular repair of traumatic injuries of the subclavian and axillary arteries. Injury. 2005 [cited March 13, 2022];36(6):778–82. Available from: [https://www.injuryjournal.com/article/S0020-1383\(05\)00004-5/fulltext](https://www.injuryjournal.com/article/S0020-1383(05)00004-5/fulltext)
7. Danetz JS, Cassano AD, Stoner MC, Ivatury RR, Levy MM. Feasibility of endovascular repair in penetrating axillosubclavian injuries: a retrospective review. J Vasc Surg. 2005 [cited March 13, 2022];41(2):246–54. Available from: [https://www.jvascsurg.org/article/S0741-5214\(04\)01639-8/fulltext](https://www.jvascsurg.org/article/S0741-5214(04)01639-8/fulltext)
8. Fox C, Gillespie D, O'Donnell S, Rasmussen T, Goff J, Johnson C, et al. Manejo contemporáneo del trauma vascular en tiempos de guerra. Revista de Cirugía Vascular. 2005;41:638-44. Retrieved April 22, 2017, from [http://www.jvascsurg.org/article/S0741-5214\(05\)00032-7/fulltext](http://www.jvascsurg.org/article/S0741-5214(05)00032-7/fulltext)
9. Gallucci GL, Maximiliano R, Gallucci J, De Carli P, Maignon G. Comienzo tardío de la trombosis de la arteria axilar después de una fractura de cuello humeral sin desplazamiento: informe de un caso. J Hombro Codo Cirug. 2007;16:E7–E8.
10. Salas C. Trauma Vascular, Visión del Cirujano Vascular. Revista Médica Clínica Las Condes. 2011;22:686-95. Retrieved April 20, 2017, from <http://www.sciencedirect.com/science/article/pii/S0716864011704813>
11. Ivatury R, Anand R, Ordonez C. Penetrating Extremity Trauma, World Journal of Surgery. 2015;39:1389-96. Retrieved May 18, 2017, from <http://sci-hub.cc/10.1007/s00268-014-2865-8>
12. Komori K, Okadome K, Sugimachi K. Factor relajante de origen endotelial e injertos venosos- Br. j , Surg (Ed. Esp) 1991; 6: 553-556.