

# Does intervertebral disc degeneration in adolescent idiopathic scoliosis correlate with patient-reported pain scores?

Boylan, Conor; Thimmaiah, Ravindra; McKay, George; Gardner, Adrian; Newton Ede, Matthew; Mehta, Jwalant; Spilsbury, Jonathan; Marks, David; Jones, Morgan

DOI:

[10.1007/s00586-023-08082-9](https://doi.org/10.1007/s00586-023-08082-9)

License:

Creative Commons: Attribution (CC BY)

*Document Version*

Publisher's PDF, also known as Version of record

*Citation for published version (Harvard):*

Boylan, C, Thimmaiah, R, McKay, G, Gardner, A, Newton Ede, M, Mehta, J, Spilsbury, J, Marks, D & Jones, M 2024, 'Does intervertebral disc degeneration in adolescent idiopathic scoliosis correlate with patient-reported pain scores? A review of 968 cases', *European Spine Journal*. <https://doi.org/10.1007/s00586-023-08082-9>

[Link to publication on Research at Birmingham portal](#)

## General rights

Unless a licence is specified above, all rights (including copyright and moral rights) in this document are retained by the authors and/or the copyright holders. The express permission of the copyright holder must be obtained for any use of this material other than for purposes permitted by law.

- Users may freely distribute the URL that is used to identify this publication.
- Users may download and/or print one copy of the publication from the University of Birmingham research portal for the purpose of private study or non-commercial research.
- User may use extracts from the document in line with the concept of 'fair dealing' under the Copyright, Designs and Patents Act 1988 (?)
- Users may not further distribute the material nor use it for the purposes of commercial gain.

Where a licence is displayed above, please note the terms and conditions of the licence govern your use of this document.

When citing, please reference the published version.

## Take down policy

While the University of Birmingham exercises care and attention in making items available there are rare occasions when an item has been uploaded in error or has been deemed to be commercially or otherwise sensitive.

If you believe that this is the case for this document, please contact [UBIRA@lists.bham.ac.uk](mailto:UBIRA@lists.bham.ac.uk) providing details and we will remove access to the work immediately and investigate.



# Does intervertebral disc degeneration in adolescent idiopathic scoliosis correlate with patient-reported pain scores? A review of 968 cases

Conor Boylan<sup>1,2</sup> · Ravindra Thimmaiah<sup>1,2</sup> · George McKay<sup>2</sup> · Adrian Gardner<sup>1,2</sup> · Matthew Newton Ede<sup>2</sup> · Jwalant Mehta<sup>2</sup> · Jonathan Spilsbury<sup>2</sup> · David Marks<sup>2</sup> · Morgan Jones<sup>2</sup>

Received: 23 April 2023 / Revised: 13 October 2023 / Accepted: 1 December 2023

© The Author(s) 2024

## Abstract

**Purpose** Report the rate and severity of degenerative disc disease (DDD) in non-surgical adolescent idiopathic scoliosis (AIS) patients and correlate these findings with patient-reported symptomatology scores. Additionally, to quantify the rate of concurrent pathological radiological findings in this group.

**Methods** This was a retrospective chart review study at a single tertiary centre. AIS patients aged 10–16 who had received a whole spine MRI between September 2007 and January 2019 and who had not received surgical intervention to their spine were included. MRI scan reports were screened to extract those who had evidence of DDD. These were then reviewed by a blinded second reviewer who graded every disc using the Pfirrmann grading system. SRS-22 scores were extracted for patients when available.

**Results** In total, 968 participants were included in the study. Of these, 93 (9.6%) had evidence of DDD, which was Pfirrmann grade  $\geq 3$  in 28 (2.9%). The most commonly affected level was L5/S1 (59.1% of DDD cases).

A total of 55 patients (5.7%) had evidence of syringomyelia, 41 (3.4%) had evidence of spondylolisthesis (all L5/S1), 14 (1.4%) had bilateral L5 pars defects, and 5 (0.5%) had facet joint degeneration. Spondylolisthesis and bilateral pars defects were more common in patients with DDD identified on MRI scan ( $p < 0.001$  and  $p = 0.04$ , respectively).

Function ( $p = 0.048$ ) and pain ( $p = 0.046$ ) scores were worse in patients with DDD.

**Conclusion** We present a baseline for the rate and severity of DDD in the non-operative AIS cohort. This should assist in decision-making and counselling of patients prior to surgery.

**Level of evidence** III.

**Keywords** Adolescent idiopathic scoliosis · Degenerative disc disease · Magnetic resonance imaging · Prevalence · Severity · Non-surgical

## Introduction

Adolescent idiopathic scoliosis (AIS) affects 1–3% of children aged 10–16 years and the natural history includes back pain, deformity, psychosocial problems, and reduction in quality of life [1, 2]. A pathology commonly associated with

AIS in both early and late stages is degenerative disc disease (DDD) [3]. This describes both structural damage and accompanying inflammatory changes to the intervertebral discs [4, 5]. DDD may predispose patients to higher rates of chronic lower back pain and disc herniation [4, 6, 7].

A minority of previous studies have attempted to quantify the rate of occult DDD in non-operative or conservatively managed AIS patients, reporting DDD rates ranging from 0 to 11.9% [8–11]. However, these studies typically review patients specifically selected for MRI, are limited by small sample sizes and heterogeneous datasets, and fail to undertake a detailed analysis of disc quality [9–12]. Furthermore, no previous studies appropriately investigate patient-reported symptoms and how they relate to DDD.

✉ Conor Boylan  
conortboylan@gmail.com

<sup>1</sup> University of Birmingham, Birmingham, UK

<sup>2</sup> The Royal Orthopaedic Hospital NHS Foundation Trust, The Woodlands, Bristol Road South, Northfield, Birmingham B31 2AP, UK

We investigated and reported on the rate and severity of radiologically identified DDD in a non-selected AIS population who have not undergone surgical intervention and investigated the relationships between the presence and severity of DDD with patient-reported symptoms. Second, we quantified the rate of concurrent pathological radiological findings in this group and investigated how the prevalence differs between patients with and without radiological DDD.

## Methodology

### Participant selection

This was a retrospective study undertaken at a single tertiary centre for spinal deformity surgery, where it is a routine standard of care for all individuals aged 10–16 years with a presumed diagnosis of AIS to undergo an MRI of the whole spine prior to them being seen in clinic. This allows proper characterisation of curve morphology and disc characteristics as well as any concurrent pathological findings in the spine and is thus the gold standard in workup of AIS patients. All scans are reviewed and reported by a fellowship-trained consultant radiologist. From the database of these MRI reports, participants were included for review in this study. All images were taken between September 2007 and January 2019. Images prior to September 2007 were before digital PACS and were not available for review. Exclusion criteria were incomplete demographic data, an incomplete scan report, non-AIS diagnosis or previous spinal surgery. To factor for potential transitional segments, non-functional discs were excluded from analysis.

The term “non-operative patients” is used to describe the participants in our study. This includes patients who had not received surgical intervention at the time of the scan, regardless of whether they later went on to receive surgery or not.

### Rate and severity of disc degeneration

From individuals who met the inclusion criteria, MRI reports were examined and information in the presence of DDD, spondylomyelia, spondylolisthesis (includes anterolisthesis and retrolisthesis), pars defects, and facet joint degeneration was collected. All MRI images with radiologist-reported DDD were then reviewed by a blinded second reviewer who applied a Pfirrmann grade to every intervertebral disc from C2/3 to L5/S1.

The Pfirrmann grading system is a validated tool for assessing the degree of degeneration of intervertebral discs using an MRI scan. It takes into account the disc structure, height, signal intensity, and the distinction of the nucleus and annulus as separate entities [13]. In keeping with previous

studies, grade 3 or higher was considered to indicate significant DDD [14].

### MRI scanner parameters

From August 2011 onwards, MR scans were performed on Siemens Skyra 3 Tesla Magnets using a 24-element spine matrix coil. Sagittal T1 (TR/TE 819/11, 3 mm slices with 0.3 mm gap, matrix 448\*314) and T2 (TR/TE 3770/104, 3 mm slices with 0.3 mm gap, matrix 512\*307) whole spine, coronal T1 (TR/TE 830/9.9, 3 mm slices with 0.6 mm gap, matrix 448\*269) T/L spine and axial T2 (TR/TE 4180/114, 4 mm slices with 1 mm gap, matrix 448\*269) views were utilised. Unfortunately, MRI scan parameters were unavailable for scans performed prior to this date.

### SRS-22 symptomatology scores

Patient-reported outcomes were obtained via a Scoliosis Research Society 22 (SRS-22) questionnaire, where available, for participants included in the study [15]. Where multiple questionnaire results were available, the closest to the time of the MRI scan was used. SRS-22 scores were considered in their five domains: function, pain, self-image, mental health, and management satisfaction. All five domains, as well as the overall score, were used independently and in combination in statistical analysis.

### Statistical analysis

Basic data analysis was performed using *Microsoft Excel for Office 365*. Statistical analysis was performed using the *Statistical Package for Social Sciences 26 (SPSS26)* software.

Univariable analysis used independent two-tailed Mann–Whitney *U* tests for continuous data and Fisher exact tests for nominal and ordinal data. Multivariable analysis was performed using simple linear regression with the enter method. A *p* value of less than 0.05 was considered statistically significant throughout the study.

### Ethical considerations and funding

This study underwent ethical review and obtained approval prior to collection of data (IRAS project ID 279278, Ref 21/PR/0060). As this was a review of previously collected, anonymous, routine care data with no potential for affecting patient care, informed consent was deemed not to be required. An institutional charitable grant was obtained for this study to support administrative costs only.

## Results

### Participant characteristics

A total of 1086 patients were selected for data analysis, 118 of which were manually excluded following review. Reasons for exclusion and flow of participants are given in Fig. 1. This left 968 patients who met our inclusion criteria. A total of 759 (78.4%) participants were female and the mean age of the entire cohort was 13.9 years (SD 1.5, range 10–16 years). There were 533 (55.1%) participants who had appropriate SRS-22 data collected within 24 months of their MRI scan. The mean time between scan and SRS-22 survey was 4.8 months (SD 5.9 months), with all but 65 surveys being completed within 12 months of MRI. There were 435 (44.9%) participants who did not have suitable SRS-22 data available. There were 47 patients with DDD identified on MRI who did not have appropriate SRS-22 scores recorded.

### Disc degeneration and concurrent radiological findings

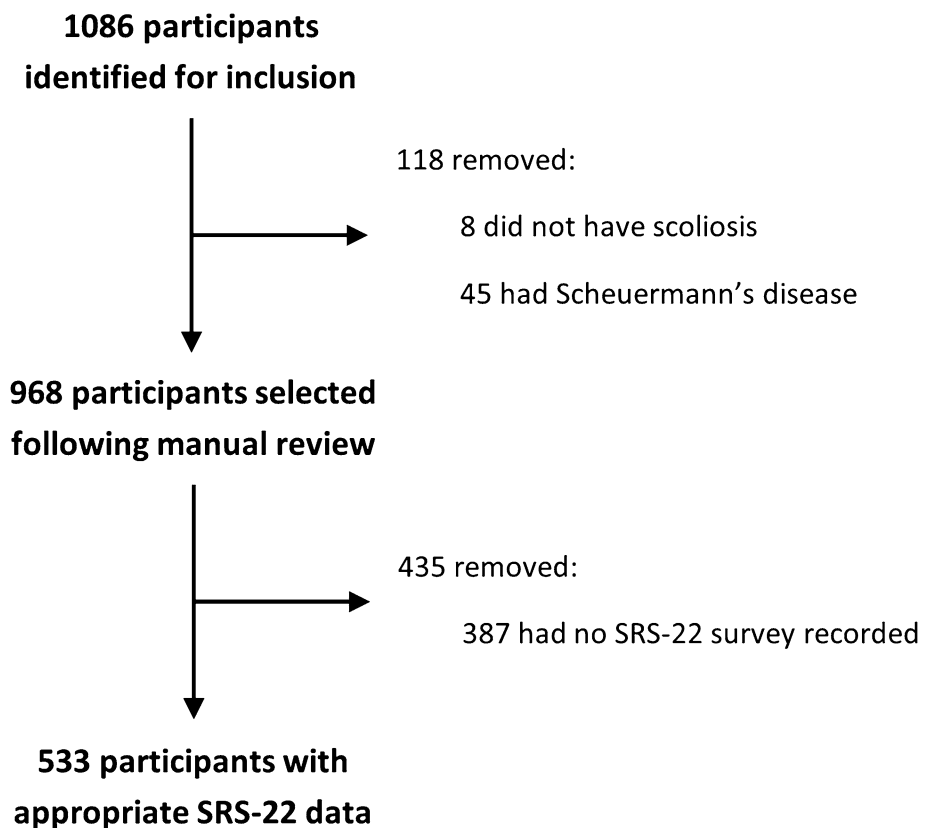
Disc degenerative disease (DDD) was identified in 93/968 (9.6%) participants. In 28 (2.9%) patients, at least one disc was found to be of Pfirrmann grade  $\geq 3$ . Only 1 disc was

graded Pfirrmann 5. The mean age for patients with DDD was 14.2 years and 80.6% were female.


The number of spinal levels affected ranged between 1 and 12, with 46 patients (49.5% of those with DDD) having only single-level disease and 47 patients (50.5% of those with DDD) having disease affecting 2 or more levels. The most commonly affected level was L5/S1 (59.1% of DDD cases), followed by L4/L5 (25.8%) and T11/12 (16.1%). Figure 2 illustrates the distribution of disc degeneration by spinal level. There was no correlation between Cobb angle and severity of disc degeneration ( $R^2 = 0.002$ ,  $F(1,85) = 0.195$ ,  $p = 0.660$ ,  $\beta = -0.048$ ).

A total of 55 patients (5.7%) had evidence of syringomyelia, 41 (4.2%) had evidence of spondylolisthesis (all L5/S1), 14 (1.4%) had bilateral L5 pars defects, and 5 (0.5%) had facet joint degeneration. Additionally, 3 unilateral L5 pars defects were noted. Both spondylolisthesis ( $p < 0.001$ ) and bilateral pars defects ( $p = 0.038$ ) were statistically significantly more common in patients with DDD than those without, as demonstrated in Table 1. Furthermore, of the 41 patients with spondylolisthesis, 5 (12.2%) had at least one disc of Pfirrmann grade  $\geq 3$ . Pfirrmann grades  $\geq 3$  were statistically significantly more common in patients with spondylolisthesis than those without.

**Fig. 1** Reasons for exclusion and flow of participants through the study



**Fig. 2** Pictorial representation of the frequency of disc degeneration at each intervertebral disc level. Grey indicates no disc degeneration, and increasingly darker red represents higher frequencies, as indicated in the key



C2/C3 = 0.0%
C3/C4 = 0.1%
C4/C5 = 0.2%
C5/C6 = 0.1%
C6/C7 = 0.1%
C7/T1 = 0.0%
T1/T2 = 0.0%
T2/T3 = 0.1%
T3/T4 = 0.1%
T4/T5 = 0.1%
T5/T6 = 0.2%
T6/T7 = 0.4%
T7/T8 = 0.8%
T8/T9 = 1.1%
T9/T10 = 1.1%
T10/T11 = 1.4%
T11/T12 = 1.5%
T12/L1 = 0.5%
L1/L2 = 0.7%
L2/L3 = 1.0%
L3/L4 = 0.8%
L4/L5 = 2.5%
L5/S1 = 5.7%

**Table 1** Frequency of each concurrent radiological finding compared between patients with and without disc degeneration identified on MRI scan

Concurrent radiological finding	Presence of disc degeneration		
	No disc degeneration ( <i>n</i> = 875) <i>N</i> (%)	Disc degeneration ( <i>n</i> = 93) <i>N</i> (%)	<i>P</i> -value*
Syringomyelia	52 (5.9)	3 (3.2)	0.353
Spondylolisthesis	29 (3.4)	12 (11.8)	<b>&lt; 0.001</b>
Bilateral pars defect	10 (1.1)	4 (4.3)	<b>0.038</b>
Facet joint degeneration	5 (0.6)	0	1.000

\**p*-values calculated using Fisher exact test

Statistically significant results are emboldened

**Table 2** Mean scores in overall and each SRS-22 sub-category compared between patients with and without disc degeneration identified on MRI scan

SRS-22 category	Presence of disc degeneration		<i>P</i> -value*
	No disc degeneration ( <i>n</i> =487) Mean (SD)	Disc degeneration ( <i>n</i> =46) Mean (SD)	
Function	4.0 (0.8)	3.8 (0.6)	<b>0.048</b>
Pain	3.7 (0.9)	3.5 (0.9)	<b>0.046</b>
Self-image	3.2 (0.9)	3.0 (0.9)	0.069
Mental health	3.8 (0.9)	3.7 (0.8)	0.822
Management satisfaction <sup>a</sup>	3.7 (1.0)	3.4 (1.0)	0.059
Overall	3.7 (0.7)	3.5 (0.6)	0.073

\**p*-value calculated using Mann–Whitney *U* test

<sup>a</sup>Management satisfaction data were not available for all responders (No disc degeneration *n*=357, Disc degeneration *n*=35). SD, standard deviation

Statistically significant results are emboldened

## Disc degeneration and SRS-22 scores

The mean scores for patients with disc degeneration identified were lower than those without disc degeneration in every domain, as demonstrated in Table 2. Function ( $U=9248.0$ ,  $z=-1.974$ ,  $p=0.048$ ,  $r=0.086$ ) and pain ( $U=9216.5$ ,  $z=-1.993$ ,  $p=0.046$ ,  $r=0.086$ ) scores differed to a statistically significant degree. There was no statistically significant difference between these cohorts in self-image mental health, management satisfaction, or overall scores.

## Discussion

Degenerative disc disease (DDD) has been identified in both early and late stages of adolescent idiopathic scoliosis (AIS) [16, 17]. Although the precise cause of DDD remains unclear and is currently a subject of active research, prevailing theories suggest a complex interplay between disc "wedging", uneven disc loading, and structural abnormalities as primary and secondary contributing factors [3].

Our study examined the prevalence of DDD in AIS patients who had not undergone surgery. Within this non-operative cohort, 9.6% (93/968) exhibited DDD, with 2.9% (28/968) having Pfirrmann grade 3 or higher disease. Another study, conducted by Ghandhari et al. [8], reported a higher DDD rate of 11.9% in non-operative patients using a different classification method (the J. Khanna method, in which degenerative discs are divided into 3 classes of severity) and a smaller sample size ( $n=42$ ). In the broader context, incidental DDD findings on MRI in asymptomatic

non-AIS paediatric populations have been reported at 19%, but rates vary between 9 and 25% due to variances in study designs [18–21].

Among the affected disc levels, L5/S1 was the most common (59.1%), followed by L4/L5 (25.8%). There is a dearth of data on degenerative disc levels in non-operative AIS patients; however, these findings align with studies investigating post-operative DDD occurrence [9, 14, 22, 23]. Notably, Nohara et al. [14] reported a similar rate (40%) of DDD at the L5/S1 junction.

The prevalence of syringomyelia as reported in the literature is highly variable (0.6–5.5%), [12, 24–26] but our value of 5.7% is consistent with the upper range of this estimate. The frequency of spondylolisthesis in our paper (4.2%) was also consistent with that previously reported by Hershman et al. (4.6%) [27]. However, our rate of bilateral pars defects (1.4%) was lower than that previously found in the literature (3.6%) [28]. Spondylolisthesis and pars defects were more common in patients with DDD, likely due to increased disc loading pressures during normal activities [29]. While some studies have established a connection between facet joint degeneration and DDD, the absence of correlation in our study could potentially be attributed to the time delay between the onset of facet joint disease and progression to disc degeneration, which would not yet have become apparent in this paediatric population [30].

Although the impact of a scoliotic deformity on the prevalence and severity of back pain in AIS remains uncertain, it is acknowledged as a significant problem [31]. In our study, we report a statistically significant correlation ( $p=0.046$ ) between the presence of disc degeneration and self-reported pain scores, although the magnitude of the difference is relatively small ( $r=0.086$ ). This is in contrast to the prevailing consensus in the literature, which is that DDD has little impact on reported pain in AIS patients. [9, 14, 23, 32, 33] Our novel findings may be related to a comparatively large group size, which is better able to detect relatively small differences in SRS-22 scores.

There is a paucity of published data describing the relationship between the remaining SRS-22 categories (function, self-image, mental health, and management satisfaction) and DDD, so direct comparison with our study is not possible. Green et al. [9] report no significant difference in overall SRS-22 score between patients with Pfirrmann grade I/II and grade III/IV intervertebral discs, which is consistent with our study. We found that overall SRS-22 score did not differ between patients with and without DDD to a statistically significant degree ( $p=0.073$ ).

Our study was limited by its retrospective design which meant SRS-22 questionnaires were not collected for all participants, and many were collected some time before or after MRI scans were taken; to ameliorate this, future studies should be prospective in nature. Furthermore, we were not



yet able to correlate pre-operative DDD with post-operative outcomes. We also did not assess curve characteristics for all participants included in the study, principally due to the large cohort size and subsequent resource limitations. Lastly, as Pfirrmann grading was performed by one reviewer only it was impossible to assess interobserver reliability, which has been reported as variable in the literature [13, 34].

## Conclusion

The rate of DDD in our conservatively managed AIS population is 9.6%, being of Pfirrmann grade  $\geq 3$  in 2.9%. The most commonly affected disc was L5/S1, which was involved in 59.1% of cases. Rates of spondylolisthesis and bilateral pars defects were significantly higher in patients with radiologically identified DDD. Function and pain scores as reported on SRS-22 questionnaires were statistically significantly worse in patients with DDD, although clinical significance remains to be determined.

While many studies have explored the long-term effects of surgical treatment for AIS on disc health, none prior to this have provided a reliable baseline rate of DDD in non-operative patients. Our study addresses this gap and provides valuable insights into the prevalence and severity of pre-existing DDD in AIS patients, as well as its impact on patient symptomatology. This should assist in decision-making and counselling of patients prior to surgery and should guide future research on the long-term impact of spinal fusion.

**Author contributions** CB made substantial contributions to the conception and design of the work as well as the acquisition, analysis, and interpretation of data. He drafted the work and revised it critically for important intellectual content, approved the version to be published and agrees to be accountable for all aspects of the work in ensuring that questions related to the accuracy or integrity of any part of the work are appropriately investigated and resolved. RT made substantial contributions to the conception and design of the work as well as the acquisition, analysis, and interpretation of data. He revised the work critically for important intellectual content, approved the version to be published and agrees to be accountable for all aspects of the work in ensuring that questions related to the accuracy or integrity of any part of the work are appropriately investigated and resolved. GM made substantial contributions to the conception and design of the work as well as the acquisition, analysis, and interpretation of data. He revised the work critically for important intellectual content, approved the version to be published and agrees to be accountable for all aspects of the work in ensuring that questions related to the accuracy or integrity of any part of the work are appropriately investigated and resolved. AG made substantial contributions to the conception and design of the work as well as the acquisition, analysis, and interpretation of data. He revised the work critically for important intellectual content, approved the version to be published and agrees to be accountable for all aspects of the work in ensuring that questions related to the accuracy or integrity of any part of the work are appropriately investigated and resolved. MN made substantial contributions to the conception and design of the

work as well as the acquisition, analysis, and interpretation of data. He revised the work critically for important intellectual content, approved the version to be published and agrees to be accountable for all aspects of the work in ensuring that questions related to the accuracy or integrity of any part of the work are appropriately investigated and resolved. JM made substantial contributions to the conception and design of the work as well as the acquisition, analysis, and interpretation of data. He revised the work critically for important intellectual content, approved the version to be published and agrees to be accountable for all aspects of the work in ensuring that questions related to the accuracy or integrity of any part of the work are appropriately investigated and resolved. JS made substantial contributions to the conception and design of the work as well as the acquisition, analysis, and interpretation of data. He revised the work critically for important intellectual content, approved the version to be published and agrees to be accountable for all aspects of the work in ensuring that questions related to the accuracy or integrity of any part of the work are appropriately investigated and resolved. DM made substantial contributions to the conception and design of the work as well as the acquisition, analysis, and interpretation of data. He revised the work critically for important intellectual content, approved the version to be published and agrees to be accountable for all aspects of the work in ensuring that questions related to the accuracy or integrity of any part of the work are appropriately investigated and resolved. MJ made substantial contributions to the conception and design of the work as well as the acquisition, analysis, and interpretation of data. He revised the work critically for important intellectual content, approved the version to be published and agrees to be accountable for all aspects of the work in ensuring that questions related to the accuracy or integrity of any part of the work are appropriately investigated and resolved.

**Funding** This study received a £200 grant from the Royal Orthopaedic Hospital Charitable Fund which was used for administrative costs only. This is a past relationship.

## Declarations

**Conflict of interest** The authors have no conflicts of interest to declare.

**Ethical approval** This study underwent ethical review and obtained approval prior to collection of data (IRAS project ID 279278, Ref 21/PR/0060).

**Consent to participate** All patient information used as part of this study and publication was collected with consent to use for research purposes from the persons in question.

**Open Access** This article is licensed under a Creative Commons Attribution 4.0 International License, which permits use, sharing, adaptation, distribution and reproduction in any medium or format, as long as you give appropriate credit to the original author(s) and the source, provide a link to the Creative Commons licence, and indicate if changes were made. The images or other third party material in this article are included in the article's Creative Commons licence, unless indicated otherwise in a credit line to the material. If material is not included in the article's Creative Commons licence and your intended use is not permitted by statutory regulation or exceeds the permitted use, you will need to obtain permission directly from the copyright holder. To view a copy of this licence, visit <http://creativecommons.org/licenses/by/4.0/>.

## References

- Weinstein S, Dolan L, Cheng J et al (2008) Adolescent idiopathic scoliosis. *Lancet* 371(9623):1527–1537. [https://doi.org/10.1016/S0140-6736\(08\)60658-3](https://doi.org/10.1016/S0140-6736(08)60658-3)
- Weinstein S (2019) The natural history of adolescent idiopathic scoliosis. *J Pediatr Orthop* 39(Supplement 1):S44–S46. <https://doi.org/10.1097/BPO.0000000000001350>
- Newton Ede M, Jones S (2016) Adolescent idiopathic scoliosis: evidence for intrinsic factors driving aetiology and progression. *Int Orthop* 40(10):2075–2080. <https://doi.org/10.1007/s00264-016-3132-4>
- Molinos M, Almeida C, Caldeira J et al (2015) Inflammation in intervertebral disc degeneration and regeneration. *J R Soc Interface* 12(104):20141191. <https://doi.org/10.1098/rsif.2014.1191>
- Kos N, Gradisnik L, Velnar T (2019) A brief review of the degenerative intervertebral disc disease. *Med Arch* 73(6):421. <https://doi.org/10.5455/medarh.2019.73.421-424>
- Buttermann G, Mullin W (2007) Pain and disability correlated with disc degeneration via magnetic resonance imaging in scoliosis patients. *Eur Spine J* 17(2):240–249. <https://doi.org/10.1007/s00586-007-0530-8>
- Nv A, Rajasekaran S, KS S, et al (2018) Factors that influence neurological deficit and recovery in lumbar disc prolapse—a narrative review. *Int Orthop* 43(4):947–955. <https://doi.org/10.1007/s00264-018-4242-y>
- Ghandhari H, Ameri E, Nikouei F et al (2018) Long-term outcome of posterior spinal fusion for the correction of adolescent idiopathic scoliosis. *Scoliosis Spinal Disord*. <https://doi.org/10.1186/s13013-018-0157-z>
- Green D, Lawhorne T, Widmann R et al (2011) Long-term magnetic resonance imaging follow-up demonstrates minimal transitional level lumbar disc degeneration after posterior spine fusion for adolescent idiopathic scoliosis. *Spine* 36(23):1948–1954. <https://doi.org/10.1097/BRS.0b013e3181ff1ea9>
- Jones M, Badreddine I, Mehta J et al (2017) The rate of disc degeneration on MRI in preoperative adolescent idiopathic scoliosis. *Spine J* 17(11):S332. <https://doi.org/10.1016/j.spinee.2017.10.051>
- Akazawa T, Umehara T, Iinuma M et al (2020) Spinal alignments of residual lumbar curve affect disc degeneration after spinal fusion in patients with adolescent idiopathic scoliosis: follow-up after 5 or more years. *Spine Surg Relat Res* 4(1):50–56. <https://doi.org/10.22603/ssrr.2019-0048>
- Ramirez N, Johnston C, Browne R (1997) The prevalence of back pain in children who have idiopathic scoliosis. *J Bone Jt Surg Am* 79(3):364–368. <https://doi.org/10.2106/00004623-199703000-00007>
- Pfirrmann C, Metzendorf A, Zanetti M et al (2001) Magnetic resonance classification of lumbar intervertebral disc degeneration. *Spine* 26(17):1873–1878. <https://doi.org/10.1097/00007632-200109010-00011>
- Nohara A, Kawakami N, Seki K et al (2015) The effects of spinal fusion on lumbar disc degeneration in patients with adolescent idiopathic scoliosis: a minimum 10-year follow-up. *Spine Deform* 3(5):462–468. <https://doi.org/10.1016/j.jspd.2015.04.001>
- Haheer T, Gorup J, Shin T et al (1999) Results of the Scoliosis Research Society instrument for evaluation of surgical outcome in adolescent idiopathic scoliosis. A multicenter study of 244 patients. *Spine* 24:1435–1440. <https://doi.org/10.1097/00007632-199907150-00008>
- Kouwenhoven J, Castelein R (2008) The pathogenesis of adolescent idiopathic scoliosis. *Spine* 33(26):2898–2908. <https://doi.org/10.1097/BRS.0b013e3181891751>
- Gervais J, Périé D, Parent S et al (2012) MRI signal distribution within the intervertebral disc as a biomarker of adolescent idiopathic scoliosis and spondylolisthesis. *BMC Musculoskelet Disord*. <https://doi.org/10.1186/1471-2474-13-239>
- Anakwenze O, Kancherla V, Rendon N et al (2011) Adolescent disc dysplasia and back pain. *J Child Orthop* 5(1):49–53. <https://doi.org/10.1007/s11832-010-0302-6>
- Salo S, Paaianen H, Alanen A (1995) Disc degeneration of pediatric patients in lumbar MRI. *Pediatr Radiol* 25(3):186–189. <https://doi.org/10.1007/BF02021530>
- Tertti M, Salminen J, Paaianen H et al (1991) Low-back pain and disk degeneration in children: a case-control MR imaging study. *Radiology* 180(2):503–507. <https://doi.org/10.1148/radiology.180.2.1829844>
- Ramadorai U, Hire J, Brodt E et al (2014) Incidental findings on magnetic resonance imaging of the spine in the asymptomatic pediatric population: a systematic review. *Evid Based Spine Care J* 05(02):095–100. <https://doi.org/10.1055/s-0034-1386753>
- Akazawa T, Kotani T, Sakuma T et al (2017) Spinal fusion on adolescent idiopathic scoliosis patients with the level of L4 or lower can increase lumbar disc degeneration with sagittal imbalance 35 years after surgery. *Spine Surg Relat Res* 1(2):72–77. <https://doi.org/10.22603/ssrr.1.2016-0017>
- Lonner B, Ren Y, Upasani V et al (2018) Disc degeneration in unfused caudal motion segments ten years following surgery for adolescent idiopathic scoliosis. *Spine Deform* 6(6):684–690. <https://doi.org/10.1016/j.jspd.2018.03.013>
- Do T, Frasc C, Burke S et al (2001) Clinical value of routine preoperative magnetic resonance imaging in adolescent idiopathic scoliosis. *J Bone Jt Surg Am* 83(4):577–579. <https://doi.org/10.2106/00004623-200104000-00014>
- Maiocco B, Deeney V, Coulon R et al (1997) Adolescent idiopathic scoliosis and the presence of spinal cord abnormalities. *Spine* 22(21):2537–2541. <https://doi.org/10.1097/00007632-199711010-00014>
- Dewan V, Gardner A, Forster S et al (2008) Is the routine use of magnetic resonance imaging indicated in patients with scoliosis? *J Spine Surg* 4(3):575–582. <https://doi.org/10.21037/jss.2018.07.01>
- Hershman S, Hochfelder J, Dean L et al (2013) Spondylolisthesis in operative adolescent idiopathic scoliosis: prevalence and results of surgical intervention. *Spine Deform* 1(4):280–286. <https://doi.org/10.1016/j.jspd.2013.05.003>
- Mukhopadhyay S, Batra S, Kamath S et al (2011) Incidence of pars defects in adolescent idiopathic scoliosis: an MRI study. *Acta Orthop Traumatol Turc* 45:209–214. <https://doi.org/10.3944/AOTT.2011.2555>
- Tenny S, Gillis C (2021) Spondylolisthesis. [Updated 2021 May 29]. In: StatPearls [Internet]. StatPearls Publishing 2021, Treasure Island (FL). Jan Available from <https://www.ncbi.nlm.nih.gov/books/NBK430767/>
- Perolat R, Kastler A, Nicot B et al (2018) Facet joint syndrome: from diagnosis to interventional management. *Insights Imaging* 9(5):773–789. <https://doi.org/10.1007/s13244-018-0638-x>
- Balagué F, Pellisé F (2016) Adolescent idiopathic scoliosis and back pain. *Scoliosis Spinal Disord*. <https://doi.org/10.1186/s13013-016-0086-7>
- Danielsson A, Cederlund C, Ekholm S et al (2001) The prevalence of disc aging and back pain after fusion extending into the lower lumbar spine. A matched MR study twenty-five years after surgery for adolescent idiopathic scoliosis. *Acta Radiol* 42(2):187–197
- Akazawa T, Minami S, Kotani T et al (2012) Long-term clinical outcomes of surgery for adolescent idiopathic scoliosis 21 to 41 years later. *Spine* 37(5):402–405. <https://doi.org/10.1097/BRS.0b013e31823d2b06>



34. Rim D (2016) Quantitative Pfirrmann disc degeneration grading system to overcome the limitation of Pfirrmann disc degeneration grade. Korean J Spine 13(1):1. <https://doi.org/10.14245/kjs.2016.13.1.1>

**Publisher's Note** Springer Nature remains neutral with regard to jurisdictional claims in published maps and institutional affiliations.