

Coping with Gender Dysphoria in a Rural Environment during Adolescence

Manifestações da Disforia de Género no Adolescente em Ambiente Rural

Ana Luísa RIBEIRO¹, Carlos MAGALHÃES VIEIRA¹, Marta PIRES RIBEIRO¹, Justino GONÇALVES², Paulo RIBEIRO³
Acta Med Port (In Press) - <https://doi.org/10.20344/amp.19731>

ABSTRACT

Gender dysphoria is socially more visible and discussed today, but still underdiagnosed. It refers to distress and/or impaired function caused by inconsistency between the sex assigned at birth and gender identification. Clinical manifestations are variable. Lack of training and investment in gender issues make the diagnosis and management in primary care complex, particularly in conservative and isolated communities, with poor access to information and specialized health services. We describe the diagnosis of gender dysphoria and use of a patient centered multidisciplinary and family approach in a 12-year-old rural born adolescent, assigned female at birth. Our aim is to raise awareness of early symptoms and signs of gender dysphoria and problems faced by transgender people and their families during childhood, leading to gender dysphoria, and we hope our successful approach might improve healthcare provision for these patients, particularly in rural areas.

Keywords: Adolescent; Gender Dysphoria; Gender Identity; Rural Population

RESUMO

A disforia de género adquiriu recentemente maior visibilidade social e mais espaço de debate público, mas permanece subdiagnosticada. Refere-se a um sofrimento e/ou impacto na funcionalidade, causados pela incongruência entre o sexo designado no nascimento e a identidade de género. As manifestações clínicas são variáveis. A falta de formação e investimento em questões de género dificultam o diagnóstico e a abordagem em cuidados de saúde primários, particularmente em comunidades rurais, onde é mais complicado aceder a cuidados especializados e informação. Descrevemos o diagnóstico e a utilização de uma abordagem multidisciplinar, centrada no paciente e família, num adolescente de 12 anos, designado do sexo feminino ao nascimento, com identidade de género masculina. Pretende-se dar a conhecer sinais, sintomas e problemas enfrentados por alguns indivíduos transgénero na infância e respetivas famílias, que podem favorecer disforia de género, esperando que a abordagem utilizada contribua para melhorar os cuidados de saúde a estes utentes, nomeadamente em áreas rurais.

Palavras-chave: Adolescente; Disforia de Género; Identidade de Género; População Rural

INTRODUCTION

Gender dysphoria (GD) is defined by the Diagnostic and Statistical Manual of Mental Disorders 5 Text Revision™ (DSM-5 TR™) as a marked, persistent incongruence between one's experienced/expressed gender and the sex assigned at birth (at least six months) that leads to discomfort, significant distress, and/or impaired functioning.¹

Puberty is related to a major body transformation, including the development of secondary sexual characteristics, which may worsen the child's discomfort and trigger GD. During adolescence, this can manifest in poor socialization, anxiety, depression, suicidal thoughts, and high-risk behaviors (e.g., illicit drug use, unprotected sexual activity).²

Screening and identification of early signs of GD is crucial to a child's or adolescent's wellbeing, but a lack of training makes management of GD in primary care complex and challenging, especially in more traditional, rural areas.³

We describe the diagnosis of GD and the implementation of a patient-centered multidisciplinary and family approach in a transgender adolescent, to enlighten early manifestations of GD and difficulties faced by trans people, but also by other elements of the lesbian, gay, bisexual, transgender, queer or questioning, intersex, asexual, and plus (LGBTQIA+) community, their families and primary care professionals from a rural environment.

CASE DESCRIPTION

AL (fictitious name) is a 12-year-old adolescent assigned female at birth, with no relevant past medical history, studying at the local school with good performance, currently in 8th grade. Being the youngest child of six, from a low-medium socioeconomic background and a rural nuclear family, AL's family history included moderate alcohol consumption (father) and previous major depressive disorder (mother – from 1995 to 2000 related to conflict in peer relationships). The relationship amongst family members was described as close and positive, especially with the mother and the oldest sister, who left the house to study abroad, but it was described as conflicting with the father. The genogram and family relationships are represented in Fig. 1.

1. Medicina Geral e Familiar. Unidade Local de Saúde de Trás-os-Montes e Alto Douro. Chaves. Portugal.

2. Serviço de Psiquiatria da Infância e Adolescência. Unidade Local de Saúde de Trás-os-Montes e Alto Douro. Vila Real. Portugal.

3. Psicologia Clínica. Unidade Local de Saúde de Trás-os-Montes e Alto Douro. Vila Real. Portugal.

✉ **Autor correspondente:** Ana Luísa Ribeiro. analuisapiresribeiro@gmail.com

Recebido/Received: 05/02/2023 - **Aceite/Accepted:** 14/08/2023 - **Publicado Online/Published Online:** 22/01/2024

Copyright © Ordem dos Médicos 2024



The patient presented to a routine yearly primary health care checkup, accompanied by his mother. On examination, there was an evident evasive attitude, manifested by poor investment in speaking, yes or no answers only when questioned, and no effort to elaborate the conversation. The patient was dressed in loose-fitting sports clothing, and when body parts were exposed to perform blood pressure and abdominal examination, multiple patterned scars and some fresh superficial wounds on the forearms and abdomen were evident and appeared to be self-inflicted. It was also possible to ascertain the presence of hirsutism, vulgar facial-dorsal acne and overweight. The mother expressed concerns regarding an isolated episode of alcohol ingestion and a suicidal attempt with pills that, according to the patient, was not planned and occurred following a relationship breakdown with a 19-year-old girl whom the patient had met online, described as the first amorous experience. Both episodes were not disclosed beyond the mother and the child, and no healthcare professionals had been involved. The mother mentioned the child was struggling with anxiety, lack of sleep, poor socialization with peers/family and increased appetite. She also recalled that, as early as 2 years old, AL used to preferably play with the brother's toys instead of the sister's stereotyped 'girly' games, not appreciating dresses, skirts and pink clothes.

We started our approach by assessing the youth's concerns and sources of anxiety, related to being perceived as a girl by others, excessive weight, and acne. We also identified the presence of panic attacks at school as an active problem. A referral was made to the psychiatry department, and the case was discussed with a community psychologist, a nutritionist, and the school health team. Routine child visits were scheduled every two weeks. Laboratory and imaging work-up, including endocrine panel and pelvic suprapubic ultrasound were performed due to virilization signs but the results were unremarkable.

The cause of the scars and the motivation for the suicide attempt were only disclosed by the adolescent during the second medical appointment. The patient stated feeling uncomfortable with breast growth and menstrual bleeding and did not wish to achieve a masculine or female body image, even though he preferred to be addressed by a male name, currently used by the team. The patient also felt very disturbed by comments from colleagues about his appearance (e.g., "You will never be a real man") and constant disagreements with the father, who used to treat the adolescent as 'daddy's girl' before puberty began and the dynamic shifted into one of conflict and distance.

During the first three visits the patient seemed very keen to cooperate. Contrasting with this pleasing behavior towards healthcare professionals, the patient became more depressed at home, revealed irritable mood, insomnia and school grades/performance decreased. At this point the patient was assessed by the local child and adolescent psychiatry department in the context of GD, where the diagnosis was confirmed, and sertraline 25 mg and quetiapine 50 mg were prescribed. A referral was also made by the primary care team to two centers for sexology and sexuality, one at a time, as requested by the mother and AL, in order to overcome breast growth and the development of female characteristics. Both centers declined the referral due to the lack of capacity to respond in reasonable time to patients outside their catchment area and also because AL was already followed by the local child and adolescent psychiatrist, who would be expected to be the one to actually make the referral if deemed necessary, according to one of the centers.

Acne, hirsutism and weight improved with lifestyle modifications and directed therapy (laser and topical treatment), but not mental wellbeing. Even with regular medical appointments, supportive psychotherapy, pharmacological therapy, and the attempt by the community school health team and school board members to promote an inclusive educational environment, the patient felt hopeless, suffering with social judgement and comments at school and beyond, and showed impaired concentration.

According to the mother, the patient continued to enroll in high-risk behaviors (alcohol and cannabis consumption), and the most serious incident culminated with his admission in a comatose state to the local emergency department during school hours due to binge ingestion of alcohol. AL was found alone and covered with ground dirt in an isolated area outside the school by the firefighters who were routinely patrolling the area. On admission, AL presented a blood alcohol content of 3.1 g/L and panel drug testing was negative. There were no signs of non-consensual sexual activity. After regaining consciousness, the adolescent regretted the episode and admitted to having skipped school, drinking alcohol, and smoking cannabinoids with older friends that day, who also reported feeling very ashamed.

That episode was a turning point. The father, previously described by both the mother and the patient as a rigid and conservative person, was called to participate. He revealed not being upset but rather confused and guilty with the severity of the situation. He seemed to realize the suffering his child was dealing with. A judicial complaint concerning the individuals who sold beverages to the minor was filed and the school was also involved. However, stigma towards the adolescent intensified since, living in a small city, the episode of emergency admission spread to the school community and other parents.

A care and safety plan was negotiated with both the parents and the patient. Some aspects that the adolescent thought

to be helpful during the therapeutic process included transitioning to a new school in an urban area, parental support and acceptance of AL's gender expression and choices, and enrolling in pleasurable activities, like football and skating (unavailable in the previous area). The patient committed to sharing concerns with parents or healthcare professionals rather than colleagues or online, to avoid high-risk behaviors and to improve overall school performance. AL's parents and siblings made an effort to remain flexible with his choices, and parental assertiveness was maintained regarding rules and limits on core matters such as drugs and alcohol consumption, setting age-appropriate boundaries for social media use, and establishing limits on when and where the child can go out and with whom they should spend time.

As primary care clinicians, we became not only a source of support for both the patient and his family members, but also a resource in terms of information and guidance. Parental psychological support was also provided. During our approach, the assumption of a sick role was not encouraged, and positive reinforcement of achievements was provided.

One year later, the patient started art lessons at a new school. The depressive symptoms and cognitions (attention, learning and memory) improved. His social and academic skills improved, and AL stated that being addressed to by his preferred social name by teachers and colleagues added a sense of belonging. Parental support and reconnection with father translated in regaining the feeling of protection and love. Due to progressive development of secondary sexual characteristics, AL agreed to be referred to a pediatric endocrinology specialist. To our knowledge, he is not engaged in any sexual or romantic relationship. AL is currently observed every three months, alternating between the family physician, psychiatry and psychologist, and is weaning sertraline and quetiapine. Until the date of article acceptance, no referral was made to the sexology center by the child and adolescent psychiatrist.

The timeline of relevant events is summarized on Table 1.

DISCUSSION

Children with cross-gender identification are at risk of GD. Role playing during childhood and adolescence is not considered unusual, but some individuals might still be confused about their gender identity beyond puberty.^{4,5} Even though watchful waiting and careful observation are reasonable approaches to GD during childhood, withholding medical intervention may do more harm than good.²

Family physicians are in a privileged position to identify gender diversity and maladaptive coping mechanisms and to promote healthy and positive outcomes due to their proximity with families and communities and continuity of care throughout the life cycle.⁶ During childhood, these individuals may frequently prefer clothing, hairstyles, toys, activities, and playmates that are stereotypically considered more appropriate for the opposite sex, reflecting an innate preference of the child.^{5,7} During this stage, particularly after the ages of five to six, their primary source of distress is related to their inability to be perceived by others as their authentic gender, which may result in mood or behavior problems. Gender dysphoria may intensify or emerge as they begin to understand the consistency of the designated gender, for example, through the development of genitalia. The desire for genitals that correspond with gender identity is a distinguished characteristic of GD (designated males may try to hide or even cut off their penises, and designated females may ask for a penis from their parents).^{2,5,8} Consistent, persistent, and insistent gender-diverse behaviors and expression in prepubertal children appear to be associated with continued GD after puberty.^{2,8,9} With the appearance of secondary sexual characteristics, the feeling that internal gender identity does not match their genitalia might be enhanced and therefore aggravate distress, which may become overwhelming, leading to isolation, anxiety, depression, suicidality, and dangerous behavior (e.g., illicit drug use, unprotected sexual activity).⁵ Therefore, early identification of children who are struggling with gender identity may help to prevent adverse mental and/or physical health consequences.

We have learned that, in these situations, a multidisciplinary and multi-dimensional family approach is recommended.^{3,10} The treatment of GD in adults involves psychotherapy, hormonal treatment, and surgical treatment. Parental engagement, education, and coaching is key when approaching children with GD by increasing acceptance of gender fluidity and facilitating harmony between the child and their environment. Working with the school community is also important.³

The case described revealed that the lack of information, community discrimination, social isolation, and segregation during childhood may have a serious impact on mental health. This article also points to the fact already described in the literature that transgender adolescents in rural communities are at risk of drug use and self-harm, of being rejected by family and exploited or abused by adults during sexual initiation. Uncontrolled social media use and a lack of dialogue between family members seem to worsen the problem.

The literature suggests there are disparities in terms of information and mental health access in rural areas due to geographical barriers (transportation, time to travel, accommodation costs), financial difficulties, and education opportunities. The evidence also supports that schools in rural areas present significantly less exposure and access to other transgender

adolescents, resources, and support groups, which means there is a tendency for lower levels of community belongingness.¹¹ An inclusive, comprehensive, patient-and family-centered intervention involving local health resources, school, and all household members contributed to a positive outcome.³

To the best of our knowledge, there are very few reports of GD in Portuguese adolescents. We have described our first case of GD diagnosis and management, a challenging case marked by advances and setbacks, requiring new skills and tools not provided during medical education, to keep up with gender lexicon and indiscriminatory supportive solutions (how to address a transgender patient, surveillance specificities and healthcare resources). As for the difficulties faced, the authors recommend that future efforts must be made to guarantee equal access to mental, sexology, and sexual health services, regardless of the patient's location, and that any barriers to the contact between primary care and secondary care services must fade. A validated questionnaire to screen gender dysphoria and a form to expedite the referral would have been very helpful to our clinical practice, given the limited resources available. Beyond medical practice, it is also essential to invest in the training of healthcare and education professionals and to promote the inclusion and wellbeing of gender minorities.

AUTHOR CONTRIBUTIONS

ALR: Study design, writing and critical review of the manuscript.

CMV, MPR: Writing and critical review of the manuscript.

JG, PR: Study design, writing, critical review and approval of the manuscript.

PROTECTION OF HUMANS AND ANIMALS

The authors declare that the procedures were followed according to the regulations established by the Clinical Research and Ethics Committee and to the Helsinki Declaration of the World Medical Association updated in 2013.

DATA CONFIDENTIALITY

The authors declare having followed the protocols in use at their working center regarding patients' data publication.

PARENTAL AND PATIENT CONSENT

Obtained.

COMPETING INTERESTS

The authors have declared that no competing interests exist.

FUNDING SOURCES

This research received no specific grant from any funding agency in the public, commercial, or not-for-profit sectors.

REFERENCES

1. American Psychiatric Association. Diagnostic and Statistical Manual of Mental Disorders. 5th ed. Washington DC; APA: 2022.
2. Forcier M, Olson-Kennedy J. Gender development and clinical presentation of gender diversity in children and adolescents. [cited 2022 Oct 13]. Available from: <https://www.uptodate.com/contents/gender-development-and-clinical-presentation-of-gender-diversity-in-children-and-adolescents>.
3. Malpas J. Between pink and blue: a multi-dimensional family approach to gender nonconforming children and their families. *Fam Process*. 2011;4:453-70.
4. National Health Service. Gender dysphoria. 2020. [cited 2022 Oct 13]. Available from: <https://www.nhs.uk/conditions/gender-dysphoria/>.
5. Kaltiala-Heino R, Bergman H, Tyolajarvi M, Frisén L. Gender dysphoria in adolescence: current perspectives. *Adolesc Health Med Ther*. 2018;9:31-41.
6. Olson J, Forbes C, Belzer M. Management of the transgender adolescent. *Arch Pediatr Adolesc Med*. 2011;165:171-6.
7. Fridell SR, Owen-Anderson A, Johnson LL, Bradley SJ, Zucker KJ. The playmate and play style preferences structured interview: a comparison of children with gender identity disorder and controls. *Arch Sex Behav*. 2006;35:729-37.
8. Wallien MS, Cohen-Kettenis PT. Psychosexual outcome of gender-dysphoric children. *J Am Acad Child Adolesc Psychiatry*. 2008;47:1413-23.
9. Steensma TD, McGuire JK, Kreukels BP, Beekman AJ, Cohen-Kettenis PT. Factors associated with desistence and persistence of childhood gender dysphoria: a quantitative follow-up study. *J Am Acad Child Adolesc Psychiatry*. 2013;52:582-90.
10. Prasad G, Aparna B. A case report of gender dysphoria with morbid jealousy in a natal female. *Indian J Psychol Med*. 2017;39:800-2.
11. Anderson H. Rural transgender and gender-nonconforming individuals' experiences with social media during adolescence. Minneapolis; Walden University: 2019.

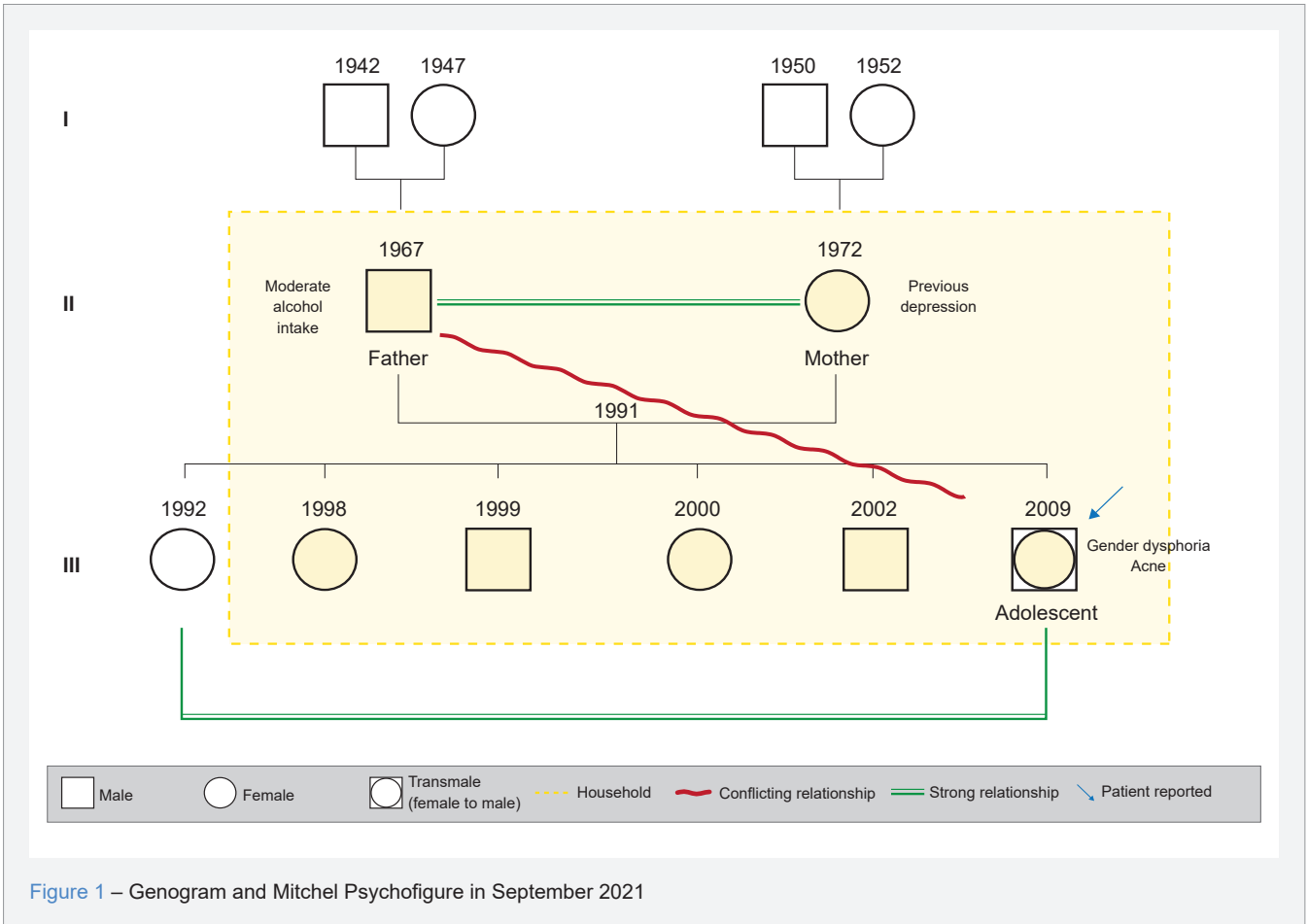


Table 1 – Timeline of relevant events

Timeline of relevant events	
2009	Birth of AL.
2011	From age 2, the mother recalls AL playing with the brother's toys instead of sister's 'girly' games, and not appreciating dresses, skirts or pink clothes.
2019/2020	Social withdrawal began due to the COVID-19 pandemic confinement and oldest sister leaving home to study abroad. Puberty began (menarche by the end of the year), reported anxiety related to female body and conflicts with the father.
7/2021	First amorous experience with a 19-year-old girl.
8/2021	Relationship breakup and beginning of self-mutilation and alcohol consumption. Symptoms of poor concentration, sleep disturbance and irritability. Panic attacks at school. First episode of suicide attempt with pills.
9/2021	Routine checkup 12-13 years old, started regular follow up (15 - 30 days) with family doctor, psychology, nutrition and school health team. Opened up with the family doctor about gender questioning on second appointment.
10/2021	First appointment with child and adolescent psychiatry department, started quetiapine and sertraline. School performance declined.
01/2022	Abandoned psychiatry follow-up, stating not feeling understood or improving. Referred to a center for sexology and sexual health by the family doctor, which alleged lack of resources for patients outside the catchment area and did not accept the referral.
04/2022	Rescheduled a second appointment with previous child and adolescent psychiatry department which confirmed the diagnosis of gender dysphoria. Sense of hopelessness. Suffers with social judgement and comments at school and beyond. Continued to engage in high-risk behaviors (alcohol and tobacco abuse).
05/2022	Admitted, unconscious, to the local emergency department from binge ingestion of alcohol and cannabinoids during school hours. Involvement of the father, negotiation and setting of a care and safety plan. Cessation of consumptions. New referral by the family doctor to a different center of sexology and sexual health, which did not accept the referral as AL was already being followed by a psychiatrist at the local hospital.
06/2022	Episode of binge drinking and consumptions spreading to school community and other parents, intensifying the stigma towards AL. Continued implementation of the care plan.
09/2022	Transition to a new urban school and enrollment in pleasurable activities. Started to sense acceptance by peers, family and school members. Improvement of depressive symptoms and cognitions. Gave two interviews to the local university to share the experience of being transgender.