



eISSN 2282-2054

<https://www.pagepressjournals.org/index.php/ecj/index>

Publisher's Disclaimer. E-publishing ahead of print is increasingly important for the rapid dissemination of science. The **Early Access** service lets users access peer-reviewed articles well before print / regular issue publication, significantly reducing the time it takes for critical findings to reach the research community.

These articles are searchable and citable by their DOI (Digital Object Identifier).

The **Emergency Care Journal** is, therefore, e-publishing PDF files of an early version of manuscripts that undergone a regular peer review and have been accepted for publication, but have not been through the typesetting, pagination and proofreading processes, which may lead to differences between this version and the final one.

The final version of the manuscript will then appear on a regular issue of the journal.

E-publishing of this PDF file has been approved by the authors.

Emerg Care J 2024 [Online ahead of print]

To cite this Article:

Almadwahi N, Alhanash S, Barat A, et al. **Acute limb ischemia due to left brachial artery occlusion in a 40-year-old female patient: a case report.** *Emerg Care J* doi: 10.4081/ecj.2024.11930

 ©The Author(s), 2023

Licensee [PAGEPress](#), Italy

Note: The publisher is not responsible for the content or functionality of any supporting information supplied by the authors. Any queries should be directed to the corresponding author for the article.

All claims expressed in this article are solely those of the authors and do not necessarily represent those of their affiliated organizations, or those of the publisher, the editors and the reviewers. Any product that may be evaluated in this article or claim that may be made by its manufacturer is not guaranteed or endorsed by the publisher.

Acute limb ischemia due to left brachial artery occlusion in a 40-year-old female patient: a case report

Nabil Almadwahi,¹ Sallam Alhanash,² Ali Barat,² Mohammed Alshujaa,² Mohammed Najran,² Ali Fadhel,² Eman Al-Jammal,³ Faisal Ahmed,⁴ Abdulfattah Altam,⁵ Mohamed Badheeb⁶

¹Department of Vascular Surgery, Al-Thora Modern Hospital, School of Medicine, Sana'a University of Medical Sciences, Sana'a, Yemen; ²Department of General Surgery, Dhamar General Hospital, Faculty of Medicine, Tamar University, Tamar, Yemen; ³Student Research Committee, Dhamar General Hospital, Faculty of Medicine, Tamar University, Tamar, Yemen; ⁴Department of Urology, School of Medicine, Ibb University, Ibb, Yemen; ⁵Department of General Surgery, School of Medicine, 21 September University, Sana'a, Yemen; ⁶Department of Internal Medicine, Yale New Haven Health, Bridgeport Hospital, Bridgeport, USA

Correspondence: Sallam Alhanash, Department of General Surgery, Dhamar General Hospital, Faculty of Medicine, Tamar University, Tamar, Yemen.

Tel/Fax: +967.4428950

E-mail: Sallamalhansh95@gmail.com

Keywords: case report; acute limb ischemia; embolectomy; brachial artery occlusion.

Conflict of interest: the authors declare no potential conflict of interest, and all authors confirm accuracy.

Ethics approval and consent to participate: no ethical committee approval was required for this case report by the Department because this article does not contain any studies with human participants or animals. Informed consent was obtained from the patients included in this study.

Patient consent for publication: the patient gave her written consent to use her data for the publication of this case report and any accompanying images.

Availability of data and materials: all data underlying the findings are fully available.

Contributions: patient management: SA, NA, MN, EA, and NM; data collection: AF, MA, and FA; manuscript drafting: FA, AA, and MB; manuscript revision: AB and M. All authors read and approved the final version of the manuscript.

Abstract

Acute upper limb ischemia (ALI) due to brachial artery occlusion is a rare but catastrophic condition that poses a significant threat to limb viability and can result in limb amputation or death. Accurate diagnosis and timely intervention are crucial to avoid catastrophic consequences. Literature on ALI due to brachial artery occlusion is scant and usually related to atrial fibrillation. We report a 40-year-old female presented with sudden onset left upper limb pain, change in color, and neurological deficits in the last three days. A color Doppler ultrasound revealed a complete occlusion of the left brachial artery with echogenic thrombosis suggestive of ALI. The patient urgently underwent a thrombectomy with an uneventful outcome. In conclusion, even though ALI due to brachial artery occlusion is rare, a heightened level of suspicion, precise diagnosis, and timely management are essential to prevent any fatal consequences.

Introduction

Acute arterial occlusion, also known as acute limb ischemia (ALI), is a vascular emergency characterized by a sudden loss of limb perfusion within two weeks following an inciting event that is

usually related to atrial fibrillation, underlying hypercoagulable or occlusive states.^{1,2} The occurrence of ALI is estimated to be between 10 and 14 cases per 100,000 individuals annually and is predominantly observed in the lower extremities.³ Conversely, upper limb ALI is less commonly observed and may be associated with a broader spectrum of etiologies, which are often unrecognized.² Furthermore, managing ALI in the upper limbs presents additional challenges, including the determination of limb viability, coupled with the underlying etiology, both of which, can significantly influence the therapeutic approach in these cases.⁴

The clinical manifestation and symptoms of arterial occlusion are contingent on the specific artery involved.⁵ ALI of the brachial artery typically being of cardiac origin, while trauma, vasculitis, aneurysms, and iatrogenic injuries are other causes of acute thrombosis.⁵ Literature on upper extremity ALI due to spontaneous brachial artery occlusion is scant with a few published reports.⁶ In this case, we report a case of ALI due to acute left brachial artery occlusion in a 40-year-old female.

Case report:

Patient Information: A 40-year-old female presented with sudden onset left upper limb pain for three days associated with a color change, and neurological deficits (swelling, numbness, and weakness). The pain was progressively worsening and he was unresponsive to medication. She also mentioned a history of low-grade fever, chest pain, and dyspnea in the last week. No history of palpitations or hemoptysis was observed. She denied any history of abortion, claudication, cardiovascular, or autoimmune diseases. She had a history of smoking, Khat consumption, and oral contraceptive (OCP) use for 29 years, which was discontinued three months before the onset of the symptoms.

Clinical findings: The patient manifested complete wakefulness upon presentation. The initial evaluation of the patient's vital signs indicated a body temperature of 37.8 °C, an oxygen saturation level of 98%, a respiratory rate of 18 respiration /min, a blood pressure of 130/90 mmHg, and an asymmetry in the pulse, with an absence of a pulse in the left upper extremity (Brachial, ulnar, and radial arteries) and a regular rhythm of 68 beats/min in the right upper extremity. The affected upper limb presented with symptoms of coldness, cyanosis, and non-fixed mottling, accompanied by delayed capillary refill exceeding four seconds. Paresthesia was clinically observable and a muscle force grading was one out of four.

Diagnostic assessment: Erythrocyte sedimentation rate (ESR): 20 mm/ 1st hour and C-reactive protein (CRP): 24 mmol/l. The laboratory data of complete blood cell, renal function test, liver function test, hypercoagulability workup, and coagulation tests, among other blood tests, exhibited normal ranges. The electrocardiography results were also found to be normal sinus rhythm. The left brachial artery was completely occluded with echogenic thrombosis as demonstrated by color Doppler ultrasound examination, which was indicative of ALI. The condition was classified using the Rutherford classification system and was determined to be grade IIb which indicates an immediate threat that can be mitigated with prompt revascularization.⁷

Therapeutic Interventions:

Initial treatment commenced with a bolus intravenous infusion of unfractionated Heparin 5000 units stat followed by a continuous infusion of 1000 units per hour and Atorvastatin PO 80 mg stat and 40 mg daily. Upon obtaining radiological confirmation of ALI, given that the ALI was classified as grade IIb, an urgent surgical intervention was warranted.

Surgical interventions:

The surgical intervention includes a multiple-pass Fogarty thrombectomy followed by local alteplase infusion (Figure 1).

Follow-up and outcome:

Heparin infusion was continued to achieve the desired effect of Partial thromboplastin time (PTT) which was 2 to 2.5 times higher than the baseline. On the second postoperative day, the left brachial, radial, and ulnar artery pulses were detectable without any signs of cyanosis. The sensory and motor assessment evinced complete restoration. The color Doppler US indicated a normal follow and a positive triphasic signal in both radial and ulnar arteries. No additional thrombotic events affecting either arterial or venous circulation were documented during the patient's hospitalization.

The postoperative follow-up rheumatologic tests were within normal range and only a weakly positive antinuclear antibody (ANA) with a titer of 1:80 (IgG anticardiolipin antibodies:13 (Normal 15 – 20 GPL U/mL), IgM anticardiolipin antibodies: 7.39 (Normal: 12.5 – 20 MPL U/mL), β 2-GPI: anti-beta 2 glycoprotein I: 16 (Normal: \leq 20 SGU U/mL), lupus anticoagulants:34 (Normal: 20-39 GPL units). Laboratory tests for syphilis, TB, HIV, and leprosy all came back negative. Computed tomography angiography (CTA) of the abdomen, pelvis, and lower extremities was performed and revealed a normal aorta and main branches. Other diagnostic tests included a normal ECG and a transthoracic

echocardiography, which revealed no arrhythmias or heart thrombi. Based on these findings, the patient was transferred to a rheumatologist, where a hypercoagulable state was suspected for diagnosis, and treatment with anticoagulation was commenced. The patient was followed by an internist for a year and had no problems or symptoms of recurrence.

Discussion

Our report highlights a distinctive presentation of upper ALI due to acute brachial artery occlusion in a middle-aged female. Upper limb ALI accounts for a minority of cases, with a higher incidence reported among older patients, averaging 75 years old.² The presentation of ALI in the upper limb does not significantly differ from that in the lower extremities. The classical presentation of excruciating pain, associated with pallor, pulselessness, and neurological deficit, is sufficient to establish the diagnosis of ALI, as observed in our case.^{2,6} Nevertheless, ALI usually presents in a spectrum with variable degrees of severity, typically necessitating further diagnostic imaging to assess limb viability and the level of occlusion.² The Rutherford classification has been extensively utilized in assessing the risk for ALI, categorizing it as viable (class I), threatened (class II), marginally threatened (IIa), immediately threatened (IIb), and irreversible (class III) based on vascular exam, Doppler US findings, and sensorimotor deficits.⁷

Overall, ALI represents a consequence of an underlying etiology, typically a cardio-embolic phenomenon, which is reported in up to 60% of patients.² This manifestation is particularly prevalent among elderly individuals suffering from atrial fibrillation, which constitutes approximately 80% of cardioembolic etiologies, in conjunction with valvular heart disease or prior ischemic heart disease that leads to cardiac wall motion abnormalities.⁵ Additionally, atherosclerotic disease, aneurysmal formations, traumatic injuries, and previous vascular interventions are known contributing factors for ALI in the upper limbs.⁵

Previous reports have shown inconsistencies in the most commonly involved artery in upper limb ALI, with some reports observing a higher incidence of brachial artery occlusion.³ Nevertheless, most of these cases were reported in patients with existing cardiac arrhythmias, atherosclerotic disease, prior trauma, or coronary or vascular interventions.^{1,8} In contrast, there are few reports of ALI in the native brachial artery.⁶ Notably, arterial occlusion secondary to autoimmune-related vasculitis has been reported in the literature.⁶ The challenge in diagnosing such cases stems from their non-specific clinical presentation and the necessity for a heightened index of suspicion. Furthermore, the diagnostic process for autoimmune conditions is typically extensive and beyond the scope of many medical facilities, presenting a critical issue considering the urgent nature of ALI.¹ In addition, most of these cases involve small arteries, causing distal (i.e., digit) ischemia.^{1,2} In the presented case, the patient demonstrated a classic presentation of ALI, devoid of any discernible cardiac etiology, preceding

trauma, endovascular intervention, or a personal or familial history suggestive of a hypercoagulable state. In addition, the proximal arterial occlusion represented an atypical presentation, that was concerning for an underlying hypercoagulability.

A limited number of risk factors have been observed to influence the occurrence of ALI, including anatomical location, gender, and various risk factors such as trauma, older age, smoking, obesity, high levels of cholesterol, diabetes, and hypertension.^{1,2} Additional factors that could put individuals at increased risk include heart failure, stroke, arthritis, fibromuscular dysplasia, intra-cardiac lesions, and malignant tumors.⁹ Notably, during the COVID-19 era, an increased incidence of upper limb ALI was observed, particularly affecting multiple arterial segments, especially in patients with coexisting chronic atherosclerotic disease.¹⁰ Our patient had a history of smoking and oral contraceptive (OCP) use, both of which are associated with hypercoagulability. It is essential to acknowledge that smoking has been linked to chronic atherosclerosis, a finding similarly observed with oral OCP use.¹¹ Prior epidemiological studies have also identified associations between smoking, OCP use, and autoimmune diseases.^{9,11} Allegedly, while our patient's presentation and further diagnostic work-up were not indicative of specific autoimmune conditions, it might be crucial to consider the relative variability of time and duration of auto-antibodies development, in addition to the possibility of the seronegative condition.¹² These patients, as in our condition, require prolonged and close monitoring.

The delayed diagnosis or treatment of ALI is associated with the risk of limb amputation and poor clinical outcomes. It is important to note that while the clinical examination has a crucial role in ALI assessment, imaging is required to assess the limb viability, and occlusion levels, which can be achieved using Doppler US with a high sensitivity and specificity of 88% and 96%, respectively, and was utilized in our patient.⁶ Initial management typically involves immediate anticoagulation with unfractionated heparin. Despite the widespread adoption of this practice, there is a notable absence of prospective controlled trials substantiating its efficacy.⁴ The choice of subsequent intervention is influenced by the location of the occlusion, the presumed etiology, and available surgical expertise. The European Society for Vascular Surgery has accorded Fogarty balloon thrombo-emblectomy a class IIb recommendation. This method has been extensively employed as a primary treatment for upper limb ALI and was performed on our patient, who was categorized as immediately threatened (IIb), necessitating urgent surgical intervention.⁴ Alternative approaches include catheter-directed thrombolysis. While this method has demonstrated relatively positive outcomes, most studies involving upper extremity cases included patients with milder Rutherford classes (*i.e.*, I or IIa).⁴ Furthermore,

there are no studies, to the best of our knowledge, that have assessed its long-term outcomes. Notably, the long-term outcomes for lower extremity ALI have been less than favorable in retrospective studies.¹³ Many experts favor thromboembolectomy, particularly for brachial artery occlusion, due to the easier surgical access and lower risk of complications.¹⁴ To date, there are no head-to-head trials comparing thromboembolectomy with catheter-directed thrombolysis for upper limb ALI. However, a Cochrane meta-analysis encompassing five clinical trials for lower limb ALI indicated lower incidences of cerebrovascular accidents, major bleeding, and embolization in the thromboembolectomy group.¹⁵ Further prospective studies are needed to establish the optimal treatment of upper limb ALI.

Conclusions

Even though ALI due to brachial artery occlusion is rare, a heightened level of suspicion, precise diagnosis, and timely management are essential to prevent any fatal consequences. A multidisciplinary approach is essential to address the complexities associated with the disease and its treatment.

References:

1. Smith DA, Lilie CJ. Acute Arterial Occlusion. In, StatPearls. Treasure Island (FL) ineligible companies. Disclosure: Craig Lilie declares no relevant financial relationships with ineligible companies.: StatPearls Publishing Copyright © 2023, StatPearls Publishing LLC.; 2023
2. Huang D, Ruzicka J, León L, Ganti L. Acute Upper Extremity Arterial Occlusion Diagnosed on POCUS in the Emergency Department. *Pocus J* 2023;8:25-9.
3. Bae M, Chung SW, Lee CW, et al. Upper Limb Ischemia: Clinical Experiences of Acute and Chronic Upper Limb Ischemia in a Single Center. *Korean J Thorac Cardiovasc Surg* 2015;48:246-51.
4. Björck M, Earnshaw JJ, Acosta S, et al. Editor's Choice - European Society for Vascular Surgery (ESVS) 2020 Clinical Practice Guidelines on the Management of Acute Limb Ischaemia. *Eur J Vasc Endovasc Surg* 2020;59:173-218.
5. Licht PB, Balezantis T, Wolff B, et al. Long-term outcome following thromboembolectomy in the upper extremity. *Eur J Vasc Endovasc Surg* 2004;28:508-12.
6. Mughal AY, Kishi P. Acute Brachial Artery Occlusion on Point-of-Care Ultrasound in the Emergency Department: A Case Report. *Clin Pract Cases Emerg Med* 2022;6:302-4.

7. Rutherford RB. Clinical staging of acute limb ischemia as the basis for choice of revascularization method: when and how to intervene. *Semin Vasc Surg* 2009;22:5-9.
8. Senarslan DA, Yildirim F, Tetik O. Three Cases of Large-Diameter True Brachial and Axillary Artery Aneurysm and a Review of the Literature. *Ann Vasc Surg* 2019;57:273.e11-.e15.
9. Williams WV. Hormonal contraception and the development of autoimmunity: A review of the literature. *Linacre Q* 2017;84:275-95.
10. Aliasgarzadeh S, Arabzadeh A, Fathibitaraf S, Negaresh M. Sudden development of the upper and lower limb ischemia as the first manifestation of COVID-19 infection. *Int J Surg Case Rep* 2022;96:107332.
11. Pereira-da-Silva T, Napoleão P, Costa MC, et al. Cigarette Smoking, miR-27b Downregulation, and Peripheral Artery Disease: Insights into the Mechanisms of Smoking Toxicity. *J Clin Med* 2021;10.
12. McLafferty RB, Edwards JM, Taylor LM, Jr., Porter JM. Diagnosis and long-term clinical outcome in patients diagnosed with hand ischemia. *J Vasc Surg* 1995;22:361-7; discussion 7-9.
13. Schrijver AM, de Vries JP, van den Heuvel DA, Moll FL. Long-Term Outcomes of Catheter-Directed Thrombolysis for Acute Lower Extremity Occlusions of Native Arteries and Prosthetic Bypass Grafts. *Ann Vasc Surg* 2016;31:134-42.
14. Vennesland JB, Søreide K, Kvaløy JT, et al. A Population-Based Study of Incidence, Presentation, Management and Outcome of Primary Thromboembolic Ischemia in the Upper Extremity. *World J Surg* 2019;43:2320-7.
15. Darwood R, Berridge DC, Kessel DO, et al. Surgery versus thrombolysis for initial management of acute limb ischaemia. *Cochrane Database Syst Rev* 2018;8:Cd002784.

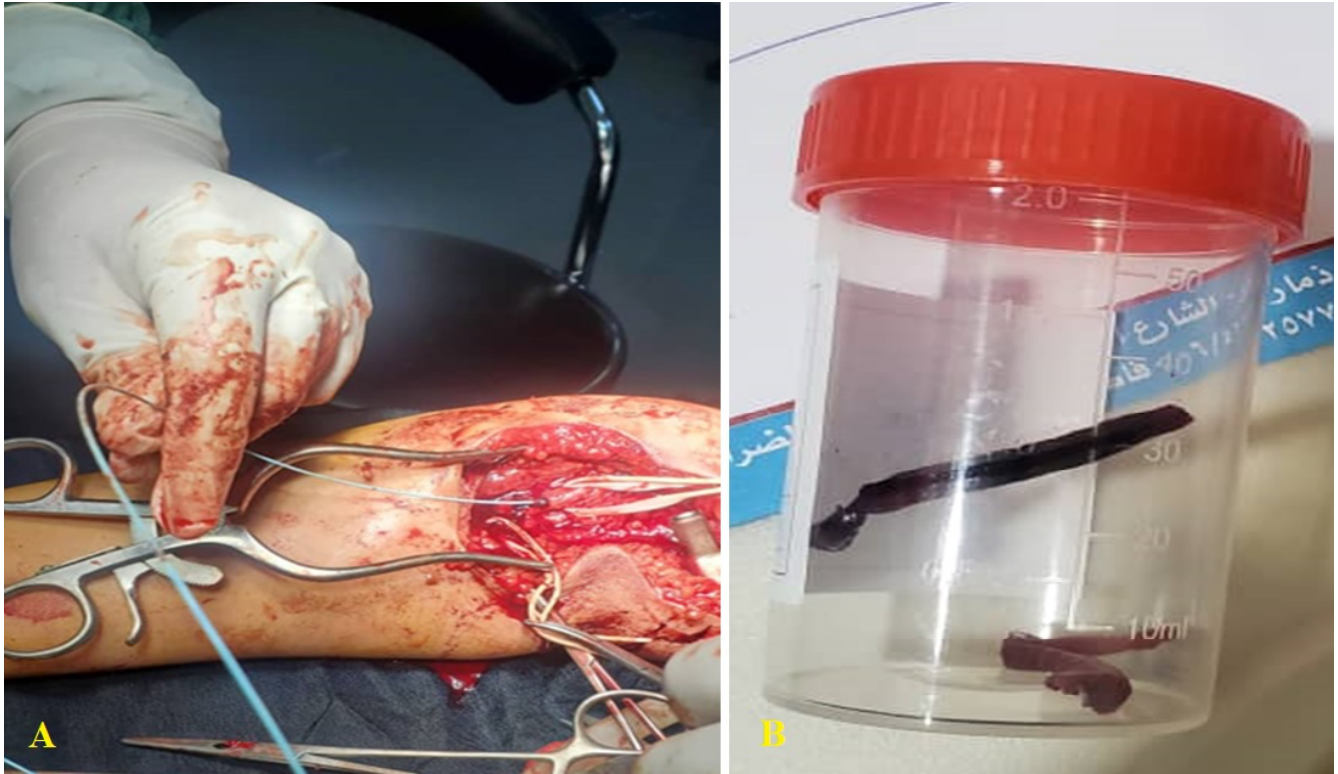


Figure 1. Intraoperative photos showing A) the thrombectomy of brachial, radial, and ulnar arteries; B) the removed clots.

Submitted: 8 October 2023

Accepted: 22 December 2023

Early access: 22 January 2024