

## Use of a Compact, Lightweight X-ray Unit to Reduce the Risk of Five Invasive Procedures in the Emergency Room

Yutaka Igarashi<sup>1</sup>, Shimpei Ikeda<sup>1,2</sup>, Kunio Hirai<sup>3</sup>, Naoki Tominaga<sup>1,4</sup>,  
Taiki Mizobuchi<sup>1</sup>, Kenta Shigeta<sup>1</sup>, Hiromoto Ishii<sup>1</sup> and Shoji Yokobori<sup>1</sup>

<sup>1</sup>Department of Emergency and Critical Care Medicine, Nippon Medical School, Tokyo, Japan

<sup>2</sup>Department of Radiology, Nippon Medical School Chiba Hokusoh Hospital, Chiba, Japan

<sup>3</sup>Division of Radiological Technology, Nippon Medical School Hospital, Tokyo, Japan

<sup>4</sup>Department of Emergency and Critical Care Medicine, Saitama City Hospital, Saitama, Japan

**Background:** Many invasive procedures performed in the emergency room (ER) have potential risks and complications. Because of their limitations, in particular size, portable X-ray devices are generally not used during such procedures. However, miniaturized units enable physicians to obtain X-ray images without assistance.

**Methods:** We developed a safe, compact, and lightweight X-ray unit that was used during five invasive procedures in the ER. In all procedures, a chest X-ray image was obtained, to confirm the utility of the unit.

**Results:** Case 1 (central venous catheter placement): After needle and guidewire insertion and catheter placement, the location of the catheter could be confirmed. Case 2 (chest tube insertion): During insertion of a chest tube into the pleural space, the tip of the thoracic tube was confirmed to be at the correct location. Case 3 (percutaneous tracheostomy or cricothyroidotomy): After needle and guidewire insertion, the guidewire was visualized in the right main bronchus and was inserted into the trachea. Case 4 (resuscitative endovascular aortic balloon of the aorta): The captured image revealed that the catheter was located in zone I before balloon inflation. Case 5 (Sengstaken-Blakemore tube): The image revealed that the balloon was located in the stomach.

**Conclusions:** The portable X-ray unit improved medical safety during invasive procedures frequently performed in the ER. (*J Nippon Med Sch* 2022; 89: 555–561)

**Key words:** thoracic radiography, complications, central venous catheters, chest tubes, tracheotomy

### Introduction

Critically ill patients, regardless of status, are first transferred to the emergency room (ER) for diagnosis and resuscitation. Many invasive ER procedures performed for such patients are associated with potential risks, including post-procedural complications<sup>1,2</sup>. Intraoperative imaging, such as ultrasonography and fluoroscopy, has reduced the incidences of some complications. However, patients must be transported to the fluoroscopy room. In addition, because ultrasound waves can be disrupted by air and gas and do not penetrate deeply, some areas can-

not be visualized. Although intraoperative radiology does not require patients to be moved and can capture images from areas that cannot be visualized with ultrasound, its use has been limited because of the size of conventional devices and the need for technicians<sup>3</sup>.

Portable X-ray devices have become increasingly miniaturized, permitting physicians to obtain X-ray images anywhere with ease<sup>4,6</sup>. Thus, intraoperative X-ray devices offer safety benefits during medical procedures. However, little is known about the use of portable X-ray devices during invasive procedures. We developed and

Correspondence to Yutaka Igarashi, Department of Emergency and Critical Care Medicine, Nippon Medical School, 1-1-5 Sendagi, Bunkyo-ku, Tokyo 113-8603, Japan

E-mail: igarashiy@nms.ac.jp

[https://doi.org/10.1272/jnms.JNMS.2022\\_89-504](https://doi.org/10.1272/jnms.JNMS.2022_89-504)

Journal Website (<https://www.nms.ac.jp/sh/jnms/>)



Fig. 1

Photograph of the compact, lightweight X-ray unit and another widely used portable X-ray device (Sirius 130 HP, Hitachi, Tokyo, Japan). The compact and lightweight X-ray unit comprises an X-ray tube (CALNEO Xair, Fujifilm Corporation, Tokyo, Japan), laptop computer, and flat panel detector (CALNEO Smart, Fujifilm Corporation, Tokyo, Japan).

assessed the safety of a compact, lightweight X-ray device and report its utility for frequently performed invasive procedures in the ER.

## Materials and Methods

### Setting

This study was conducted in a single center and was approved by the Ethics Committee of Nippon Medical School Hospital, Japan (30-09-993). In Japan, only doctors and radiology technicians are authorized to operate X-ray devices.

### Medical Equipment

The compact, lightweight X-ray unit has been commercialized and comprises three parts: an X-ray tube, weighing only 3.5 kg (CALNEO Xair, Fujifilm Corporation, Tokyo, Japan); a laptop with which the operator controls the functioning of the device; and a flat panel (CALNEO Smart, Fujifilm Corporation, Tokyo, Japan) (Fig. 1). The preset parameters were 90 kV and 0.5 mAs for the chest, 90 kV and 2.5 mAs for the abdomen, and 70 kV and 2 mAs for the extremities. Although conventional mobile X-ray units require technical knowledge, such as kV and mAs settings before examination, this X-ray unit is superior in terms of usability. This device has received marketing approval from the Pharmaceuticals and Medical Devices Agency of Japan.

## Procedures

In this study, chest radiographs were taken to confirm the location of the catheter or tube tip during five frequently performed invasive ER procedures. The procedures were central venous catheter (CVC) (or peripherally inserted central catheters) placement, chest tube insertion, percutaneous tracheostomy (or cricothyrotomy), resuscitative endovascular balloon occlusion of the aorta (REBOA), and Sengstaken-Blakemore (SB) tube insertion.

While performing the procedure, a physician wearing an X-ray radiation-protective apron placed the flat panel detector of the unit under the patient and the X-ray tube above. When the guidewire, catheter, or tube was inserted, the physician selected the radiation intensity, pressed the relevant button, and immediately viewed the image on the laptop screen. If the catheter and tube tips were wrongly positioned, another X-ray image was taken after repositioning.

## Results

### Case 1: CVC Placement

A 48-year-old woman was intubated and received mechanical ventilation after surgical clipping for a cerebral aneurysm. The patient required CVC placement in the right internal jugular vein. A physician set the X-ray devices, an ultrasound device, and a flat panel detector under the patient during preoperative preparation (Fig. 2). When the needle and guidewire were inserted, a chest radiograph showed the guidewire in the superior vena cava (Fig. 3A). When the catheter was placed, a chest radiograph showed that the catheter tip was in the correct location (Fig. 3B).

### Case 2: Chest Tube Insertion

A 70-year-old woman presenting with difficulty breathing was diagnosed with congestive heart failure and bilateral pleural effusion. The effusion was drained because oxygen was required to maintain a percutaneous saturation of over 90%. During insertion of the chest tube into the pleural space, an intraoperative chest radiograph confirmed that the tip of the thoracic tube had reached the correct location (Fig. 4).

### Case 3: Percutaneous Tracheostomy

A 60-year-old man diagnosed with intracerebral hematoma was intubated and received mechanical ventilation. A tracheostomy was required for prolonged endotracheal intubation. A Pean clamp forceps was placed at the insertion site, and a chest radiograph was taken. Forceps were used to determine the position of the tip of the intuba-

tion tube in relation to the insertion site (Fig. 5A). The intubation tube was withdrawn by 3.5 cm because there was a 3-cm gap between the tip of the intubation tube and insertion site (Fig. 5B). When the needle and guidewire were inserted, an intraoperative chest radiograph confirmed the presence of the guidewire in the right main bronchus (Fig. 5C). After adequate dilatation, the dilator was removed, and a tracheostomy tube was inserted into the trachea above the guiding catheter.

**Case 4: REBOA**

A 70-year-old man was transported to the ER after a

traffic accident. Computed tomography (CT) revealed splenic and renal hemorrhage and pelvic fracture. The patient's blood pressure decreased after the CT scan. A REBOA catheter was inserted and advanced into the aorta, after which a 7-French introducer sheath was inserted through the right femoral artery. An intraoperative chest radiograph revealed the REBOA catheter in zone I extending from the origin of the left subclavian artery to the celiac artery before balloon inflation (Fig. 6). After balloon inflation, the patient's blood pressure increased,

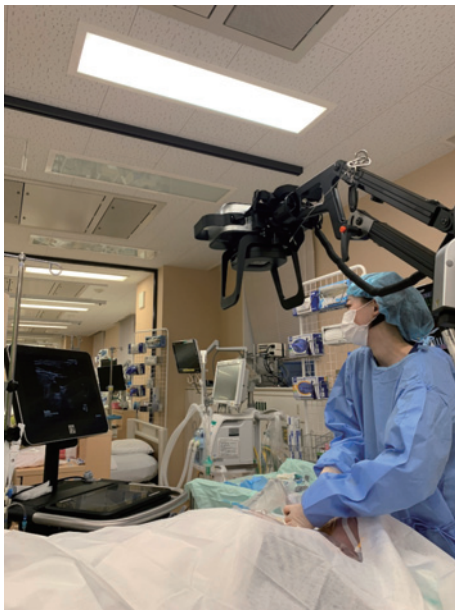

Fig. 2

Setting for the compact, lightweight X-ray unit and ultrasonography device. A physician positions the X-ray unit, ultrasound device, and flat panel detector under the patient during preoperative preparation.

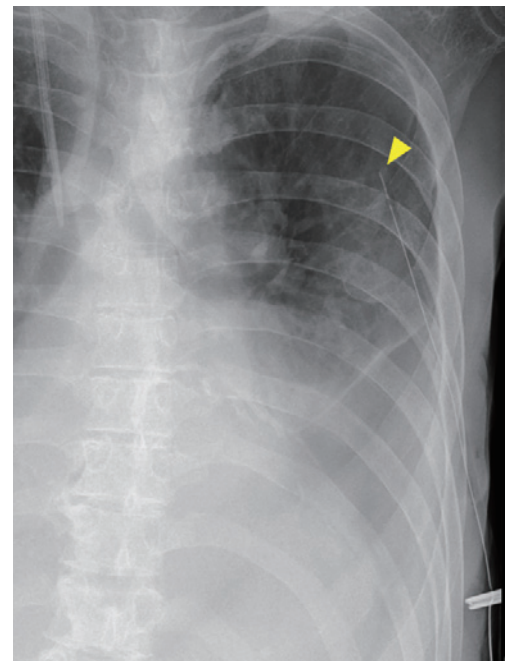


Fig. 4

Chest tube insertion. Chest X-ray image showing bilateral pleural effusion. The tip of the chest tube (arrowhead) is located at the left apical pulmonary lesion.

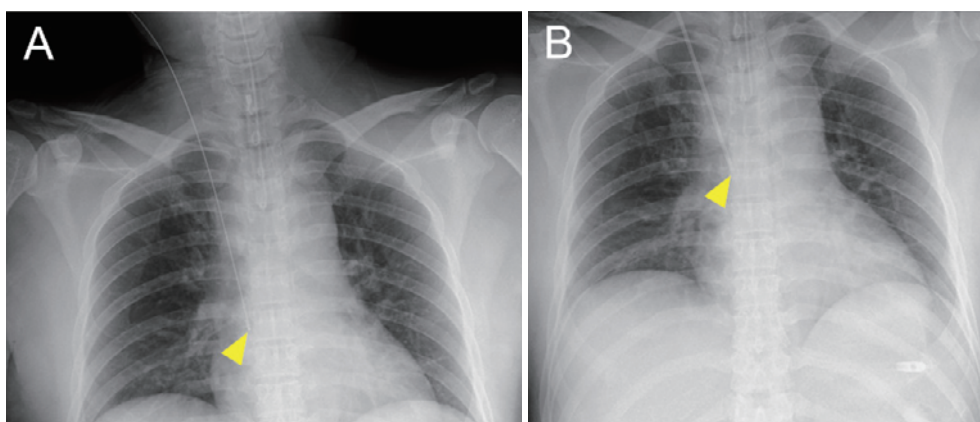


Fig. 3

Central venous catheter placement. (A) Chest X-ray image showing the tip of the guidewire (arrowhead) in the superior vena cava. (B) Chest X-ray image showing the catheter tip (arrowhead) in the superior vena cava.



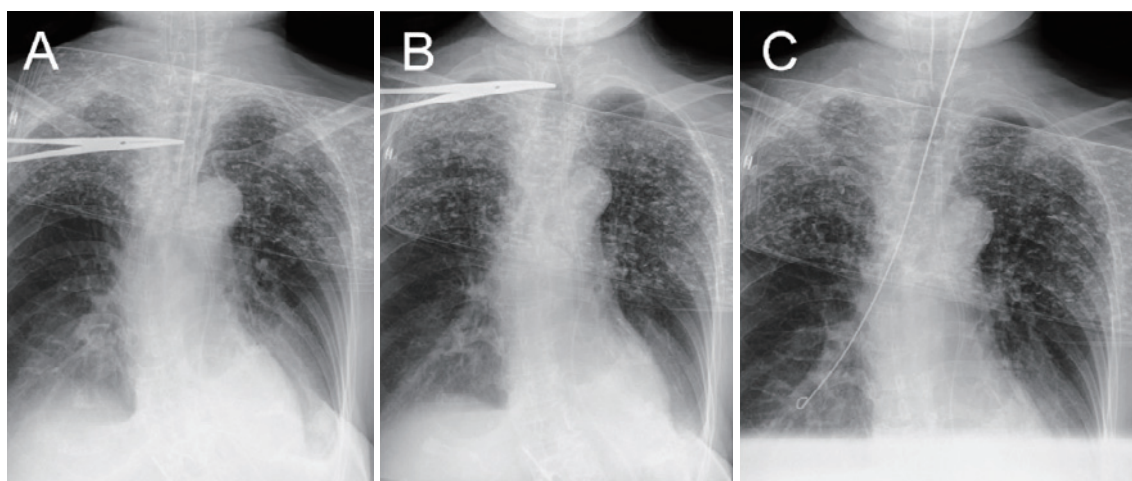


Fig. 5

Percutaneous tracheostomy. (A) Image showing a distance of 3 cm between the tip of endotracheal tube and Pean clamp forceps. (B) Image showing the location of the tip of the endotracheal tube in relation to the Pean clamp forceps after withdrawing the endotracheal tube by 3.5 cm. (C) Chest X-ray image showing the guidewire in the right main bronchus.

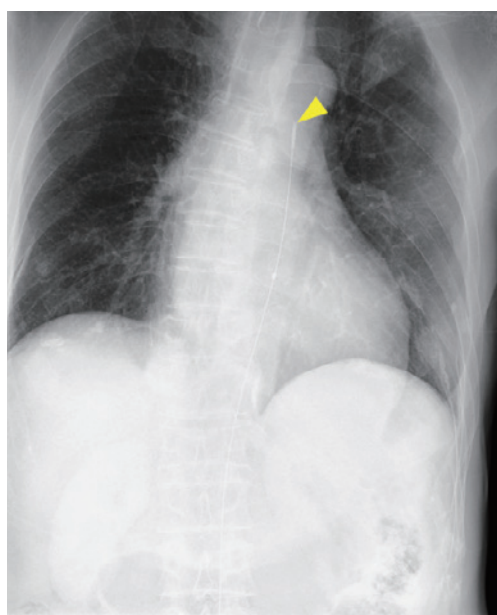


Fig. 6

Resuscitative endovascular balloon occlusion of the aorta. Chest X-ray image showing the tip of the resuscitative endovascular balloon occlusion of the aorta catheter (arrowhead) in zone I.

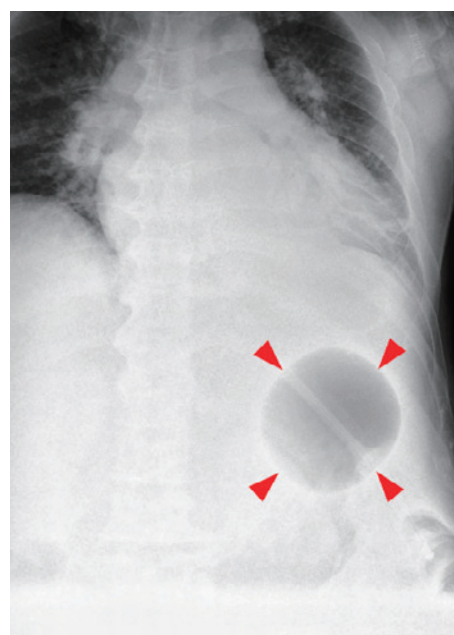


Fig. 7

Sengstaken–Blakemore (SB) tube insertion. Chest X-ray image showing the balloon of the SB tube (arrowhead) in the stomach.

and splenectomy could be performed.

#### Case 5: SB Tube Insertion

A 48-year-old man diagnosed with alcoholic cirrhosis and esophageal varices presented with hematemesis and was transferred to our hospital. He had hypotension and anemia with a hemoglobin level of 3.1 g/dL. As it was difficult to stop the bleeding with an endoscope, an SB tube was inserted. After balloon inflation, an intraopera-

tive chest radiograph showed that the balloon was located in the stomach (Fig. 7). The SB tube was then pulled, and the esophageal balloon was inflated. Subsequently, his blood pressure increased and hemoglobin level normalized. On the next day, endoscopic variceal ligation was performed successfully.

### Discussion

An intraprocedural visualization technique that uses a compact, lightweight X-ray unit was used during five frequently performed invasive procedures. Observations from these case studies suggest that this technique reduces the risk of complications during invasive procedures. Below, we review the complications of each procedure and describe how a compact, lightweight X-ray unit was useful for preventing complications.

**CVC insertion:** The safety and ease of procedures for CVC insertion have improved. However, the rate of complications for CVC insertion remains high. A retrospective cohort study reported an overall complication rate of 15%. The complications included failure to place the catheter (22%), arterial puncture (5%), catheter malposition (4%), pneumothorax (1%), subcutaneous hematoma (1%), hemothorax (<1%), and cardiac arrest (<1%). Ultrasound-guided techniques have reduced the risk of inadvertent arterial puncture (risk ratio [RR] 0.21, 95% confidence interval [CI] 0.06 to 0.82;  $P = 0.02$ ) and hematoma (RR 0.26, 95% CI 0.09 to 0.76;  $P = 0.01$ ) for the subclavian vein. However, ultrasound-guided techniques cannot detect misplacement of the CVC or ensure placement at the correct location. Fluoroscopy is often used for insertion of peripherally inserted central catheters, and a randomized controlled trial found that mispositioning of the catheter tip was significantly less frequent for fluoroscopy-guided technique than for blind bedside technique<sup>7</sup>. An X-ray-guided technique, in contrast, might avoid arrhythmias induced by overly deep insertion of guidewires and catheters<sup>8</sup>. Moreover, this technique allows physicians to spot abnormal findings, even in cases of iatrogenic pneumothorax.

**Chest tube insertion:** Chest tube drains are indicated for hemothorax, massive pleural effusion, large or progressive pneumothorax, and postoperative management in thoracic surgery. All intrathoracic organs, including the lung, diaphragm, heart, large vessels, and esophagus, are potentially at risk of injury during chest tube insertion. Chest tube placement in the right ventricle, although rare, is life-threatening. Early (<24 h after placement) complications occurred in 3% and 8% of cases in a previous study<sup>9</sup>. Although point-of-care ultrasound during tube insertion has reduced complications<sup>10</sup>, it cannot confirm placement of the tip of the chest tube, which could be placed at an inappropriate location, such as within the interlobar space. Correct placement of the tip of the chest tube can be confirmed with a compact, lightweight X-ray unit.

**Percutaneous tracheostomy (or cricothyroidotomy):** Percutaneous tracheostomy was developed in 1985 and was based on a modification of the Seldinger principles. The advantages of this technique over surgical tracheostomy are simplicity, a smaller skin incision, lower incidences of wound infection and peristomal bleeding, and decreased mortality after patient transfer<sup>11-15</sup>. However, perioperative complications of percutaneous tracheostomy include paratracheal insertion, tracheal laceration, pneumothorax, loss of airway, and hemorrhage<sup>16</sup>. An X-ray-guided technique could assist in confirming the location of the tube and guidewire during the procedure and paratracheal insertion, thereby reducing the risk of tracheoesophageal fistula. Additionally, although bronchoscopy might be helpful for percutaneous tracheostomy<sup>17</sup>, it requires more space and an operator. Hence, the compact and lightweight X-ray unit could replace the bronchoscope. Moreover, our technique can be used for percutaneous tracheostomy and cricothyroidotomy.

**REBOA:** REBOA is an alternative to aortic clamping by thoracotomy for non-compressible torso hemorrhage and is a tool for temporary hemostasis. Fluoroscopic or radiographic confirmation of the position of the REBOA catheter when inflated is recommended. Actual and theoretical risks include unintended placement in the aortic arch, renal artery, zone II, or contralateral iliac artery<sup>18</sup>. A number of complications, such as aortic injury, ischemic injury, arterial dissection, thrombosis, and embolic events, have been reported<sup>19,20</sup>. Appropriate placement of the tip of the REBOA catheter can be confirmed with the compact, lightweight X-ray unit.

**SB tube:** Inflation of the gastric balloon outside the stomach is associated with numerous major complications, including airway obstruction, tracheal injury, esophageal rupture, and jejunal rupture<sup>21-26</sup>. Although the position can be confirmed by auscultation, the manufacturer recommends the use of fluoroscopy. However, rupture of esophageal varices often results in shock due to massive bleeding, and the patient may have difficulty moving. Hence, the compact, lightweight X-ray unit may also be useful for this procedure.

### Reduction in Treatment Time

The present device has several potential advantages. Physicians can obtain X-ray images without assistance as soon as the patient presents to the hospital. At least, it reduces the time spent on contacting and traveling with technicians. As an example, it took 8.0 min for the ordering (5.5 min) and traveling (2.5 min), for a total 22.7 min from the time the examination was placed to time the X-

ray films were uploaded to the picture archiving and communication system<sup>27</sup>. In addition, although fluoroscopy-guided procedures can prevent complications, they require transferring the patient to the fluoroscopy room<sup>7</sup>. A study of peripherally inserted central catheters found that the average transfer time was approximately 26 min, which was similar to the procedure time<sup>8</sup>. Our technique could be particularly useful for critically ill patients who cannot be safely transferred to the fluoroscopy room.

#### Radiation Dose

A single chest X-ray results in an exposure to 0.02 mGy of radiation<sup>5</sup>, whereas fluoroscopy results in 20 mGy/min of radiation<sup>28</sup>. A total of 0.63 min is required to insert a CVC by radiologists using fluoroscopy<sup>29</sup>, and patients are exposed to an average of 12 mGy of radiation during fluoroscopy-assisted CVC insertion. Therefore, radiation exposure during CVC insertion would be lower with the compact X-ray technique than with fluoroscopy<sup>29</sup>.

#### Limitations

This study has several limitations. First, no control group was included in this study. Although it is plausible that increased visibility improves safety, it could not be determined if the device contributed to safety. To our knowledge, this method is straightforward and safe, but difficulties may arise in the future. We were unable to adequately investigate risk and troubleshooting. Second, the study did not evaluate image quality. However, no X-ray images were retaken because of poor quality. In addition, emergency physicians are unfamiliar with adjusting the position of the flat panel detector. Hence, images were sometimes not obtained. Use of a larger panel might resolve this issue.

#### Conclusions

We developed a visualization technique that uses a compact, lightweight X-ray unit for invasive procedures in the ER. This technique appears to reduce the risk of complications during such procedures.

**Acknowledgements:** This study was conducted in collaboration with Fujifilm Corporation (Tokyo, Japan), which provided the medical equipment and technical support.

**Conflict of Interest:** None declared.

#### References

1. Comerlato PH, Rebelatto TF, Santiago de Almeida FA, et

al. Complications of central venous catheter insertion in a teaching hospital. *Rev Assoc Med Bras* (1992) [Internet]. 2017 Jul;63(7):613–20. Available from: <https://www.ncbi.nlm.nih.gov/pubmed/28977087>

2. Silberzweig JE, Sacks D, Khorsandi AS, Bakal CW, Society of Interventional Radiology Technology Assessment C. Reporting standards for central venous access. *J Vasc Interv Radiol* [Internet]. 2003 Sep;14(9 Pt 2):S443–52. Available from: <https://www.ncbi.nlm.nih.gov/pubmed/14514860>
3. Shah R, Qayed E. Bedside endoscopic retrograde cholangiopancreatography using portable X-ray in acute severe cholangitis. *Case Rep Gastrointest Med* [Internet]. 2018; 2018:8763671. Available from: <https://www.ncbi.nlm.nih.gov/pubmed/29682365>
4. Omori K, Muramatsu KI, Nagasawa H, et al. The utility of a portable X-ray system. *Air Med J* [Internet]. 2019 May - Jun;38(3):212–4. Available from: <https://www.ncbi.nlm.nih.gov/pubmed/31122590>
5. Omori K, Yanagawa Y, Muramatsu KI, et al. Experience using a portable X-ray system at the scene transported by a physician-staffed helicopter. *Acute Med Surg* [Internet]. 2019 Oct;6(4):396–9. Available from: <https://www.ncbi.nlm.nih.gov/pubmed/31592083>
6. Yanagawa Y, Ohsaka H, Oode Y, Omori K. A case of fatal trauma evaluated using a portable X-ray system at the scene. *J Rural Med* [Internet]. 2019 Nov;14(2):249–52. Available from: <https://www.ncbi.nlm.nih.gov/pubmed/31788152>
7. Glauser F, Breault S, Rigamonti F, Sotiriadis C, Jouannic AM, Qanadli SD. Tip malposition of peripherally inserted central catheters: a prospective randomized controlled trial to compare bedside insertion to fluoroscopically guided placement. *Eur Radiol* [Internet]. 2017 Jul;27(7):2843–9. Available from: <https://www.ncbi.nlm.nih.gov/pubmed/27957644>
8. Cho SB, Baek HJ, Park SE, et al. Clinical feasibility and effectiveness of bedside peripherally inserted central catheter using portable digital radiography for patients in an intensive care unit: A single-center experience. *Medicine* [Internet]. 2019 Jun;98(26):e16197. Available from: <https://www.ncbi.nlm.nih.gov/pubmed/31261562>
9. Collop NA, Kim S, Sahn SA. Analysis of tube thoracostomy performed by pulmonologists at a teaching hospital. *Chest* [Internet]. 1997 Sep;112(3):709–13. Available from: <https://www.ncbi.nlm.nih.gov/pubmed/9315804>
10. McElnay PJ, Lim E. Modern techniques to insert chest drains. *Thorac Surg Clin* [Internet]. 2017 Feb;27(1):29–34. Available from: <https://www.ncbi.nlm.nih.gov/pubmed/27865324>
11. Friedman Y, Mayer AD. Bedside percutaneous tracheostomy in critically ill patients. *Chest* [Internet]. 1993 Aug;104(2):532–5. Available from: <https://www.ncbi.nlm.nih.gov/pubmed/8339644>
12. Toye FJ, Weinstein JD. Clinical experience with percutaneous tracheostomy and cricothyroidotomy in 100 patients. *J Trauma* [Internet]. 1986 Nov;26(11):1034–40. Available from: <https://www.ncbi.nlm.nih.gov/pubmed/3783779>
13. Hazard P, Jones C, Benitone J. Comparative clinical trial of standard operative tracheostomy with percutaneous tracheostomy. *Crit Care Med* [Internet]. 1991 Aug;19(8):1018–24. Available from: <https://www.ncbi.nlm.nih.gov/pubmed/1860325>
14. Griggs WM, Myburgh JA, Worthley LI. A prospective comparison of a percutaneous tracheostomy technique with standard surgical tracheostomy. *Intensive Care Med*



- [Internet]. 1991;17(5):261-3. Available from: <https://www.ncbi.nlm.nih.gov/pubmed/1939869>
15. Ciaglia P, Graniero KD. Percutaneous dilatational tracheostomy. Results and long-term follow-up. *Chest* [Internet]. 1992 Feb;101(2):464-7. Available from: <https://www.ncbi.nlm.nih.gov/pubmed/1735273>
  16. Klotz R, Probst P, Deininger M, et al. Percutaneous versus surgical strategy for tracheostomy: a systematic review and meta-analysis of perioperative and postoperative complications. *Langenbecks Arch Surg* [Internet]. 2018 Mar;403(2):137-9. Available from: <https://www.ncbi.nlm.nih.gov/pubmed/29282535>
  17. Easterday TS, Moore JW, Redden MH, et al. Percutaneous tracheostomy under bronchoscopic visualization does not affect short-term or long-term complications. *Am Surg* [Internet]. 2017 Jul 1;83(7):696-8. Available from: <https://www.ncbi.nlm.nih.gov/pubmed/28738937>
  18. Scott DJ, Eliason JL, Villamaria C, et al. A novel fluoroscopy-free, resuscitative endovascular aortic balloon occlusion system in a model of hemorrhagic shock. *J Trauma Acute Care Surg* [Internet]. 2013 Jul;75(1):122-8. Available from: <https://www.ncbi.nlm.nih.gov/pubmed/23940855>
  19. Long B, Hafen L, Koefman A, Gottlieb M. Resuscitative endovascular balloon occlusion of the aorta: A review for emergency clinicians. *J Emerg Med* [Internet]. 2019 Jun;56(6):687-97. Available from: <https://www.ncbi.nlm.nih.gov/pubmed/31010604>
  20. Ribeiro Junior MAF, Feng CYD, Nguyen ATM, et al. The complications associated with Resuscitative Endovascular Balloon Occlusion of the Aorta (REBOA). *World J Emerg Surg* [Internet]. 2018;13:20. Available from: <https://www.ncbi.nlm.nih.gov/pubmed/29774048>
  21. Goff JS, Thompson JS, Pratt CF, Tomasso GI, Penn I. Jejunal rupture caused by a Sengstaken-Blakemore tube. *Gastroenterology* [Internet]. 1982 Mar;82(3):573-5. Available from: <https://www.ncbi.nlm.nih.gov/pubmed/6976285>
  22. Wang HS, Lin J, Wang F, Miao L. Tracheal injury characterized by subcutaneous emphysema and dyspnea after improper placement of a Sengstaken-Blakemore tube: A case report. *Medicine* [Internet]. 2018 Jul;97(30):e11289. Available from: <https://www.ncbi.nlm.nih.gov/pubmed/30045253>
  23. Hamm DD, Papp JP. Rupture of esophagus during use of Sengstaken-Blakemore tube. *Postgrad Med* [Internet]. 1974 Aug;56(2):199-200. Available from: <https://www.ncbi.nlm.nih.gov/pubmed/4854179>
  24. Chien JY, Yu CJ. Images in clinical medicine. Malposition of a Sengstaken-Blakemore tube. *N Engl J Med* [Internet]. 2005 Feb 24;352(8):e7. Available from: <https://www.ncbi.nlm.nih.gov/pubmed/15728803>
  25. Kelly DJ, Walsh F, Ahmed S, Synnott A. Airway obstruction due to a Sengstaken-Blakemore tube. *Anesth Analg* [Internet]. 1997 Jul;85(1):219-21. Available from: <https://www.ncbi.nlm.nih.gov/pubmed/9212152>
  26. Nielsen TS, Charles AV. Lethal esophageal rupture following treatment with Sengstaken-Blakemore tube in management of variceal bleeding: a 10-year autopsy study. *Forensic Sci Int* [Internet]. 2012 Oct 10;222(1-3):e19-22. Available from: <https://www.ncbi.nlm.nih.gov/pubmed/22721936>
  27. Abujudeh H, Vuong B, Baker SR. Quality and operations of portable X-ray examination procedures in the emergency room: queuing theory at work. *Emerg Radiol* [Internet]. 2005 Jul;11(5):262-6. Available from: <https://www.ncbi.nlm.nih.gov/pubmed/16133619>
  28. Lee RK, Chu WC, Graham CA, Rainer TH, Ahuja AT. Knowledge of radiation exposure in common radiological investigations: a comparison between radiologists and non-radiologists. *Emerg Med J* [Internet]. 2012 Apr;29(4):306-8. Available from: <https://www.ncbi.nlm.nih.gov/pubmed/21873321>
  29. Xu BJ, Duszak R Jr, McGinnis RS, Stanfill JG, O'Rear J, An AQ. Increased fluoroscopy time for central venous catheter placement by radiology residents versus staff radiologists. *J Am Coll Radiol* [Internet]. 2013 Jul;10(7):518-22. Available from: <https://www.ncbi.nlm.nih.gov/pubmed/23827004>

(Received, March 7, 2021)

(Accepted, August 4, 2021)

(J-STAGE Advance Publication, September 14, 2021)

Journal of Nippon Medical School has adopted the Creative Commons Attribution-NonCommercial-NoDerivatives 4.0 International License (<https://creativecommons.org/licenses/by-nc-nd/4.0/>) for this article. The Medical Association of Nippon Medical School remains the copyright holder of all articles. Anyone may download, reuse, copy, reprint, or distribute articles for non-profit purposes under this license, on condition that the authors of the articles are properly credited.