

Secondary Cutaneous Ossification in Keloids of the Lower Abdomen: A Report of Two Cases

Mamiko Tosa¹, Shin-ichi Ansai² and Rei Ogawa¹

¹Department of Plastic, Reconstructive and Aesthetic Surgery, Nippon Medical School Hospital, Tokyo, Japan

²Division of Dermatology and Dermatopathology, Nippon Medical School Musashikosugi Hospital, Kanagawa, Japan

Cutaneous ossification is a rare benign dermatological condition in which bone forms in the dermis or subcutaneous tissue. It is classified as primary when it emerges without a pre-existing condition and secondary when it is associated with an underlying condition such as trauma, scars, inflammation, or neoplastic disease. The secondary form accounts for most cases of cutaneous ossification. The pathogenesis of cutaneous ossification is not clear. Keloids are benign fibroproliferative skin disorders characterized by chronic inflammation. Their pathogenesis is also not fully understood. We report two cases of postoperative secondary ossification in lower abdominal keloids and review the literature on secondary ossification of the skin. We speculate that severe chronic inflammation in keloids drives osteoblastic transformation of mesenchymal stem cells, endothelial cells, or fibroblasts in the keloids.

(J Nippon Med Sch 2022; 89: 546–549)

Key words: cutaneous ossification, keloid, secondary ossification, inflammation

Introduction/Background

Cutaneous ossification (also known as osteoma cutis) and cutaneous calcification (calcinosis cutis) are rare conditions that involve deposition of calcium salts in skin and subcutaneous tissues. However, unlike cutaneous calcification, cutaneous ossification is associated with dystrophic deposits of bone¹. Although this benign condition may present as a primary skin lesion, it is usually secondary to skin conditions such as trauma, scars, and inflammation and malignant and benign neoplastic lesions¹. The cause of cutaneous ossification is unclear.

Keloids are a benign recalcitrant fibroproliferative skin disorder that arises from damage to the dermis. The recurrence rate after surgical treatment is 40-70% but decreases to less than 10% when surgery is accompanied by adjuvant treatments such as postoperative radiotherapy²⁻⁴. There are no specific drugs for this condition because of the lack of suitable animal models. To our knowledge, there are no detailed studies of secondary ossification associated with keloids.

Here we describe two cases of cutaneous ossification

associated with postoperative lower abdominal keloids and review the literature on secondary ossification of the skin.

Case 1

Four years previously, a 42-year-old woman visited our outpatient clinic for assessment of scar pain after gynecological surgery for uterine fibroids. Clinical examination revealed a hard, red, elastic, and raised 3 × 2.5-cm mass in the lower part of the postoperative scar (**Fig. 1a**). The patient had no history of skin cancer in this area and no personal or family history of bone or metabolic disorders. Postoperative keloid was diagnosed and she underwent complete surgical resection followed by electron beam therapy. Histopathological analysis revealed a nodular dermal lesion consisting of excessive “keloidal collagen bundles,” ie, thick, haphazardly arrayed, glassy, and eosinophilic collagen bundles that formed nodular, whorled masses. The number of fibroblasts in the lesion was elevated (**Fig. 2a**). Notably, the lower part of the lesion contained small nodules of bone tissue (**Fig. 2b**).

Correspondence to Mamiko Tosa, Department of Plastic, Reconstructive and Aesthetic Surgery, Nippon Medical School Hospital, 1-1-5 Sendagi, Bunkyo-ku, Tokyo 113-8603, Japan

E-mail: tosa-m@nms.ac.jp

https://doi.org/10.1272/jnms.JNMS.2022_89-502

Journal Website (<https://www.nms.ac.jp/sh/jnms/>)

These clinical and pathological findings indicated a diagnosis of postoperative keloid associated with secondary cutaneous ossification. No recurrence has been observed at 2 years after surgery (Fig. 1b), and the patient continues to be followed up.

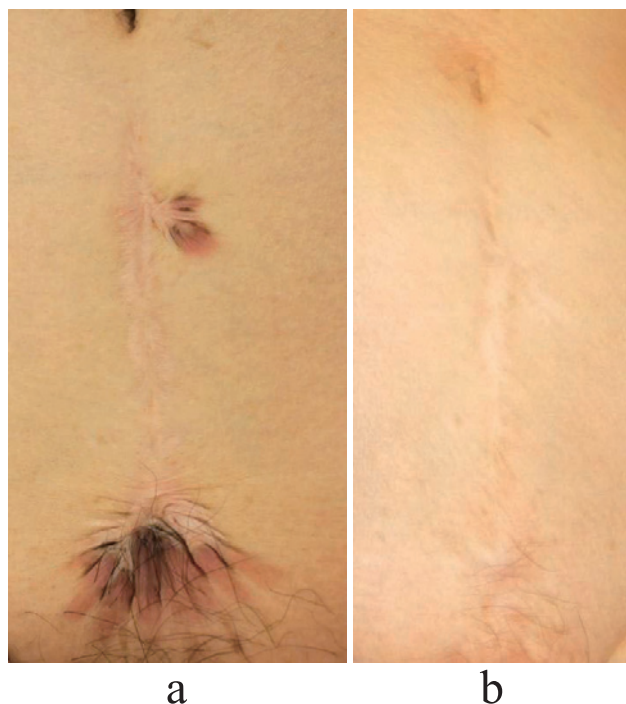

Fig. 1 Preoperative (a) and postoperative (b) images showing the clinical findings for Case 1. The patient had a keloid in the lower part of the postoperative scar. No recurrence was observed at 2 years after surgical resection and adjuvant radiotherapy.

Case 2

A 32-year-old woman visited our outpatient clinic for assessment of scar pain after dermatological surgery for an epidermal cyst 6 years previously. Clinical examination revealed a hard, red, elastic, and raised 3 × 11-cm mass in the postoperative scar (Fig. 3a). The patient had no history of skin cancer in this area and no personal or family history of bone or metabolic disorders. Postoperative keloid was diagnosed and she underwent complete surgical resection followed by electron beam therapy. Histopathological analysis revealed findings similar to those of Case 1 (Fig. 4a, b), namely, keloidal collagen, elevated fibroblast numbers, and small ossified nodules in the lower part of the lesion (Fig. 4c). Postoperative keloid associated with secondary cutaneous ossification was diagnosed. No recurrence has been observed at 3 years after surgery (Fig. 3b).

Discussion

Cutaneous ossification involves deposition of bone in skin and is caused by production of osteoblast tissue¹. To date, three large case series on secondary cutaneous osteoma have been published. In 1963, Roth et al. summarized the causes of secondary cutaneous ossification in 120 cases they experienced and 305 cases they identified in the literature: they detected 153 skin conditions that developed before secondary cutaneous ossification, including acne vulgaris, acne, scleroderma, dermatomyositis, basal cell carcinoma, scarring, venous stasis, calcified epithelioma, and folliculitis⁵. In 1997, Burgdorf and Nase-

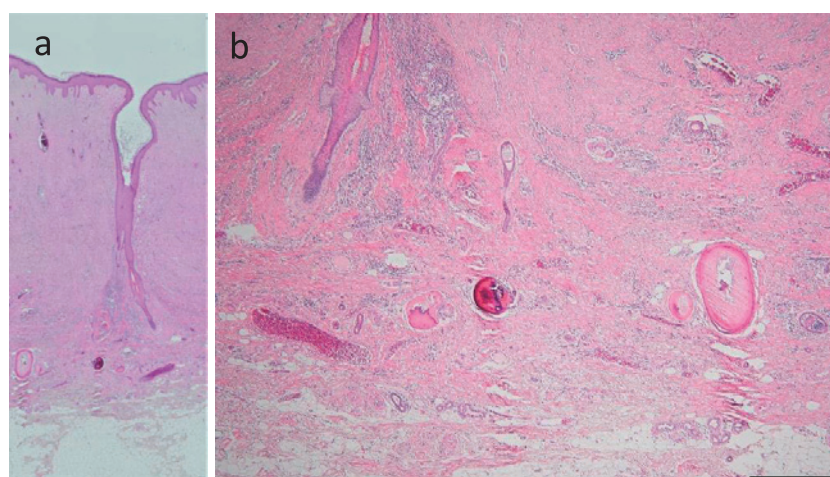


Fig. 2 Histological findings for Case 1. (a) Low-power image showing a nodular lesion in the dermis. The lesion consisted of large numbers of collagen bundles that formed nodular and whorled masses and were associated with increased fibroblast numbers. The lower part of the lesion contained small nodules of bony tissue. (b) Higher-power image showing bony tissues in the lower part of the keloid.

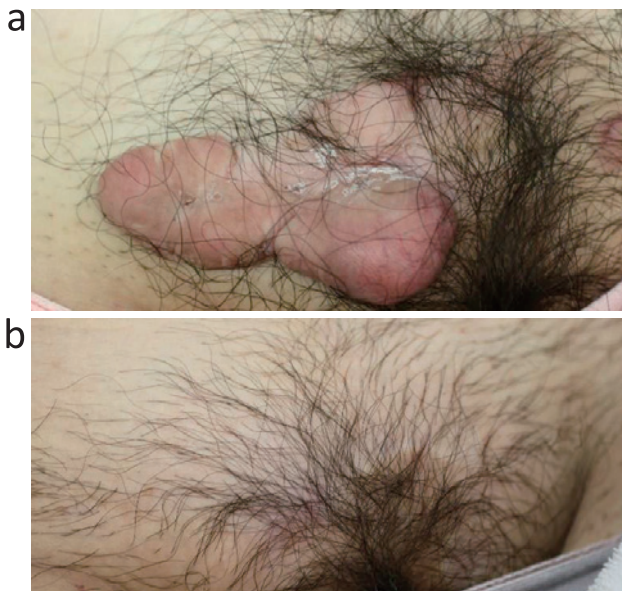


Fig. 3 Preoperative (a) and postoperative (b) images showing the clinical findings for Case 2. The patient had a keloid in the pubic area. No recurrence was observed at 3 years after surgery.

mann⁶ described 10 primary and 25 secondary cases of cutaneous ossification they identified among 20,000 skin biopsy materials. The secondary causes were epithelioma, basal cell carcinoma, melanocytic nevus, appendageal and fibrous proliferation, inflammation, and trauma. In 2002, Conlin et al. reported 74 cases of primary and secondary cutaneous osteomas and found that benign neoplasms, especially melanocytic nevus, were the most common cause of secondary cases⁷. In 2014, Ishida et al. summarized these reports and showed that secondary cutaneous ossification accounted for 83% of all cutaneous ossification cases and that the most common causes of secondary cases were pilomatricoma (21%), melanocytic nevus (19%), and inflammation or trauma (10%) (Table 1)⁸. To our knowledge, cutaneous ossification associated with keloidal scarring has not been reported.

Although the pathogenesis of secondary cutaneous ossification has not been elucidated, Burgdorf and Nasemann⁶ suggested that cutaneous ossification is generally caused by either transformation of primitive mesenchymal cells into osteoblasts or metaplastic transformation of other, as yet undetermined, dermal cells as a result of stimulation by particular cellular environments. With regard to the latter theory, Schumachers and Worret suggested that the undetermined dermal cells may be fibroblasts: they hypothesized that cutaneous ossification may involve an intracellular signaling pathway that induces skin fibroblasts to proliferate abnormally and later differ-

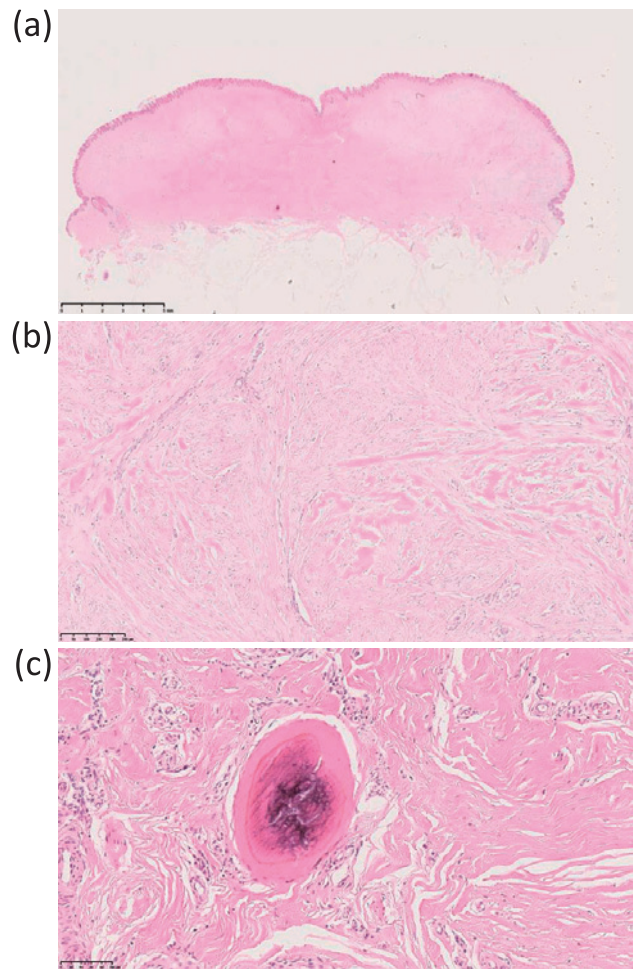


Fig. 4 Histological findings for Case 2. (a) Low-power image showing a nodular lesion in the dermis. The lesion consisted of nodule-forming, whorled collagen bundles and a high number of fibroblasts. The lower part of the lesion had small nodules consisting of bony tissue. (b) and (c) Higher-power images showing the thick, glassy, eosinophilic collagen bundles (b) and bony tissue in the lower part of the keloid (c).

Table 1 Causes of cutaneous osteoma (modified with permission from Ishida et al., 2014 under a Creative Commons Attribution Noncommercial License)

Primary	47 (17.3%)
Secondary	224 (82.7%)
Common cause of secondary	
Pilomatricoma	56 (20.7%)
Melanocytic nevus	51 (18.8%)
Inflammation or trauma	26 (9.6%)
Basal cell carcinoma	19 (7%)

entiate into bone tissue⁹.

There is limited evidence that one or both of these possibilities could mediate keloid ossification. Mesenchymal stem cells in keloid lesions give rise to abnormal fibroblasts and myofibroblasts¹⁰. Because mesenchymal stem cells can readily differentiate into osteoblasts¹⁰, mesenchymal stem cells in keloids may give rise to osteoblasts. This is further supported by the association between *GNAS* mutations and cutaneous ossification. *GNAS* regulates adipose-derived mesenchymal progenitor cell commitment, and inactivating mutations in this gene induce osteoblast differentiation¹¹.

With regard to the possibility that undetermined dermal cells differentiate into osteoblasts, a previous study reported that tissue injury—from trauma or infection, for example—that produces local hypoxia can induce endothelial cells to express BMPs, which causes them to convert into osteoblasts¹². Because keloids develop after trauma, are associated with chronic inflammation, and have dysregulated endothelial cells², this mechanism may drive keloid ossification. This is supported by findings for the rare condition called osteonevus of Nanta, which is characterized by ossification of the intradermal nevus¹³. Chronic inflammation is thought to be a trigger of ossification in this condition since cell infiltration is present near the osteoma and around hair follicles¹⁴. Interestingly, our cases of ossified keloid occurred in the pubic area, and histological findings indicated peri-follicular inflammation and calcification. This supports the hypothesis that chronic inflammation in keloids leads to local calcification and ossification.

Another possibility is that fibroblasts, which are abundant, abnormal, and proliferate vigorously in keloids, differentiate into osteoblasts, possibly as a result of chronic inflammation in keloids⁹. This hypothesis is supported by the observation that cutaneous ossification lesions not only contain osteoblasts and bone¹⁵, they are surrounded by type I collagen and osteonectin-positive fibroblasts¹⁶.

There are two types of normal bone ossification: endochondral ossification, where hyaline cartilage is replaced by bony tissue, and membranous bone formation, where bone forms directly without cartilage analogs⁸. Ossification in keloids is likely due to membranous bone formation, since the lesions in both our patients had no cartilage tissue.

In conclusion, chronic inflammation, which is severe in keloids, may drive local mesenchymal stem cells, endothelial cells, or fibroblasts to differentiate into osteoblasts that then generate bony nodules in keloids. Future stud-

ies should examine the mechanisms that induce bone formation in keloids.

Conflict of Interest: None declared.

References

1. Ragsdale BD. Tumors of fatty, muscular and osseous tissue. In: Elder D, Elenitsas R, Jaworsky C, et al, editors. *Lever's histopathology of the skin*. 8th ed. Philadelphia: Lippincott-Raven Publishers; 1997. p. 965–7.
2. Ogawa R, Dohi T, Tosa M, et al. The latest strategy for keloid and hypertrophic scar prevention and treatment: The Nippon Medical School (NMS) Protocol. *J Nippon Med Sch*. 2021;88:2–9.
3. Ogawa R. Keloid and hypertrophic scars are the result of chronic inflammation in the reticular dermis. *Int J Mol Sci*. 2017 Mar 10;18(3):606–16.
4. Lutgendorf MA, Adriano EM, Taylor BJ. Prevention and management of keloid scars. *Obstet Gynecol*. 2011 Aug; 118(2 Pt 1):351–6.
5. Roth SI, Stowell RE, Helwig EB. Cutaneous ossification. Report of 120 cases and review of the literature. *Arch Dermatol*. 1963;76:44–54.
6. Burgdorf W, Nasemann T. Cutaneous osteomas: a clinical and histopathologic review. *Arch Derm Res*. 1997;260:121–35.
7. Conlin PA, Jimenez-Quintero LP, Rapini RP. Osteomas of the skin revisited: a clinicopathologic review of 74 cases. *Am J Dermatopathol*. 2002;24:479–83.
8. Ishida M, Iwai M, Kagotani A, et al. Epidermal cyst of the skin with ossification: report of two cases. *Int J Clin Exp Pathol*. 2014;7(4):1823–5.
9. Schuhmachers G, Worret W. Osteoma cutis. Pathogenesis and therapeutic possibilities. *Hautarzt*. 1992;43:422–5.
10. Lim KH, Itinteang T, Davis PF, et al. Stem cells in keloid lesions: A review. *Plast Reconstr Surg Glob Open*. 2019;7(5):e2228.
11. Bastepe M. *GNAS* Mutations and heterotopic ossification. *Bone*. 2018;109:80–5.
12. Kim ES, Kim KJ, Chang SE, et al. Metaplastic ossification in a cutaneous pyogenic granuloma: a case report. *J Dermatol*. 2004;31:326–9.
13. Kamat G, Myageri A, Rao R. Osteonevus of Nanta presenting as nodule over left eyebrow. *Case Rep Dermatol Med*. 2012;26:1–2.
14. López-Robles J, Pérez-Plaza A, Requena L, et al. Osteoma cutis arising in common blue nevus (Blue Osteonevus): A clinicopathologic, immunohistochemical, and dermoscopic study. *Am J Dermatopathol*. 2019;41(2):e19–20.
15. Cottoni F, Dell'Orbo C, Quacci D, et al. Primary osteoma cutis; clinical, morphological and ultrastructural study. *Am J Dermatopathol*. 1993;15:77–81.
16. Oikarinen A, Tuomi ML, Kallionen M, et al. A study of bone formation in osteoma cutis employing biochemical, histochemical and in situ hybridization techniques. *Acta Derm Venereol*. 1992;72:172–4.

(Received, March 17, 2021)

(Accepted, April 30, 2021)

(J-STAGE Advance Publication, April 11, 2022)

Journal of Nippon Medical School has adopted the Creative Commons Attribution-NonCommercial-NoDerivatives 4.0 International License (<https://creativecommons.org/licenses/by-nc-nd/4.0/>) for this article. The Medical Association of Nippon Medical School remains the copyright holder of all articles. Anyone may download, reuse, copy, reprint, or distribute articles for non-profit purposes under this license, on condition that the authors of the articles are properly credited.