

Meralgia Paresthetica Caused by Surgery in the Park-Bench Position

Rinko Kokubo¹, Kyongsong Kim¹, Katsuya Umeoka¹,
Toyohiko Isu² and Akio Morita³

¹Department of Neurosurgery, Nippon Medical School Chiba Hokusoh Hospital, Chiba, Japan

²Department of Neurosurgery, Kushiro Rosai Hospital, Hokkaido, Japan

³Department of Neurosurgery, Nippon Medical School, Tokyo, Japan

Objective: Meralgia paresthetica (MP) is an entrapment neuropathy of the lateral femoral cutaneous nerve (LFCN). We report a rare case of MP after microvascular decompression (MVD) surgery in the park-bench position in a patient with hemifacial spasm.

Case: The patient was a nondiabetic 46-year-old woman (height: 155 cm, weight: 42 kg) who consumed alcohol infrequently. After a first MVD for right hemifacial spasm, the symptom recurred and she underwent a second MVD procedure in the park-bench position, after which hemifacial spasm resolved. However, she reported right anterolateral thigh pain and dysesthesia without motor weakness. The pain was limited to the LFCN area, and a pelvic compression test elicited a positive Tinel-like sign. Our preliminary diagnosis was MP. Because conservative therapy was ineffective, she underwent LFCN block 9 months after the second MVD procedure. Her pain improved dramatically and we made a definitive diagnosis of MP. There has been no recurrence after 30 months of observation, although she reported persistent mild dysesthesia in the LFCN area.

Conclusion: MP is a rare complication after MVD surgery in the park-bench position. LFCN block can resolve symptoms and hasten diagnosis. (*J Nippon Med Sch* 2022; 89: 355–357)

Key words: lateral femoral cutaneous nerve, park-bench position

Introduction

Meralgia paresthetica (MP) is an entrapment neuropathy of the lateral femoral cutaneous nerve (LFCN) that is idiopathic, iatrogenic, or caused by external compression. MP due to direct injury in the surgical field during iliac bone graft harvest¹, anterior-approach hip arthroplasty², and laparoscopic appendectomy³ has been reported, as has MP related to prone surgical position^{4–6}. Other studies^{7,8} have reported MP in patients undergoing procedures in the beach-chair position and in those undergoing shoulder surgery in the lateral decubitus position.

Patients are placed in the park-bench position when the lateral suboccipital approach is used for microvascular decompression (MVD), tumor removal, and cerebral vascular surgery. Complications elicited by treatments the park-bench position have been reported, e.g., complications in the face and neck area (massive macroglossia⁹

and brachial plexopathy with massive neck swelling¹⁰) and around the shoulders and trunk (long thoracic nerve injury¹¹, position-related pressure ulcers¹², and axillary artery compression¹³). We describe a rare MP complication in a patient with hemifacial spasm who had undergone MVD in the park-bench position.

Case Report

The patient was a nondiabetic 46-year-old woman (height: 155 cm, weight: 42 kg) who consumed alcohol infrequently. She consented to the submission of this case report for publication. She underwent a first MVD for right hemifacial spasm at age 35 years. Her symptom soon recurred and she subsequently received Botox treatment, which also failed to control her hemifacial spasm. Therefore, she underwent a second MVD procedure in our department and was placed in the park-bench posi-

Correspondence to Rinko Kokubo, MD, PhD, Department of Neurosurgery, Nippon Medical School Chiba Hokusoh Hospital, 1715 Kamagari, Inzai, Chiba 270-1694, Japan

E-mail: rin-ko927@nms.ac.jp

https://doi.org/10.1272/jnms.JNMS.2022_89-112

Journal Website (<https://www.nms.ac.jp/sh/jnms/>)

tion with her left side up. The duration of surgery was 4 hours and 53 minutes.

Her hemifacial spasm completely resolved after surgery. However, she experienced right anterolateral thigh pain (7 of 10 on a numerical rating scale [NRS]) and dysesthesia without motor weakness, which were not present preoperatively. Lumbar magnetic resonance imaging did not reveal what elicited the symptoms limited to the LFCN area. We noted a Tinel-like sign where the right LFCN penetrated the inguinal ligament. The result of a pelvic compression test was positive. Thus, the preliminary diagnosis was MP.

We advised removal of items exerting external compression and prescribed pregabalin, vitamin B12, and neurotrophin. She underwent LFCN block 9 months after the second MVD procedure. LFCN block was administered at the bedside, without fluoroscopic guidance, with the patient in supine position. We delivered the blocking agent (5 mL of 1% lidocaine) at the entrapment point, the area positive for the Tinel-like sign, i.e., the inguinal ligament located about 2 cm medial and 2 cm caudal to the anterior superior iliac spine. After LFCN blockage, the NRS value decreased from 6 to 2, and our final diagnosis was MP. Her dysesthesia in the LFCN area worsened slightly after nerve blockage but was controlled by re-administration of neurotrophin (NRS: 3). There has been no recurrence of pain during the subsequent 30 months of observation.

Discussion

The LFCN, a pure sensory nerve running from the first to the third lumbar nerve roots, penetrates between the inguinal ligament and sartorius muscle near the superior anterior iliac spine. Entrapment in this area is not rare¹⁴⁻¹⁶ and can be idiopathic, iatrogenic, or due to external compression. Although MP due to patient positioning during surgery has been reported⁴⁻⁸, the role of park-bench position has not been adequately investigated.

LFCN compression around the superior anterior iliac spine, the site of LFCN penetration, has been reported^{7,17}, and anatomical LFCN variations resulting in MP have been documented¹⁸⁻²¹. Gartsman⁸ found that, during repair of lesions of the rotator cuff in the lateral position, compression elicited entrapment of the LFCN contralateral to the surgical site. The mechanism(s) involved in lateral position and park-bench position may differ. Unlike the lateral position, park-bench position requires rotation of the body, and the pubic fixture device may exert pressure on the surgical side.

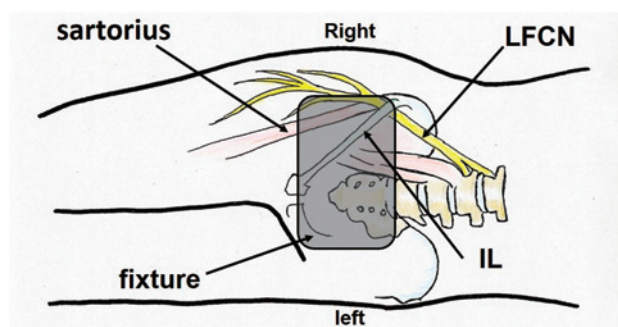


Fig. 1A Relationship between the lateral femoral cutaneous nerve (LFCN) and the fixture device, with the patient in park-bench position. Note fixture-induced meralgia paresthetica upon LFCN compression where the nerve penetrates the inguinal ligament (IL).

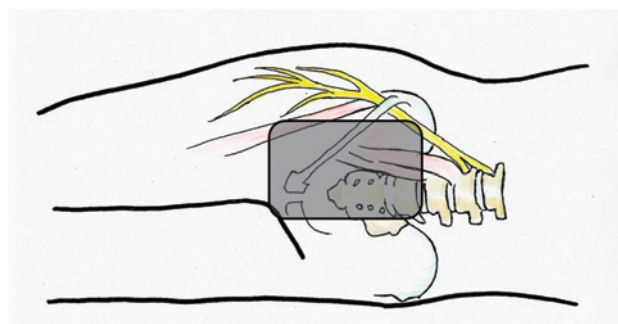


Fig. 1B On the basis of the present experience, in the future we will place the fixture device as shown here to avoid compressing the LFCN.

In park-bench position, the rotation force applied is stronger when the patient is in prone position than in lateral position. Although placing the fixture device in the pubic area may prevent rotation of the core-our patient was short and slender-the fixture device reached the LFCN and we thus cannot exclude the possibility of compression on the inside of the superior anterior iliac spine. This may explain why we encountered this rare MP complication (Fig. 1A). On the basis of this experience, in the future we will place the fixture device as shown in Figure 1B.

MP is diagnosed on the basis of clinical symptoms and the effect of nerve blocks¹⁸⁻²¹. Symptoms are limited to the area affected by the LFCN (the anterolateral thigh); motor weakness is absent. The Tinel-like sign and pelvic compression sign are diagnostically useful²². Treatment options are removal of external items exerting compression, medication, LFCN block, and LFCN neurolysis²³⁻²⁵. LFCN blocks were effective in 96-100% of patients; 20% reported improvement after a second block^{26,27}. Our pa-

tient's symptoms were consistent with MP and positive for the Tinel and compression tests; however, she initially refused LFCN blocking that would have led to a definitive diagnosis. Because conservative treatment was ineffective, she ultimately consented to LFCN blockage, which hastens diagnosis and is an effective, less invasive treatment for pain due to MP.

Conclusion

MP is a rare complication after MVD surgery in the park-bench position. LFCN block yields a definitive early diagnosis.

Conflict of Interest: None.

References

- Kurz LT, Garfin SR, Booth RE. Harvesting autogenous iliac bone grafts: A review of complications and techniques. *Spine*. 1989 Dec 14;12:1324-31.
- Goulding K, Beaulé PE, Kim PR, Fazekas A. Incidence of lateral femoral cutaneous nerve neuropraxia after anterior approach hip arthroplasty. *Clin Orthop Relat Res*. 2010 Sep;468(9):2397-404.
- Polidori L, Magarelli M, Tramutoli R. Meralgia paresthetica as a complication of laparoscopic appendectomy. *Surg Endosc*. 2003 May;17(5):832.
- Grossman MG, Ducey SA, Nadler SS, Levy AS. Meralgia paresthetica: Diagnosis and treatment. *J Am Acad Orthop Surg*. 2001 Sep-Oct;9(5):336-44.
- Harney D, Patijn J. Meralgia paresthetica: Diagnosis and management strategies. *Pain Med*. 2007 Nov-Dec;8(8):669-77.
- Streiffner RH. Meralgia paresthetica. *Am Fam Physician*. 1986 Mar;33(3):141-4.
- Levy BJ, Tauberg BM, Holtzman AJ, Gruson KI. Reducing lateral femoral cutaneous nerve palsy in obese patients in the beach chair position: Effect of a standardized positioning and padding protocol. *J Am Acad Orthop Surg*. 2019 Jun 15;27(12):437-43.
- Gartsman GM. Arthroscopic acromioplasty for lesions of the rotator cuff. *J Bone Joint Surg Am*. 1990 Feb;72(2):169-80.
- Toyama S, Hoya K, Matsuoka K, Numai T, Shimoyama M. Massive macroglossia developing fast and immediately after endotracheal extubation. *Acta Anaesthesiol Scand*. 2012 Feb;56(2):256-9.
- Shimizu S, Sato K, Mabuchi I, et al. Brachial plexopathy due to massive swelling of the neck associated with craniotomy in the park bench position. *Surg Neurol*. 2009 Apr;71(4):504-8.
- Paluzzi A, Woon K, Bodkin P, Robertson PI. 'Scapula alata' as a consequence of park bench position for a retromastoid craniectomy. *Br J Neurosurg*. 2007 Oct;21(5):522-4.
- Yoshimura M, Iizaka S, Kohno M, et al. Risk factors associated with intraoperatively acquired pressure ulcers in the park-bench position: A retrospective study. *Int Wound J*. 2016 Dec;13(6):1206-13.
- Jain V, Davies M. Axillary artery compression in park bench position during a microvascular decompression. *J Neurosurg Anesthesiol*. 2011 Jul;23(3):264.
- Cheatham SW, Kolber MJ, Salamh PA. Meralgia paresthetica: A review of the literature. *Int J Sports Phys Ther*. 2013 Dec;8(6):883-93.
- van Slobbe AM, Bohnen AM, Bernsen RM, et al. Incidence rates and determinants in meralgia paresthetica in general practice. *J Neurol*. 2004 Mar;251(3):294-7.
- Parisi TJ, Mandrekar J, Dyck PJ, et al. Meralgia paresthetica: Relation to obesity, advanced age, and diabetes mellitus. *Neurology*. 2011 Oct;77(16):1538-42.
- Aszmann OC, Dellon ES, Dellon AL. Anatomical course of the lateral femoral cutaneous nerve and its susceptibility to compression and injury. *Plast Reconstr Surg*. 1997 Sep;100(3):600-4.
- Ghent WR. Further studies on meralgia paresthetica. *Can Med Assoc J*. 1961 Oct 14;85(16):871-5.
- Murata Y, Takahashi K, Yamagata M, et al. The anatomy of the lateral femoral cutaneous nerve, with special reference to the harvesting of iliac bone graft. *J Bone Joint Surg Am*. 2000 May;82(5):746-7.
- Ray B, D'Souza AS, Kumar B, et al. Variations in the course and microanatomical study of the lateral femoral cutaneous nerve and its clinical importance. *Clin Anat*. 2010 Nov;23(8):978-84.
- Kokubo R, Kim K, Morimoto D, et al. Anatomic variation in patient with lateral femoral cutaneous nerve entrapment neuropathy. *World Neurosurg*. 2018 Jul;115:274-6.
- Nouraei SA, Anand B, Spink G, O'Neill KS. A novel approach to the diagnosis and management of meralgia paresthetica. *Neurosurg*. 2007 Apr;60(4):696-700.
- de Ruyter GC, Kloet A. Comparison of effectiveness of different surgical treatments for meralgia paresthetica: Results of a prospective observational study and protocol for a randomized controlled trial. *Clin Neurol Neurosurg*. 2015 Jul;134:7-11.
- Hanna A. Transposition of the lateral femoral cutaneous nerve. *J Neurosurg*. 2018 Apr;13:1-6.
- Morimoto D, Kim K, Kokubo R, et al. Deep decompression of the lateral femoral cutaneous nerve under local anesthesia. *World Neurosurg*. 2018 Oct;118:659-65.
- Tagliafico A, Serafini G, Lacelli F, Perrone N, Valsania V, Martinoli C. Ultrasound-guided treatment of meralgia paresthetica (lateral femoral cutaneous neuropathy): Technical description and results of treatment in 20 consecutive patients. *J Ultrasound Med*. 2011 Oct;30(10):1341-6.
- Williams PH, Trzil KP. Management of meralgia paresthetica. *J Neurosurg*. 1991 Jan;74(1):76-80.

(Received, December 19, 2020)

(Accepted, February 3, 2021)

(J-STAGE Advance Publication, March 9, 2021)

Journal of Nippon Medical School has adopted the Creative Commons Attribution-NonCommercial-NoDerivatives 4.0 International License (<https://creativecommons.org/licenses/by-nc-nd/4.0/>) for this article. The Medical Association of Nippon Medical School remains the copyright holder of all articles. Anyone may download, reuse, copy, reprint, or distribute articles for non-profit purposes under this license, on condition that the authors of the articles are properly credited.