

Follicular conjunctivitis caused by *Chlamydia trachomatis* in an infant Saharan population: molecular and clinical diagnosis

J Javaloy, C Ferrer, M T Vidal, J L Alió

Br J Ophthalmol 2003;87:142-146

Series editors: W V Good and S Ruit

See end of article for authors' affiliations

Correspondence to: Consuelo Ferrer, Dpto Biología Molecular, Instituto Oftalmológico de Alicante, Avenida de Denia no 111, 03015 Alicante, Spain; cferrer@oftalio.com

Accepted for publication 20 April 2002

Aims: To ascertain the prevalence of acute trachoma as a supposed endemic disease among infants in the Saharan refugee camps of Tindouf (Algeria) and to evaluate the efficacy of treatment with a single dose of azithromycin.

Methods: 527 children aged between 3 and 17 were evaluated in the camp schools in October 2001. All the children were clinically and microbiologically examined, including slit lamp checks of anterior segment and two conjunctival swabs, one for the detection of membrane lipopolysaccharide by quick immunoassay test Clearview Chlamydia MF and the other for the detection of specific DNA by chlamydia plasmid specific polymerase chain reaction (PCR) assay. After examination, a single dose of azithromycin was administered to each child. One month later samples from positive children and 12 random negative children by the first PCR were taken to perform a new PCR assay.

Results: *Chlamydia trachomatis* was suspected in 2.47% of the children, papillary hypertrophy being the most frequently seen clinical sign. Scarring changes secondary to trachoma were detected in 11.7% of the children. Only four cases (0.8%) were positive to the immunoassay test and 12 cases (2.27%) were positive by PCR. After treatment a second PCR was performed on positive children and they were negative of chlamydia DNA amplification. However, one child who was negative and received the treatment was positive in the second PCR assay.

Conclusion: Acute trachoma prevalence is much lower than expected among infants in this Saharan population. The possible reasons could be the recent improvements in hygiene and health care. Cicatricial trachoma is more frequent. The Clearview immunoassay test has very low sensitivity in the detection of this disease. A single dose of azithromycin is sufficient to treat chlamydial conjunctivitis. However, a programme of improvement in hygiene and health care is necessary to prevent re-infection.

Trachoma is one of the oldest illnesses of those known to humankind, being the most frequent cause of blindness that could be avoided in developing countries.¹ In chronic conjunctivitis produced by *Chlamydia trachomatis* (serotypes A-C), the various reinfections end up causing scarring of the conjunctiva, xerosis, entropion-trichiasis, permanent damage to the cornea, and opaqueness which results in blindness.² It is an illness associated with poverty and lack of hygiene. It is propagated through direct contact with the eye secretions³ or by flies that come into contact with these secretions.^{4,5} The environmental characteristics and habits that most influence its eradication are the presence and use of toilets, the supply of running drinking water, and the daily washing of the children's faces.⁶⁻⁹ These factors, along with the close contact with cattle in the domestic environment, contribute to an increase in the presence of the flies among the population and leads to a condition known as "ocular promiscuity" favouring eye to eye contact by the insects.^{3,5,8}

Trachoma has been eliminated as an illness which causes blindness in various endemic countries and regions, by means of significant improvements in the social and economic situation of the population and by means of specific sanitary measures. However, in some of the countries where trachoma was endemic, there are still residual pockets of trachoma and complications, such as entropion-trichiasis, which requires surgery of the eyelid.¹⁰

The prophylactics, in addition to the raising of awareness to improve hygiene, are decisive in eradicating the illness. The appearance of an antibiotic called azithromycin has brought

new hope to the treatment of this illness that is still prevalent in many countries.¹¹⁻¹⁶

The Arab Saharan Democratic Republic is a nation without land which has lived in refugee camps for more than 25 years, situated in the heart of the Algerian Sahara desert. Health care in the refugee camps is maintained principally through the expeditions sent by different non-governmental organisations (NGOs) and official aid organisms. According to the estimates of the World Health Organization (WHO), there must be more than 2000 blind people in the camps and three times as many visually impaired. The adults with palpebral scars and the children infected by chlamydia constitute the reservoir for future generations of blind people due to trachoma.^{4,5} There is no documentary evidence about the prevalence and incidence of trachoma in the camps, only estimates based on data of similar populations which lead us to presume a high impact in this society.

The clinical diagnosis of the late cicatricial stages of trachoma is simple, because of the relative specificity of its appearance. On the other hand the predictive value of the signs habitually present in the extreme cases of conjunctivitis is quite low. In this way, a low clinical-bacteriological correlation for acute infections by *Chlamydia trachomatis* has been reported.¹⁷⁻²⁰ Therefore, in order to conclude that a follicular conjunctivitis is produced by *C trachomatis* a microbiological diagnosis is necessary. Among the existing tests to detect *C trachomatis* in biological samples, the polymerase chain reaction (PCR) is the most favoured owing to its high sensitivity and specificity.²⁰⁻²⁷ Its main limitation lies in its availability in economically deprived areas where simpler tests

Table 1 Simplified trachoma grading proposed by the WHO.²⁸ The signs were grouped according to whether they were acute or chronic

	Abbreviation	Denomination	Clinical findings
Acute trachoma	TF	Trachomatous inflammation—follicular	Presence of five or more follicles at least 0.5 mm in diameter, in the upper tarsal conjunctiva
	TI	Trachomatous inflammation—intense	The tarsal conjunctiva appears red, rough and thickened. There are usually numerous follicles which may be partially or totally covered by the thickened conjunctiva
Cicatricial trachoma	TS	Trachomatous scarring	The presence of scarring in the tarsal conjunctiva. Scars are easily visible as white lines, bands, or sheets in the tarsal conjunctiva
	TT	Trachomatous trichiasis	At least one eyelash rubs on the eyeball. Evidence of recent removal of intumed eyelashes should also be graded as trichiasis
	CO	Corneal opacity	The pupil margin is blurred viewed through the opacity. Such corneal opacities cause significant visual impairment (less than 6/18 or 0.3 vision), and therefore visual acuity should be measured if possible.

are necessary with lower costs to help with the diagnosis in these countries.

The objective of this work has been (i) to undertake an epidemiological study to find out the current prevalence of active trachoma infection in the child population in the refugee camps of the Arab Saharan Democratic Republic in Tindouf (Algeria) by means of DNA detection of *C trachomatis* by PCR, (ii) to compare the results obtained by PCR with those obtained by Clearview immunoassay test, and (iii) to evaluate the efficacy of treatment with a single dose of azithromycin.

MATERIALS AND METHODS

Patients and clinical evaluation

During the month of October 2001, 527 children aged between 3 and 17, living in schools or nurseries of the Saharan refugee camps of Tindouf, were evaluated consecutively by the same group of researchers. In order to select the schools in which the studies were undertaken the advice of the ministries of health and education was taken into account. They were informed of the objective of the study and chose the geographical area and the centres which would be representative of the Saharan population in terms of the social, economic, and cultural characteristics of the inhabitants.

Each child underwent a biomicroscopic check with a slit lamp and two samples (conjunctival swabs) were taken for microbiological study. Name, age, sex, weight, and clinical data of interest was registered, and the samples of each child were marked with an identification number.

In the clinical check the following signs were taken into account: hyperaemia, secretions, small follicles in low quantities, large follicles (over 0.5 mm) in quantities over five, papillae, tarsal scarring (line of Arlt), scarring of limbic follicles (Herbert's pits), pannus, entropion, trichiasis, leucoma, and xerosis. The simplified classification for trachoma proposed by the WHO²⁸ was applied, the signs were grouped according to whether they were acute or chronic. The possible cases considered from a clinical point of view as acute trachoma were those in which the signs found led to them being included in the TF (trachomatous follicular) or TI (intense) groups of the aforesaid classification. The signs included in the groups TS (scarring), TT (trichiasis), or CO (corneal opacity) were considered criteria of chronic trachoma (Table 1).

After examination, a single dose of azithromycin (Zithromax, Pfizer), was provided for each child (20 mg/kg). One month later, some ocular samples from those children were taken. Because the children were scattered around the camp, it was only possible to take samples of nine of the 12 children

whose microbiological analysis was positive. Twelve negative children also were taken at random to perform a new PCR assay.

Ocular samples

Conjunctival swabs of each eye were taken with a dry cotton bud, ensuring the greatest quantity of epithelial cells were obtained.

One of the swabs was used to detect the lipopolysaccharide epitope of Chlamydia (LPS) by immunoassay and the other to detect *C trachomatis* DNA by the PCR.

Detection of lipopolysaccharide epitope of *Chlamydia* spp

The detection of the LPS was performed by a rapid immunoassay test, Clearview Chlamydia MF (Unipath, Bedford, UK). The cells of the swab were suspended in 1.5 ml of sterile water by vortex. After spinning, 0.6 ml of extraction reagent was added to the pellet and heated at 80°C for 10–12 minutes. Five drops of extract were applied to the sample window of the test unit.

Clearview Chlamydia MF immunoassay test is used normally to direct qualitative detection of *C trachomatis* antigen in either female endocervical swab specimens or male urine specimens.²⁹

Detection of *Chlamydia trachomatis* DNA

DNA extraction

Swabs were placed into 1.5 ml of sterile water and vortex. After spinning, the DNA was isolated by using the InstaGene Matrix (Bio-Rad Laboratories, Hercules, CA, USA) as specified by the manufacturer.

DNA amplification by PCR

Extracted DNA was amplified using a RoboCycler 96 Temperature Cycle (Stratagene, La Jolla, CA, USA).

The specific primers used for chlamydial DNA amplification were KL-1 and KL-2, derived from the sequence of the conserved cryptic plasmid.³⁰ The PCR was performed as described by Mahony *et al.*³⁰ Aliquots (10 µl) of each amplified product were electrophoretically separated in a 2% agarose gel in 1X TRIS-borate-EDTA buffer and visualised using ethidium bromide under ultraviolet illumination.

RESULTS

The average age of the population studied was 9.74 (SE 2.81), with ages of between 3 and 16 years old and 52% were girls.

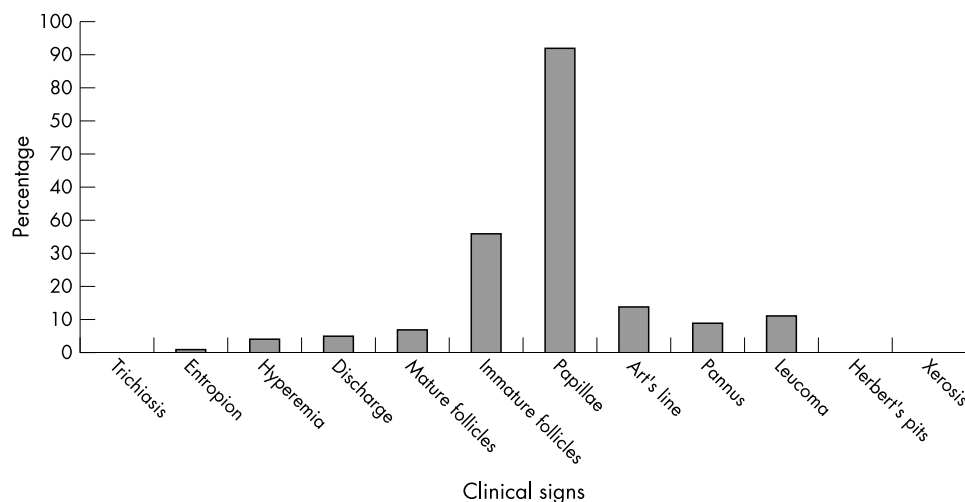


Figure 1 Frequency of appearance of the different clinical signs in the child population.

The children were from nine schools which were geographically as close as possible, in such a way that all were located in the "Daira" (settlement) of Auserd and had a maximum distance of 5 km between them.

Clinical features

The clinical sign that appeared with most frequency among the 527 children studied was the presence of papillae (92%), followed by the follicles smaller than 0.5 mm, line of Arlt, leucoma, pannus, and follicles larger than 0.5 mm and in quantities over five. Figure 1 shows the percentage of all the parameters studied and their prevalence in the child population.

According to the classification of Table 1, acute trachoma was present in only 2.47% of the children examined. However, cicatricial trachoma appeared with greater frequency than acute trachoma. There were 47 children showing line of Arlt, 25 children with pannus, and none with Herbert pits; therefore, the percentage of cicatricial trachoma was 11.7%.

Test for the detection of LPS

Only four samples were positive using the Clearview test, their corresponding clinical signs are shown in Table 2. Only two of these four showed the same results by PCR. Therefore, the specificity and sensitivity of this test is very low for this kind of samples, 50% and 16.67%, respectively.

Results obtained by amplification of DNA

Of the 527 samples taken in the first sampling, 12 were positive by amplification of DNA of *C trachomatis*. Of these 12 samples, only two were also positive with the Clearview test. Table 2 shows the clinical features of the samples detected by PCR

During the second sampling, 1 month after administrating azithromycin to the population, 21 samples were taken, nine from children who had been positive with the first PCR test and 12 samples from children who had been negative. All the children who had been positive were negative by the PCR in the second analysis. However, one of the 12 children who had been negative in the first analysis was positive 1 month later.

DISCUSSION

In the present work, an active trachoma epidemiological study of child population from a trachoma endemic area in Algeria was performed by PCR, according to the method of Mahony.³⁰

Our results indicate that the incidence of acute trachoma in the child population in this area is much lower than expected. In studies carried out previously in other endemic areas, it has been observed that the child population is the preferred target of the recurring severe infections by *Chlamydia trachomatis*, their secretions constituting an important reservoir of the parasite in these areas.³ This low incidence may be due to the social and cultural changes that have recently occurred in the population. The impact of the environmental conditions on the distribution of trachoma as an epidemic has been documented on many occasions.^{6-8 31} Of all the factors analysed, the distance from water and the presence of cattle in the domestic environment seem to have a strong association with the incidence of the infection.^{3 7} Recent changes in the lifestyle of the adult and child community that inhabit the refugee camps may explain the low prevalence obtained. These changes include the recent incorporation of all children from the age of 3 into schools and the fact that the domestic

Table 2 Samples positives by PCR or by Clearview immunoassay test and their corresponding clinical signs

Sample number	Positive by PCR	Positive by immunoassay	Signs of acute trachoma	Signs of cicatricial trachoma
CH1	+		SF	
CH27	+	+		Pannus
CH28	+		SF	
CH39	+		BF	Line of Arlt
CH66		+		
CH74	+		SF	Pannus
CH125	+		BF	
CH240		+		
CH310	+	+	SF	
CH365	+			
CH368	+		SF	
CH373	+		SF	
CH374	+			
CH385	+			

SF = small follicles; BF= follicles longer than 0.5 mm.

animals (goats and camels) have been moved towards the outside areas of the "Dairas" (settlements).

The WHO has recommended a simplified classification of trachoma in which the main clinical signs are detailed.²⁸ In this classification the clinical signs that lead to suspicion of follicular conjunctivitis caused by *C trachomatis*, are the presence of follicles of the appropriate size and the enlargement of the tarsal conjunctiva. In the Saharan population studied the existence of papillae was practically universal (92%); however, this sign was as frequent as unspecific. Together with this, the presence of grains of sand causing chronic irritation of the ocular surface was almost constant. Mild follicular hypertrophy was also very frequent (36%). The presence of irritating factors due to the environmental conditions such as the desert sand and dust, led us to discard these unspecific signs as suspicious of infection by trachoma in the acute phase.

Taking into account the rest of the signs of trachoma, large follicles in quantities over 5, the prevalence of clinical trachoma in the acute phase was 2.47%. A priori, this prevalence could correspond to the 2.27% obtained using the PCR; however, if we analyse the samples that were positive by the PCR we can see that they do not correspond to those that were diagnosed on the basis of the clinical signs. This consolidates the fact that the correlation between the clinical and the microbiological diagnosis is very poor. The low efficacy of the clinical suspicion of acute trachoma (presence of follicular conjunctivitis) as a diagnostic instrument has been brought to light in other studies in which the clinical-microbiological correlation whether by culture, immunoassay, PCR, etc, was very low.¹⁷⁻²⁰

Using the Clearview immunoassay test the percentage of individuals who had *C trachomatis* is 0.08%. This test has not been previously used in conjunctival samples, only in urethral and exocervical samples, in which it has a sensitivity of 67.7–93% and a specificity of 95.5–99.8% respectively.²⁹⁻³² We have used this immunoassay test because it is quick and easy to carry out in the place where the sample is taken. In addition, on detecting the genus specific lipopolysaccharide of membrane of chlamydia, a priori, it should also be capable of detecting both groups of serotypes (A-C to D-K).³³ The low rate of positives in comparison with the PCR test, may be due to the lower sensitivity of the test in samples with a low quantity of cells, as occurs in the urethral samples in which the sensitivity drops to 67.7%.³² However, it does not have levels as low as obtained in this study when compared to the PCR test. Another cause that could explain the low correlation between the two tests could be that a sample was taken from each eye for each test and that in the moment of taking the sample the conjunctivitis was unilateral; nevertheless, this is an unusual situation. This circumstance, or the appearance of a false positive for no apparent reason, could explain the fact that there are two samples that were positive by the Clearview test and negative by PCR. These two samples underwent another PCR test based on the amplification of a zone of the chromosome, specifically the gene *omp-1*.³⁴ Several DNA regions can be used as a target for amplification, including the cryptic plasmid,³⁰ major outer membrane protein (MOPS),³⁴ or rRNA genes.²³ In this work we have used the plasmid based PCR, because it is more sensitive than the bacteria chromosome based PCR to detect *C trachomatis*.²¹⁻³⁵ However, in endocervical samples some strains have been detected that did not show this plasmid.³⁶⁻³⁷ Although no strain with these characteristics has been detected to date in conjunctival samples, a second PCR was carried out to amplify the MOMP gene present in the bacterial chromosome in the two samples that were negative by PCR and positive by Clearview. Both of them were negative, supporting the theory of a low specificity of the Clearview test, a cross reaction between a major glycolipid antigen of chlamydia and the innermost core of the lipopolysaccharide of enteric bacteria³⁸ or unilateral acute trachoma in the moment of taking the sample.

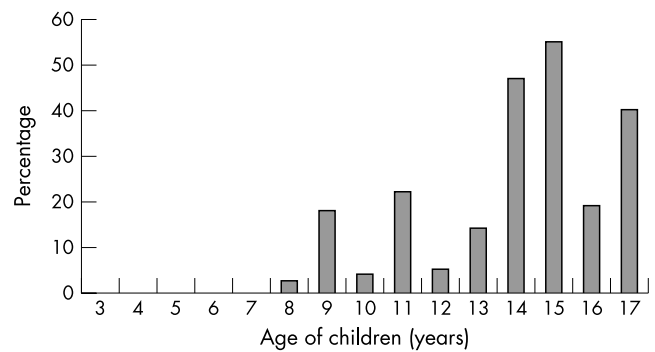


Figure 2 Percentage of children with cicatricial trachoma grouped by age.

Using PCR we have obtained 12 positive samples corresponding to 2.27% of the population studied. In these samples, not all showed symptoms of acute trachoma, nor were all those with symptoms of acute trachoma positive with the PCR. This leads us to the conclusion that the clinical diagnosis is useful as a guide but is not sufficient to be able to declare whether a patient is infected by *C trachomatis* or not.

The percentage of cicatricial trachoma by clinical picture was double that of acute trachoma. As expected, this percentage increases in children as their age increases because reinfection is a necessary factor in order to produce cicatricial trachoma (Table 2). The recent adoption of environmental measures which, in our opinion, has caused a decrease in acute infections has not prevented the presence of these in older children and adolescents (Fig 2).

The WHO has chosen trachoma as a priority objective in its global project "Vision 2020." In this project, international efforts to eliminate trachoma as a potentially blinding disease will be based on the strategy named project GET (Global Elimination of Trachoma) elaborated by the WHO—a combination of operations known as "SAFE"⁵ which includes Surgical procedures, Antibiotic treatment, Facial cleaning, and Environmental changes. We have already seen how an improvement in the environmental conditions has reduced trachoma in this Saharan population. If we observe the results obtained in the samples taken 1 month after the treatment with azithromycin we can see that the treatment is indeed effective as none of the children who had *C trachomatis* detected in the first PCR had it detected in the second. But the fact that one of the children who was negative by the first PCR, received the treatment, and 1 month later was positive, contributes even more to support the idea that environmental changes are necessary in addition to the administration of antibiotics to avoid reinfection, and in this way eradicate trachoma from these countries.

Given the results obtained, and contrary to what could be expected, the prevalence of the acute trachomatous infection—in the school age population of this poor area with a hot, dry climate—is relatively low at 2.27%; the low figures obtained, together with the higher figures for cicatricial trachoma, can be explained by taking into account recent cultural and environmental hygiene changes, such as universal schooling and the distancing of the cattle from the domestic environment. In addition to the administration in mass of doses of oral azithromycin, social and cultural changes are necessary in order to improve the hygienic conditions if the rate of transmission is to be reduced.

ACKNOWLEDGEMENTS

We thank Belen Esteban for her collaboration with the taking of samples and her knowledge of Saharan customs. We thank the health authorities of Saharan refugee camps of Tindouf for their invaluable assistance in recruiting patients.

We would also like to thank Jorge J Pacheco, Raquel Pérez, Lorena Rodrigo, Felipe Cáliz and M Angeles Cáliz for their invaluable collaboration in the campaign.

Supported by a grant from the Generalitat Valenciana (AE01-117), Rotary Club Alicante, Fundación Jorge Alió, Colegio de Farmacéuticos de Alicante, Ayuntamiento de Villena, Asociación del Pueblo Saharai de Villena, and UNICEF.

Authors' affiliations

J Javaloy, M T Vidal, J L Alió, Instituto Oftalmológico de Alicante, Alicante, Spain
C Ferrer, Dpto Biología Molecular, Instituto Oftalmológico de Alicante, Alicante, Spain
J L Alió, División de Oftalmología, Universidad Miguel Hernández, Alicante, Spain

REFERENCES

- 1 Thylefors B, Négrel AD, Parajasegaram R, et al. Global data on blindness. *Bull World Health Organ* 1995;**73**:115-21.
- 2 Grayston JT, Wang SP, Yeh LJ, et al. Importance of reinfection in the pathogenesis of trachoma. *Rev Infect Dis* 1985;**7**:717-25.
- 3 Darougar S, Forsey T, Jones BR, et al. Isolation of Chlamydia trachomatis from eye secretions (tears). *Br J Ophthalmol* 1979;**63**:256-8.
- 4 Emerson PM, Bailey RL, Mahdi OS, et al. Transmission ecology of the fly *Musca sorbens*, a putative vector of trachoma. *Trans R Soc Trop Med Hyg* 2000;**94**:28-32.
- 5 Forsey, Darougar S. Transmission of chlamydiae by the housefly. *Br J Ophthalmol* 1981;**65**:147-50.
- 6 Marx R. Social factors and trachoma: a review of the literature. *Soc Sci Med* 1989;**29**:23-34.
- 7 Prost A, Négrel AD. Water, trachoma and conjunctivitis. *Bull World Health Organ* 1989;**67**:9-18.
- 8 Prüss A, Mariotti SP. Preventing trachoma through environmental sanitation: a review of the evidence base. *Bull World Health Organ* 2000;**78**:258-66.
- 9 Esrey SA, Potash JB, Roberts L, et al. Effects of improved water supply and sanitation on ascariasis, diarrhoea, dracunculiasis, hookworm infection, schistosomiasis and trachoma. *Bull World Health Organ* 1991;**69**:609-21.
- 10 Lewallen S, Courtright P. Blindness in Africa: present situation and future needs. *Br J Ophthalmol* 2001;**85**:897-903.
- 11 Laming AC, Currie BJ, DiFrancesco M, et al. A targeted, single-dose azithromycin strategy for trachoma. *Med J Aust* 2000;**172**:163-6.
- 12 Tabbara KF, Abu El-Asrar MA, Al-Omar O, et al. Single-dose azithromycin in the treatment of trachoma. A randomized, controlled study. *Ophthalmology* 1996;**103**:842-6.
- 13 Whitty CJ, Glasgow KW, Sadiq ST, et al. Impact of community-based mass treatment for trachoma with oral azithromycin on general morbidity in Gambian children. *Pediatr Infect Dis J* 1999;**18**:955-8.
- 14 Schachter J, West SK, Mabey D, et al. Azithromycin in control of trachoma. *Lancet* 1999;**354**:630-5.
- 15 Nessi F, Guex-Groseir Y. Negativation of Chlamydia trachomatis PCR in conjunctival swabs after therapy with a single dose of 1 gram azithromycin. *Invest Ophthalmol Vis Sci* 2001;**42**:S257.
- 16 Négrel AD, Mariotti SP. WHO alliance for the global elimination of blinding trachoma and the potential use of azithromycin. *Int J Antimicrob Agents* 1998;**10**:259-62.
- 17 Talley AR, Garcia-Ferrer F, Laycock KA, et al. The use of polymerase chain reaction for the detection of chlamydial keratoconjunctivitis. *Am J Ophthalmol* 1992;**114**:685-92.
- 18 Bersudsky V, Rehany U, Tendler Y, et al. Diagnosis of chlamydial infection by direct enzyme-linked immunoassay and polymerase chain reaction in patients with acute follicular conjunctivitis. *Graefes Arch Clin Exp Ophthalmol* 1999;**237**:617-20.
- 19 Zhang W, Wu Y, Zhao J. Rapid diagnosis and treatment of chlamydial conjunctivitis. *Chin Med J [Engl]* 1995;**108**:138-41.
- 20 Haller EM, Auer-Grumbach P, Stuenzner D, et al. Evaluation of two nonculture antigen tests and three serostests for detection of anti-chlamydial antibodies in the diagnosis of ocular chlamydial infections. *Graefes Arch Clin Exp Ophthalmol*. 1996;**234**:510-4.
- 21 Mahony JB, Luinstra KE, Sellors JW, et al. Comparison of plasmid- and chromosome-based polymerase chain reaction assays for detecting Chlamydia trachomatis nucleic acids. *J Clin Microbiol* 1993;**31**:1753-8.
- 22 Bobo L, Munoz B, Viscidi R, et al. Diagnosis of Chlamydia trachomatis eye infection in Tanzania by polymerase chain reaction/enzyme immunoassay. *Lancet* 1991;**338**:847-50.
- 23 Claas HC, Melchers WJ, de Bruijn IH, et al. Detection of Chlamydia trachomatis in clinical specimens by the polymerase chain reaction. *Eur J Clin Microbiol Infect Dis* 1990;**9**:864-8.
- 24 Mahony JB, Luinstra KE, Jang D, et al. Chlamydia trachomatis confirmatory testing of PCR-positive genitourinary specimens using a second set of plasmid primers. *Mol Cell Probes* 1992;**6**:381-8.
- 25 Kluytmans JA, Goessens WH, Mouton JW, et al. Evaluation of Clearview and Magic Lite tests, polymerase chain reaction, and cell culture for detection of Chlamydia trachomatis in urogenital specimens. *J Clin Microbiol* 1993;**31**:3204-10.
- 26 Elnifro EM, Storey CC, Morris DJ, et al. Polymerase chain reaction for detection of Chlamydia trachomatis in conjunctival swabs. *Br J Ophthalmol* 1997;**81**:497-500.
- 27 Bass CA, Jungkind DL, Silverman NS, et al. Clinical evaluation of a new polymerase chain reaction assay for detection of Chlamydia trachomatis in endocervical specimens. *J Clin Microbiol* 1993;**31**:2648-53.
- 28 Taylor HR. Trachoma grading: a new grading scheme. *Rev Int Trach Pathol Ocul Trop Subtrop Sante Publique* 1987;**64**:175-81.
- 29 Arumainayagam JT, Matthews RS, Uthayakumar S, et al. Evaluation of a novel solid-phase immunoassay, Clearview Chlamydia, for the rapid detection of Chlamydia trachomatis. *J Clin Microbiol* 1990;**28**:2813-4.
- 30 Mahony JB, Luinstra KE, Sellors JW, et al. Confirmatory polymerase chain reaction testing for Chlamydia trachomatis in first-void urine from asymptomatic and symptomatic men. *J Clin Microbiol* 1992;**30**:2241-5.
- 31 Takourt B, Milad A, Radouani F, et al. Isolation of Chlamydia trachomatis in trachomatous Moroccan patients. *J Fr Ophthalmol* 1996;**19**:527-32.
- 32 Chernesky M, Jang D, Krepel J, et al. Impact of reference standard sensitivity on accuracy of rapid antigen detection assays and a leukocyte esterase dipstick for diagnosis of Chlamydia trachomatis infection in first-void urine specimens from men. *J Clin Microbiol* 1999;**37**:2777-80.
- 33 Brade H, Brade L, Nano FE. Chemical and serological investigations on the genus-specific lipopolysaccharide epitope of Chlamydia. *Proc Natl Acad Sci USA* 1987;**84**:2508-12.
- 34 Lan J, Ossewaarde JM, Walboomers JM, et al. Improved PCR sensitivity for direct genotyping of Chlamydia trachomatis serovars by using a nested PCR. *J Clin Microbiol* 1994;**32**:528-30.
- 35 Roosendaal R, Walboomers JM, Veltman OR, et al. Comparison of different primer sets for detection of Chlamydia trachomatis by the polymerase chain reaction. *J Med Microbiol* 1993;**38**:426-33.
- 36 An Q, Olive DM. Molecular cloning and nucleic acid sequencing of Chlamydia trachomatis 16S rRNA genes from patient samples lacking the cryptic plasmid. *Mol Cell Probes* 1994;**8**:429-35.
- 37 Farencena A, Comanducci M, Donati M, et al. Characterization of a new isolate of Chlamydia trachomatis which lacks the common plasmid and has properties of biovar trachoma. *Infect Immun* 1997;**65**:2965-9.
- 38 Nurminen M, Leinonen M, Saikku P, et al. The genus-specific antigen of Chlamydia: resemblance to the lipopolysaccharide of enteric bacteria. *Science* 1983;**220**:1279-81.