

Carcinoma gingival: reporte de un caso clínico

Gingival carcinoma: a case report

Carcinoma gengival: um relatório de caso

Adel Martínez Martínez¹
Marlon Reina Batista²
Antonio Diaz Caballero³

Recibido: 17 de noviembre 2022

Aprobado: 22 de noviembre 2022

Publicado: 31 de diciembre de 2022

Cómo citar este artículo:

Martínez Martínez A, Reina Batista M, Diaz Caballero A. Carcinoma gingival: reporte de un caso clínico. Revista Nacional de Odontología (2022); 18(2), 1-15.
doi: <https://doi.org/10.16925/2357-4607.2022.02.08>

Reporte de caso. <https://doi.org/10.16925/2357-4607.2022.02.08>

¹ Oral Surgeon, Assistant Professor, Department of Oral Medicine, Gitouc Investigation Group, Faculty of Dentistry, University of Cartagena. Cartagena, Colombia.

Correo electrónico: amartinezm4@unicartagena.edu.co.

ORCID: <https://doi.org/0000-0001-7008-2222>

² Oral Pathologist, Professor, Department of Oral Medicine, Metropolitan University, Barranquilla, Colombia.

Correo electrónico: lapatologiaoral@hotmail.com.

ORCID: <https://doi.org/0000-0001-6791-7268>

³ Periodontist, Professor, Department of Oral Medicine, Director of Gitouc Investigation Group, School of of Dentistry, University of Cartagena. Cartagena, Colombia.

Correo electrónico: adiazc1@unicartagena.edu.co.

ORCID: <https://doi.org/0000-0001-9693-2969>



Resumen

El carcinoma de células escamosas o escamocelular es una neoplasia epitelial maligna que se caracteriza por que sus manifestaciones clínicas son variadas. El objetivo de este artículo es presentar el caso clínico de un paciente con carcinoma gingival de células escamosas, sin antecedentes de factores de riesgo comunes para el desarrollo de esta neoplasia: mujer de 95 años con un historial de seis meses de una lesión proliferativa dolorosa y de rápido crecimiento en la encía marginal vestibular de los dientes # 33-32-31-43-42-41. De acuerdo con los signos y síntomas clínicos, se da una impresión clínica de carcinoma gingival y un diagnóstico diferencial de granuloma central de células gigantes, se tomó una biopsia por escisión de la lesión. El diagnóstico fue de carcinoma de células escamosas. Después de tres días, la paciente falleció en el hospital por un cuadro de disnea severa que le produjo un paro cardiorrespiratorio. El carcinoma gingival de células escamosas es una afección con un buen pronóstico cuando se diagnostica y trata a tiempo, este artículo informó un caso de un paciente que falleció antes de realizar un tratamiento a lesión tumoral.

Palabras clave: cáncer oral; carcinoma escamocelular; neoplasia gingival; detección temprana de cáncer.

Abstract

Squamous-cell carcinoma is a malignant epithelial neoplasm characterized by various clinical manifestations. Present study aimed to report a case of gingival squamous-cell carcinoma in a who patient did not present risk factors associated with the referred neoplasm. A 95-year-old female, attended dental services exposing a rapidly growing, painful proliferative lesion of 6 months of evolution, located in vestibular marginal gingiva, which affected teeth # 33-32-31-43-42-41. According to clinical symptoms and differential diagnosis (central giant cell granuloma and malignant neoplasm), an excisional biopsy was obtained. Diagnosis of referred carcinoma was obtained after three days of patient decease consequent to a severe dyspnea case. Gingival squamous-cell carcinoma is a condition that usually has a good prognostic when diagnostic and treatment are established on time. This study reports a clinical case of a patient who died before having an opportunity to access treatment.

Keywords: oral cancer; squamous cell carcinoma; gingival neoplasms; early detection of cancer.

Resumo

O carcinoma de células escamosas é uma neoplasia epitelial maligna caracterizada por manifestações clínicas variáveis. O objetivo deste estudo foi relatar um caso de carcinoma espinocelular, no qual o paciente não apresentava fatores de risco para o desenvolvimento dessa neoplasia. Uma mulher de 95 anos de idade foi observada com 6 meses de história de uma lesão proliferativa dolorosa de crescimento rápido na gengiva marginal vestibular na zona dos dentes # 33-32-31-43-42-41. Assim, diante dos sintomas clínicos e do diagnóstico diferencial de granuloma central de células gigantes e neoplasia maligna, foi obtida uma biópsia excisional da lesão. Foi feito o diagnóstico de carcinoma espinocelular. Após três dias, o paciente falecido no hospital apresentou dispnéia grave. O carcinoma de células escamosas gengival é uma condição com bom prognóstico quando diagnosticado e tratado precocemente. Este estudo relatou um caso de paciente que morreu antes de realizar um tratamento tumoral.

Palavras-chave: câncer bucal; carcinoma de células escamosas; neoplasias gengivais; detecção precoce de câncer.

Introduction

Oral cancer is a very frequent neoplasm worldwide, such term comprises neoplasms of labial mucosa, tongue, gingiva, floor of mouth, and palate. Squamous-Cell Carcinoma (SCC) is known as the most prevalent malignant neoplasm from oral cavity, according to World Health Organization (WHO), it corresponds to more than 90% of all malignant mouth lesions [1]. It is also established as a major cause of morbidity and mortality in patients diagnosed with head and neck cancer. SCC presents more frequently in male population; it generally appears after the fifth decade of life [2]. Most common sites of presentation are lateral and ventral tongue surface, floor of mouth and buccal mucosa followed in lower frequency by soft palate and gingiva [3].

Gingiva as previously referred presents a lower frequency of appearance, it comprises about 10% of all SCC but affects 91% of patients older than 66 years diagnosed with gingival carcinoma [4,5]. Two main factors that have influence in most diseases are genetic and epigenetic factors, despite that, etiology of SCC remains unknown, however, some predisposing factors such as smoking, high alcohol consumption, as well as chewing betel leaves, inverted smoking, oral candidiasis, use of mouthwash, and mate intake are some habits that have been associated with SCC. Other factors like diet lifestyle and nutrition, exposure to radiation, ethnicity, familiar and genetic predisposition, immunosuppression, occupational risks, and presence of some diseases like syphilis and infectious proliferative processes caused by human papillomavirus (HPV) are considered as well [6-9].

Clinical characteristics of gingival carcinoma differ for each case, and it can be presented as diverse exophytic lesions that may be verrucous, papillary, ulcerated, erythroplastic, leukoplakic, or erythroleukoplakic, these lesions have possibility to develop painful symptoms depending on their extension and/or location, and resorption level of adjacent bone [10], despite this, gingival carcinoma is normally painless and located in keratinized tissue [11,12]. SCC is usually preceded by a variety of cellular and tissue alterations confined to epithelium when epithelial dysplasia shows a severe degree, there are greater possibilities of a malignant transformation, consequently, an adequate characterization of histopathological characteristics of each dysplasia subtype is essential to determine an accurate prognosis [13].

Gingival neoplasms are relatively infrequent compared to other benign gingival lesions, its diagnosis represents a challenge for clinicians, who may not suspect a carcinoma considering that there are many other commonly found pathologies (central giant cell granuloma, peripheral giant cell granuloma, infectious proliferative processes caused by human papillomavirus). Gingival neoplastic lesions show an early

invasion of subjacent bone due to thinness of attached gingiva; it is worth noting that prognostic implications of such behavior are still unclear [14].

Treatment of gingival carcinoma is primarily surgical. Radical neck dissection, or its modification, as a standard treatment for metastatic lymph nodes. Radiotherapy is not usually employed as a treatment for early stages of gingivobuccal cancer; it is used either as postoperative adjuvant treatment or as definitive treatment for advanced cancer with or without chemotherapy. Chemotherapy has been used as neoadjuvant, adjuvant or palliative treatment [15]. Regardless of advances in diagnosis and treatment during last 40 years, overall, 5-year survival rate for oral and oropharyngeal SCC has shown minimal improvement and it remains around 50%. Thus, early diagnosis and treatment of carcinoma by health care providers is essential to achieve a good prognosis [16,17].

Authors report in this study a case of gingival carcinoma involving right mandibular region, affecting zone of canine, lateral and central teeth.

Clinical case

A 95-year-old female referring a gingival overgrowth was examined at Stomatology Clinic from Oral Medicine Department of Cartagena University Dental School. Patient reported that gingival augmentation was affecting lower incisors and had an evolution of 6 months. Woman's background included three myocardial infarctions over the last six years, sulfamide allergy, drug-controlled hypertension, oral anticoagulant treatment including clopidogrel and acetylsalicylic acid (ASA). Physical examination showed a low weight patient who needed help to mobilize, mentally oriented in one of three dimensions, in person but not in space or time, mild dyspnea and oral breathing were also observed, overall, health condition was considered regular. Lymph nodes palpation revealed presence of two firms, fixed and asymptomatic nodules in submandibular region. Intraoral clinical evaluation showed an exophytic lesion, measuring 2 x 3 cm that involved teeth #31-41-42-43-44, exposing an irregular surface of soft consistency, bluish-red color, mobile with a pedunculated base and necrotic areas, Lesion was asymptomatic. Other oral mucous membranes observed were within normal characteristics (figure 1).

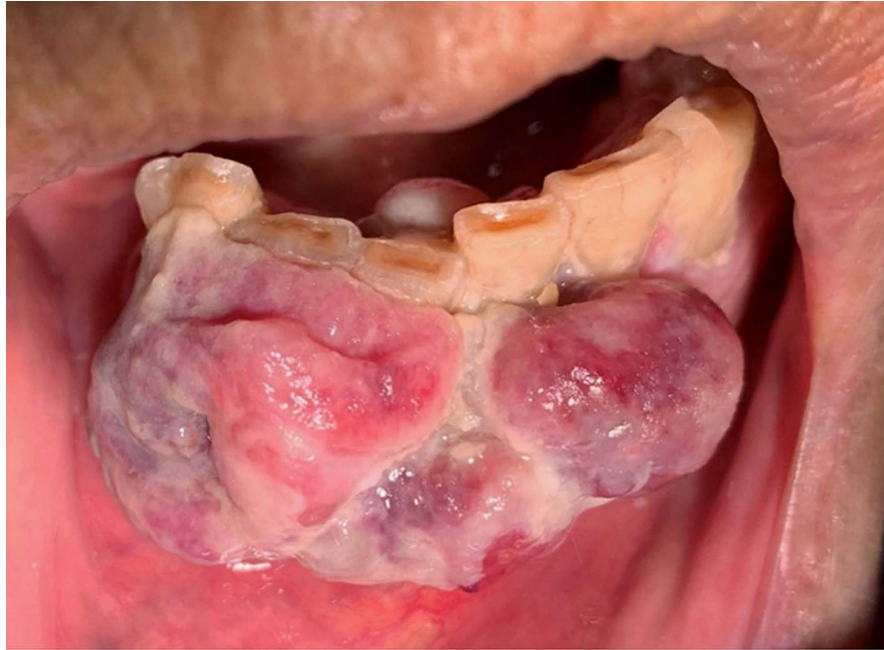

Figure 1. Clinical view of an exophytic lesion, measuring 2 x 3 cm, located in mandibular incisive zone, showing an irregular surface of soft consistency, bluish-red color, mobile with a pedunculated base and necrotic areas, asymptomatic.

There was evidence of dental biofilm accumulation and halitosis due to poor oral hygiene (figure 2).

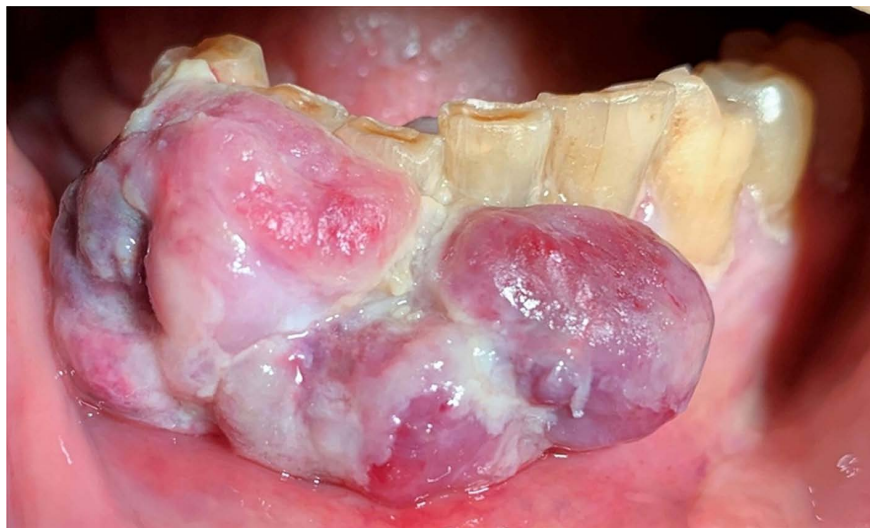

Figure 2. Evidence of dental biofilm accumulation due to poor oral hygiene. Periapical radiography showed radiolucent areas with loss of cortical bone continuity among interproximal zone between teeth #31-41-42-43 (figure 3).

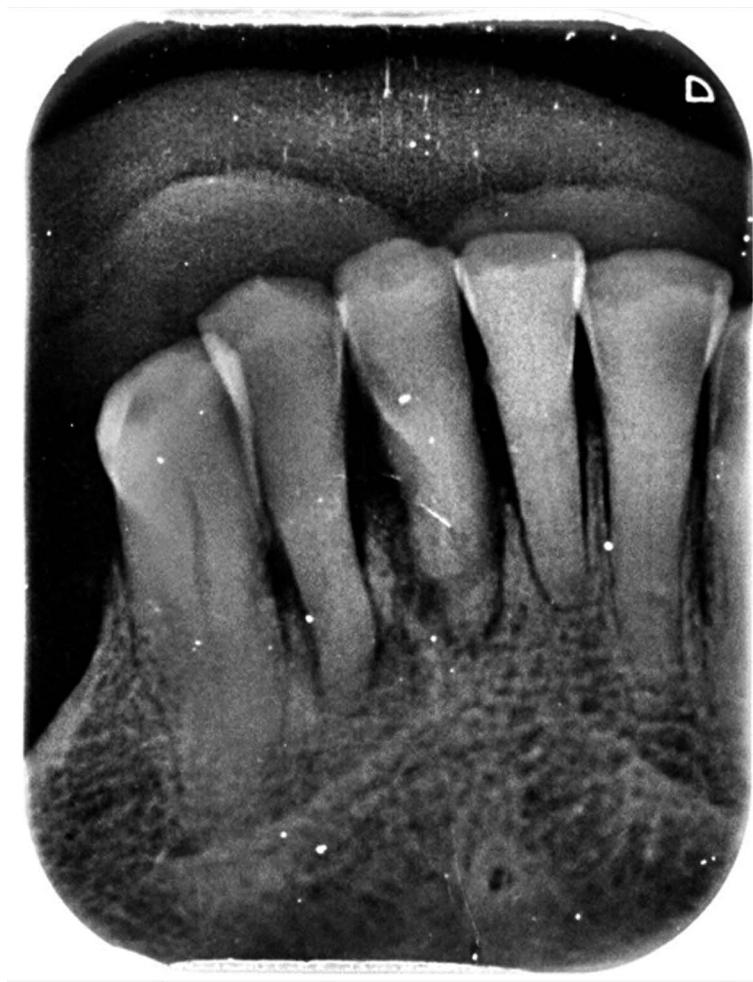


Figure 3. Periapical radiograph showing radiolucent areas with loss of cortical bone continuity

Given the clinical and radiological aspects, differential diagnoses were central giant cell granuloma, peripheral giant cell granuloma, an infectious proliferative process caused by human papillomavirus (HPV), and SCC. Laboratory tests were performed previous surgical excision for diagnostic purposes (platelet count: 510000/cm, partial thromboplastin time: 28.8 sec – control: 27.3 sec). Excision was done through curettage and extraction of central and lateral lower incisors was performed, teeth #41-42 (figure 4-5).

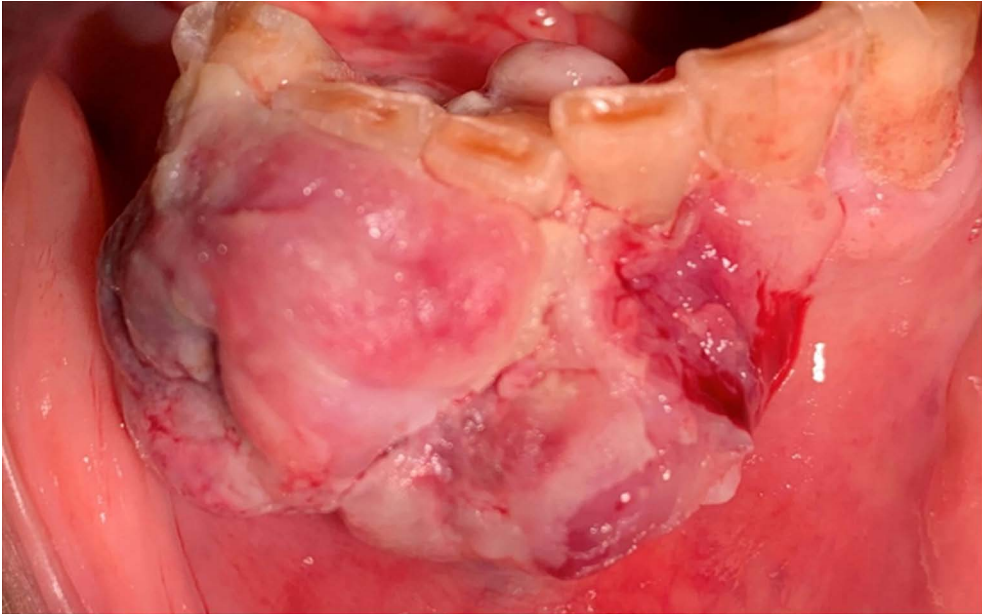


Figure 4. Partial lesion removal using a scalpel to observe bleeding reaction

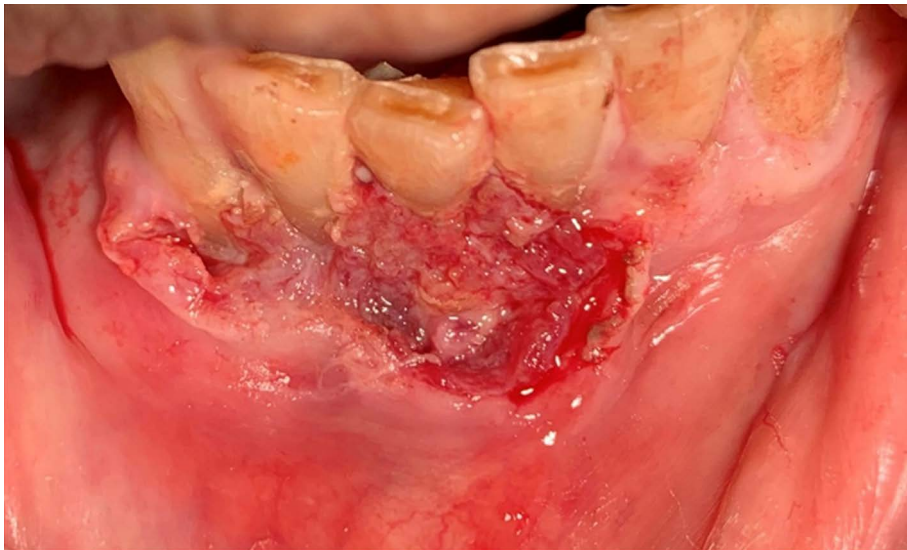

Figure 5. Bleeding reaction from lesion did not represent a risk.

During tissue removal, purulent material appeared due to presence of an acute abscess (figure 6).

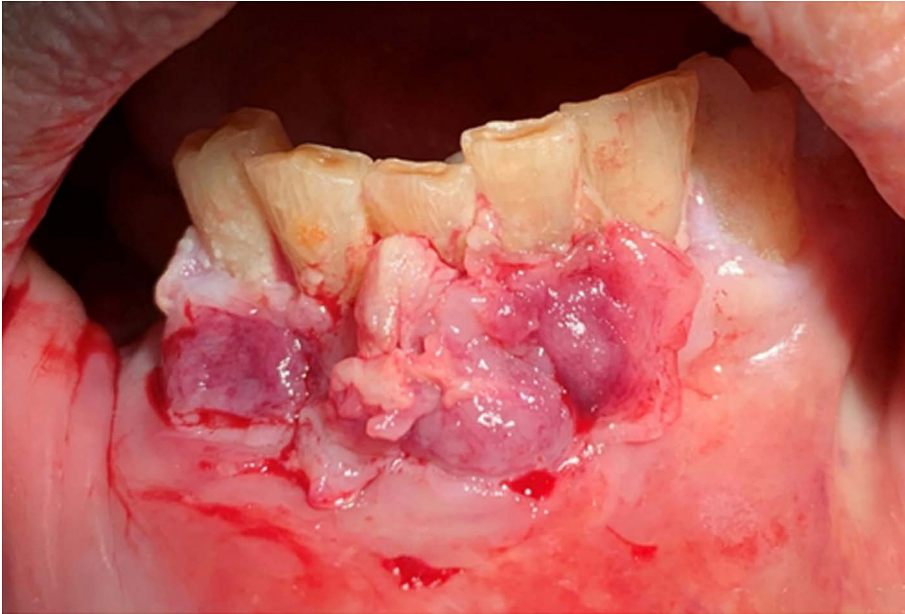


Figure 6. Purulent material appeared during tissue removal.

After removing all affected tissue, treated area was electrocoagulated and sutured (Figure 7).

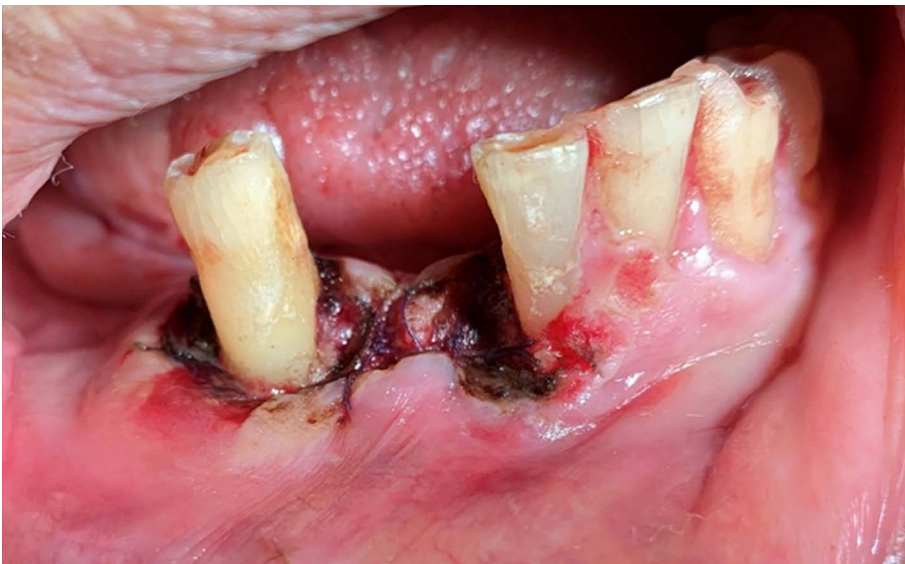

Figure 7. Electrocoagulation and suture of surgical area.

24 hours after surgical excision was performed, patient presented a severe case of dyspnea, she attended emergency services from a local hospital where admitted. Signs and symptoms included cyanosis, severe dyspnea, adynamia, chest pain, and high heart rate. An electrocardiogram revealed cardiac arrhythmia and chest radiography showed pulmonary atelectasis (left lung) due to a bronchial obstruction originated by a tumor. X-Ray revealed right lung metastasis as well (Figure 8).

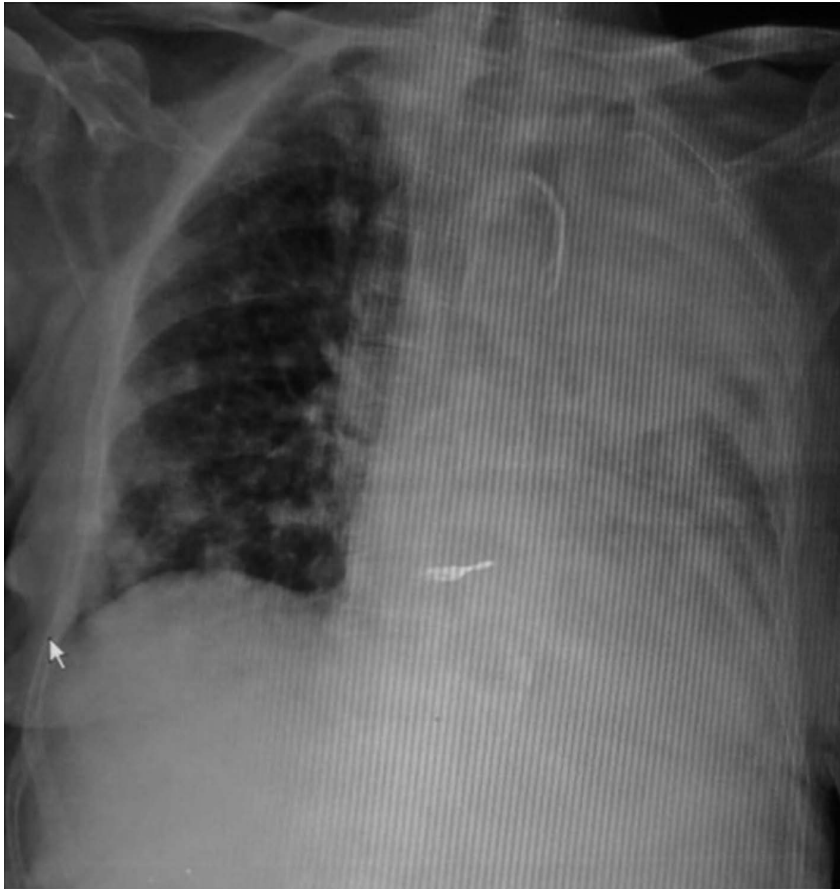

Figure 8. Chest X-Ray showed atelectasis of left lung originated by a bronchial obstruction, as well as right lung metastasis

The patient died after three days of hospitalization. Histopathological analysis of biopsy specimen revealed a malignant neoplasm of epithelial origin, characterized by invasive proliferation of nests and cords constituted by neoplastic epithelial cells, these cells exhibited cellular and nuclear pleomorphism, nuclear hyperchromatism, loss of intercellular cohesion, multiple and clearly visible nucleoli, individual cell keratinization and atypical mitoses (figure 9).

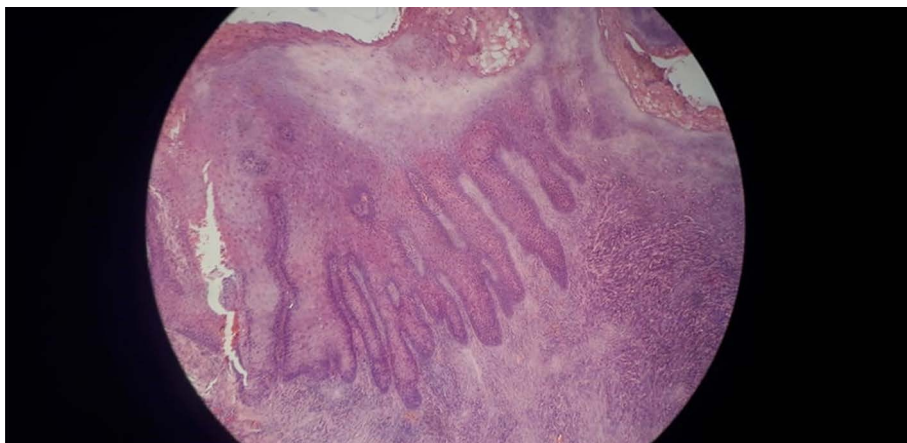


Figure 9. Observed pseudoepitheliomatous hyperplasia and alteration of keratinized sections (10x).

Numerous blood vessels, hemorrhage zones, edema, as well as an intense and diffuse mononuclear inflammatory infiltrate were observed in fibrous connective tissue stroma. Epithelial lining of oral mucosa exhibited a hyperparakeratinized-stratified pattern, showing hyperplasia, exocytosis and hydropic degeneration. Previously referred characteristics led us to finally diagnose a gingival squamous-cell carcinoma poorly differentiated (figures 10-11).

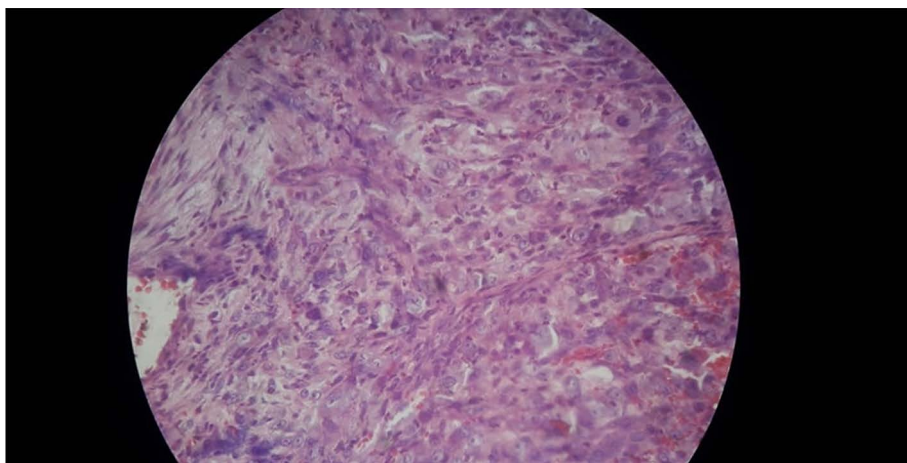


Figure 10. Stroma invaded by epithelioid cells showing hyperchromatism, pleomorphism, and dischesivity (40x).

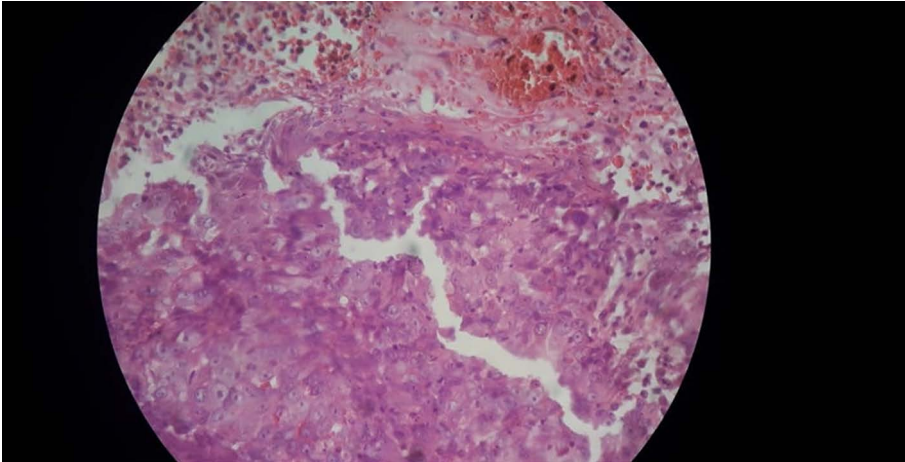


Figure 11. Epithelial cells invading connective tissue, which is shown hyperchromatic. Presence of hemorrhages (40x).

Discussion

Oral cancer is the most frequent mouth malignant neoplasm. It represents 96% of all malignant tumors in this location, and approximately 3% of all malignancies in men and 2% in women [18-20]. However, difference in male:female ratio has been decreasing over the past half-century, probably because women are now exposing themselves more to some known oral carcinogens such as tobacco and alcohol [21]. In some regions of South America, in the Caribbean, inverted smokers have a higher prevalence of oral cancer in women than they do in men [22]. Tobacco use is recognized as main factor for developing oral cancer and mixing it with alcohol consumption increases possibility of acquiring said disease. Besides, alcohol consumption it is shown to be associated with oral and pharyngeal cancer, even in non-smoker's patients [23]. Presence of mouth malignancies have been linked to other factors such as HPV, which is normally related to cancer in young patients that not necessarily consume the previously referred factors (tobacco and alcohol) [24,25].

Gingival squamous-cell carcinoma, which develops from oral mucosal epithelial lining, accounts for over 90% of these tumors, second-most commonplace of appearance is mandibular gingiva. Several studies have also found that periodontal disease may increase risk of developing oral cancer [26]. Ye et al. [27] studied correlation between periodontal disease and of risk oral cancer, pooled results showed that there is a significant correlation between periodontal disease and oral cancer risk with OR = 3.21 and the 95% CI = 2.25–4.16 ($P < 0.05$), indicating that periodontal disease can increase oral cancer development risk almost by twice. Yao et al [28] published a

meta-analysis, evaluating association of periodontal disease with oral cancer risk, five studies were eligible, and authors found a significant association between compared pathologies, OR = 3.53, 95 % CI (1.52-8.23); patients diagnosed with periodontal disease have an increased susceptibility to acquiring oral cancer.

Gingival carcinoma is not aggressive, and survival rate is better, compared to other scc originated from different locations. Prognostic depends mostly on lymph node pathological metastasis, perineural invasion, and extracapsular spread [29]. In this report, patient had a history of occasional cigarette smoking during her youth and denied alcohol consumption; she was a passive smoker for more than 30 years, presented dyspnea episodes, constant cough, and respiratory alterations without a medical diagnosis. She attended our service showing unusual gingival growth, which represented a difficulty for her to eat and correctly perform oral hygiene. First reported symptoms suggested a periodontal disorder.

A possibility to consider is that this gingival tumor was concomitant with an undiagnosed malignant pulmonary neoplasm, considered chest x-ray and its findings as well as symptomatology that led our patient to hospital emergency services and that ultimately caused her death. According to Cabral et al. [30] chance of recovery is favorable when lesion size is less than 1 cm, our patient showed a bigger lesion, and her general health condition helped to conclude with a poor prognostic.

Conclusions

Gingival squamous-cell carcinoma is a condition that presents a higher chance of improvement when carcinomatous lesions are diagnosed and treated early. In late stages, presence of nodules, metastasis, and invasion of adjacent structures worsen prognosis.

Acknowledgments

To our dear patient who allowed us to learn from her case. R.I.P

Conflict de interests

Authors do not report any conflict of interest.

References

1. Sankaranarayanan R, Ramadas K, Amarasinghe H, Subramanian S, Johnson N. Oral Cancer: Prevention, early detection, and treatment. In: Gelband H, Jha P, Sankaranarayanan R, Ramadas K, Amarasinghe H, Subramanian S, Johnson N. *Cancer: Disease Control Priorities*, 3rd ed. Washington (DC): The International Bank for Reconstruction and Development / The World Bank; 2015. <https://bit.ly/3FgXrmH>
2. Chinn SB, Myers JN. Oral Cavity Carcinoma: Current Management, Controversies, and Future Directions. *J Clin Oncol*. 2015;33(29):3269–3276. <https://doi.org/10.1200/JCO.2015.61.2929>
3. Cabral LA, de Carvalho LF, Salgado JA, Brandão AA, Almeida JD. Gingival squamous cell carcinoma: a case report. *J Oral Maxillofac Res*. 2010;1(3):e6. <https://doi.org/10.5037/jomr.2010.1306>
4. Yoon TY, Bhattacharyya I, Katz J, Towle HJ, Islam MN. Squamous cell carcinoma of the gingiva presenting as localized periodontal disease. *Quintessence Int* 2007;38:97-102.
5. Seoane J, Varela-Centelles PI, Walsh TF, Lopez-Cedrun JL, Vazquez I. Gingival squamous cell carcinoma: Diagnostic delay or rapid invasion? *J Periodontol* 2006;77:1229-33.
6. Kumar M, Nanavati R, Modi TG, Dobariya C. Oral cancer: Etiology and risk factors: A review. *J Can Res Ther* 2016;12:458-63.
7. Boscolo-Rizzo P, Del Mistro A, Bussu F, Lupato V, Baboci L, Almadori G, DA Mosto MC, Paludetti G. New insights into human papillomavirus-associated head and neck squamous cell carcinoma. *Acta Otorhinolaryngol Ital*. 2013 Apr; 33(2): 77-87.
8. González M, Motta LA, Moreno A, Chala AI, Tupaz HA, García DA. La infección por virus del papiloma humano afecta el pronóstico del cáncer orofaríngeo escamocelular. Revisión de la literatura. *UnivOdontol*. 2014 Jul-Dic; 33(71): 55-63.
9. Martínez-Martínez A, Lujan-Pardo MP, López-Aparicio E. High risk serotypes of the human papillomavirus (HPV) in patients with exofitic lesions in the oral cavity. *Salud, Barranquilla* [online]. 2018, vol.34, n.2 [cited 2019-05-28], pp.420-429. <https://www.scielo.org.co/pdf/sun/v34n2/2011-7531-sun-34-02-420.pdf>
10. Neville BW, Day TA. Oral Cancer and Precancerous Lesions. *CA Cancer J Clin* 2002;52:195-215.
11. Bharanidharan R, Dineshkumar T, Raghavendhar K, Kumar AR. Squamous cell carcinoma of the gingiva: A diagnostic enigma. *J Oral Maxillofac Pathol* 2015;19:267.

12. Lubek J, El-Hakim M, Salama AR, Liu X, Ord RA. Gingival carcinoma: retrospective analysis of 72 patients and indications for elective neck dissection. *Br J Oral Maxillofac Surg.* 2011;49(3):182-185.
13. Martinez C, Hernandez M, Martinez B, Adorno D. Frequency of oral squamous cell carcinoma and oral epithelial dysplasia in oral and oropharyngeal mucosa in Chile. *Rev. Méd. Chile* 2016;144(2):169-174.
14. Lee KC, Chuang SK, Philipone EM, Peters SM. Which Clinicopathologic Factors Affect the Prognosis of Gingival Squamous Cell Carcinoma: A Population Analysis of 4,345 Cases. *Int J Oral Maxillofac Surg.* 2017; 46(2): 137-143.
15. Niu LX, Prognostic factors in mandibular gingival squamous cell carcinoma: A 10-year retrospective study. *Int J Oral Maxillofac Surg.* 2017; 46(2):137 – 143. <https://doi.org/10.1016/j.ijom.2016.09.014>
16. Niu, LX, Yuan Y, Peng X, Guo CB. Risk factors and treatment of contralateral neck recurrence for unilateral oral squamous cell carcinoma: a retrospective study of 1482 cases. *Oral Oncol.* 2014; 50:1081–1088. <https://doi.org/10.1016/j.oraloncology.2014.08.003>
17. Feng Z, Li JN, Niu LX, Guo CB. Supraomohyoid neck dissection in the management of oral squamous cell carcinoma: special consideration for skip metastases at level IV or V. *J Oral Maxillofac Surg.* 2014;72:1203–1211. <https://doi.org/10.1016/j.joms.2013.12.008>
18. Kumar M, Nanavati R, Modi TG, Dobariya C. Oral cancer: Etiology and risk factors: A review. *J Can Res Ther* 2016;12:458-63.
19. Rivera C. Essentials of oral cancer. *Int J Clin Exp Pathol.* 2015;8(9):11884–11894.
20. Conway DI, Purkayastha M, Chestnutt IG. The changing epidemiology of oral cancer: definitions, trends, and risk factors. *Br Dent J.* 2018 Nov 9;225(9):867-873. <https://doi.org/10.1038/sj.bdj.2018.922>
21. Neville BW, Day TA. Oral Cancer and Precancerous Lesions. *CA Cancer J Clin* 2002;52:195-215.
22. Martinez AA, Carmona MC, Diaz A. Behavior of oral cancer at a hospital in Cartagena de indias, Colombia. *Rev Cubana Estomatol.* 2016;53(2):24-28.
23. Saman DM. A review of the epidemiology of oral and pharyngeal carcinoma: update. *Head Neck Oncol.* 2012 Jan 13;4:1. <https://doi.org/10.1186/1758-3284-4-1>

24. Hübbers CU, Akgül B. HPV and cancer of the oral cavity. *Virulence*;6(3):244–248. <https://doi.org/10.1080/21505594.2014.9995700>
25. Martínez Martínez A, Baldiris Ávila R, Díaz Caballero A. Human papillomavirus infection. Relationship with oral squamous cancer, several techniques for detecting its presence. *Av. Odontoestomatol* 2014;30 (2): 69-78. <https://scielo.isciii.es/pdf/odonto/v30n2/original2.pdf>
26. Guha N, Boffetta P, Wünsch Filho V, Eluf Neto J, Shangina O, Zaridze D, et al. Oral health and risk of squamous cell carcinoma of the head and neck and esophagus: Results of two multi-centric case-control studies. *Am J Epidemiol* 2007;166:1159-73
27. Ye L, Jiang Y, Liu W, Tao H. Correlation between periodontal disease and oral cancer risk: A meta-analysis. *J Can Res Ther* 2016;12:C237-40.
28. Yao QW, Zhou DS, Peng HJ, Ji P, Liu DS. Association of periodontal disease with oral cancer: a meta-analysis. *Tumour Biol*. 2014 Jul;35(7):7073-7. <https://doi.org/10.1007/s13277-014-1951-8>
29. Niu LX, Feng ZE, Wang DC, Zhang JY, Sun ZP, Guo CB. Prognostic factors in mandibular gingival squamous cell carcinoma: A 10-year retrospective study *Int J Oral Maxillofac Surg*, 2017 Feb;46(2):137 – 143.
30. Cabral LA, de Carvalho LF, Salgado JA, Brandão AA, Almeida JD. Gingival squamous cell carcinoma: a case report. *J Oral Maxillofac Res*. 2010;1(3):e6. 2010. <https://doi.org/10.5037/jomr.2010.1306>