

Ukr Neurosurg J. 2023;29(1):30-37
doi: 10.25305/unj.268336

Paradigm shift in vertebral eosinophilic granuloma

Muhammet Arif Ozbek, Veyselkarani Ipek, Cem Dinc

Department of Neurosurgery,
Istanbul Medipol University, Istanbul,
Turkey

Received: 05 December 2022

Accepted: 20 February 2023

Address for correspondence:

Muhammet Arif Ozbek, Department
of Neurosurgery, Istanbul Medipol
University, TEM Avrupa Otoyolu
Göztepe Çıkışı No: 1, 34214 Bağcılar,
İstanbul, e-mail: m_a_ozbek@yahoo.
com

Objective: Eosinophilic granuloma is the most common type of Langerhans cell histiocytosis. Vertebral bone involvement of eosinophilic granuloma is a rare disease. There are few studies in the literature on patients with vertebral bone involvement diagnosed with eosinophilic granuloma. There is still no clear protocol for the treatment of patients with vertebral involvement with eosinophilic granuloma. This article is a summary of the clinical follow-ups of our 6 cases diagnosed with spinal eosinophilic granuloma. We changed the chemotherapy protocol or extended the duration of chemotherapy in patients with progressive disease.

Methods: In this study, there are six patients (4 male and 2 female) with vertebral involvement of eosinophilic granuloma in our hospital between September 2017 and August 2022. The clinical findings, radiological images, treatments and follow-up results of the patients were analyzed retrospectively.

Results: In the follow-ups, a new vertebral bone involvement was observed in two patients and a femoral bone involvement was observed in another patient. One patient with neurological deficit underwent surgical treatment. Chemotherapy treatment was given to four patients with multiple bone involvement or recurrence. No recurrence was observed in three patients who started chemotherapy treatment after recurrence.

Conclusions: Surgical treatment should be considered in patients with neurological deficits and spinal instability. According to the results of our study, patients with multiple bone or systemic involvement and no neurological deficit should receive chemotherapy treatment. We recommend changing the chemotherapy protocol or extending the chemotherapy duration in patients with progressive disease.

Keywords: eosinophilic granuloma; spine; treatment

Introduction

Eosinophilic granuloma is the most common type of Langerhans cell histiocytosis. In 1953, Lichtenstein classified eosinophilic granuloma as a subgroup of the histiocytosis X disorder, which expresses the proliferation of histiocytes [1]. Eosinophilic granuloma usually affects the skeletal system. It causes osteolytic lesions in bones [2].

Langerhans cells located in the Malpighi layer of the skin are derived from dendritic progenitor cells. Langerhans cells can migrate from the bone marrow to tissues and present antigens to T lymphocyte cells. Viral factors such as EBV and HHV-6, bacterial factors and cytokines such as IL-1 and 10 can increase the proliferation of Langerhans cells [3].

The most common age group for eosinophilic granuloma is 5 to 10 years [4]. Eosinophilic granuloma is more common in men (men/women: 1.2/1) [2]. It is seen mostly in cranial bones, but vertebral bone involvement is less common.

Eosinophilic granuloma usually involves the vertebral bones, skull, long bones, pelvis, and mandible. The most commonly involved bones in adults and children are often different from each other. Thoracic vertebral bones

are more frequently involved in children, while cervical vertebral bones are more frequently involved in adults [5]. Less frequently, other organs may be affected in eosinophilic granuloma (lung, skin, pituitary gland, brain, gastrointestinal tract, etc.) [6].

Objective: Treatment parameters in eosinophilic granuloma are constantly changing. This article is a summary of the clinical follow-ups of our 6 cases diagnosed with spinal eosinophilic granuloma, for which the most current treatments were applied. We started chemotherapy treatment for patients with multiple bone involvement and no neurological deficit. We changed the chemotherapy protocol or extended the duration of chemotherapy in patients with progressive disease.

Materials and methods

Between September 2017 and August 2022, 6 patients (4 males, 2 females) diagnosed with eosinophilic granuloma and having vertebral bone involvement were followed up in our hospital (**Table 1**).

The clinical findings, radiological imaging (CT, MRI, PET-CT, skeletal surveys, technetium bone scans, etc.), histopathology analysis of biopsy, treatment methods



Table 1. Clinical information of 6 patients with vertebral involvement diagnosed with eosinophilic granuloma

Case	Sex	Age	Involved vertebra	Other skeletal lesions	Surgery	Biopsy	Chemotherapy	Radiotherapy	Evolution	Follow-up, year
1	F	38	C5, T7	No	Anterior approach	No	Yes	No	No recurrence	1
2	F	9	T1, T12	No	No	Spine (needle)	Yes	No	Recurrence, L3 vertebra	4
3	M	47	S1	Femur	No	Spine (needle)	Yes	No	Recurrence, femur bone	4
4	M	23	L3	No	No	Spine (needle)	No	No	No recurrence	4
5	M	41	T6	No	No	Spine (needle)	No	No	No recurrence	5
6	M	28	C4	No	No	Spine (needle)	Yes	No	Recurrence, L2 vertebra	3

and clinical course of the patients were analyzed retrospectively. In our study, we examined 4 male and 2 female patients. The ages of these patients ranged from 9 to 47 years. Their mean age was 30.3. The patients were followed for an average of 4 years after diagnosis.

Results

Clinical presentation

Patients with high-risk factors such as multiple bone involvement, multisystem involvement and skull base bone involvement have a higher risk of recurrence and worse prognosis [7]. In patients with eosinophilic granuloma, the clinical course varies according to the location of the tumor. The most common symptom in these patients was pain. Common clinical findings are pain, neurologic deficit and kyphosis. In our study, there was a patient with deficits in left arm abduction strength and left biceps muscle strength. There was one patient with a history of trauma.

Radiographic presentation

It is characteristic of spinal eosinophilic granuloma to see osteolytic vertebral lesions on radiological imaging. The plain radiograph is the first and simplest imaging to show osteolytic lesions. CT and MRI should be performed as further examinations. CT scans show osteolytic lesions and decreased height of the vertebral body. On MRI, lesions give iso or low-intensity signals on T1-weighted images and high-intensity signals on T2-weighted images (Figure 1, 2). Technetium bone scans and PET/CT should be performed in patients with multiple bone involvement or multisystem involvement. PET/CT imaging was performed in four patients with multiple bone involvement or recurrence to see if there was any other involvement.

Distribution

Six patients had eight vertebral lesions scattered throughout the spinal column. Initially, four patients

had solitary spinal lesions, one patient had T1 and T12 involvement, and the other had C5 and T7 involvement. During follow-up, one patient had involvement of the femur in addition to the spine, and two patients had vertebra bone involvement.

Biopsy

The biopsy is important in making a pathological diagnosis. Pathological diagnosis was made in five patients in our study by taking a specimen from the solitary lesion with a CT-guided needle biopsy. One patient with a biopsy specimen taken during the operation made a pathological diagnosis. In patients with multifocal lesions, specimens were taken from the location with the most common involvement.

Treatment

The purpose of treatment in eosinophilic granuloma is to relieve pain and preserve neurological function and spinal stability. The first treatment applied to patients with eosinophilic granuloma of vertebral bone involvement is immobilization. Long-term immobilization was applied to five patients without neurological deficits. One patient with neurological deficit underwent surgical treatment. A anterior approach was applied to a patient with vertebral bone involvement and spinal stability was restored with internal fixation (Figure 3). Chemotherapy treatment was given to four patients with multiple bone involvement or recurrence. In only one of these patients, the disease relapsed seven months after chemotherapy treatment ended. A pediatric patient with multiple vertebral bone involvement was treated with vinblastine for a year. Seven months later, the disease relapsed. Therefore, the patient was treated with vinblastine and cytosine arabinoside combined chemotherapy for six months. One of our patients was treated with vinblastine and prednisolone for six months. In one patient, we gave five cycles of treatment with cytosine arabinoside treatment in the first five days of the 28-day period. We gave another patient a

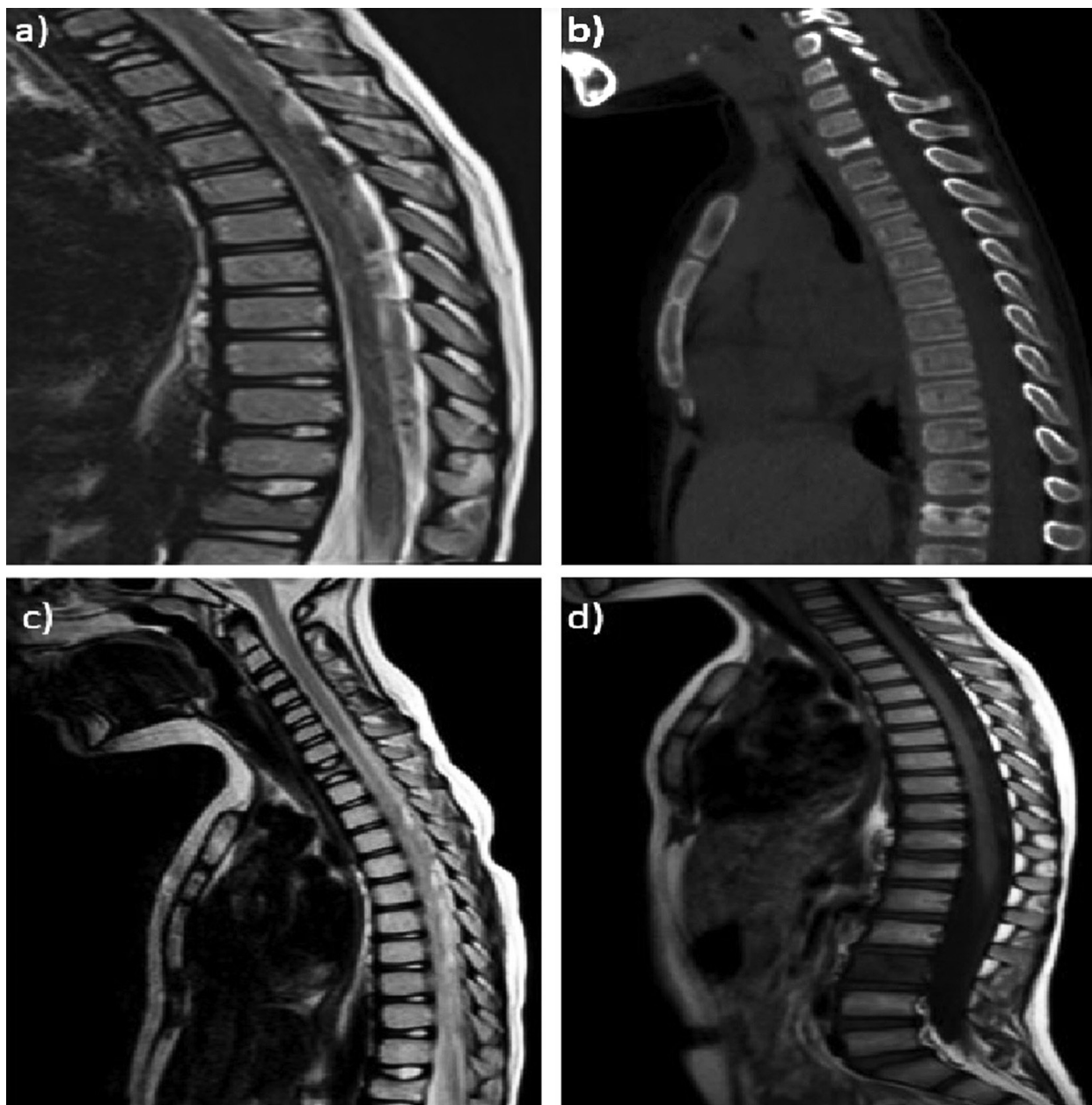


Figure 1. Radiological imaging of a 9-year-old female patient with T1 and T12 vertebral bone involvement **a,b)** MRI and CT were taken when the patient presented with back pain. There is height loss in the T1 and T12 vertebral bodies. **c)** T2 sequence of MRI of the patient was taken three months after chemotherapy treatment started. **d)** MRI of the patient was taken 18 months after the start of chemotherapy treatment, there is a hypointense signal in the L3 vertebra in the sagittal T1 sequence. It was considered a recurrence.

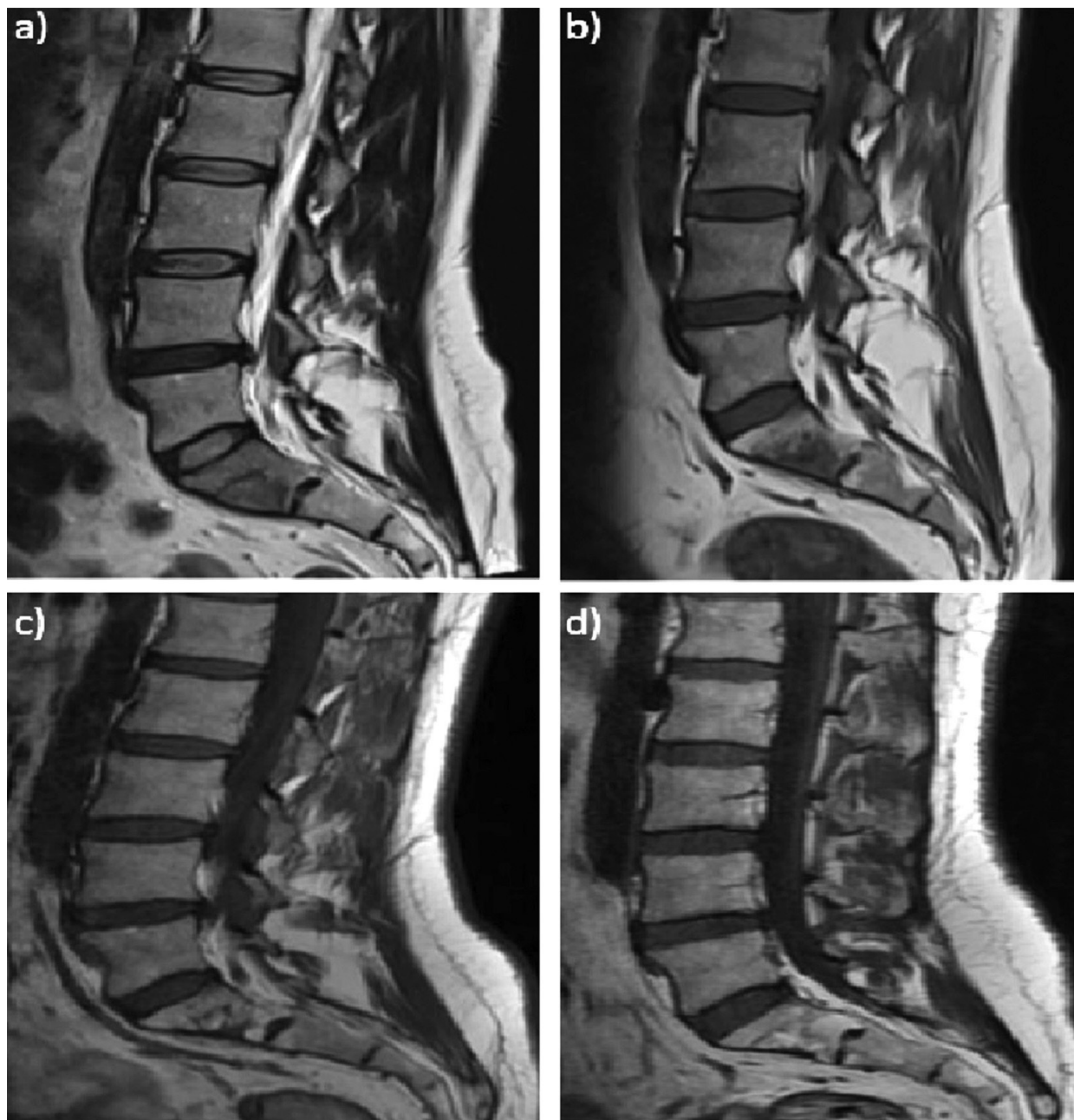

Figure 2. Radiological imaging of a 47-year-old male patient with S1 vertebral bone involvement **a)** MRI was taken after the patient had low back pain, hypointense signal was present in the S1 vertebra in the sagittal T1 sequence. **b, c, d)** Sagittal T1 sequence of the patient's control MRI was taken six months, one year, and two years later.

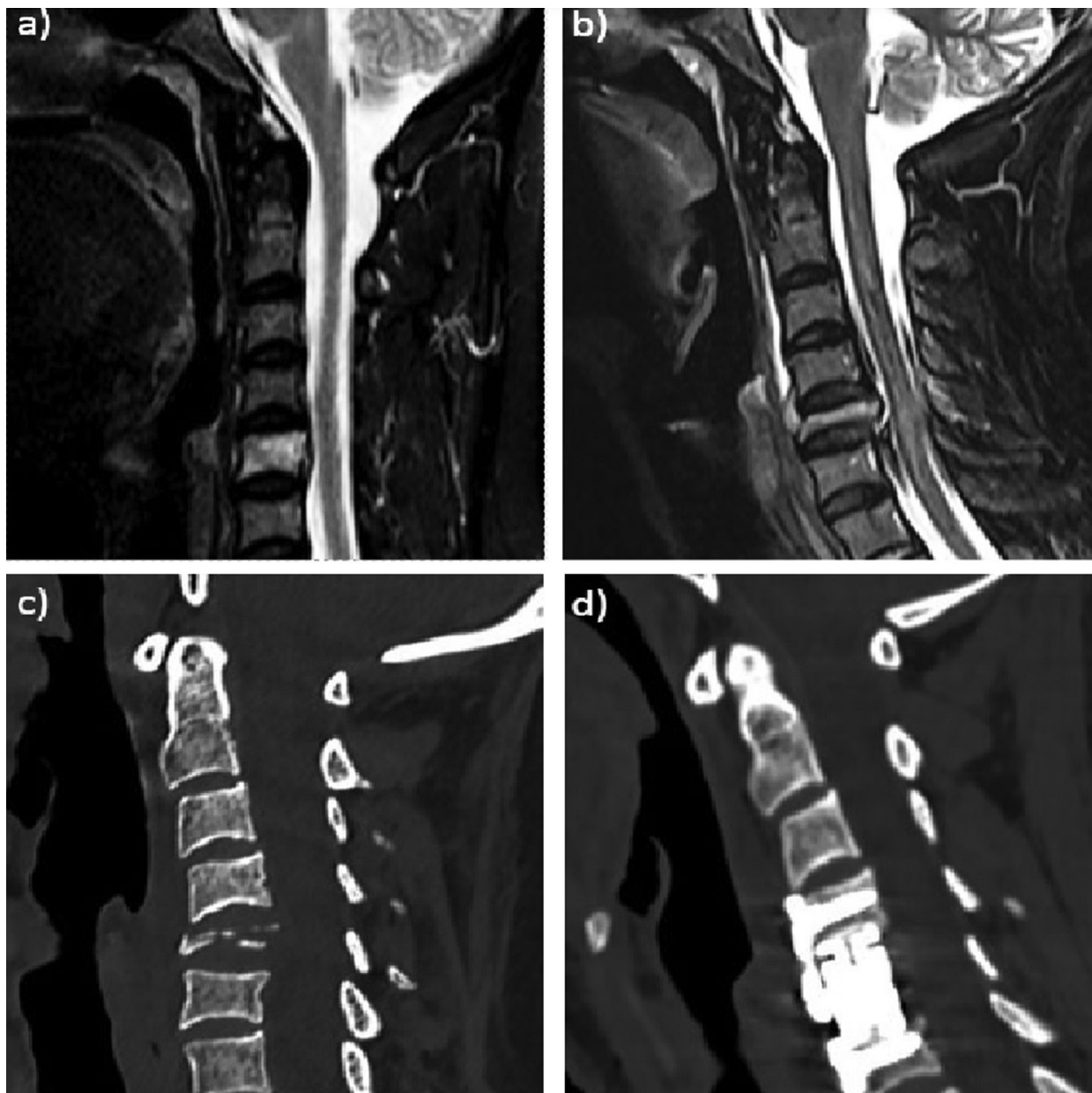


Figure 3. Radiological imaging of a 37-year-old female patient with C5 and T7 vertebral bone involvement **a)** MRI was taken when the patient presented with neck pain. There is height loss in the C5 vertebral body and edematous appearance in PLL. **b,c)** MRI and CT took after the patient complained of pain and weakness in the left arm two weeks later. There is a height loss of more than 75% in the C5 vertebra and mild narrowing of the spinal canal. **d)** CT of the patient after C5 vertebra central and left partial corpectomy and anterior plate application with C4 and C6 corpal screws.

one-cycle treatment with cytosine arabinoside treatment in the first five days of the 28-day period. It is planned to complete six or twelve cycles of treatment. There was no recurrence of the patients in the follow-ups.

Clinical follow-up

The patients were followed for an average of 4 years after diagnosis. There was a recurrence in three patients during the clinical follow-up period. Two of these patients initially had a single bone lesion. Therefore, chemotherapy treatment was not initiated for them. In only one of these patients, the disease relapsed seven months after chemotherapy treatment ended. Two patients had a recurrence of vertebra bone and one patient had a recurrence of the femur bone. Curettage and chemotherapy treatment was applied to a patient who had a recurrence of the femur bone two years after the diagnosis of eosinophilic granuloma. No recurrence was observed in these three patients after chemotherapy treatment was started.

Discussion

Eosinophilic granuloma is more common in childhood [8]. In our case series, only one of the six patients was a pediatric patient, while the others were adult patients. Eosinophilic granuloma is more common in men (men/women: 1.2/1) [2]. However, the ratio in our series is 2:1. In our study, we cannot conclude whether this ratio is significant or not.

Since there is not enough information about the etiology and natural course of eosinophilic granuloma, there is no consensus treatment algorithm in the literature. Patients with a single bone lesion and without multisystem involvement have a good prognosis and the disease may regress spontaneously in these patients. Patients with a single lesion, no motor deficit, and spinal stability should be treated conservatively. Immobilization is recommended for these patients and non-steroidal analgesic therapy is given if they have pain. Some authors have used a neck collar or spinal brace to treat patients with vertebral bone involvement. They noticed a significant recovery of collapsed vertebral height in the patients.

Surgical treatment is applied in patients with neurological deficits and spinal instability. The aim of the surgery is to improve neurological dysfunction and shorten the treatment period. Surgical treatment relieves pain faster than non-surgical treatment [10]. Surgical treatment varies according to the location and extent of the lesion. Surgical treatment may include gross total resection, internal fixation, and bone grafting. In adults, unlike children, the disease may progress more aggressively as the growth of the epiphysis stops [11]. Therefore, some authors advocated the application of more aggressive treatment methods in adults [12, 13, 14]. In the study of Wending et al. involving 30 patients, surgical treatment was applied to 28 patients [12]. In the study of Zhong et al., which included 19 patients, surgical treatment was applied to all patients [13]. In another study, Floman et al. 7 of 20 patients underwent surgical treatment [14]. In our study, one of the six patients had a neurological deficit and surgical treatment was applied to this patient, while the remaining five patients were treated conservatively. When we look at the clinical

course of the patients, it was seen that the indication for surgical treatment was limited and a significant portion of the patients benefited from conservative treatment and new chemotherapy treatment plan without surgical treatment.

It has been argued by some authors that low-dose radiotherapy treatment is effective in healing lytic bone lesions and limiting disease progression [12, 15]. Some authors have argued that low-dose radiotherapy treatment may damage endochondral growth plates and limit bone healing or lead to secondary radiation-induced morbidities such as post-radiation sarcomas and myelitis [16, 17, 18]. Because of these side effects, radiotherapy treatment was not applied to any patient in our case series. There is no definitive study in the literature that low-dose radiotherapy treatment increases survival. We recommend changing the chemotherapy protocol or extending the chemotherapy period instead of using low-dose radiotherapy in patients with progressive disease.

Chemotherapy treatment is used in patients with multiple bones or multiple system involvement [19, 20]. In eosinophilic granuloma, treatment with corticosteroid injections into the affected area is recommended [21, 22]. In chemotherapy treatment, vinca alkaloids, antimetabolites, and antifolates are preferred because they have less toxicity and mutagenicity. Other cytotoxic agents such as cyclophosphamide, cytosine arabinoside, doxorubicin, carboplatin and a newer agent 2-chlorodeoxyadenosine (2CdA) are used in patients who are resistant to treatment [23]. In the study of Greenlee et al., four patients with multiple lesions were treated with vinblastine for one year. In one patient, 6-mercaptopurine, methotrexate and prednisone treatment was given for one year after the disease relapsed. In this case, the recurrence rate was 25% in patients who received chemotherapy treatment [19]. In the study of Egeler et al., 18 patients with multiple lesions were given chemotherapy treatment containing cytosine-arabinoside, vincristine and prednisolone. Remission was achieved in 13 of 18 patients. Recurrence was seen in three patients. Two patients died due to organ failure. The recurrence rate in this case series is 16.66%. In this study, chemotherapy was given between 6 and 16 weeks [20]. In our case series, we applied cytosine arabinoside treatment to three patients who were resistant to treatment. In our series, four patients with multiple bone involvement received chemotherapy and corticosteroid treatment, and only one of these four patients relapsed seven months after the treatment was stopped. We expanded the chemotherapy treatment for the patient with relapse. We gave vinblastine and cytosine arabinoside treatment for six months. There was no recurrence in the follow-up of the patient after the treatment. In our series, the recurrence rate was 25%. However, we achieved complete remission during follow-up in patients who were administered cytosine arabinoside or a combination of vinblastine and cytosine arabinoside according to the most current chemotherapy protocol. We recommend that patients with multiple bone involvement and no neurological deficit receive chemotherapy treatment. We recommend changing the chemotherapy protocol or extending the chemotherapy duration in patients with progressive disease.

Proposed treatment protocol

We suggest that the above-mentioned conservative treatments should be the first choice for patients with solitary lesions and no neurological deficits. Immobilization is recommended in these patients and non-steroidal analgesic therapy is given if necessary. Frequent clinical follow-up is mandatory as recurrence may occur in patients receiving conservative treatment. If the patient develops a neurological deficit, timely surgical treatment should be applied. Chemotherapy treatment is recommended primarily in patients with multifocal involvement and without neurological deficit. If the patient has relapsed, chemotherapy treatment should be started. We recommend changing the chemotherapy protocol or extending the chemotherapy duration in patients with progressive disease.

Limitation

Since spinal eosinophilic granuloma is rare and our study was retrospective, we were limited to six cases. Better results can be obtained prospectively with larger series. Our work towards this continues.

Conclusions

The eosinophilic granuloma may show a single bone involvement, multiple bone involvement, or multiple system involvement. Since eosinophilic granuloma is multisystem involvement, support from many departments (neurosurgeon, hematology-oncologist, pulmonologist, ophthalmologist, otolaryngologist, etc.) is required for treatment and clinical follow-up. Eosinophilic granuloma is benign and generally has a good prognosis. However, since recurrence is common, it requires close follow-up. A neurological deficit may occur as a result of compression on the spinal canal due to vertebral bone lesions in patients. Surgical treatment should be considered in patients with neurological deficits and spinal instability. Chemotherapy treatment should be applied in patients with multiple vertebral bone involvement or recurrence. We recommend changing the chemotherapy protocol or extending the chemotherapy duration in patients with progressive disease.

Disclosure

Conflict of interest

The authors declare no conflict of interest.

Funding

The study was conducted without sponsorship.

Conflict of interest

All authors certify that they have no affiliations with or involvement in any organization or entity with any financial interest or non-financial interest in the subject matter or materials discussed in this manuscript.

Informed consent

The written informed consent was obtained from each patient or appropriate family member before the surgery.

Funding

No funding was received to assist with the preparation of this manuscript

References

1. Lichtenstein L. Histiocytosis X; integration of eosinophilic granuloma of bone, Letterer-Siwe disease, and Schüller-Christian disease as related manifestations of a single nosologic entity. *AMA Arch Pathol.* 1953 Jul;56(1):84-102.
2. Brown CW, Jarvis JG, Letts M, Carpenter B. Treatment and outcome of vertebral Langerhans cell histiocytosis at the Children's Hospital of Eastern Ontario. *Can J Surg.* 2005 Jun;48(3):230-6.
3. Chadha M, Agarwal A, Agarwal N, Singh MK. Solitary eosinophilic granuloma of the radius. An unusual differential diagnosis. *Acta Orthop Belg.* 2007 Jun;73(3):413-7.
4. Bertram C, Madert J, Eggers C. Eosinophilic granuloma of the cervical spine. *Spine (Phila Pa 1976).* 2002 Jul 1;27(13):1408-13. doi: 10.1097/00007632-200207010-00007
5. Islinger RB, Kuklo TR, Owens BD, Horan PJ, Choma TJ, Murphey MD, Temple HT. Langerhans' cell histiocytosis in patients older than 21 years. *Clin Orthop Relat Res.* 2000 Oct;(379):231-5. doi: 10.1097/00003086-200010000-00027
6. Cochran LA, Prince M, Clarke K. Langerhans' cell histiocytosis in the paediatric population: presentation and treatment of head and neck manifestations. *J Otolaryngol.* 2003 Feb;32(1):33-7. doi: 10.2310/7070.2003.35266
7. Jha SK, De Jesus O. Eosinophilic Granuloma. 2022 Sep 25. In: StatPearls. Treasure Island (FL): StatPearls Publishing; 2022 Jan.
8. Egeler RM, D'Angio GJ. Langerhans cell histiocytosis. *J Pediatr.* 1995 Jul;127(1):1-11. doi: 10.1016/s0022-3476(95)70248-2
9. Binkovitz LA, Olshefski RS, Adler BH. Coincidence FDG-PET in the evaluation of Langerhans' cell histiocytosis: preliminary findings. *Pediatr Radiol.* 2003 Sep;33(9):598-602. doi: 10.1007/s00247-003-0943-4
10. Zhou Z, Zhang H, Guo C, Yu H, Wang L, Guo Q. Management of eosinophilic granuloma in pediatric patients: surgical intervention and surgery combined with postoperative radiotherapy and/or chemotherapy. *Childs Nerv Syst.* 2017 Apr;33(4):583-593. doi: 10.1007/s00381-017-3363-8
11. Kaste SC, Rodriguez-Galindo C, McCarville ME, Shulkin BL. PET-CT in pediatric Langerhans cell histiocytosis. *Pediatr Radiol.* 2007 Jul;37(7):615-22. doi: 10.1007/s00247-007-0467-4
12. Huang W, Yang X, Cao D, Xiao J, Yang M, Feng D, Huang Q, Wu Z, Zheng W, Jia L, Wu S. Eosinophilic granuloma of spine in adults: a report of 30 cases and outcome. *Acta Neurochir (Wien).* 2010 Jul;152(7):1129-37. doi: 10.1007/s00701-010-0644-3
13. Zhong N, Xu W, Meng T, Yang X, Yan W, Xiao J. The surgical strategy for eosinophilic granuloma of the pediatric cervical spine complicated with neurologic deficit and/or spinal instability. *World J Surg Oncol.* 2016 Dec 7;14(1):301. doi: 10.1186/s12957-016-1063-6
14. Floman Y, Bar-On E, Mosheiff R, Mirovsky Y, Robin GC, Ramu N. Eosinophilic granuloma of the spine. *J Pediatr Orthop B.* 1997 Oct;6(4):260-5. doi: 10.1097/01202412-199710000-00008
15. Garg S, Mehta S, Dormans JP. An atypical presentation of Langerhans cell histiocytosis of the cervical spine in a child. *Spine (Phila Pa 1976).* 2003 Nov 1;28(21):E445-8. doi: 10.1097/01.BRS.0000096462.51682.0F
16. Corby RR, Stacy GS, Peabody TD, Dixon LB. Radiofrequency ablation of solitary eosinophilic granuloma of bone. *AJR Am J Roentgenol.* 2008 Jun;190(6):1492-4. doi: 10.2214/AJR.07.3415
17. Richter MP, D'Angio GJ. The role of radiation therapy in the management of children with histiocytosis X. *Am J Pediatr Hematol Oncol.* 1981 Summer;3(2):161-3. doi: 10.1097/00043426-198100320-00008
18. Sessa S, Sommelet D, Lascombes P, Prévot J. Treatment of Langerhans-cell histiocytosis in children. Experience at the Children's Hospital of Nancy. *J Bone Joint Surg Am.* 1994 Oct;76(10):1513-25. doi: 10.2106/00004623-199410000-00011
19. Greenlee JD, Fenoy AJ, Donovan KA, Menezes AH. Eosinophilic granuloma in the pediatric spine. *Pediatr*

- Neurosurg. 2007;43(4):285-92. doi: 10.1159/000103308
20. Egeler RM, de Kraker J, Voûte PA. Cytosine-arabioside, vincristine, and prednisolone in the treatment of children with disseminated Langerhans cell histiocytosis with organ dysfunction: experience at a single institution. *Med Pediatr Oncol.* 1993;21(4):265-70. doi: 10.1002/mpo.2950210406
21. Capanna R, Springfield DS, Ruggieri P, Biagini R, Picci P, Bacci G, Giunti A, Lorenzi EG, Campanacci M. Direct cortisone injection in eosinophilic granuloma of bone: a preliminary report on 11 patients. *J Pediatr Orthop.* 1985 May-Jun;5(3):339-42. doi: 10.1097/01241398-198505000-00016
22. Egeler RM, Thompson RC Jr, Voûte PA, Nesbit ME Jr. Intralesional infiltration of corticosteroids in localized Langerhans' cell histiocytosis. *J Pediatr Orthop.* 1992 Nov-Dec;12(6):811-4. doi: 10.1097/01241398-199211000-00021
23. Arceci RJ, Brenner MK, Pritchard J. Controversies and new approaches to treatment of Langerhans cell histiocytosis. *Hematol Oncol Clin North Am.* 1998 Apr;12(2):339-57. doi: 10.1016/s0889-8588(05)70514-1