

## Lafora disease in a Chihuahua dog: a case report

Dajana Davitkov<sup>1</sup>, Vladimir Nestic<sup>1</sup>, Darko Marinkovic<sup>2</sup>, Darko Davitkov<sup>3</sup>, Zoran Loncar<sup>4</sup>, Aleksandar Delic<sup>4</sup>, Milan Anicic<sup>2</sup>

<sup>1</sup>University of Belgrade, Faculty of Veterinary Medicine,  
Department of Forensic Veterinary Medicine, Belgrade, Serbia

<sup>2</sup>University of Belgrade, Faculty of Veterinary Medicine,  
Department of Pathology, Belgrade, Serbia

<sup>3</sup>University of Belgrade, Faculty of Veterinary Medicine,  
Department of Equine, Small Animal, Poultry and Wild Animal Diseases, Belgrade, Serbia

<sup>4</sup>Veterinary Clinic Loncar, Belgrade, Serbia

Received January 24, 2023

Accepted October 25, 2023

### Abstract

The aging process is still not fully understood, although it has been studied for centuries. One of the processes in the brain during aging is the accumulation of extracellular and intracellular deposits of amyloid and lipofuscin. Deposits of various polyglucosan bodies (PGBs) are also found in brain tissue. The accumulation of the Lafora bodies (LB), a type of PGBs, can cause the Lafora disease (LD). Initial signs of the disease in humans are tonic-clonic seizures with blindness and myoclonus seizures. Normally, all haematological and biochemical indices are within the reference range in dogs with this disease. In this case, a 7-year-old Chihuahua dog with tonic-clonic seizures was presented. According to history, neurological examination, and blood test, toxic, metabolic, and infectious causes for the seizures were ruled out. The dog was started on phenobarbital 2.5 mg/kg twice daily *per os*. Two years later, the dog died due to complications caused by a duodenal foreign body. Postmortem examination revealed hyperaemic meninges and an enlarged, oedematous brain with flattened gyri and narrowed sulci. Histopathological examination revealed multifocal to diffuse, randomly distributed PGBs that were positive on periodic acid-Schiff (PAS) staining. The diagnosis of LD in dogs is of great importance because they are a good experimental model for neurological studies of neurodegenerative diseases in humans.

*Canine, histopathology, polyglucosan bodies, seizure*

One of the main risks for neurodegenerative diseases in humans and animals is aging (Rai and Ganesh 2019). Lafora disease (LD) is an autosomal recessive disease caused by a mutation in the *EPM2A* gene or NHL repeat containing E3 ubiquitin protein ligase 1 (NHLRC1, also known as *EPM2B*) (von Klopmann et al. 2021). The disease can affect different species, but it is most common in humans and animals (Swain et al. 2017; Alisauskaite et al. 2020). The disease is characterized by an accumulation of polyglucosan bodies (PGBs) in the brain, which was first described by Gonzalo Rodríguez Lafora in a patient with myoclonus epilepsy (Machado-Salas et al. 2012; Nestic et al. 2021). In addition to the abnormal glycogen, accumulation of specific proteins such as laforin, neuronatin, malin, 20 S proteasome, desmin, and concanavalin can also be found (Rao et al. 2010; Sharma et al. 2013; Chambers et al. 2018).

The accumulation of abnormal glycogen is caused by malin dysfunction which promotes laforin degeneration and can lead to neurological disorders and epilepsy in dogs. First signs of the disease appear at approximately 7 years of age (Swain et al. 2017). The most common signs are reflex and spontaneous myoclonus, hypnic myoclonus and generalized tonic clonic seizures (Swain et al. 2017; Alisauskaite et al. 2020). Other clinical signs may include reluctance to move, disorientation and head tremors (Márquez et al. 2010).

#### Address for correspondence:

Dajana Davitkov  
Bul. oslobodjenja 18  
11000 Belgrade, Serbia

Phone: +381 638 389 857  
E-mail: [dajana@vet.bg.ac.rs](mailto:dajana@vet.bg.ac.rs)  
<http://actavet.vfu.cz/>

Several breeds of dogs have been diagnosed with this disease, including the miniature Dachshund, Basset Hound, Beagle, Poodle, Pointer, and Corgi (Schoeman et al. 2002; Lohi et al. 2005; Webb et al. 2009). The most commonly affected breed with an *EPM2B* gene mutation is the miniature Wirehaired Dachshund, thus providing an animal model for this disease (Chambers et al. 2018). The study by Sainsbury (2014) found that nearly half of the dogs studied had at least one copy and about 13% had two copies of the aberrant gene.

Analyses of the complete blood count, biochemistry, cerebrospinal fluid (CSF), and urine in dogs with LD may be within the reference range (Swain et al. 2017). There is no specific therapy for this condition, only treatment of the clinical signs.

Diagnosis of LD can be made using genetic testing, such as PCR-based sequencing, but these tests are not routinely used because they are not sufficiently reliable (Márquez et al. 2010; Swain et al. 2017). In order to distinguish between two different genotypes, the Southern blot is the most reliable method to be used (von Klopmann et al. 2021). Histopathology is the crucial method for diagnosing LD, but it can only be used post mortem. Lafora bodies are usually found in the frontal cortex but may be present in other parts of the brain (Swain et al. 2017; Rai and Ganesh 2019). Marques et al. (2010) first found LD in the perikarya of neurons. Until this discovery, LD in animals were thought to be found only in the axon (Suzuki et al. 1978).

This study presents a case report of a Chihuahua dog with LD presented as generalized tonic clonic seizures responsive to phenobarbital.

### Case description

#### Clinical and neurological examination

A 7-year-old intact female Chihuahua was presented with a 2-day history of generalized tonic-clonic seizures with a marked postictal phase. The owners reported five seizures in previous 48 hours. The last seizure occurred six hours prior to presentation. Postictal phase with disorientation and restlessness was evident. Prior to seizures the dog had no significant medical or surgical history. Vaccinations and regular monthly parasite protection were up to date. No abnormalities were noted on either general physical or neurological examination.

Based on the client's medical history, intoxication was considered less likely as the cause of the seizures. Biochemical panel values were within the reference range, except for a slight increase (less than one-fifth) in alanine transaminase (ALT) (2.288  $\mu$ kat/l, reference range 0–1.496). The CaniV-4 rapid antigen test (Bionote®, chromatographic immunoassay for the qualitative detection of *Dirofilaria immitis* antigen, antibodies to *Anaplasma phagocytophilum/Anaplasma platys*, antibodies to *Borrelia burgdorferi*, and antibodies to *Ehrlichia canis*) was negative. Magnetic resonance imaging and cerebrospinal fluid analysis were refused by the owner. Based on the data collected from the medical history, neurological examination, and blood tests, toxic, metabolic, and infectious causes of the seizures were excluded. We hypothesized that possible causes for the seizures could be idiopathic, inflammatory, or neoplastic.

The dog was started on phenobarbital 2.5 mg/kg twice daily *per os*. After initiation of phenobarbital therapy, seizures were no longer noted. The dog was reexamined on six months interval and haematology, biochemistry, and phenobarbital serum concentration were assessed at the same interval with no abnormalities detected. There was no phenobarbital dosage adjustment. Two years later, the dog died from an intestinal foreign body complication and status epilepticus caused by the omission of phenobarbital therapy.

#### Postmortem examination

Postmortem examination revealed large amounts of gas and fluid in the stomach. The duodenal mucosa was diffusely hyperaemic with multifocal necrohaemorrhagic areas

of irregular shape. A foreign body (hazelnut) was found in this part of the intestine. Pulmonary collapse was also observed.

Macroscopic examination revealed hyperaemic meninges and an enlarged, oedematous brain with flattened gyri and narrowed sulci (Plate VIII, Fig. 1). On coronal sections, the ventricular system of the brain appeared dilated, and 3 ml of cerebrospinal fluid (hydrocephalus) was found.

No other gross pathologic changes were noted.

### Histopathology

After macroscopic examination, brain samples were fixed in 10% neutral buffered formalin. After standard processing in an automated tissue processor, tissue specimens were embedded in kerosene blocks, cut into 5 µm thick sections, deparaffinized in xylene, rehydrated through a series of ethanol at decreasing concentrations, and stained with haematoxylin and eosin (HE) and periodic acid-Schiff (PAS) (Plates IX, X, Figs 2–5).

Histological examination revealed diffuse hyperaemia, multifocal white matter gliosis, and multifocal to diffuse randomly distributed PGBs. They were found in all brain tissue sections examined (frontal cerebral cortex, thalamus, hippocampus, cerebellum, brainstem). They were numerous in the cerebral cortex, thalamus, hippocampus (especially in the central part of the Ammon horn) and parts of the cerebellum (in the molecular layer and Purkinje cells as well as the large neurons of the white matter). They were sporadically presented in the frontal white matter, cerebellar granular layer, and brainstem. It is interesting that PGBs were rarely seen or completely absent in the branching part of the cerebellar white matter. They varied widely in size from just a few to 20 µm in radius. Most of them were amphophilic to slightly basophilic with a variably sized, round, smooth, occasionally radial, dark, basophilic central core. Some lacked this bright marginal zone and consisted only of a dark blue nucleus, while others were large and feathery with no nucleation. Although they were all positive on PAS-stained sections, their appearance also varied widely, ranging from aggregates of positive granular material in the neuronal cytoplasm to a weakly stained outer layer with a dense, strongly positive central core.

### Discussion

There are several diagnostic approaches for LD. Clinical signs in dogs often appear between 6 and 9 years of age. Unlike in humans, LD is not fatal in animals but causes various neurodegenerative disorders (Chambers et al. 2018). The genetic test for LD is based on Southern blotting which is too expensive for dog owners; the other option is PCR-based sequencing which is not sufficiently reliable because of the massive dodecamer repeat expansion mutation (Swain et al. 2017). This is the main reason why brain tissue histopathology is of great importance for the diagnosis of LD, especially for scientific purposes. Visualization of these LB is much easier when PAS staining is used. PGBs can also be found in liver, muscle, skin, and urinary bladder smooth muscle, but the number of these bodies is small (Iannaccone et al. 1991; Chambers et al. 2018). According to von Klopmann et al. (2021) MRI method and examination of CSF can be performed as a part of neurological examination, but findings and results of the CSF tap were unremarkable in both French Bulldog cases and in the Yorkshire Terrier/Chihuahua/Chinese Crested mixed-breed dog, while MRI may have indicated early cortical atrophy.

The dog in this report was 7 years old when the first seizure occurred and had generalized tonic-clonic seizures as in a case report presented by Espadas et al. (2018). There were no myoclonic seizures which are typical for this disease. Complete blood count, serum biochemistry, urinalysis and CSF analysis were unremarkable in patients suffering from LD (Webb et al. 2009; Swain et al. 2017).

Lafora disease is a progressive neurodegenerative disease with symptoms worsening over time despite therapy. There is no effective treatment for LD at present, and the goal of the current therapeutic approach is to manage the clinical signs and seizures. New antiepilepsy drug (Levetiracetam) can be used to control myoclonus, but for a short period of time and only in early stages of disease (Swain et al. 2017; von Klopmann et al. 2021). The use of cannabidiol (CBD) oil for LD in mice has shown no effect on seizures, but this oil can reduce cognitive damage (Aso et al. 2020). Although in some cases phenobarbital shows no or little effectiveness, in this case, seizures stopped occurring after phenobarbital therapy was started and the dog showed no new neurological signs, so we assumed idiopathic epilepsy was present in this dog.

The diagnosis of idiopathic epilepsy is based on the type of onset and nature of the seizures, a good response to phenobarbital therapy, and the absence of disease progression. Although this case had all the features of idiopathic epilepsy, it is an atypical form of structural brain disease - LD.

Lafora disease is thought to be caused by dysfunction of laforin and/or malin. Studies in mice and dogs have shown that depletion of malin can lead to accumulation of laforin and consequent formation of PGBs (Chambers et al. 2018). The diagnosis of LD in dogs is of great importance as they are a promising animal model. The reason for that, amongst others, is similarity in the onset of first clinical signs both in humans and dogs. Signs of LD in dogs are usually present in animals older than 7 years and in humans during late childhood/early adolescence, and after the onset of first clinical signs, the disease progresses at the same time rate (von Klopmann et al. 2021). A different therapeutic approach for this disease in dogs may lead to improvements in the treatment of this disease in humans.

Many authors reported presence of PGBs in the brain of old apparently healthy dogs and their formation was considered to be a part of the ageing process (Borras et al. 1999; Nestic et al. 2021). Borras et al. (1999) have found PGBs in the brain of all aged dogs studied (animals in this group were 8–18 years old). Nestic et al. (2021) discovered PGBs in almost all aged dogs (93%), with animals examined being over 10 years old. Both group of authors reported an increase in the number of PGBs with age, while they also found none in the control groups of young dogs (less than 5 years old). The dog in this study was 7 years old, which puts it in between the age limits of previous studies. The distribution pattern of PGBs was similar to those described in the above mentioned studies. Nevertheless, the age and amount of PGBs found in this case make it less likely to be an age-related change.

To our knowledge, this is the third case of LD in a Chihuahua dog (Espadas et al. 2018; Barrientos et al. 2019). In contrast to our case, LD was suspected based on neurological signs typical of this disease in dogs, but no data on gross and microscopic changes were presented. In the study of Barrientos et al. (2019), the whole genome of the Chihuahua dog was examined and the presence of both NHLRC1 alleles was found, indicating the genetic basis of this disease in Chihuahuas.

The present case indicates that LD should be considered when presented with a dog with generalized tonic clonic seizures responsive to phenobarbital. Further studies and genetic testing should be conducted to allow for better understanding of the response to phenobarbital therapy as well as more insight into the prevalence of this disease.

#### Acknowledgement

The study was supported by the Ministry of Science, Technological Development and Innovation of the Republic of Serbia (Contract number 451-03-47/2023-01/200143).

#### References

Alisaukaite N, Beckmann K, Dennler M, Zölch N 2020: Brain proton magnetic resonance spectroscopy findings in a Beagle dog with genetically confirmed Lafora disease. *J Vet Intern Med* **34**: 1594-1598

- Aso E, Andrés-Benito P, Grau-Escolano J, Caltana L, Brusco A, Sanz P, Ferrer I 2020: Cannabidiol-enriched extract reduced the cognitive impairment but not the epileptic seizures in a Lafora disease animal model. *Cannabis Cannabinoid Res* **5**: 150-163
- Barrientos LS, Maiolini A, Häni AK, Jagannathan V, Leeb T 2019: NHLRC1 dodecamer repeat expansion demonstrated by whole genome sequencing in a Chihuahua with Lafora disease. *Anim Genet* **50**: 118-119
- Borras D, Ferrer I, Pumarola M 1999: Age-related changes in the brain of the dog. *Vet Pathol* **36**: 202-211
- Chambers JK, Thongtharb A, Shiga T, Azakami D, Saito M, Sato M, Morozumi M, Nakayama H, Uchida K 2018: Accumulation of laforin and other related proteins in canine Lafora disease with EPM2B repeat expansion. *Vet Pathol* **55**: 543-551
- Espadas I, Minassian B, Wang P, Ahonen S, Sanchez-Masian D 2018: Canine Lafora disease in the Chihuahua breed. Proceedings of the 31<sup>st</sup> Annual Symposium of the ESVN-ECVN, Copenhagen, Denmark. *J Vet Intern Med* **34**: 488-530
- Iannaccone S, Zucconi M, Quattrini A, Nemni R, Comola M, Taccagni L, Smirne S 1991: Early detection of skin and muscular involvement in Lafora disease. *J Neurol* **238**: 217-220
- Lohi H, Ianzano L, Zhao XC, Chan EM, Turnbull J, Scherer SW, Ackerley CA, Minassian BA 2005: Novel glycogen synthase kinase 3 and ubiquitination pathways in progressive myoclonus epilepsy. *Hum Mol Genet* **14**: 2727-2736
- Machado-Salas J, Avila-Costa MR, Guevara P, Guevara J, Duron RM, Bai D, Tanaka M, Yamakawa K, Delgado-Escueta AV 2012: Ontogeny of Lafora bodies and neurocytoskeleton changes in laforin-deficient mice. *Exp Neurol* **236**: 131-140
- Márquez M, Pérez L, Serafin A, Teixeira S, Navarro C, Pumarola M 2010: Characterisation of Lafora-like bodies and other polyglucosan bodies in two aged dogs with neurological disease. *Vet J* **183**: 222-225
- Nesic S, Vucicevic I, Marinkovic D, Kukolj V, Anicic M, Ristoski T, Nikolic S, Aleksic-Kovacevic S 2021: Histochemical characteristics and distribution of lipofuscin and polyglucosan bodies in the brain of dogs more than 10 years old. *Vet Glas* **75**: 57-68
- Rai A, Ganesh S 2019: Polyglucosan Bodies in Aged Brain and Neurodegeneration: Cause or Consequence? In: Rath P (Ed): *Models, Molecules and Mechanisms in Biogerontology*, pp. 57-89, Springer, Singapore
- Rao SN, Maity R, Sharma J, Dey P, Shankar SK, Satishchandra P, Jana NR 2010: Sequestration of chaperones and proteasome into Lafora bodies and proteasomal dysfunction induced by Lafora disease-associated mutations of malin. *Hum Mol Genet* **19**: 4726-4734
- Sainsbury R 2014: DNA screening for Lafora's disease in miniature wire-haired dachshunds. *Vet Rec* **175**: 568
- Schoeman T, Williams J, van Wilpe E 2002: Polyglucosan storage disease in a dog resembling Lafora's disease. *J Vet Intern Med* **16**: 201-207
- Sharma J, Mukherjee D, Rao SN, Iyengar S, Shankar SK, Satishchandra P, Jana NR 2013: Neuronatin-mediated aberrant calcium signaling and endoplasmic reticulum stress underlie neuropathology in Lafora disease. *J Biol Chem* **288**: 9482-9490
- Suzuki Y, Akiyama K, Suu S 1978: Lafora like inclusion bodies in the digestive tract of the aged dog. *Acta Neuropathol* **44**: 2017-222
- Swain L, Key G, Tauro A, Ahonen S, Wang P, Ackerley C, Minassian BA, Rusbridge C 2017: Lafora disease in miniature Wirehaired Dachshunds. *PLoS ONE* **12**: e0182024
- von Klopmann T, Ahonen S, Espadas-Santiuste I, Matiasek K, Sanchez-Masian D, Rupp S, Vandenberghe H, Rose J, Wang T, Wang P, Minassian BA, Rusbridge C 2021: Canine Lafora disease: an unstable repeat expansion disorder. *Life (Basel)* **11**: 689
- Webb AA, McMillan C, Cullen CL, Boston SE, Turnbull J, Minassian BA 2009: Lafora disease as a cause of visually exacerbated myoclonic attacks in a dog. *Can Vet J* **50**: 963-967

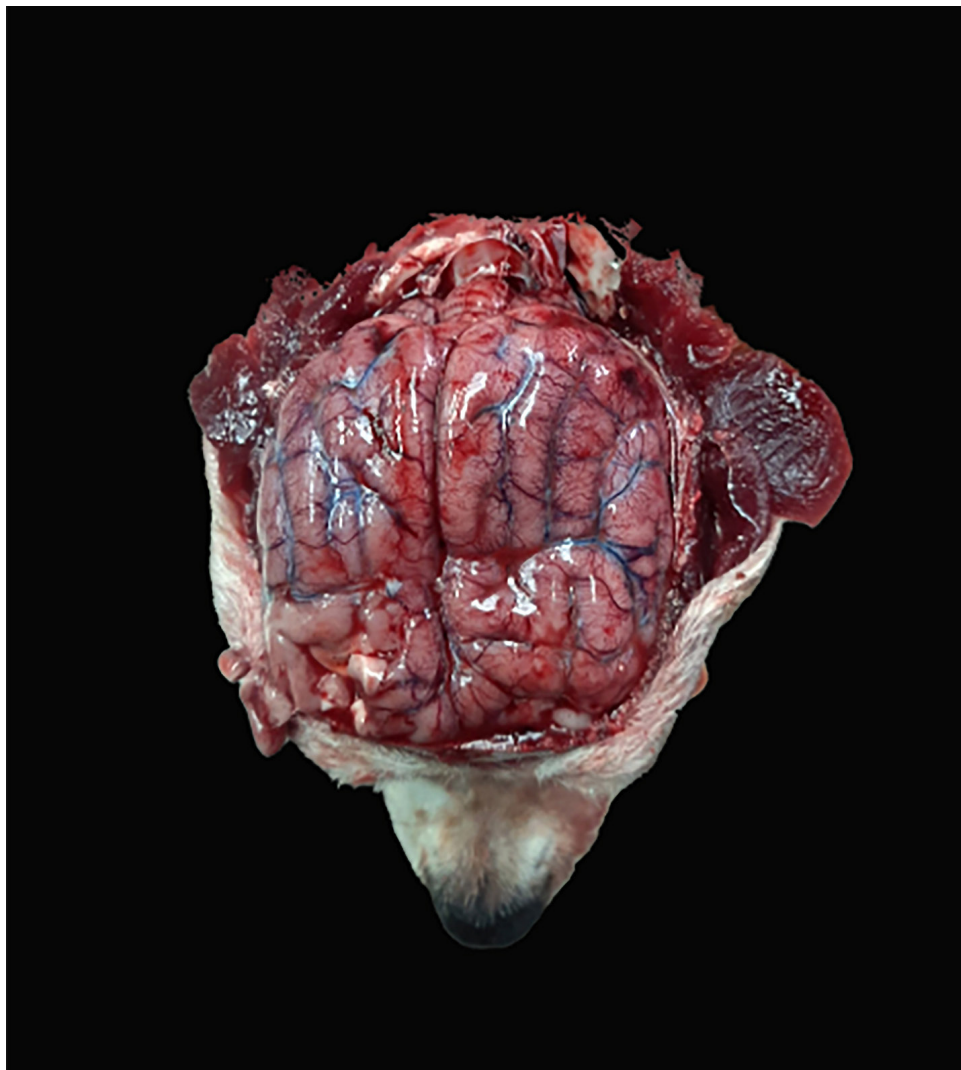


Fig. 1. Macroscopic image of the brain

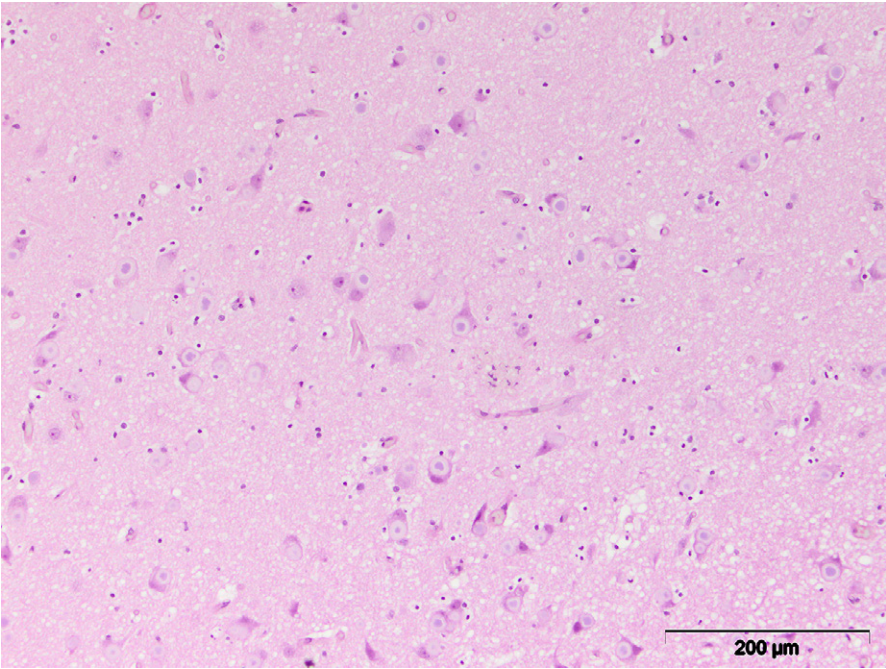


Fig. 2. Cerebral cortex, HE,  $\times 200$

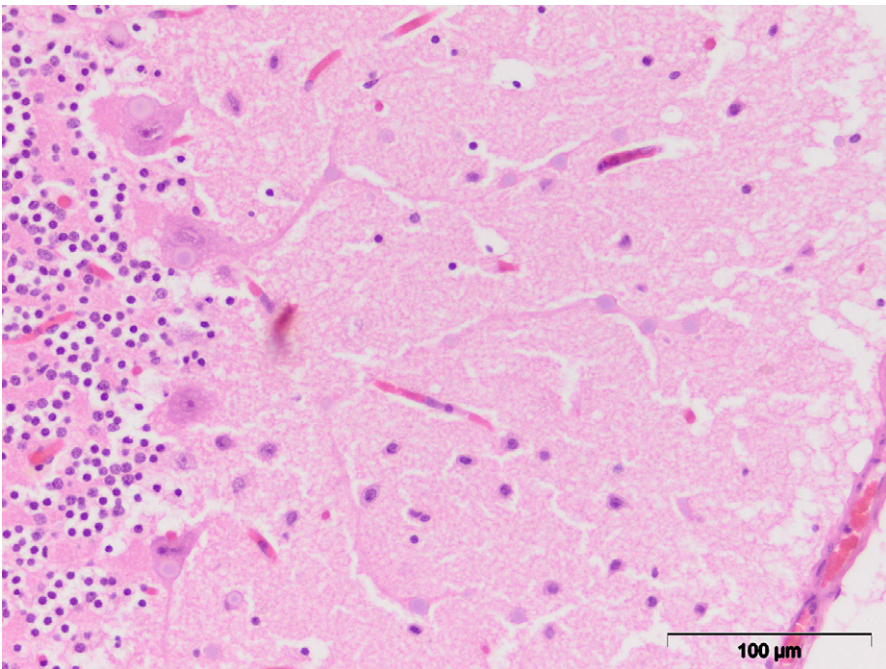


Fig. 3. Cerebellum, HE,  $\times 400$

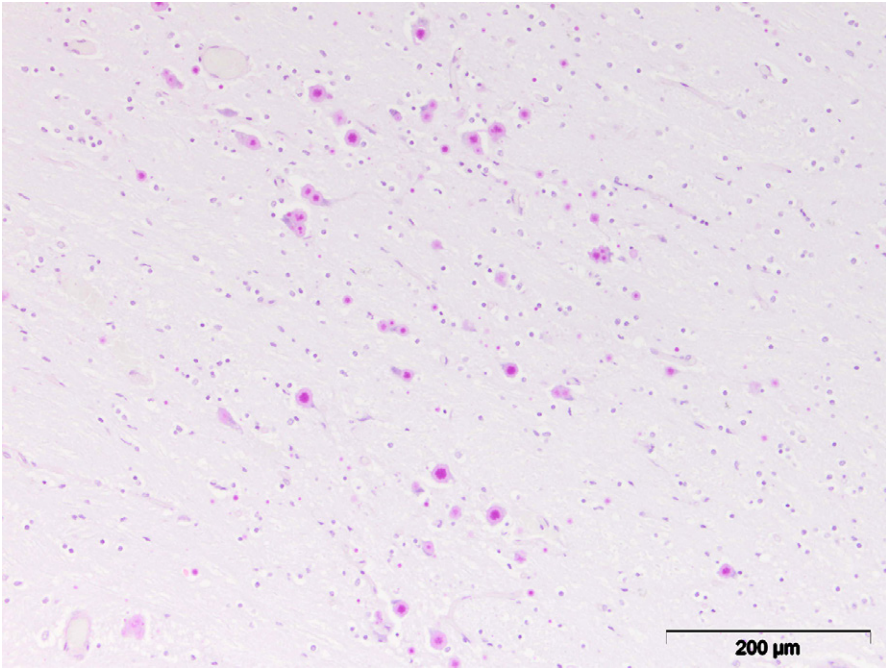


Fig. 4. Thalamus, PAS,  $\times 200$

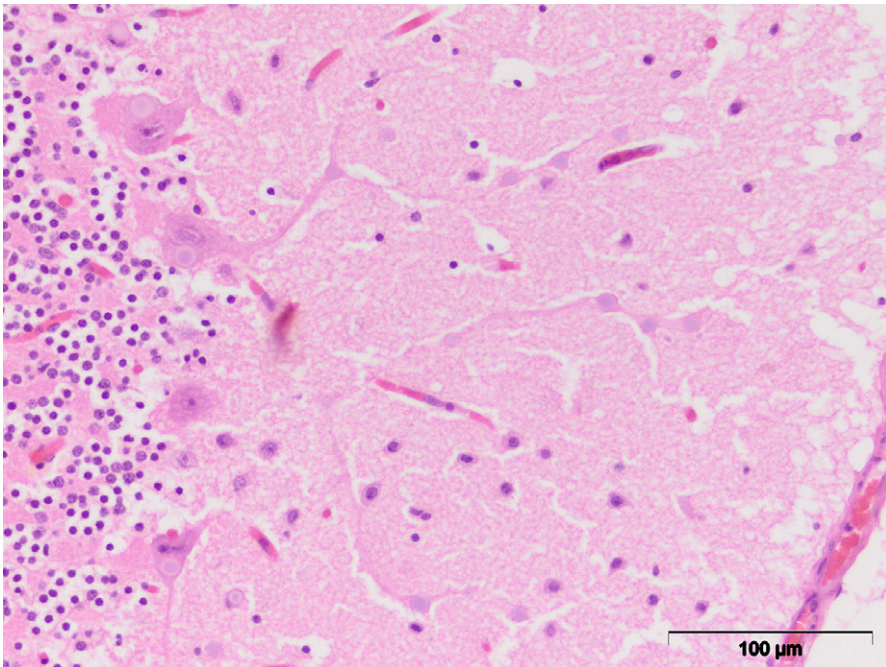


Fig. 5. Cerebellum, PAS,  $\times 200$