



---

December 2023

## Progressive Glenohumeral Instability in an Adolescent Ice Hockey Athlete: A Case Report

Kelsey J. Robinson

*Rocky Mountain University of Health Professions, kelsey.robinson@rm.edu*

Jennifer Austin

*Rocky Mountain University of Health Professions, jennifer.austin@rm.edu*

Follow this and additional works at: <https://nsuworks.nova.edu/ijahsp>

---

### Recommended Citation

Robinson KJ, Austin J. Progressive Glenohumeral Instability in an Adolescent Ice Hockey Athlete: A Case Report. *The Internet Journal of Allied Health Sciences and Practice*. 2023 Dec 15;22(1), Article 3.

This Case Study is brought to you for free and open access by the College of Health Care Sciences at NSUWorks. It has been accepted for inclusion in *Internet Journal of Allied Health Sciences and Practice* by an authorized editor of NSUWorks. For more information, please contact [nsuworks@nova.edu](mailto:nsuworks@nova.edu).

---

## Progressive Glenohumeral Instability in an Adolescent Ice Hockey Athlete: A Case Report

### Abstract

This case follows the injury presentation of a 16-year-old male, right-hand dominant, left-hand shot, Tier I ice hockey player who sustained an initial injury to the left shoulder from a body check during a game. What follows is a cascade of events involving 3 injuries and 2 surgeries, highlighting the complex and potentially compounding nature of instability. Glenohumeral (GH) instability among collision athletes is rare in the absence of contributing genetic conditions or a dislocation or subluxation event. Authors discuss the key concepts related to the diagnosis and management of GH instability, with a special emphasis on subtle injury indicators and an individualized approach to patient care.

---

### Author Bio(s)

Kelsey J. Robinson, MS, LAT, ATC, is a student pursuing a PhD in Health Sciences with a concentration in Healthcare Professions Education at Rocky Mountain University of Health Professions in Provo, UT. She is also a licensed Athletic Trainer with experience in collegiate athletics and orthopedic practice.

Jennifer Austin, PhD, LAT, ATC, GTS, is the Program Director of the Doctor of Philosophy in the Health Sciences (PhD) program. Dr. Austin is a licensed athletic trainer with extensive experience in collegiate athletics as well as over 17 years of experience as an educator.



**The Internet Journal of Allied Health Sciences and Practice**

*Dedicated to allied health professional practice and education*

**Vol. 22 No. 1 ISSN 1540-580X**

---

## Progressive Glenohumeral Instability in an Adolescent Ice Hockey Athlete: A Case Report

---

Kelsey J. Robinson

Jennifer Austin

Rocky Mountain University of Health Professions

United States

---

### **ABSTRACT**

This case follows the injury presentation of a 16-year-old male, right-hand dominant, left-hand shot, Tier I ice hockey player who sustained an initial injury to the left shoulder from a body check during a game. What follows is a cascade of events involving 3 injuries and 2 surgeries, highlighting the complex and potentially compounding nature of instability. Glenohumeral (GH) instability among collision athletes is rare in the absence of contributing genetic conditions or a dislocation or subluxation event. Authors discuss the key concepts related to the diagnosis and management of GH instability, with a special emphasis on subtle injury indicators and an individualized approach to patient care.

**Keywords:** collision athlete, posterior pain, capsular plication, individualized care

---

### **KEY POINTS:**

1. Glenohumeral instability without subluxation nor dislocation rarely occurs in collision athletes.
  2. Markers of glenohumeral instability may be subtle and masked by other symptoms.
  3. Timely and accurate diagnosis is imperative for the successful management of instability.
-

## INTRODUCTION

Ice hockey is considered a collision sport, and among other potential mechanisms of injury, it involves checking, contact between a player and the boards, and other player-to-player contacts. These mechanisms are linked to 76% of all shoulder injuries in the sport, including glenohumeral (GH) dislocations and subluxations.<sup>1</sup> Traumatic GH dislocations are frequent among young athletes, with 40% of shoulder dislocations occurring in athletes under 22 years of age.<sup>2-4</sup>

Evidence suggests that the incidence of GH instability caused by acute, traumatic mechanisms is common within collision sports, particularly in late adolescent and young adult athletes.<sup>5-7</sup> Within the ice hockey population, the injury rate continues to increase with age, and peak between 20 – 24 years old.<sup>1</sup> Data suggests shoulder injuries among ice hockey athletes account for 8.6% to 21.9% of all injuries. Often these shoulder injuries result in complex patterns, such as the occurrence of Bankart lesions in combination with Hills-Sach lesions,<sup>8</sup> increasing the difficulty of an accurate diagnosis. A tendency to report the incidence of GH instability collectively with other injuries, such as acromioclavicular (AC) joint and rotator cuff (RC) injuries, further complicates prevalence data.<sup>1,9</sup> Based on these reporting patterns, instability may occur at an increased rate than currently reported within the literature. While there is a growing body of literature regarding the recognition and treatment of GH dislocation and subluxation events among collision sport athletes, there is little evidence available for clinicians to advance their knowledge on identifying and managing GH instability in the absence of acute injury mechanisms. Thus, further attention to non-traumatic GH instability in the collision sport athlete is warranted to ensure timely and appropriate intervention.

“Minor shoulder instability” also called “occult shoulder instability” refers to shoulder pain secondary to instability caused by biomechanical, functional, or comfort-related changes.<sup>10,11</sup> Minor shoulder instability presents in the absence of a dislocation event and often without major lesions to the supporting structures of the joint.<sup>10</sup> One publication studying posterior shoulder pain and anterior instability among patients with minor shoulder instability made a notable observation: all patients presented with scapular pain.<sup>12</sup> Furthermore, 3 of the 16 patients presented without a history of dislocation or subluxation, had negative apprehension and relocation tests, and had only 2 indicators of anterior instability: posterior pain and type II scapular dyskinesia.<sup>12</sup> This case will outline the development of an unusual incident of GH instability in an ice hockey athlete and the diagnostic and treatment intricacies required for a successful return to sport.

## CASE PRESENTATION

### Patient

The patient was a 16-year-old male, right-hand dominant, left-hand shot, Tier I ice hockey player. He did not have a history of joint hypermobility or contributing genetic conditions. He sustained an initial injury to the left shoulder from a body check during a game in December 2019, causing posterior shoulder pain and scapular muscle tightness. Therapists conservatively managed this initial injury. The patient continued to play through the remainder of the season; however, 3 months after the initial injury, the patient's symptoms had not subsided and were impeding off-season strength training. The clinician referred the patient to an orthopedic physician for further examination.

### Interventions

On March 16, 2020, approximately 3 months after the initial injury, an orthopedic physician evaluated the patient. The patient's chief complaints were posterior shoulder pain and tightness of the trapezius. The patient did not present with indications of neurologic pathology, nor was there an indication of psychosocial factors that may impact the chief complaints. A full report of examination findings is available in Table 1. Following the exam, the patient was diagnosed with rotator cuff tendinopathy and apophysitis of the left shoulder. X-ray and MRI were non-significant. The patient was treated conservatively with non-steroidal anti-inflammatory drugs (NSAIDs) and physical therapy to address scapular mobility and muscular imbalances, namely of the scapular stabilizer musculature, infraspinatus, and subscapularis muscles. He progressed with mild lingering discomfort and participated in his sport until sustaining another routine body check to the left shoulder during a summer training camp 5 months later.

**Table 1.** Evaluation Findings

Date	March 2020		August 2020		November 2020		April 2021	
	Right	Left	Right	Left	Right	Left	Right	Left
<b>Kinetics</b>	Normal scapular movement	Normal scapular movement	Normal scapular movement	Type 2- medial scapular prominence, moderate	Normal scapular movement	Normal scapular movement	Normal scapular movement	Normal scapular movement
<b>Tenderness</b>	None	Acromion, trapezius	None	AC joint and posterior	None	Anteriorly; Posteriorly	None	Mild Posteriorly
<b>Flexion (active)</b>	170, with no pain	170, with no pain	175	175	170, with no pain	170, pain with extremes	160, no pain	160, pain at maximum
<b>Gh Abd</b>	110	100	100	100	160	160, pain with extremes	150	150
<b>ER0 (active)</b>	80, with no pain	75, with no pain	60	60	50	50, with pain	45, with no pain	45 with no pain
<b>IR0</b>	T2	T2, with pain	T4	T4	T5	T5	T7	T7, with pain
<b>Strength IR</b>	N/R	5-	Normal	Normal	Normal, no pain	Normal, with pain	5	5
<b>Strength FE</b>	5	5	Normal	Normal	Normal, no pain	Normal, mild pain	5	5
<b>Strength Abd</b>	5	5-	Normal	Normal	Normal, no pain	Normal, no pain	5	5
<b>Strength ER</b>	5	5	Normal	Normal	Normal, no pain	Normal, no pain	5	5
<b>Lift Off</b>	Negative	Moderately weak	Negative	Inconclusive	Not Tested	Not Tested	Not Tested	Not Tested
<b>Crepitus</b>	None	None	Negative	Negative	None	None	None	None
<b>Impingement</b>	Negative	Negative	Negative	Positive	Negative	Negative	Not Tested	Not Tested
<b>Adduction</b>	Negative	Positive	Negative	Inconclusive	Not Tested	Not Tested	Not Tested	Not Tested
<b>AC Comp</b>	Negative	Positive	Negative	Negative	Negative	Negative	Not Tested	Not Tested
<b>O'Brien's</b>	Negative	Negative	Not Tested	Not Tested	Not Tested	Not Tested	Not Tested	Not Tested
<b>Speed's</b>	Negative	Negative	Not Tested	Not Tested	Not Tested	Not Tested	Not Tested	Not Tested
<b>Inferior Laxity</b>	Not Tested	Not Tested	Not Tested	Normal	.5	.5	Not Tested	Trace with pain at extremes
<b>Posterior Laxity</b>	Not Tested	Not Tested	Not Tested	.5 with no pain	.5	.5	Not Tested	Trace with pain at extremes
<b>Anterior Laxity</b>	Not Tested	Not Tested	Not Tested	.5 with minimal pain	.5	.5	Not Tested	Trace with pain at extremes
<b>Ant-inf Laxity</b>	Not Tested	Not Tested	Not Tested	Normal	Not Tested	Not Tested	Not Tested	Trace
<b>Relocation</b>	Not Tested	Not Tested	Negative	Negative	Not Tested	Positive	Not Tested	Not Tested
<b>Anterior Stress</b>	Not Tested	Not Tested	Not Tested	Not Tested	Not Tested	Positive - Apprehensive	Not Tested	Positive - Apprehensive

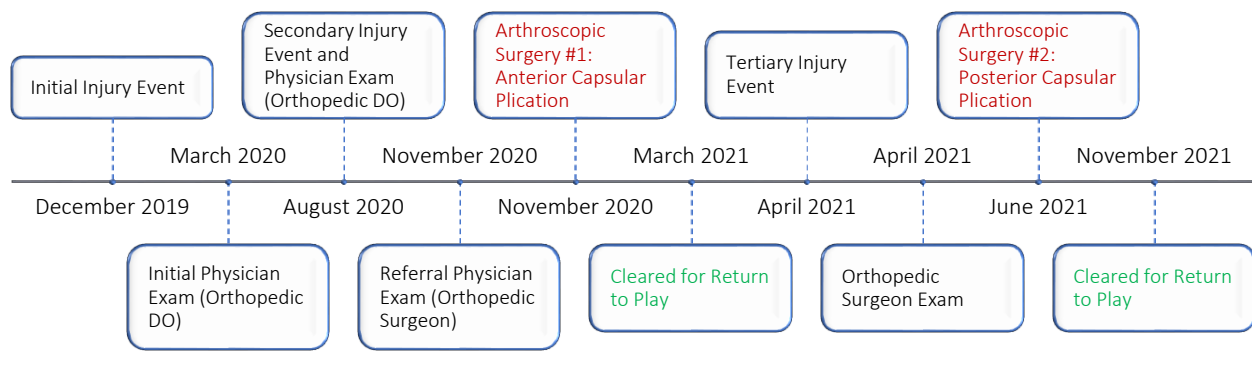
On August 6, 2020, one week following the second injury event, an orthopedic physician evaluated the patient. The patient again denied acute subluxation or dislocation but described feelings of anterior instability and pain along the posterior aspect of the GH joint. X-rays presented normally. The physical exam noted mild posterior laxity, mild anterior laxity with minimal pain, and point

tenderness over the acromion. The diagnosis was a left AC joint sprain, RC strain, and capsular sprain. The orthopedic physician recommended a second round of physical therapy and NSAIDs with no activity restrictions. The patient continued training and regular-season sport participation.

Three months later, on November 9, 2020, the patient reported to the orthopedic physician with worsening symptoms, including reports of subluxation, and was further referred for a surgical consult which occurred on November 11, 2020. Although an MRI was negative, the orthopedic surgeon noted laxity and recommended left shoulder arthroscopy. Arthroscopic surgery was performed 1 week later, on November 19, 2020. Examination under anesthesia noted laxity of 1 in all directions and a mild drive-through sign anteriorly; however, the GH joint was visually normal with no labral tears. The orthopedic surgeon completed an arthroscopic anterior capsular plication. The patient proceeded with a rehabilitation plan and reported no pain at follow-ups 7, 11, and 16 weeks postoperatively. The patient was cleared for gradual return to sport participation with no restrictions at 16 weeks postoperatively on March 10, 2021, with advice to continue his strengthening program.

Five weeks later, the patient was playing in an off-season game when he was body checked from the anterolateral side, causing immediate posterior pain similar to the pain experienced pre-surgery. Examination 1 week later, on April 23, 2021, by the orthopedic surgeon noted pain and instability posteriorly, as well as a positive anterior stress test (full examination findings are available in Table 1). The patient's symptoms progressed despite conservative management, including manual therapy, neuromuscular reeducation, and therapeutic exercise. After an additional MRI Arthrogram, the orthopedic surgeon performed a second arthroscopy with posterior capsular plications. Upon intraoperative inspection, the orthopedic surgeon noted no evidence of labral tear; however, he did recognize significant posterior instability. The patient progressed through rehabilitation with a physical therapist, an athletic trainer, and a specialized strength and conditioning program with a certified strength and conditioning specialist. The patient's programs focused on postoperative mobility, strengthening, and improving movement patterns holistically. In addition to targeting improved GH range of motion and scapular stability, the patient's rehabilitation emphasized thoracic rotation to reduce stress on the GH joint and rotator cuff stabilizers. On November 19, 2021, 5 months postoperatively, the orthopedic surgeon cleared the patient to return to contact practice and competition. At the time of this manuscript, the patient had successfully participated in regular and post-season activity without returning symptoms. Figure 1 provides a detailed timeline of patient events.

**Figure 1. Injury and Recovery Timeline**



**DISCUSSION**

Injuries of this nature are not well-documented in the literature, and none have documented a similar cascade of pathological instability events. Like the clinical patterns described in the introduction, the patient, in this case, presented for an orthopedic exam on March 16, 2020, with posterior pain and a positive lift-off test indicative of subscapular weakness. However, at that time, the patient did not complain of feelings of instability, and corresponding tests were not conducted based on presentation of symptoms and x-ray results indicating joint spaces were well maintained. Following the second injury and evaluation on August 6, 2020, the patient presented with a negative relocation test, positive posterior pain, and type II scapular dyskinesia. Table 1 provides a synopsis of the patient's orthopedic exam findings throughout care.

An accurate diagnosis of minor shoulder instability may be more complicated by the frequency with which patients present with symptoms indicative of AC joint impingement.<sup>13</sup> Several studies document the concurrent presence of symptoms of AC impingement with shoulder instability.<sup>11,14-16</sup> In the young athletic population, AC impingement may occur secondary to minor

shoulder instability; however, because of the presentation of symptoms, AC impingement may be incorrectly diagnosed as the primary and only injury.<sup>13,17</sup> The patient, in this case, presented with tenderness over the AC joint, a positive AC compression test, and posterior and anterior instability of 0.5 at the August 6, 2020 evaluation. The orthopedic physician diagnosed the patient with an AC joint sprain and shoulder capsular sprain at that time.

By the time of the orthopedic surgeon's exam on November 11, 2020, the patient also displayed signs of inferior instability. The surgeon's evaluation indicated a laxity of 0.5 in 3 directions preoperatively and instability of 1 in all directions under sedation. The diagnosis at the time of surgery was anterior-inferior instability; therefore, the surgeon completed anterior plications. The literature is mixed on arthroscopic surgical management of anterior instability. A study done on cadavers by Peltier et al<sup>18</sup> supports placing anterior-only plications in the case of anterior or anterior-inferior instability, indicating that additional plication may result in overtightening of the joint. However, research published by Westerheide et al<sup>19</sup> involving 71 shoulders with anterior instability demonstrated that patients suffering from recurrent anterior instability often have some degree of posterior capsular laxity. Addressing both anterior and posterior laxity concurrently, improved outcomes and reduced re-injury rates. The incidence of injury recurrence following arthroscopic treatment of anterior shoulder instability is relatively low, with reported rates ranging from 4 – 7.5%.<sup>19-21</sup>

Because laxity was noted anteriorly, posteriorly, and inferiorly, a healthcare provider must also consider the possibility of multidirectional instability (MDI). Although there is variation in the literature, MDI is generally defined as instability in at least 2 directions.<sup>22-26</sup> Multidirectional instability typically results from a genetic condition that causes generalized laxity of joint capsules or repetitive microtraumas to a joint, such as those seen in overhead sports.<sup>25</sup> It would be unusual for a collision sport athlete whose primary GH movement patterns are below 90 degrees of flexion and abduction to present with MDI without an underlying genetic condition or repetitive microtrauma.

Following the patient's third injury on April 16, 2021, the evaluation revealed trace instability in all directions and a positive apprehension test. Posterior instability was diagnosed after unsuccessful conservative management resulting in the orthopedic surgeon performing a second surgery and placing capsular plications posteriorly.

## CONCLUSION

In this case, the patient presented without an initial subluxation or dislocation event or complaints of instability. Although the athlete presented with subtle indicators of joint instability early on, including posterior pain and type II scapular dyskinesis, diagnosis of GH instability was delayed. This timeline is consistent with research indicating that symptoms suggestive of AC joint injury may appear secondary to GH instability, masking the instability symptoms and delaying accurate diagnosis and treatment.<sup>13,17</sup>

The cascade of events involving 3 injuries and 2 surgeries, highlights the complex and potentially compounding nature of GH instability, emphasizing the importance of accurate and timely recognition of joint instability to successful injury management and return to sport.<sup>19</sup> Publications related to shoulder instability primarily center around dislocations and subluxations, and resources for treatment and rehabilitation are widely available in the literature. This case indicates that some collision sport athletes may display signs of instability before experiencing a subluxation or dislocation and may present with more subtle symptoms. Early recognition and management strategies incorporating appropriately individualized care techniques and the expertise of diverse clinician perspectives may be vital to preventing more extensive injuries and reducing the need for surgery and extended time away from sports participation.

Although recommendations vary across the literature regarding the diagnosis and management of shoulder instability, it is clear that a timely and accurate diagnosis is imperative for the successful management of GH instability, particularly in the athletic population.<sup>19</sup> Clinicians should consider GH instability in patients under the age of 40, who present with posterior shoulder pain and scapular dyskinesis in the absence of a dislocation or subluxation event.<sup>13</sup>

---

## REFERENCES

1. Mölsä J, Kujala U, Myllynen P, Torstila I, Airaksinen O. Injuries to the upper extremity in ice hockey: analysis of a series of 760 injuries. *Am J Sports Med.* 2003;31(5):751-757.
2. Cameron KL, Mountcastle SB, Nelson BJ, Duffey ML, Svoboda LCSJ, Owens LCBD. History of shoulder instability and subsequent injury during four years of follow-up: a survival analysis. *J Bone Joint Surg.* 2013;95(5):439-445.
3. Hovelius L, Augustini B, Fredin H, Johansson O, Norlin R, Thorling J. Primary anterior dislocation of the shoulder in young patients. A ten-year prospective study. *J Bone Joint Surg Am.* 1996;78(11):1677-1684.

4. Rhee YG, Cho NS, Cho SH. Traumatic anterior dislocation of the shoulder: factors affecting the progress of the traumatic anterior dislocation. *Clin Orthop Surg.* 2009;1(4):188-193.
5. Trojan JD, Meyer LE, Edgar CM, Brown SM, Mulcahey MK. Epidemiology of shoulder instability injuries in collision collegiate sports from 2009 to 2014. *Arthroscopy.* 2020;36(1):36-43.
6. Owens BD, Agel J, Mountcastle SB, Cameron KL, Nelson BJ. Incidence of glenohumeral instability in collegiate athletics. *Am J Sports Med.* 2009;37(9):1750-1754.
7. Kraeutler MJ, Currie DW, Kerr ZY, Roos KG, McCarty EC, Comstock RD. Epidemiology of shoulder dislocations in high school and collegiate athletics in the United States: 2004/2005 through 2013/2014. *Sports Health.* 2018;10(1):85-91.
8. Dwyer T, Petrera M, Bleakney R, Theodoropoulos JS. Shoulder instability in ice hockey players: incidence, mechanism, and MRI findings. *Clin Sports Med.* 2013;32(4):803-813.
9. Emery CA, Meeuwisse WH. Injury rates, risk factors, and mechanisms of injury in minor hockey. *Am J Sports Med.* 2006;34(12):1960-1969.
10. Castagna A, Grasso A, Vinanti G. Minor shoulder instabilities. *Shoulder Arthroscopy and MRI Techniques.* Springer; 2003:193-212.
11. Castagna A, Nordenson U, Garofalo R, Karlsson J. Minor shoulder instability. *Arthroscopy.* 2007;23(2):211-215.
12. Castagna A, Conti M, Borroni M, et al. Posterior shoulder pain and anterior instability: a preliminary clinical study. *Chir Organi Mov.* 2008;91(2):79-83.
13. Nordenson U, Garofalo R, Conti M, et al. Minor or occult shoulder instability: an intra-articular pathology presenting with extra-articular subacromial impingement symptoms. *Knee Surg Sports Traumatol Arthrosc.* 2011;19(9):1570-1575.
14. Boileau P, Zumstein M, Balg F, Penington S, Bicknell RT. The unstable painful shoulder (UPS) as a cause of pain from unrecognized anteroinferior instability in the young athlete. *J Shoulder Elbow Surg.* 2011;20(1):98-106.
15. Pieper H-G, Quack G, Krahl H. Impingement of the rotator cuff in athletes caused by instability of the shoulder joint. *Knee Surg Sports Traumatol Arthrosc.* 1993;1(2):97-99.
16. Warner J, Micheli LJ, Arslanian LE, Kennedy J, Kennedy R. Scapulothoracic motion in normal shoulders and shoulders with glenohumeral instability and impingement syndrome. A study using Moiré topographic analysis. *Clin Orthop Relat Res.* 1992;(285):191-199.
17. Jobe F, Kvitne R, Giangarra C. Shoulder pain in the overhand or throwing athlete. The relationship of anterior instability and rotator cuff impingement. *Orthop Rev.* 1989;18(9):963-975.
18. Peltier KE, McGarry MH, Tibone JE, Lee TQ. Effects of combined anterior and posterior plication of the glenohumeral ligament complex for the repair of anterior glenohumeral instability: a biomechanical study. *J Shoulder Elbow Surg.* 2012;21(7):902-909.
19. Westerheide KJ, Dopirak RM, Snyder SJ. Arthroscopic anterior stabilization and posterior capsular plication for anterior glenohumeral instability: a report of 71 cases. *Arthroscopy.* 2006;22(5):539-547.
20. Gartsman GM, Roddey TS, Hammerman SM. Arthroscopic treatment of anterior-inferior glenohumeral instability: two to five-year follow-up. *J Bone Joint Surg.* 2000;82(7):991.
21. Kim S-H, Ha K-I, Cho Y-B, Ryu B-D, Oh I. Arthroscopic anterior stabilization of the shoulder: two to six-year follow-up. *J Bone Joint Surg.* 2003;85(8):1511-1518.
22. Jacobson ME, Rigggenbach M, Wooldridge AN, Bishop JY. Open capsular shift and arthroscopic capsular plication for treatment of multidirectional instability. *Arthroscopy.* 2012;28(7):1010-1017.
23. Neer CIF, CR. Inferior capsular shift for involuntary inferior and multidirectional instability of the shoulder. *J Bone Joint Surg.* 1981;63:1208-1217.
24. Schenk TJ, Brems JJ. Multidirectional instability of the shoulder: pathophysiology, diagnosis, and management. *J Am Acad Orthop Surg.* 1998;6(1):65-72.
25. Longo UG, Rizzello G, Loppini M, et al. Multidirectional instability of the shoulder: a systematic review. *Arthroscopy.* 2015;31(12):2431-2443.
26. Ren H, Bicknell RT. From the unstable painful shoulder to multidirectional instability in the young athlete. *Clin Sports Med.* 2013;32(4):815-823.