



9-2023

Cyclic Alternating Pattern of Encephalopathy (Cape) In CNS Infection: A Case Report

Zaid Waqar

Pakistan Institute of Medical Sciences, Islamabad, Pakistan

Soban Khan

Pakistan Institute of Medical Sciences, Islamabad, Pakistan

Maryam Khalil

Pakistan Institute of Medical Sciences, Islamabad, Pakistan

Bushra Khalid

Pakistan Institute of Medical Sciences, Islamabad, Pakistan

Zakir Jan

Pakistan Institute of Medical Sciences, Islamabad, Pakistan

See next page for additional authors

Follow this and additional works at: <https://ecommons.aku.edu/pjns>



Part of the [Neurology Commons](#)

Recommended Citation

Waqar, Zaid; Khan, Soban; Khalil, Maryam; Khalid, Bushra; Jan, Zakir; Adil, Muhammad; and Saddiqa, Amina (2023) "Cyclic Alternating Pattern of Encephalopathy (Cape) In CNS Infection: A Case Report," *Pakistan Journal of Neurological Sciences (PJNS)*: Vol. 18: Iss. 3, Article 7.

Available at: <https://ecommons.aku.edu/pjns/vol18/iss3/7>

Cyclic Alternating Pattern of Encephalopathy (Cape) In CNS Infection: A Case Report

Authors

Zaid Waqar, Soban Khan, Maryam Khalil, Bushra Khalid, Zakir Jan, Muhammad Adil, and Amina Saddiqa



CYCLIC ALTERNATING PATTERN OF ENCEPHALOPATHY (CAPE) IN CNS INFECTION: A CASE REPORT

Zaid Waqar¹, Soban Khan¹, Maryam Khalil¹, Bushra Khalid¹, Zakir Jan¹, Muhammad Adil¹, Amina Saddiqa¹

¹Pakistan Institute of Medical Sciences, Islamabad

Correspondence Author: Zaid Waqar Department of Neurology, Pakistan Institute of Medical Sciences, Islamabad **Email:** chikky789@gmail.com

Date of submission: April 27, 2023 **Date of revision:** August 2, 2023 **Date of acceptance:** August 31, 2023

ABSTRACT

Cyclic Alternating Pattern of Encephalopathy (CAPE) is rare EEG phenomenon first described in 1944 in a comatose patient. It is similar to sleep EEG pattern of cyclic alternating pattern (CAP) which is a periodic electroencephalogram activity of non-REM sleep. The cyclic alternating pattern (CAP) is defined by sequences of transient electrocortical events that are different from the tonic background and repeat at intervals of up to one minute. CAPE, however, is abnormal EEG pattern. In this pattern of EEG abnormality slow wave activity of 1-2Hz alternates with fast activity of 6-10 hertz. Here we present a case of patient with CNS infection on mechanical ventilation whose EEG showed the above-mentioned pattern.

Keywords: CAPE; encephalopathy, EEG, meningitis, encephalitis

INTRODUCTION

Cyclic Alternating Pattern of Encephalopathy (CAPE) is an EEG pattern with irregular low-voltage rapid activity (between 6 and 10 Hz) followed by high-voltage, slow waves without any external stimulation.¹ Romano and Engel are credited with first describing this pattern using the term ECAP pattern in 1944; Fischgold and Mathis continued this description in 1959. Cyclic alternating pattern in EEG practice was considered a sign of cerebral disturbance in past. However, in recent years it has been realized that it is a specific type of periodic activity that comprises of two phases a slow phase and a fast phase. These phases alternate and correlate with clinical outcome.² It is a spontaneous feature of normal sleep and involved typically in stage changes and nocturnal motor activity. Its physiological amount (CAP rate) varies with age.³ This term was first described in 1944 in patients in deep coma and since 1985 it is known that similar pattern is also seen during NREM stage of sleep. It is thought cyclical alternating pattern has been less recognized and underreported because of its similarity to burst suppression pattern of EEG but it can be differentiated from later by the presence of reactivity. Its clinical significance remains unknown in state of coma and further studies in time can elucidate the importance of EEG cyclical alternating pattern.

Cyclic Alternating Pattern of Encephalopathy (CAPE) is a new word that was added to the 2021 revision of the ACNS Standardised Critical Care

EEG Terminology. It is described as background pattern alterations that persist at least 10 seconds and alternate regularly across at least 6 cycles in patients with encephalopathy. CAPE's therapeutic relevance is yet unclear. Here we present a case of central nervous system infection having CAPE.

PRESENTATION OF CASE

An 18-year-old male having no previous co morbidities presented in Emergency of Pakistan Institute of Medical Sciences with history of holo-cephalic headache, fever and multiple episodes of generalized tonic clonic fits for one day. At time of presentation, his vital signs were blood pressure of 115/70 mmHg, heart rate of 128 beats per minute, respiratory rate 24 breaths per minute, temperature of 39 degree Celsius and SpO₂ of 99% on 10 L O₂ support via face mask. His GCS was 7/15 (E2V1M4). Pupils were bilateral equal and reactive and signs of meningeal irritation were present. Generalized hypertonia and bilateral down going plantars were noted. He went into status epilepticus and was shifted to ICU for mechanical ventilator support.

Laboratory investigations showed total leukocyte count of 10610/micro litre with neutrophilic predominance, haemoglobin of 12.3g/dl and platelet count of 101000/micro litre. Serum chemistry revealed CPK levels of 596 U/L with normal renal, hepatic and coagulation profile. Hepatitis B and C screening were negative. Plain computed tomography brain was unremarkable. Malarial parasite smear was negative.

Cerebrospinal fluid routine examination showed WBC of 6/micro litre with RBC count of 2000/micro litre, protein 60.6 mg/dl and glucose of 74.6 mg/dl. Electroencephalography showed cyclical alternating pattern while he was on ventilatory support. HSV PCR I & II were negative.

Treatment started on the lines of meningio-encephalitis. He remained on ventilatory

support for nine days and then weaned off. He was shifted to neurology ward and completed 14 days course of antibiotics and antivirals. His GCS improved and remained fit free with no signs of respiratory distress and neurological failure again. Magnetic resonance imaging brain were unremarkable. He was discharged on oral anti-epileptic drugs with Modified Rankin Scale score 0.

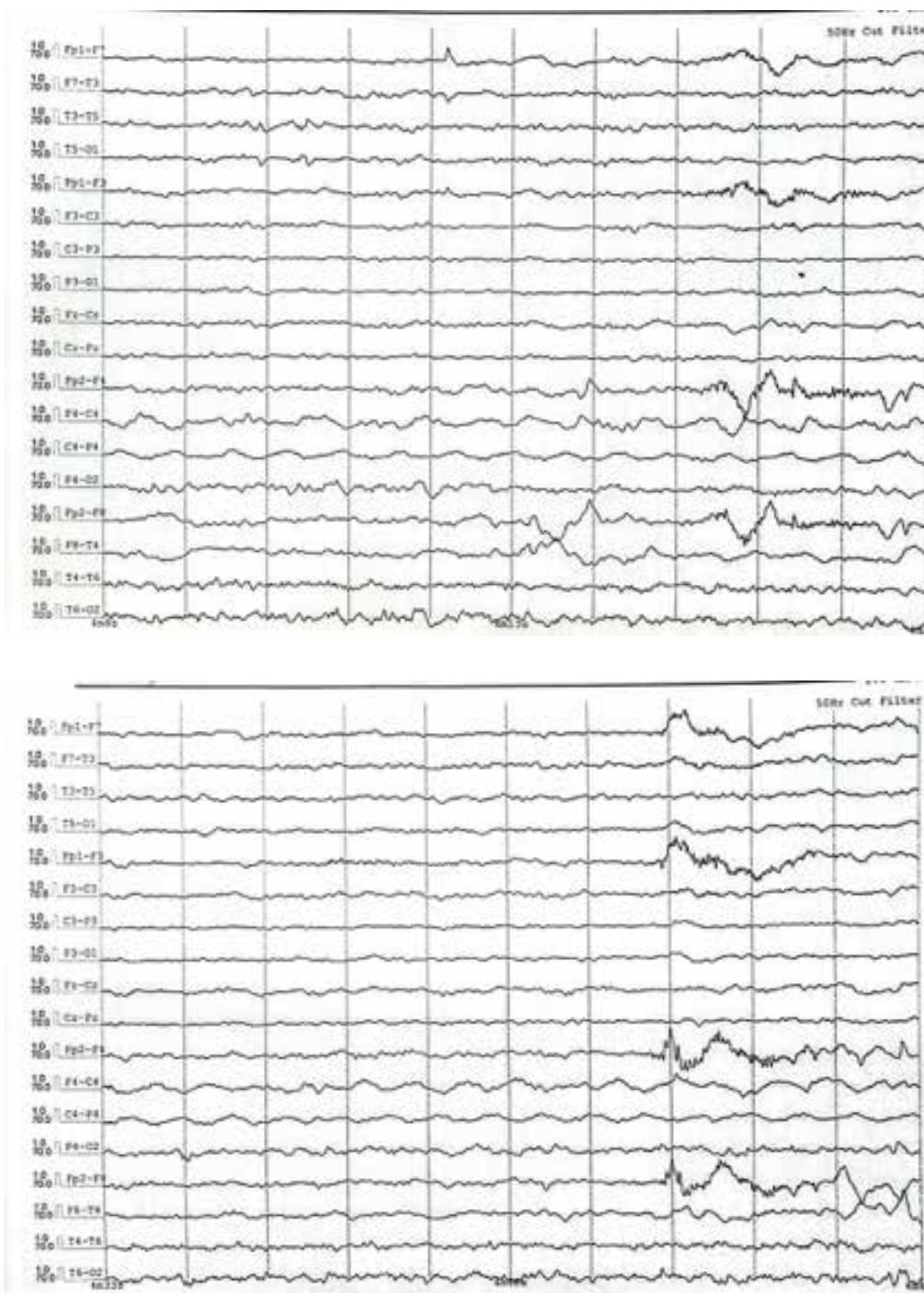


Figure 1: Section of EEG Montage showing irregular low-voltage rapid activity followed by high-voltage, slow waves characteristic of CAPE

DISCUSSION

CAPE is a rare phenomenon that is seen in comatose patients. In one of the largest patient databases, patients studied over a period of four years, 11 Patients were identified who had Cyclical Alternating Pattern of encephalopathy on EEG and all were in comatose state. Most of these patients survived coma state and regained good functional status hence confirmed good prognosis of cyclical alternating pattern of encephalopathy.¹ Good

prognosis may be explained by the fact that it is a typical pattern seen during normal sleep. ECAP of sleep often happens during the NREM sleep stage and frequently comes before the change from NREM to REM sleep. ECAP during sleep is sometimes seen at a time when the brain is attempting to sustain sleep during a period of sleep instability. More case reports in future will likely throw better light on this rare presentation.

REFERENCES

1. Kassab MY, Farooq MU, Diaz-Arrastia R, Van Ness PC. The clinical significance of EEG cyclic alternating pattern during coma. *J Clin Neurophysiol.* 2007;24(6):425-428. doi:10.1097/WNP.0b013e31815a028e
2. Mario GT, Liborio P. The cyclical alternating pattern (CAP) in human sleep; *Handbook of Clinical Neurophysiology*, Elsevier: (6) 2005;79-93.
3. Terzano MG, Parrino L, Smerieri A. Les bases neurophysiologiques de l'insomnie: le rôle des tracés alternant cycliques (CAP) [Neurophysiological basis of insomnia: role of cyclic alternating patterns]. *Rev Neurol (Paris).* 2001;157(11 Pt 2):S62-S66.

Conflict of interest: Authors declare no conflict of interest.

Funding disclosure: Nil

Authors' contribution:

Zaid Waqar; concept, case management, manuscript writing

Soban Khan; case management, manuscript writing

Maryam Khalil; case management, manuscript writing

Bushra Khalid; case management, manuscript revision

Zakir Jan; case management, manuscript revision

Muhammad Adil; case management, manuscript revision

All the authors have approved the final version of the article, and agree to be accountable for all aspects of the work.