

ORIGINAL RESEARCH

Patients with adult-acquired buried penis and their surgical management: a single-center study

Melissa Wong¹, Bryan Torres², Aadit Patel², Abigail Chaffin², David Jansen², Wayne JG Hellstrom^{1,*}

¹Department of Urology, Tulane University School of Medicine, New Orleans, LA 70112, USA

²Division of Plastic Surgery, Tulane University School of Medicine, New Orleans, LA 70112, USA

***Correspondence**
whellst@tulane.edu
(Wayne JG Hellstrom)

Abstract

Adult-acquired buried penis (AABP) is a condition in which the suprapubic fat (the escutcheon) conceals the penis. The etiologies of AABP include obesity, pelvic lymphedema, lichen sclerosis, and scar contraction following a circumcision. If untreated, AABP can lead to hygiene-related infections, urinary and sexual disorders, and psychological issues, such as depression, diminished self-esteem, and poor quality of life. When weight reduction fails to resolve this condition, surgical correction can successfully manage the patient's AABP. The goal of surgical repair is to extract the telescoped penis from the escutcheon. In our experience, this has been successful with a urologist/plastic surgeon team. Cases of surgical repair for AABP performed at a single medical center from 2012 to 2022 were retrospectively reviewed. Fourteen patients, whose age ranged from 40 to 74 years old, were identified, and their characteristics as well as the surgical techniques performed on them were reviewed. All patients were obese, their body mass index ranging from 32.1 to 62.4; eight patients were severely obese. Five patients had a history of adult circumcision, 5 had a prior diagnosis of lichen sclerosis, and 3 had genital lymphedema. The initial procedures were routine but with some variation. The surgical techniques included performing a panniculectomy and/or an escutcheonectomy, degloving the penis, removing nonfunctional fibrotic tissue, incising the suspensory ligament, and using a meshed split-thickness skin graft (STSG) for penile coverage. The most common complication was wound dehiscence. Two patients with complications required a return to the operating room; one patient returned for closure of an infected wound and the other for penile reconstruction and the placement of a new STSG for lymphedema. All patients eventually recovered, with no further complications reported.

Keywords

Adult-acquired buried penis; Escutcheon; Surgical repair; Meshed split-thickness skin graft

1. Introduction

While an uncommon condition, adult-acquired buried penis (AABP) has been recognized for at least a century. It was first described as the "apparent absence of the penis" by Keyes in 1919. Keyes referred to a case in which "under the skin above the scrotum a movable body was felt, liberated by incision and discovered to be the penis" [1]. Since this initial description, this condition and its treatment has continued to be recognized and further described in the literature.

Today, AABP is simply understood as a condition in which the suprapubic fat (the escutcheon) conceals the penis. Due to poor fixation of the skin, the penis telescopes into the suprapubic fat, which leads to shortening and complete covering of the penis. Unlike pediatric buried penis, AABP is due to several contributing etiologies, such as obesity, pelvic lymphedema, lichen sclerosis, and cicatrix following a circumcision.

Furthermore, AABP is a morbid condition that affects patients both physically and psychologically, as the escutcheon hinders proper hygiene of the scrotal area, thereby causing skin breakdown, inflammation, and infection. The associated chronic inflammation can create an environment that leads to malignancy. In a cohort of 150 patients, penile squamous cell carcinoma was observed in 7% of patients, and premalignant lesions were observed in 25% of patients [2]. Aside from the long-term risks, patients experience daily symptoms as well, such as urinary infections, sexual dysfunction, and psychological stress. In a study of 11 patients, 64% reported clinical depression, and 91% reported erectile dysfunction [3]. Clearly, AABP impacts patients' quality of life, which can be improved by surgical correction.

The goal of surgical repair is to extract the penis from the escutcheon. In our experience, this has been successful with the teamwork of a urologist and a plastic surgeon. The

main role of the urologist is to safely unbury the penis and remove any nonfunctional tissue, whereas the main role of the plastic surgeon is to close the wound in a manner that allows successful healing.

The goal of this retrospective cohort study is to provide an analysis of the predisposing factors of patients with AABP and the procedures performed on them. In doing so, we hope to provide better insight into this condition and to provide the appropriate techniques needed for repair.

2. Materials and methods

Cases of surgical repair for AABP were retrospectively identified from our database of cases spanning from January 2012 to September 2022. Patients who were 18 years or older, who had a primary diagnosis of AABP, and who underwent surgical repair involving a urologist and a plastic surgeon met the inclusion criteria of this review. Fourteen patients, who met these criteria, were individually evaluated by the urologist and plastic surgeon and had their surgeries performed at a single medical center. The demographics, characteristics, and the comorbidities of these patients as well as the surgical techniques performed on these patients were reviewed.

3. Procedure details

A preoperative evaluation of patients was performed, accessing the severity of the pannus, the scrotum, the penis, and the quality of skin, *e.g.*, viable or diseased. A specified percentage of weight loss was not required, but weight loss was encouraged, particularly if the patient needed improved blood glucose control. Any necessary surgical skin marking was performed in the preoperative holding area (Fig. 1A). Once in the operating room, the patient was positioned in a supine or lithotomy position. First, a Foley catheter was placed to help identify the urethra. In some cases, a dorsal slit was performed if the urethral meatus was not easily identified. If there was a concern for urethral stricture disease (USD), a cystoscopy was optionally performed.

Surgical repair proceeded with removing the diseased penile skin or completely degloving the penis. This was accomplished with a circumferential incision below the coronal sulcus and with a ventral incision to release any phimotic bands. Penile degloving involved releasing the dartos layer from the corporal bodies to the root of the penis. At this point, the suspensory ligament was exposed and incised to completely mobilize the penis to its full length (Fig. 1B,C). With the glans exposed, its overlying penile skin was removed or salvaged depending on its quality. The proximal corporal bodies were fixated to the fascia or periosteum of the pubic bone by using several tacking sutures, such as 2-0 Vicryl sutures. The sutures were placed at the 2- and 10-o'clock positions in a longitudinal direction parallel to the penile shaft to avoid injuring the neurovascular bundles.

If the patient had a severely redundant pannus, a panniculectomy was performed. The pannus tissues were removed by the plastic surgeon and then primarily closed. During this step, care was taken to preserve the bilateral spermatic cord structures. Drains were routinely placed under the remaining

skin flaps prior to this closure.

The wound closure began with closing the skin flaps around the base of the penis in a layered fashion, thereby leaving the penile shaft in need of skin coverage. A meshed split-thickness skin graft (STSG), which was harvested from either the anterior thigh or the pannus if a panniculectomy had been performed, was used to cover the penile skin defect. Once properly prepared with a dermatome then meshed, the STSG was placed over the skin defect and appropriately sutured (Fig. 1D). Depending upon the surgeon's preference, the graft site was either wrapped in a gauze dressing or managed with a vacuum-assisted closure, which uses negative pressure to promote healing. Adjunctive procedures were tailored to meet the needs of each patient, which included cystoscopy, removal of scrotal skin for scrotoplasty, meatoplasty for meatal stenosis or stricture of the fossa navicularis, and correction of penile curvature.

The patients were admitted postoperatively to the hospital for observation and given medications to suppress erections, *e.g.*, ketoconazole and prednisone. The Foley catheter was maintained to not only allow the penile dressing to be kept clean and dry but also to ease the concern for any acute urinary retention. Patients were discharged on postoperative day one if they reached relevant milestones, including controlled pain, ambulation, and toleration of their regular diet. Patients were discharged with the Foley catheter, which was removed at their follow-up appointment on postoperative day 7 through 10. The removal of the drains, which occurred during a similar timeline, were contingent upon the drains' output, the patients' overall healing status, and the plastic surgeon's clinical judgement.

4. Results

The age of patients ranged from 40 to 74 years old, with a mean of 57.86, and the body mass index (BMI) of patients ranged from 32.1 to 62.4, with a mean of 43.31 (+/-8.78) (Table 1). All of the 14 patients were in the obese category, and 8 patients were in the severe obese category. Five patients had a history of adult circumcision, 5 patients had a prior diagnosis of lichen sclerosis, and 3 patients had genital lymphedema (Table 1). Six patients were diagnosed with USD, and 4 of these 6 had prior surgeries for their USD, including urethral dilation or urethroplasty. Besides obesity, these patients' other comorbidities included diabetes mellitus, obstructive sleep apnea, and hypertension. Symptoms reported by these patients included skin irritations or infections, erectile dysfunction, painful erections, frequent urinary tract infections, and difficulties with urinary stream. A STSG, with a range in size of 24 to 170 square centimeters, was used for penile reconstruction in 14 patients. Ten patients had a panniculectomy, and the pannus was used for their STSG. The other 4 patients had their STSG harvested from an anterior thigh. As mentioned above, adjunctive procedures included cystoscopy, scrotoplasty, meatoplasty, and correction of penile curvature. Five patients had a cystoscopy performed at the start of the procedure, 9 patients had a scrotoplasty, 3 patients had a meatoplasty, and 5 patients had plastic surgery procedures to correct penile curvature.

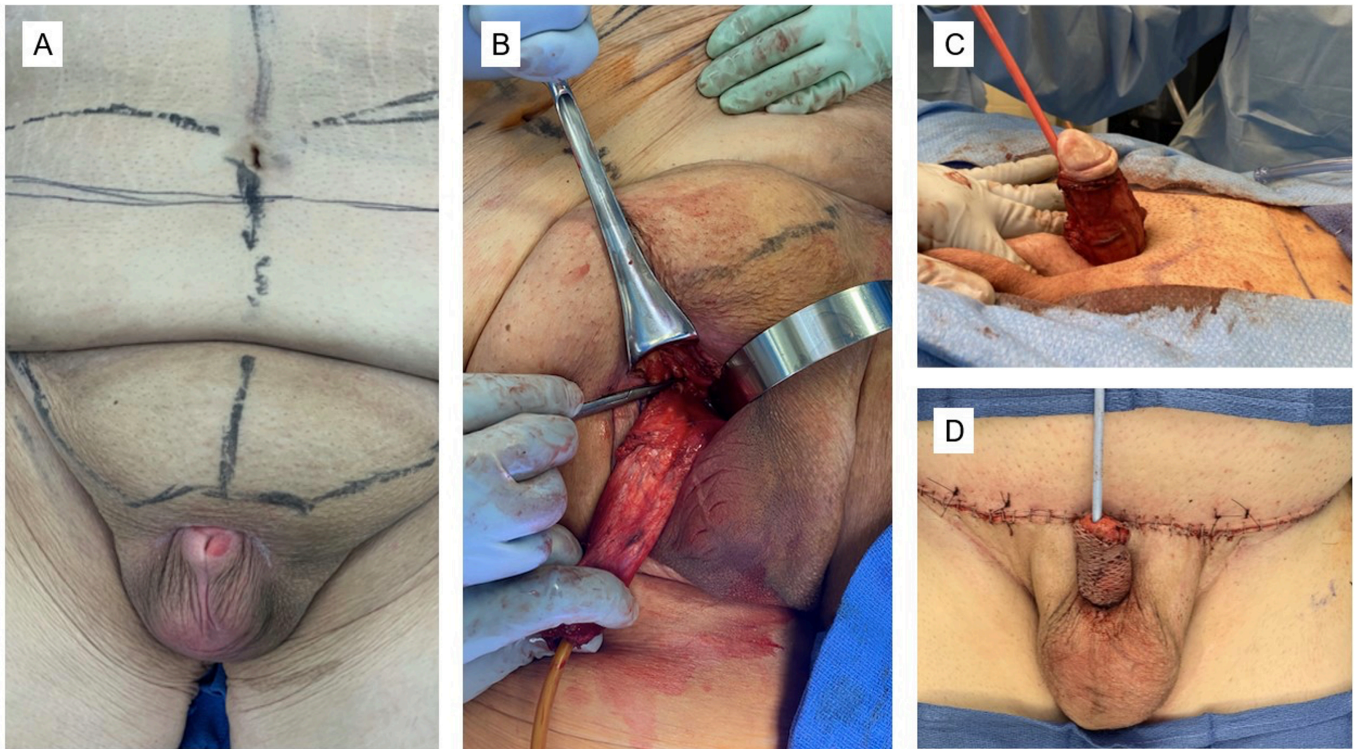


FIGURE 1. Surgical repair. (A) Typical presentation of a patient with AABP prior to surgery. The patient's skin has been marked (in the preoperative holding area) for the panniculectomy and for the skin graft harvested from the pannus. (B,C) The patient's penis has been degloved during surgical repair. The poor tissue has been excised, and the penis is no longer buried by the escutcheon. The full length of the penis can be assessed and measured to determine the size of graft required for penile coverage. (D) A meshed split-thickness skin graft was used for coverage of the penile shaft.

TABLE 1. Preoperative characteristics of patients.

Characteristics	n
Patients, n	14
Age, years	57.86 ± 10.73
40–59	8 (57%)
≥60	6 (43%)
BMI, kg/m ²	43.31 ± 8.78
30–39	6 (43%)
≥40	8 (57%)
Predisposing factors	
Obesity	14 (100%)
Lichen sclerosis	5 (36%)
Adult circumcision	5 (36%)
Genital lymphedema	3 (21%)

Values are expressed as the mean ± standard deviation or number (%).

BMI: body mass index.

All patients were seen for follow-up and had their repairs monitored for healing and complications. The majority of patients healed without complication. The incisions closed, and the meshed appearance of the graft disappeared over time (Fig. 2A,B). Of the 14 patients, 5 had complications. The most common postoperative complication was wound dehiscence,

which was observed in 3 of the 14 patients. Of these 3 patients, 1 had a wound infection and returned to the operating room for wound closure, whereas the other 2 patients had a mild dehiscence and thus treated with local wound care. One patient had a hematoma at the panniculectomy incision, which was evacuated at bedside. Another patient, who returned to the operating room 14 months later for development of genital lymphedema, required penile reconstruction and the placement of a new STSG.

5. Discussion

Obesity is the single most common predisposing factor to AABP, as increased weight can lead to the increased size of the escutcheon. An enlarged escutcheon covers the penile shaft while the penis is fixed in place by its fascial attachments, causing a telescoping of the penis. In the United States, the prevalence of obesity has risen in recent years from 30.5% (1999–2000) to 41.9% (2017–2020) [4]. It can be theorized that as obesity rates rise, the prevalence of AABP will thereby increase. Other contributing conditions, including lichen sclerosis, lymphedema, and prior circumcision, were also represented in our cohort of patients. Of our 14 patients, 5 had a circumcision as an adult. Although a circumcision is the most common procedure performed by urologists, surgeons should carefully consider the complications of a circumcision and its potential impact.

Kara *et al.* [5] reviewed 13 patients who had adult buried

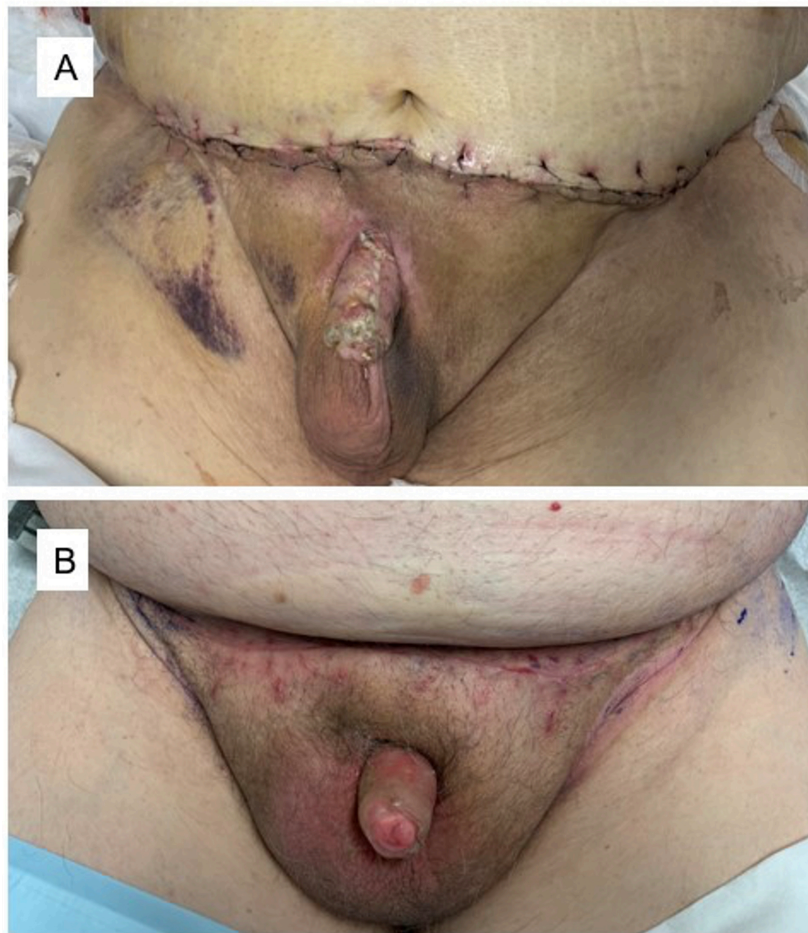


FIGURE 2. Postoperative healing. (A) The appearance of the repaired buried penis at 2 weeks postoperation. The incisions are healing appropriately. (B) The appearance of the repaired buried penis at 7 weeks postoperation. The incisions are healed, and the meshed appearance of the graft is less visible.

penis as a result of their childhood circumcision. It is suggested that the burying of the penis is related to the removal of excessive penile skin. If performed on a patient to help expose a partially buried penis, the circumcision can further telescope the penis. In some cases, the circumcision can lead to the development of a cicatrix, a fibrotic ring that traps the penis completely [5]. Therefore, the potential complication of this routine procedure should be recognized, especially in a patient with a developing AABP.

The use of STSGs instead of full-thickness skin grafts (FTSGs) in corrective procedures for AABP is warranted. We have theorized that the STSG has greater flexibility and is therefore less prone to disruption. As patients naturally have nocturnal erections, the STSG has greater flexibility to stretch, whereas the FTSG may tear. Although there are no direct comparisons of their use in the genital region, the outcomes regarding the use of STSGs and FTSGs have been compared in patients with other types of wounds. FTSGs were noted to have lower rates of postgraft contracture and therefore less need for surgical release, and STSGs were noted to have higher rates of improved cosmesis and successful grafting outcomes [6]. In the setting of AABP, the use of STSGs and FTSGs have been reported on separately. For example, Fuller *et al.* [7] used STSGs, and rates of graft survival were reported at a mean of 91.7% in a cohort of 12 people. In

contrast, Monn *et al.* [8] used FTSGs for penile grafts in 13 patients and reported 100% success in graft acceptance and minimal wound complications. Without a direct comparison, it will be difficult to unequivocally determine which graft is appropriate for these patients.

The successful outcomes associated with the meshed skin graft can be correlated to its overall composition and application. Specifically, the meshed graft allows drainage of any fluid collections and minimizes the amount of graft that heals through secondary intention. One criticism of the meshed graft concerns its appearance as it heals, which we describe as pebbled or cobblestoned. Black *et al.* [9] described their method of harvesting and applying the meshed STSG, noting the effort required to lay down the graft without stretching the meshed slits. During the follow-up of nine patients, the meshed pattern decreased over time. In addition to the mesh's ability to drain fluids and to successfully establish, they are also easier to apply to the contours of the graft bed [9]. All of our patients received a meshed STSG, with all patients having good graft acceptance and long-term cosmesis. While there are multiple methods to cover the penis, the common goals are for the graft to survive, for the wound to heal without complications, and for good cosmesis.

In a recent systematic review of 21 studies, postoperative complications ranged from 0 to 80.8%, with genital wound

infections and lymphedema as the most common complications [10]. This is in alignment with our study, where return to the operating room was required for a wound dehiscence involving infection and for genital lymphedema. Fortunately, we did not encounter graft-related complications, such as graft contracture or graft loss, which are reported in 4.7% to 33% of cases and observed more often in FTSGs compared to STSGs [10].

This study is limited by its retrospective nature, by the relatively small number of patients included for review, and by being performed at a single institution. In addition, there was limited follow-up in some patients, which prevented in-depth analysis of outcomes, complications, and recurrence.

6. Conclusions

AABP will continue to present itself to practicing urologists and plastic surgeons, especially with the high prevalence of obesity. With the morbid effect of AABP on patients, it is important that these patients receive the appropriate management, such as weight reduction and surgical repair. If the urologist/plastic surgeon team follows the standard surgical steps for AABP repair, as well as tailoring the procedure to the patient's need, the patient is more likely to have a successful outcome.

ABBREVIATIONS

AABP, adult-acquired buried penis; USD, urethral stricture disease; STSG, split-thickness skin graft; BMI, body mass index; FTSG, full-thickness skin grafts.

AVAILABILITY OF DATA AND MATERIALS

The data presented in this study are available on reasonable request from the corresponding author.

AUTHOR CONTRIBUTIONS

MW and WJGH—designed the research study. MW—performed the data collection and data analysis, wrote the manuscript. AC and WJGH—provided help and advice on assembly of data. BT, AP, AC, DJ, and WJGH—contributed to editorial changes in the manuscript.

ETHICS APPROVAL AND CONSENT TO PARTICIPATE

This study was approved by the Institutional Review Board of Tulane University Biomedical IRB (IRB Reference No. 2022-1714). Informed consent was waived by the institutional review board because this was a retrospective study. Patient information was anonymized before the analysis.

ACKNOWLEDGMENT

The authors wish to thank Scott Bailey, Department of Urology, Tulane University School of Medicine, for editing and

preparing this manuscript.

FUNDING

This research received no external funding.

CONFLICT OF INTEREST

The authors declare no conflict of interest.

REFERENCES

- [1] Keyes EL. Diseases of the penis-anatomy-anomalies-injuries-inflammations. In *Urology* (pp. 637–641). 1st edn. Appleton & Co.: New York, NY. 1917.
- [2] Pekala KR, Pelzman D, Theisen KM, Rogers D, Maganty A, Fuller TW, *et al.* The prevalence of penile cancer in patients with adult acquired buried penis. *Urology*. 2019; 133: 229–233.
- [3] Rybak J, Larsen S, Yu M, Levine LA. Single center outcomes after reconstructive surgical correction of adult acquired buried penis: measurements of erectile function, depression, and quality of life. *The Journal of Sexual Medicine*. 2014; 11: 1086–1091.
- [4] Centers for Disease Control and Prevention. Adult obesity facts. 2022. Available at: <https://www.cdc.gov/obesity/data/adult.html> (Accessed: 01 May 2023).
- [5] Kara Ö, Teke K, Çiftçi S, Üstüner M, Uslubaş AK, Bosnalı E, *et al.* Buried penis in adults as a complication of circumcision: surgical management and long-term outcomes. *Andrologia*. 2021; 53: e13921.
- [6] Alsaif A, Karam M, Hayre A, Abul A, Aldubaikhi A, Kahlar N. Full thickness skin graft versus split thickness skin graft in paediatric patients with hand burns: systematic review and meta-analysis. *Burns*. 2023; 49: 1017–1027.
- [7] Fuller TW, Theisen K, Rusilko P. Surgical management of adult acquired buried penis: escutcheonectomy, scrotoectomy, and penile split-thickness skin graft. *Urology*. 2017; 108: 237–238.
- [8] Monn MF, Socas J, Mellon MJ. The use of full thickness skin graft phalloplasty during adult acquired buried penis repair. *Urology*. 2019; 129: 223–227.
- [9] Black PC, Friedrich JB, Engrav LH, Wessells H. Meshed unexpanded split-thickness skin grafting for reconstruction of penile skin loss. *Journal of Urology*. 2004; 172: 976–979.
- [10] Falcone M, Sokolakis I, Capogrosso P, Yuhong Y, Salonia A, Minhas S, *et al.* What are the benefits and harms of surgical management options for adult-acquired buried penis? A systematic review. *BJU International*. 2023; 131: 8–19.

How to cite this article: Melissa Wong, Bryan Torres, Aadit Patel, Abigail Chaffin, David Jansen, Wayne JG Hellstrom. Patients with adult-acquired buried penis and their surgical management: a single-center study. *Journal of Men's Health*. 2023; 19(11): 11-15. doi: 10.22514/jomh.2023.112.