

Effect of immunostimulating *Limosilactobacillus* strain in rats with trinitrobenzenesulfonate (TNBS)-induced colitis

**Jovanka Lukić^{1*}, Ivana Strahinić¹, Marina Milenković²,
Jelena Begović¹**

¹Laboratory for Molecular Microbiology, Institute of Molecular Genetics and Genetic Engineering, University of Belgrade, Vojvode Stepe 444a, 11010 Belgrade, Serbia

²Department of Microbiology and Immunology, University of Belgrade – Faculty of Pharmacy, Vojvode Stepe 450, 11010, Belgrade, Serbia

*Corresponding author: Jovanka Lukić, e-mail: lukicjovanka@imgge.bg.ac.rs

Abstract

The aim of the study was to test the potential of immunostimulating *Limosilactobacillus fermentum* BGHI14 strain to reduce the damage of colon tissue in rats with 2,4,6-trinitrobenzenesulfonic acid (TNBS)-induced colitis. Wistar rats were treated with *L. fermentum* BGHI14 in the regime of preventive, therapeutic and continuous treatment 22 days prior to and/or 7 days after the administration of TNBS. After sacrifice, the colon tissue samples were taken for RNA isolation, gene expression analysis, histopathological analysis, and malondialdehyde measurement. Judging from the body weights, histopathological scores, malondialdehyde levels and transcription of IL-1 β and Tight junction protein 1 (Tjp-1) coding genes, preventive and therapeutic treatment proved to be the most protective in the applied conditions. On the other hand, continuous treatment did not affect the intensity of tissue damage. Considering these results, we discussed the possible mechanisms which might stand behind the protective action of immunostimulating probiotic bacteria in the case of mucosal barrier damage.

Key words: colitis, *Limosilactobacillus fermentum*, probiotic, pro-inflammatory cytokines, lipid peroxidation

doi.org/10.5937/arhfarm73-46399

Introduction

Gut barrier dysfunction is a major cause of digestive tract inflammations designated as inflammatory bowel diseases (IBD). Crohn's disease (CD) is a highly prevailing inflammatory disease and commonly involves the ileal part of the gastrointestinal (GI) tract (1,2). At the moment there is enough evidence showing that CD weakens acute immune response, leading to defective clearance of luminal bacteria that invade the intestinal tissue and cause chronic inflammation (3). One of the simplest experimental models of CD is 2,4,6-trinitrobenzenesulfonic acid (TNBS)-induced colitis that develops after intracolonic TNBS administration. Although the TNBS model results only in tissue damage in the colon, due to the nature of inflammatory lesions that include the entire intestinal wall, it corresponds to CD in humans (4, 5). Gut wall necrosis induced by TNBS leads to the entrance of luminal microorganisms in the colonic tissue and mounting of acute inflammatory response. Accordingly, extermination of intestinal microbiota has been able to prevent the progression of TNBS colitis (5, 6).

Strategies developed until now have been aimed at modulating the immune response in order to maintain remission in Crohn's disease (7). Lactobacilli have been tested in IBD in the context of the prolongation of remission after surgery (8). However, in some CD patients, the incidence of relapse was higher after treatment with probiotic lactobacilli (9). Ambiguous results obtained with lactobacilli in IBD treatment impose the need for a comprehensive examination of mechanisms of action of probiotic lactobacilli (10).

Limosilactobacillus fermentum is the heterofermentative lactic acid bacterium present in foods, milk of mammals, vaginal tract and GI tract of new-borns and children (11, 12, 13, 14, 15). Although it does not belong to the indigenous intestinal microbiota (16), different *L. fermentum* strains exhibit various probiotic effects on the host (17, 18). In our previous study, we followed the reaction of healthy colon tissue of rats after ingestion of *L. fermentum* BGHI14 (19). In this study, we tested the effect of the same strain in the late phase of acute TNBS-induced colitis. In addition, due to the immune response of colon tissue to BGHI14, as reported in our previous work, we have chosen to apply TNBS three weeks after the start of BGHI14 treatment, because we expect that at this point transient immune reaction has already withdrawn.

Materials and methods

Bacterial preparation

The strain *Limosilactobacillus fermentum* BGHI14 isolated from breast-fed neonate faeces was used in the study. The bacteria were cultivated in MRS medium (Oxoid Limited, Hampshire, United Kingdom) at 37 °C anaerobically (19). For animal treatment, 10 ml of fresh overnight bacterial culture (with approximately 10¹⁰ colony forming unites (CFU)/ml) was pelleted, washed in saline and resuspended in 1 ml of sterile 11 % skimmed milk (Mlekara Subotica, Serbia).

Experimental animals

Female Wistar rats, 5-6 weeks of age, weighing 140 ± 10 g, were purchased from the Farm of Military Medical Academy, Belgrade, and for experimental purposes were housed in the animal facility of the Faculty of Pharmacy, University of Belgrade. The research was approved by the Ethical Committee of the Faculty of Pharmacy, University of Belgrade, and experimental procedures were performed in accordance with the institutional guidelines on care for experimental animals No. 2/09. A veterinarian inspected the animals once a week, checking for distress or existence of physical injuries.

Study design

The experimental design is shown in Figure 1. Animals were grouped in five treatment regimens (nine per group) and treated daily by oral gavage using a stainless steel feeding tube (18 G, Instech Solomon, Plymouth Meeting, PA, USA). Two groups of animals were treated with BGHI14 suspension in skimmed milk for 21 days, while the remaining three groups received skimmed milk. On day 22 of treatment onset, rats from two BGHI14-treated and two milk fed groups were administered TNBS through the anus, as described in our previous paper (19). The remaining group was administered phosphate buffered saline (PBS). On the day of colitis induction, two colitic groups, one BGHI14-treated and one milk fed group, had the treatment changed so that for BGHI14-treated rats' bacterial treatment was stopped and feeding was continued with milk (preventively treated colitic rats), and for milk receiving rats BGHI14 treatment was started (therapeutically treated colitic rats). For rats from the remaining groups, the same treatment was continued (colitic continuously BGHI14-treated, colitic controls, and healthy controls). Animals were fed for the following seven days and were sacrificed

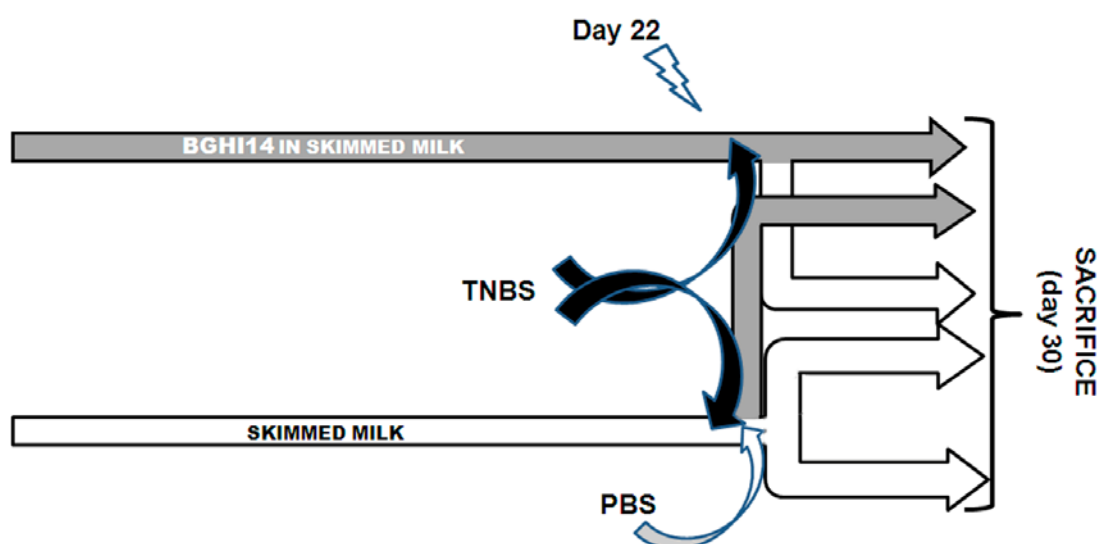


Figure 1. Study design

Slika 1. Dizajn studije

using increasing CO₂ concentration on day 30 from the beginning of the experiment. Colons were sampled for histological analysis, RNA isolation and biochemical assay. Additionally, colonic content was sampled for total DNA isolation.

Histological processing of tissue

Colon tissue was processed for histopathological analysis as described in our previous paper (19). Paraffin blocks were prepared using a rotary microtome (RM2125RT, Leica Microsystems, Wetzlar, Germany). Damage and inflammation in the colon tissue were estimated semi-quantitatively using the following criteria: crypt and submucosal muscle layer hypertrophy, presence of immune cells in underlying fat tissue, presence and type of immune cell infiltrate in submucosal loosely organized tissue and in submucosal muscles, crypt damage, submucosal widening, absorptive surface decrease and necrotic tissue presence. Histological sections were photographed using NIS-Elements Microscope Imaging Software 2.3 (Nikon Instruments Inc., Tokyo, Japan).

RNA isolation

The isolation of RNA was performed according to the protocol by Chomzynski & Sacchi (20), with modifications described in our previous paper (19). Shortly, tissue was pulverized in liquid nitrogen and resuspended in denaturing solution containing guanidine thiocyanate as denaturing agent. Repeated acid phenol, pH 4, extractions were performed for protein and DNA contamination removal. Centrifugation steps at $15\,000 \times g$, + 4 °C were performed in an Eppendorf 5417R centrifuge (Eppendorf). RNA concentrations were measured spectrophotometrically using a Nanovue Plus Spectrophotometer (GE Healthcare, Little Chalfont, United Kingdom).

Quantitative real-time PCR (qRT-PCR)

Reverse transcription (RT) reaction was set according to the instructions of the enzyme manufacturer (Thermo Scientific). Random hexamers, RNase inhibitor and dNTP set were purchased from Thermo Scientific. All reaction steps were performed in the Gene AmpR System 2700 apparatus (Applied Biosystem). Controls without reverse transcriptase were included for a DNA contamination check. Complementary cDNA obtained in reverse transcription was used as a template in a qPCR reaction performed in the 7500 Real Time System apparatus (Applied Biosystems). All primers used were from Invitrogen (Paisley, United Kingdom) and described in our previous paper (19). KAPA SYBR FAST Universal Master Mix (KAPA Biosystems) was used, and two-step reaction conditions were as follows: 3 min at 95 °C, 40 cycles with 15 s at 95 °C and 60 s at 60 °C. For relative quantification, tenfold cDNA dilutions were used.

Lipid peroxidation assay

The level of oxidative stress in rats' colon tissue was determined as the malondialdehyde (MDA) level in tissue homogenates. The test was done according to

McCluskey *et al.* (21), with modifications. Colon tissue was pulverized in liquid nitrogen and next homogenized as a 10 % suspension in 1.15 % KCl in glass homogenizers (Sigma-Aldrich, St. Louis, Missouri, USA). Immediately after homogenization, 200 μ l of homogenate was mixed with 600 μ l of solution containing 0.375 % TBA (Sigma), 0.25 M HCl and 15 % solution of trichloroacetic acid (TCA). The mixture was incubated for 15 min at 95 °C, cooled, centrifuged shortly at 1 000 $\times g$ (5417R, *Eppendorf centrifuge*, Hamburg, Germany), + 4 °C, and supernatant absorbance was determined at 532 nm using spectrophotometer Ultrospec 3300 pro (Amersham Bioscience, Piscataway, New Jersey, USA). As per the MDA standard, 1,1,3,3-tetramethoxypropane (Sigma-Aldrich) in the concentration range 0.1-1 μ M was used.

Statistical analysis and data presentation

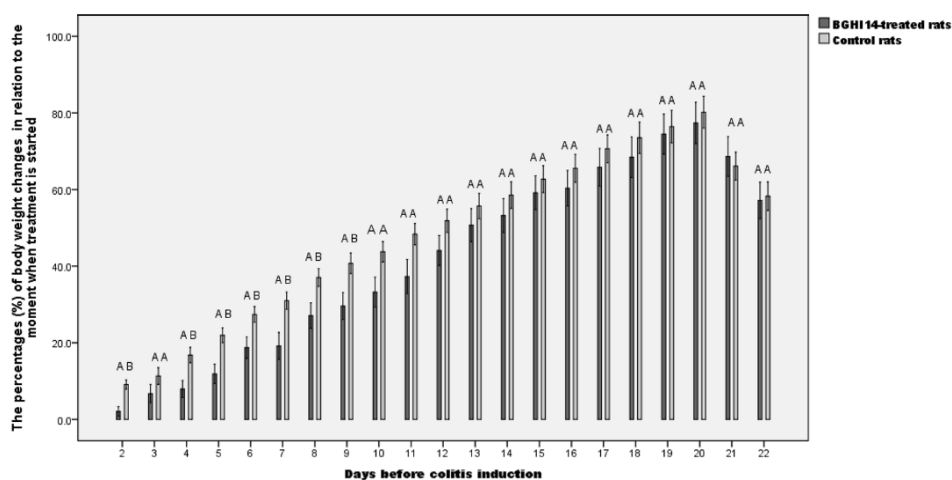
The results are presented graphically, using bar charts representing the mean value of the group with standard errors. Differences between groups were considered to be statistically different if the p value was lower than 0.05 ($p < 0.05$). Statistical differences are marked above bars, with different letters representing statistical significance between groups. Data were analyzed using the Mann-Whitney test. All statistical analyses and graph drawing were performed in SPSS 18.0 software for Windows.

Results

Body weight of rats during treatment

Percentages of body weight changes in relation to the moment when the treatment started and to the moment of colitis induction are shown in Figure 2. Prior to colitis induction, significantly lower percentages of body mass changes in BGHI14-treated rats compared to untreated rats were observed on days 2nd, 4th, 5th, 6th, 7th, 8th and 9th from the feeding onset. After colitis induction, reduction of weights was detected in colitic compared to healthy rats, with statistical significance reached on days 3 and 4 for preventively treated rats, days 2, 3, 4 and 6 for therapeutically treated rats, and all days until sacrifice for continuously treated and control colitic rats. Additionally, on day 7 from TNBS instillation, continuously treated rats demonstrated a significantly lower percentage of body weight changes relative to preventively treated rats.

A



B

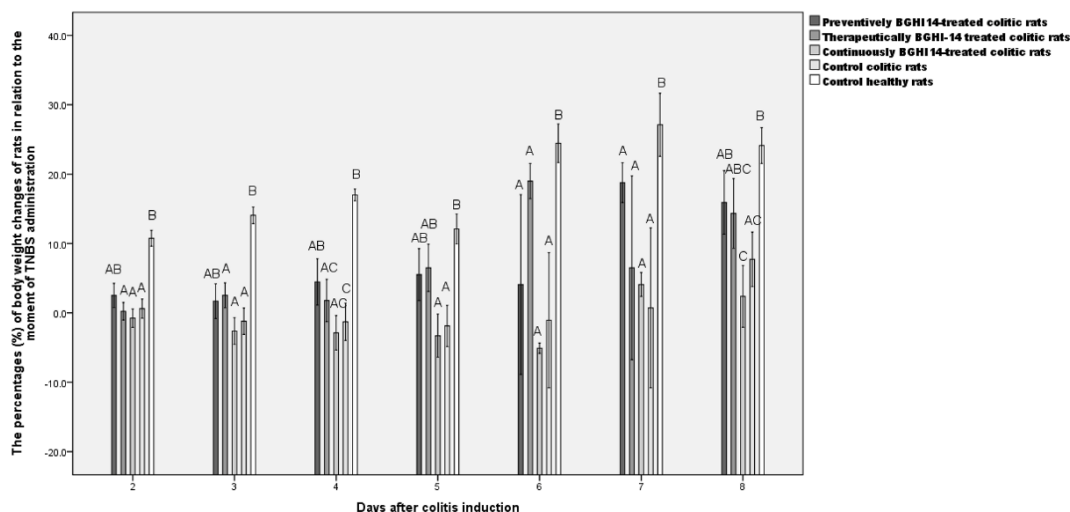


Figure 2. The percentages of body weight changes of rats treated with *Limosilactobacillus fermentum* BGHI14 and of control rats (A) before colitis induction in relation to the moment when treatment is started; (B) after colitis induction in relation to the moment of TNBS administration. Different letters above the bars indicate statistically significant difference between the treatments (n = 9).

Slika 2. Procenti promene telesne težine pacova tretiranih sa *Limosilactobacillus fermentum* BGHI14 i kontrolnih pacova (A) pre indukcije kolitisa u odnosu na početak tretmana; (B) posle indukcije kolitisa u odnosu na trenutak primene TNBS. Različita slova iznad grafikona ukazuju na statistički značajne razlike između tretmana (n = 9).

Histological scoring of damage and inflammation in colon tissue

Colitis induction resulted in a statistically significant increase in pathohistological scores in the late acute phase of disease (Figure 3). Preventively BGHI14-treated rats showed significantly lower scores compared to continuously treated rats, though the significance is marginal ($p = 0.05$). In colitic rats, remains of necrotic tissue were evident, as well as absorptive surface decrease, crypt and submucosal muscle hypertrophy, and transmural infiltrates of polymorphonuclear cells, monocytes and eosinophils (Figure 4).

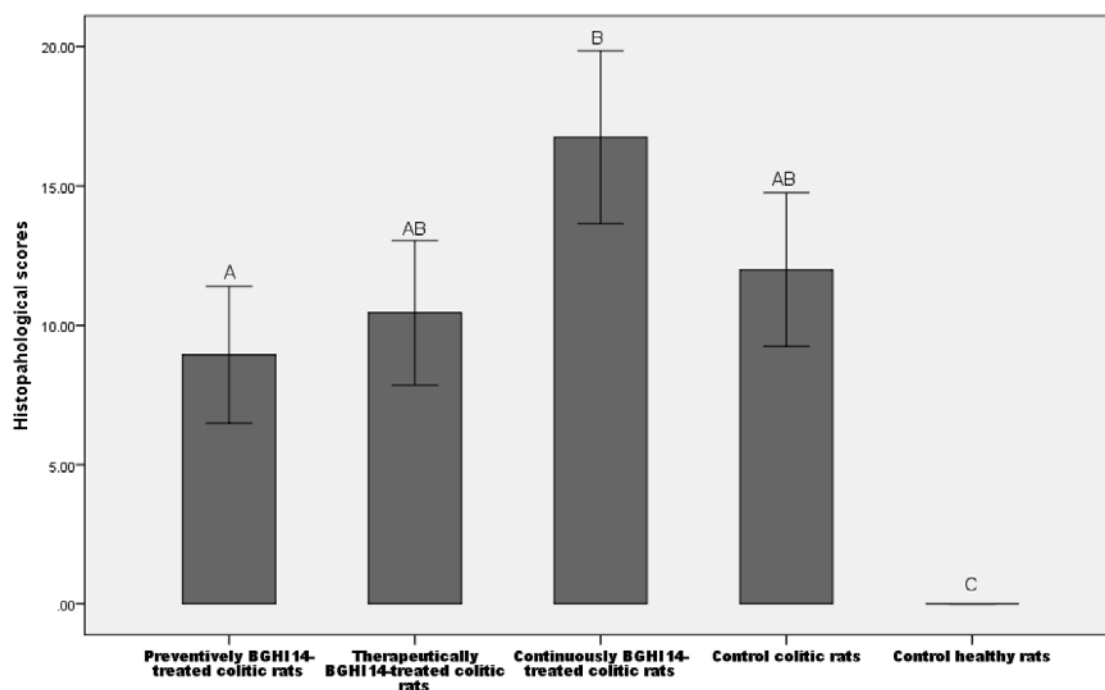


Figure 3. Pathohistological scores measuring damage and inflammation in colon tissue of colitic and healthy rats. Different letters above the bars indicate statistically significant difference between the treatments ($n = 9$).

Slika 3. Patohistološki rezultati merenja oštećenja i zapaljenja u tkivu debelog creva pacova sa kolitisom i zdravih pacova. Različita slova iznad grafikona ukazuju na statistički značajne razlike između tretmana ($n = 9$).

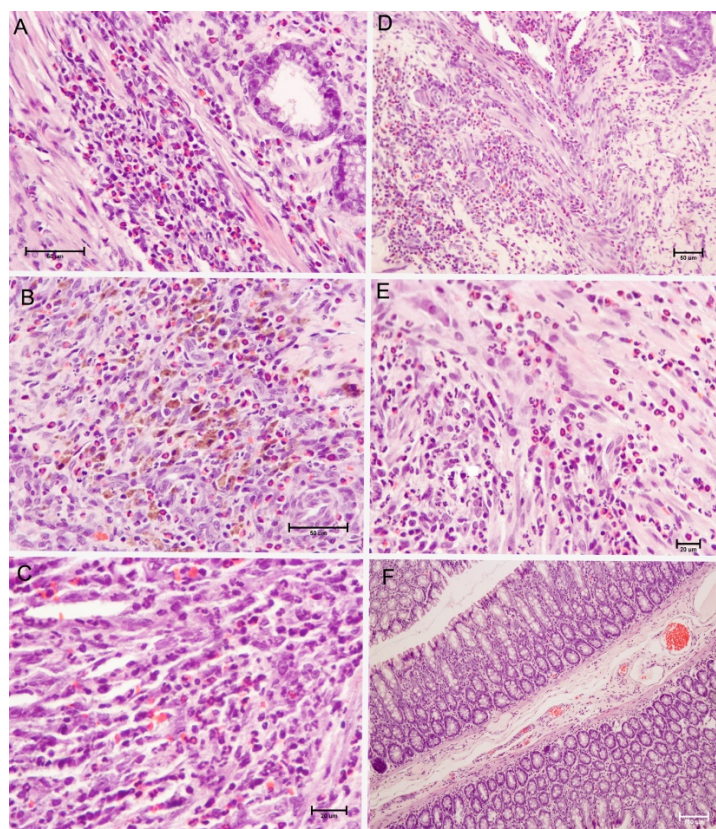


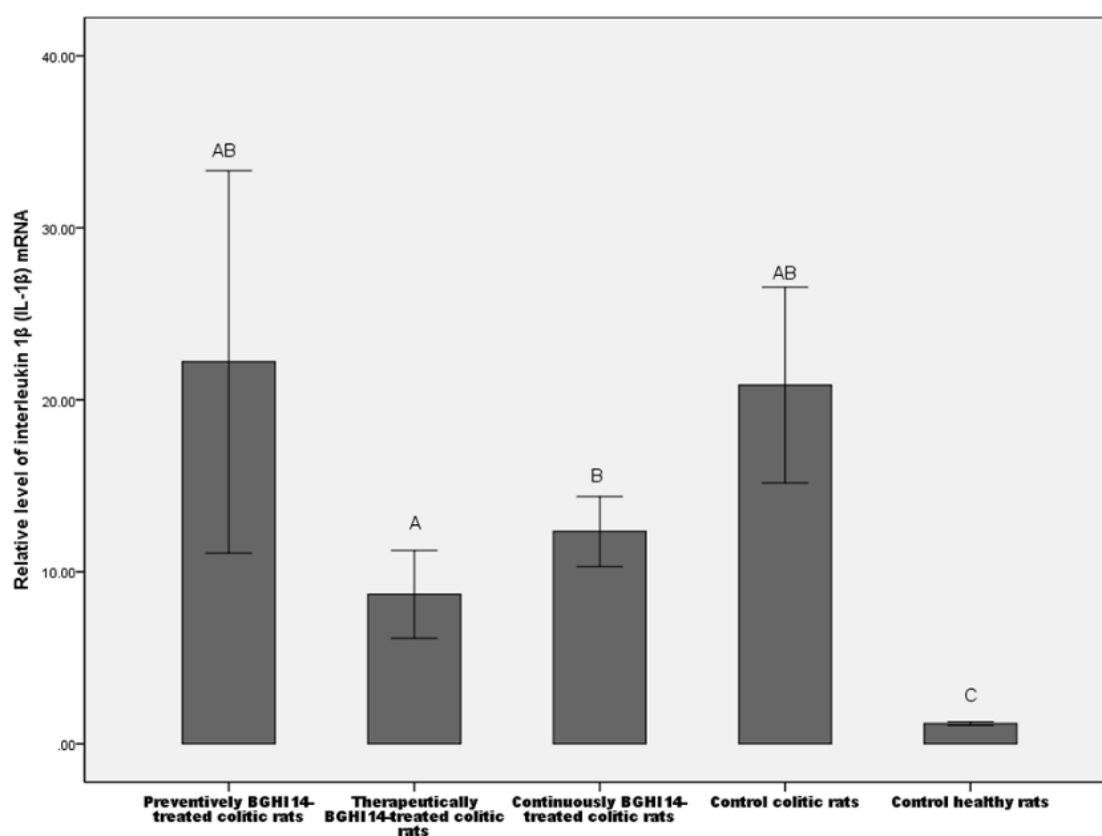
Figure 4. Cross sections of colon tissue: (A) (400×) mononuclear and neutrophil infiltrate of mucosal muscle layer in a colon of preventively treated colitic rats; (B) (400×) neutrophils, mononuclear cells and eosinophils in submucosal infiltrate in a therapeutically treated colitic rat; additionally macrophages with haemoglobin content are visible indicating abundant bleeding in displayed area; (C) (600×) and (D) (200×) inflammation of submucosal muscles with mononuclear cells and sporadic neutrophils and eosinophils in a colon of continuously treated rats; (E) (400×) section of tissue of control colitic rats depicting monocytes, neutrophils and eosinophils in mucosal muscles and in submucosa; (F) (100×) tissue of a healthy control rat.

Slika 4. Poprečni presecci tkiva debelog creva: (A) (400×) mononuklearni i neutrofilni infiltrat mukoznog mišićnog sloja u debelom crevu preventivno lečenih pacova sa kolitisom; (B) (400×) zastupljenost neutrofila, mononuklearnih ćelija i eozinofila u submukoznom infiltratu kod terapeutski tretiranih pacova sa kolitisom; dodatno vidljivi makrofagi sa sadržajem hemoglobina ukazuju na obilno krvarenje u prikazanom području; (C) (600×) i (D) (200×) zapaljenje submukoznih mišića sa mononuklearnim ćelijama i sporadičnim neutrofilima i eozinofilima u debelom crevu stalno tretiranih pacova; (E) (400×) presek tkiva kontrolnih pacova sa kolitisom koji prikazuje monocite, neutrofile i eozinofile u mukoznim mišićima i u submukozi; (F) (100×) tkivo zdravog kontrolnog pacova.

Transcription of genes in colon tissue

Transcription of genes coding for molecular markers of inflammation (tumour necrosis factor alpha, $TNF\alpha$ and interleukin 1 beta, $IL-1\beta$) and epithelial cell markers (tight junction protein 1, $Tjp1$) in colon tissue was assessed for evaluation of BGHI14 effects in colitic rats. Colitis induction caused a significant increase in $IL-1\beta$ mRNA levels. Among colitic rats, therapeutically BGHI14-treated group showed significantly lower $IL-1\beta$ mRNA levels relative to continuously treated rats (Figure 5A), though very low ($p = 0.046$). On the other hand, $TNF\alpha$ transcription was not changed in late acute phase of TNBS colitis relative to healthy rats, irrespective of the BGHI14 treatment regime (not shown). A statistically significant decrease in $Tjp1$ mRNA level was observed after colitis induction, with the exception of therapeutically BGHI14-treated animals. Moreover, therapeutically treated rats showed significantly higher $Tjp1$ mRNA transcript levels compared to continuously treated ($p = 0.019$) and nontreated ($p = 0.031$) colitic rats (Figure 5B).

A



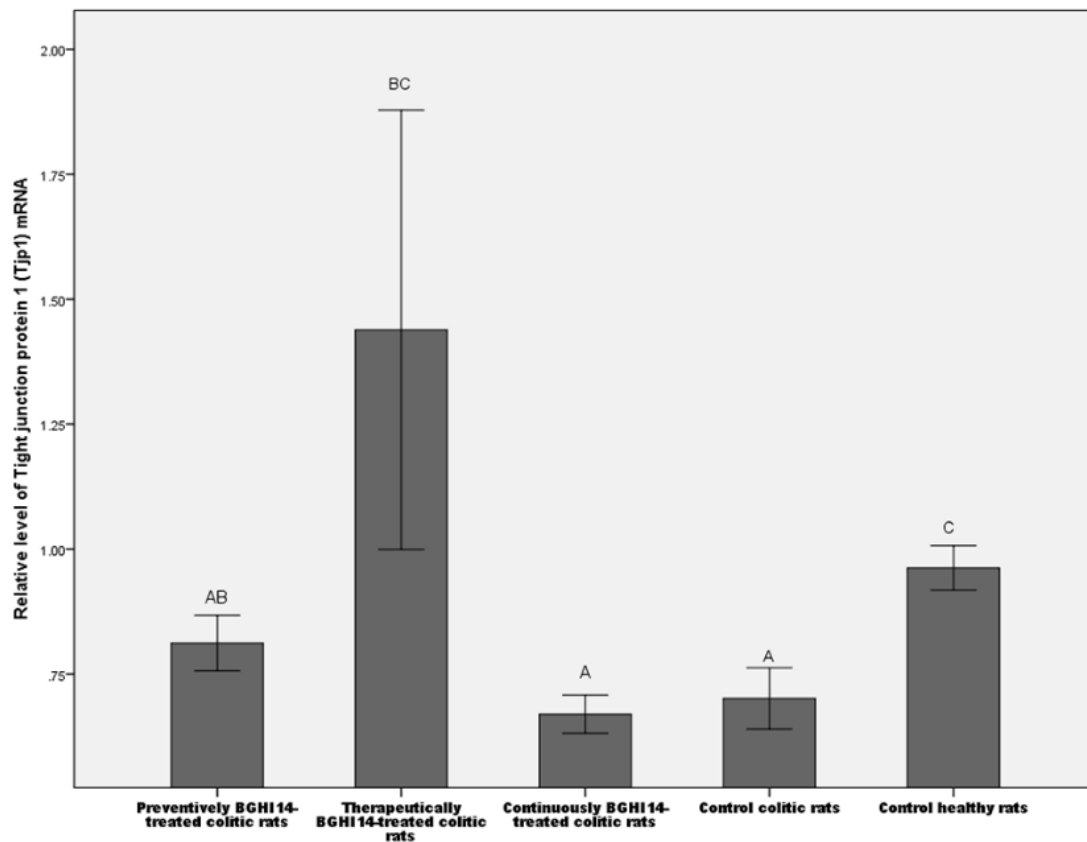
B

Figure 5. Impact of different *Limosilactobacillus fermentum* BGHI14 treatment regimens on mRNA expression of: (A) *IL-1 β* , and (B) *Tjp1* genes in colon tissue of colitic rats. Different letters above the bars indicate statistically significant difference between the treatments (n = 9).

Slika 5. Uticaj različitih režima primene *Limosilactobacillus fermentum* BGHI14 na ekspresiju iRNK: (A) *IL-1 β* i (B) *Tjp1* gena u tkivu debelog creva pacova sa kolitisom. Različita slova iznad grafikona ukazuju na statistički značajne razlike između tretmana (n = 9).

Lipid peroxidation in colon tissue

Levels of lipid peroxidation are presented as the amount of MDA in μ moles per gram of the tissue (Figure 6). TNBS administration did not increase MDA levels seven days after colitis induction. BGHI14 affected lipid peroxidation levels only after therapeutical administration, when a significant decrease of MDA levels was observed compared to control colitic rats (p = 0.04).

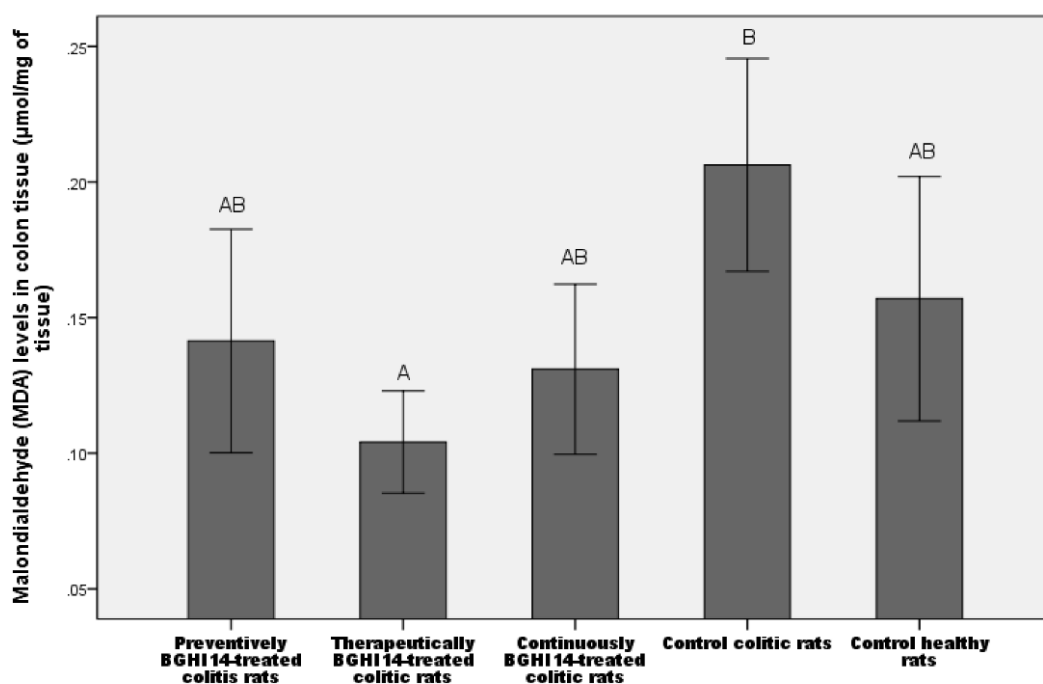


Figure 6. Malondialdehyde (MDA) levels in colon tissue of colitic and healthy rats. Different letters above the bars indicate statistically significant difference between the treatments (n = 9).

Slika 6. Nivo malondialdehida (MDA) u tkivu debelog creva pacova sa kolitisom i zdravih pacova. Različita slova iznad grafikona ukazuju na statistički značajne razlike između tretmana (n = 9).

Discussion

CD occurs as a result of a weakened immune response in the intestinal mucosa to luminal bacteria. Similar mechanisms are responsible for the progression of TNBS-colitis in rats. There is a growing body of evidence reporting positive effect of lactobacilli in the case of TNBS-colitis in animal models (22). We previously demonstrated probiotic potential and immunostimulatory activity of *Limosilactobacillus fermentum* BGHI14 strain (19, 23, 24). The same strain was tested in current research for eventual protection in TNBS-colitis in Wistar rats.

Tracking of the animals' body weights during treatment showed that the preventive and therapeutic treatments were the most effective in alleviating the consequences of the administration of TNBS. Histopathological observations revealed the reduction of damage of the colon tissue only in the case of preventively treated rats. However, therapeutically treated rats showed increased levels of *Tjp1* gene expression compared to untreated and continuously treated colitic rats. Tight junctions are important for the maintenance of intestinal epithelial cell polarization and for preventing the entry of

luminal substances in intestinal tissue (25). We assume that these results reflect the degree of tissue damage that was the least pronounced in the case of therapeutically treated rats. In addition, the level of proinflammatory *IL-1 β* cytokine mRNA was decreased in therapeutically treated animals compared to continuously treated rats, indicating that the therapeutic treatment was the most effective in reducing inflammation. The results obtained in qPCR for therapeutic treatment were also supported by the level of malondialdehyde in the tissue of the colon in colitic rats, which was the lowest in this treatment group. Reactive species produced by phagocytes during inflammation can cause oxidative damage to intestinal tissue (26). However, in our study, colitis induction did not lead to an increase of lipid peroxidation, which implies that other mechanisms might be causing the damage, such as matrix metalloproteinases, as proposed by Schepens et al. (27).

Regardless of the immunostimulating effect of strain BGHI14 in healthy rats, the same strain showed a tendency to decrease the damage of colon tissue in rats with colitis when introduced before or after the induction of disease. Such action of BGHI14 can be explained by referring to the model outlined by Eckman et al. (28). In accordance with this model, the activation of NF- κ B signalling pathway, which is the main pathway that is activated in eukaryotic cells after interaction with microorganisms, has different effects on the progression of damage, depending on whether it is activated in the acute or in the chronic phase of inflammation (28, 29). Epithelial restitution in acute injury could be achieved by nuclear factor kappa B (NF- κ B) activation involving epithelial and myeloid cells (28). However, NF- κ B signalization during the course of existing inflammation would not be beneficial, because epithelial cells have already elevated cytoprotective molecule levels so there is no benefit from additional NF- κ B activation. Moreover, it could lead to the aggravation of disease scores by additionally activating myeloid cells and adaptive immune response. The presence of strain BGHI14 at the moment of induction of damage in therapeutic treatment could lead to the release of cytoprotective factors by epithelial cells and protect against damage. Similarly, in the case of preventive treatment, the level of cytoprotective factors could be increased, making epithelium prepared for the insult that followed. However, in the case of continuous treatment with BGHI14, additional activation of myeloid cells could undo the positive effects that resulted from the synthesis of cytoprotective factors. Similarly to our results, Geier et al. (30) observed no effect of continuous *Lb. fermentum* administration to colitic rats.

To summarize, the presented research has demonstrated beneficial effects of *L. fermentum* BGHI14 in the amelioration of experimental colitis in Wistar rats, when BGHI14 was applied either before or after colitis induction. This was contrasted with the continuous (before and after) administration regime of BGHI14, which did not show any beneficial effects. This study is preliminary in terms of detecting the existence of an effect of BGHI14 in the case of a single experimental model of inflammatory bowel disease (IBD). In order to make the results relevant for eventual clinical application, the inclusion of other IBD models would be needed, along with detailed mechanistic studies to confirm the above provided hypothesis behind the protective effects of BGHI14. In the first place,

future studies should test the degree of activation of myeloid cells, as well as the levels of cytoprotective factors in the intestinal mucosa BGHI14 treated animals, without and with disease induction. Furthermore, the results presented here imply the potential for use of BGHI14 in treatment of other intestinal pathologies, including infections, which would broaden the utilization potential of the tested species.

Acknowledgments

The authors would like to thank Petar Milosavljevic from the Military Medical Academy, Belgrade, Serbia, for photographing and inspecting the histological sections. This work was supported by the Ministry of Education, Science and Technological Development of the Republic of Serbia under Contract No. 451-03-47/2023-01/200042.

Conflicts of interest

The strain *L. fermentum* BGHI14 is deposited in the BCCM/LMG Bacterial Culture Collection, Belgium under patent deposition, and is subject to the license agreement between the Institute of Molecular Genetics and Genetic Engineering, University of Belgrade, Belgrade, Serbia and Invetlab d.o.o. Belgrade, Serbia. The funders had no role in the design of the study; in the collection, analyses, or interpretation of data; in the writing of the manuscript, or in the decision to publish the results. The authors have not declared any conflicts of interest.

References

1. Jagtap G, Niphadkar V. Protective effect of aqueous extract of *Bombax malabaricum* DC on experimental models of inflammatory bowel disease in rats and mice. *Indian J Exp Biol.* 2011;49:343.
2. Sartor B. Mechanisms of disease: pathogenesis of Crohn's disease and ulcerative colitis. *Nat Clin Pract Gastroenterol Hepatol.* 2006;3:390.
3. Hayee B, Rahman Z, Sewell G, Smith M, Segal W. Crohn's disease as an immunodeficiency. *Expert Rev Clin Immunol.* 2010;6:585.
4. Dithel G, Vasina V, Barbara G, de Ponti F. Animal models of chemically induced intestinal inflammation: predictivity and ethical issues. *Pharmacol Ther.* 2013;139:71.
5. Llopis M, Antolín M, Guarner F, Salas, Malagelada R. Mucosal colonization with *Lactobacillus casei* mitigates barrier injury induced by exposure to trinitrobenzene sulphonic acid. *Gut.* 2005;54:955.
6. Guarner F, Malagelada R. Role of bacteria in experimental colitis. *Best Pract Res Clin Gastroenterol.* 2003;17:793.
7. Corte C, Saxena P, Tattersall S, Selinger C, Leong RW. When to use biological agents in inflammatory bowel disease. *J Gastroenterol Hepatol.* 2012;27:1141.

8. Farnworth R. The evidence to support health claims for probiotics. *J Nutr.* 2008;138:1250S.
9. Seksik P, Dray X, Sokol H, Marteau P. Is there any place for alimentary probiotics, prebiotics or synbiotics, for patients with inflammatory bowel disease? *Mol Nutr Food Res.* 2008;52:906.
10. Prantera C, Scribano L, Andreoli A, Luyi C. Ineffectiveness of probiotics in preventing recurrence after curative resection for Crohn's disease - a randomized controlled trial with *Lactobacillus GG*. *Gut.* 2002;51:405.
11. Jiménez E, Langa S, Martín V, Arroyo R, Martín R, Fernández L, et al. Complete genome sequence of *Lactobacillus fermentum* CECT 5716, a probiotic strain isolated from human milk. *J Bacteriol.* 2010;192:4800.
12. Kaewnopparat S, Dangmanee N, Kaewnopparat N, Srichana T, Chulasiri M, Settharaksa S. In vitro probiotic properties of *Lactobacillus fermentum* SK5 isolated from vagina of a healthy woman. *Anaerobe.* 2013;22:6.
13. Mikelsaar M, Zilmer M. *Lactobacillus fermentum* ME-3 - an antimicrobial and antioxidative probiotic. *Microb Ecol Health Dis.* 2009;21:1.
14. Park H, Lee Y, Moon E, Seok H, Cho A, Baek W, et al. Immunoenhancing effects of a new probiotic strain, *Lactobacillus fermentum* PL9005. *J Food Prot.* 2005;68:571.
15. Fazeli R, Hajimohammadali M, Moshkani A, Samadi N, Jamalifar H, Khoshayand R, et al. Aflatoxin B1 binding capacity of autochthonous strains of lactic acid bacteria. *J Food Prot.* 2009;72:189.
16. Walter J. Ecological role of lactobacilli in the gastrointestinal tract: implications for fundamental and biomedical research. *Appl Environ Microbiol.* 2008;74:4985.
17. Dinić M, Lukić J, Djokić J, Milenković M, Strahinić I, Golić N, et al. *Lactobacillus fermentum* postbiotic-induced autophagy as potential approach for treatment of acetaminophen hepatotoxicity. *Front Microbiol.* 2017;8:594.
18. Dinić M, Herholz M, Kačarević U, Radojević D, Novović K, Đokić J, et al. Host-commensal interaction promotes health and lifespan in *Caenorhabditis elegans* through the activation of HLH-30/TFEB-mediated autophagy. *Aging (Albany NY).* 2021;13(6):8040-8054.
19. Lukic J, Strahinic I, Milenkovic M, Golic N, Kojic M, Topisirovic L, et al. Interaction of *Lactobacillus fermentum* BGHI14 with rat colonic mucosa: implications for colitis induction. *Appl Environ Microbiol.* 2013;79:5735.
20. Chomczynski P, Sacchi N. The single-step method of RNA isolation by acid guanidinium thiocyanate-phenol-chloroform extraction: twenty-something years on. *Nat Protoc.* 2006;1:581.
21. McCluskey D, Sava D, Harbison C, Muro-Cacho A, Giffe T, Ping X, et al. Hepatoprotective effects of select water-soluble PARP inhibitors in a carbon tetrachloride model. *Int J Crit Illn Inj Sci.* 2011;1:97.
22. Daniel C, Poiret S, Godercourt D, Dennin V, Leyer G, Pot B. Selecting lactic acid bacteria for their safety and functionality by use of a mouse colitis model. *Appl Environ Microbiol.* 2006;72:5799.
23. Veljović K, Dinić M, Lukić J, Mihajlović S, Tolinački M, Živković M, et al. Promotion of early gut colonization by probiotic intervention on microbiota diversity in pregnant sows. *Front Microbiol.* 2017;8:2028.
24. Golić N, Veljović K, Popović N, Djokić J, Strahinić I, Mrvaljević I, et al. In vitro and in vivo antagonistic activity of new probiotic culture against *Clostridium difficile* and *Clostridium perfringens*. *BMC Microbiol.* 2017;17(1):108.

25. Bruewer M, Luegering A, Kucharzik T, Parkos A, Madara L, Hopkins M, et al. Proinflammatory cytokines disrupt epithelial barrier function by apoptosis-independent mechanisms. *J Immunol.* 2003;171:6164.
26. Rochat T, Bermúdez-Humarán L, Gratadoux J, Fourage C, Hoebler C, Corthier G, et al. Anti-inflammatory effects of *Lactobacillus casei* BL23 producing or not a manganese-dependant catalase on DSS-induced colitis in mice. *Microb Cell Fact.* 2007;6:22.
27. Schepens A, Vink C, Schonewille J, Roelofs M, Brummer J, van der Meer R, et al. Supplemental antioxidants do not ameliorate colitis development in HLA-B27 transgenic rats despite extremely low glutathione levels in colonic mucosa. *Inflamm Bowel Dis.* 2011;17:2065.
28. Eckmann L, Nebelsiek T, Fingerle A, Dann M, Mages J, Lang R, et al. Opposing functions of IKK β during acute and chronic intestinal inflammation. *Proc Natl Acad Sci U S A.* 2008;105:15058.
29. HuaZhang A, Cheng Q, XueTao C. Regulation of Toll-like receptor signaling in the innate immunity. *Sci China Life Sci.* 2010;1:34.
30. Geier S, Butler N, Giffard M, Howarth S. Prebiotic and symbiotic fructooligosaccharide administration fails to reduce the severity of experimental colitis in rats. *Dis Colon Rectum.* 2007;50:1061.

Efekat imunostimulišućeg soja roda *Limosilactobacillus* kod pacova sa kolitisom izazvanim trinitrobenzensulfonatom (TNBS)

**Jovanka Lukić^{1*}, Ivana Strahinić¹, Marina Milenković²,
Jelena Begović¹**

¹ Grupa za interakcije probiotika i mikrobiote sa domaćinom, Laboratorija za molekularnu mikrobiologiju, Institut za molekularnu genetiku i genetičko inženjerstvo, Univerzitet u Beogradu, Vojvode Stepe 444a, 11010 Beograd, Srbija

² Katedra za mikrobiologiju i imunologiju, Univerzitet u Beogradu – Farmaceutski fakultet, Vojvode Stepe 450, 11010 Beograd, Srbija

*Autor za korespondenciju: Jovanka Lukić, e-mail: lukicjovanka@imgge.bg.ac.rs

Kratak sadržaj

Cilj ovog istraživanja je bio da se ispita potencijal imunostimulišućeg soja *Limosilactobacillus fermentum* BGHI14 da smanji oštećenje tkiva debelog creva kod pacova sa kolitisom izazvanim 2,4,6-trinitrobenzensulfonskom kiselinom (TNBS). Pacovi Wistar soja su tretirani sojem *L. fermentum* BGHI14 u režimu preventivnog, terapijskog i kontinuiranog tretmana 22 dana pre i/ili 7 dana nakon primene TNBS. Nakon žrtvovanja, uzorci debelog creva su sakupljeni za izolaciju RNK, analizu ekspresije gena, histopatološke analize i merenje malondialdehida. Na osnovu telesnih težina pacova, histopatoloških rezultata, nivoa malondialdehida i transkripcije IL-1 β citokina i proteina tesnih međucelijskih veza (Tjp-1), preventivni i terapijski tretman su se pokazali kao najefikasniji u primenjenim uslovima. S druge strane, kontinuirano lečenje nije uticalo na intenzitet oštećenja tkiva. Uzimajući u obzir ove rezultate, razmotreni su mogući mehanizmi koji stoje iza zaštitnog delovanja imunostimulišućih probiotičkih bakterija u slučaju oštećenja mukozne barijere.

Ključne reči: kolitis, *Limosilactobacillus fermentum*, probiotik, pro-inflamatorni citokini, lipidna peroksidacija
