



# Rare Benign Median Nerve Angiogenetic Lipofibromatous Hamartoma: A Case Report

Talak Doddabasappa Mruthyunjaya,<sup>1</sup> Harish Ugrappa,<sup>1</sup> Bharathkrishna Sanchi,<sup>1</sup> Akash Kumar<sup>1</sup>

## Abstract

Only a few cases of lipofibromatous hamartoma (LFH) of the median nerve have been described in the literature. LFH is a rare and low growing benign fibro-fatty tumour. It is characterised by the proliferation of mature adipocytes within the epineurium and the perineurium of the peripheral nerves. The median nerve is most frequently affected in the upper extremities. Carpal tunnel syndrome, paraesthesia, numbness and pain are frequently the results of involvement of the median nerve. In presented case, in addition to fibrolipoma, there was also new blood vessel formation noted, which was attributed to the chronicity of the lesion. Diagnosis was missed by ultrasound and MRI due to the presence of blood vessels. Histopathological diagnosis was confirmed. Surgical treatment with carpal tunnel release and neurolysis were performed. This resulted in favourable outcome in 3 months.

**Key words:** Lipofibromatous hamartoma (LFH); Median nerve; Angiogenesis; Carpal tunnel syndrome; Short tau inversion recovery (STIR).

1. Department of Orthopaedics, Sri Siddhartha Institute of Medical Sciences and Research Centre, T Begur, Bangalore Rural, Karnataka, India.

Correspondence:  
AKASH KUMAR  
akasha856@gmail.com

## ARTICLE INFO

Received: 25 September 2023  
Revision received: 28 November 2023  
Accepted: 29 November 2023

## Introduction

The condition known as lipofibromatous hamartoma (LFH) is characterised by the widespread infiltration of peripheral nerves by infrequent fibrous and adipose tissues. Emmett referred to this tissue development as a hamartoma.<sup>1</sup> Although the specific cause of LFH is still unclear, often proposed aetiology include congenital malformation and trauma.<sup>2</sup> The median nerve is primarily affected by LFH in 80 % of cases, however studies have also included the buccinators, sciatic, plantar, superficial peroneal and posterior interosseous nerves associated with nerve territory overgrowth of bone and soft tissue accounting for 62 % of cases. It was found that the female-to-male ratio was 2:1 in cases with macrodactyly and 1:1 in those without. The majority of these incidences are in infants, while children and teenagers have them less frequently.<sup>3</sup> Pa-

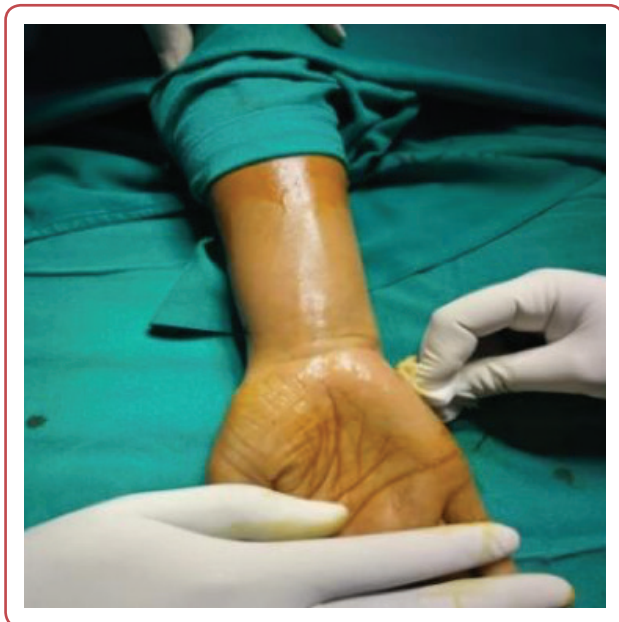tients frequently exhibit symptoms of carpal tunnel syndrome and nerve compression associated with an expanding mass along the median nerve territory in the area between the distal forearm and fingers. Although no exact guidelines have been established for the diagnosis and treatment of LFH, asymptomatic patients may be monitored or treated prophylactically with a carpal tunnel release, either with or without neurolysis, in the case of large tumours.

## Case history

Written informed consent was taken from the patient. A 31-year-old female patient complained

of right wrist swelling for the last seven years, discomfort for the past six months and paraesthesia in the thumb, index and middle finger for the past three months. The swelling, which started off small in size, steadily grew until it covered the whole distal third of the right forearm's flexor area. Her daily tasks were challenging due to the dull aching pain, which was mild to moderate and steadily deteriorated.

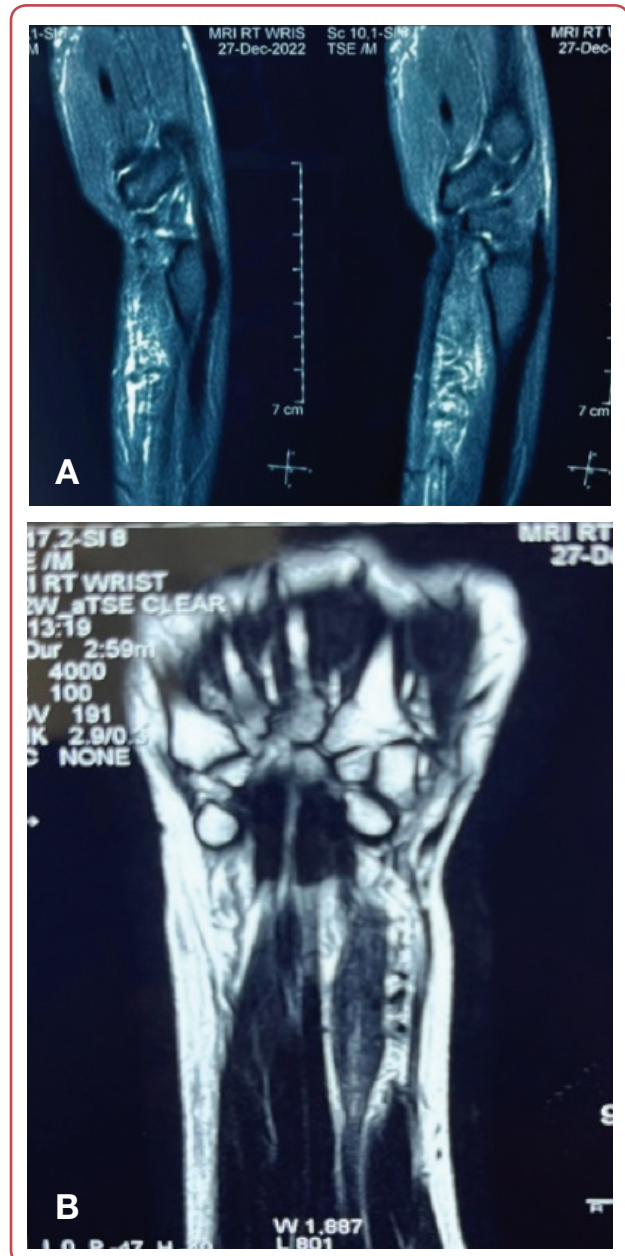
When palpated, the swelling was widespread and reached the distal portion of the forearm from the palmar crease (Figure 1). Swelling ranged in consistency from soft to firm. It wasn't reducible or compressible. The swelling was pulsatile without affecting any vessels. The patient's first three digits also showed motor impairment and sensory loss. Additionally, there was muscle atrophy in the thenar and hypothenar areas. Carpal tunnel syndrome was clinically diagnosed. Ultrasound imaging indicated a soft tissue mass with many blood vessels entangling the median nerve and compressing it. An X-ray of the right wrist and hand revealed a soft tissue enlargement without any bone abnormalities. Nerve conduction tests were not done. According to an ultrasound scan, the median nerve was being compressed by an arteriovenous malformation.



**Figure 1:** Diffuse swelling over the flexor aspect of the right wrist, just below the palmar crease extending up to distal third of forearm

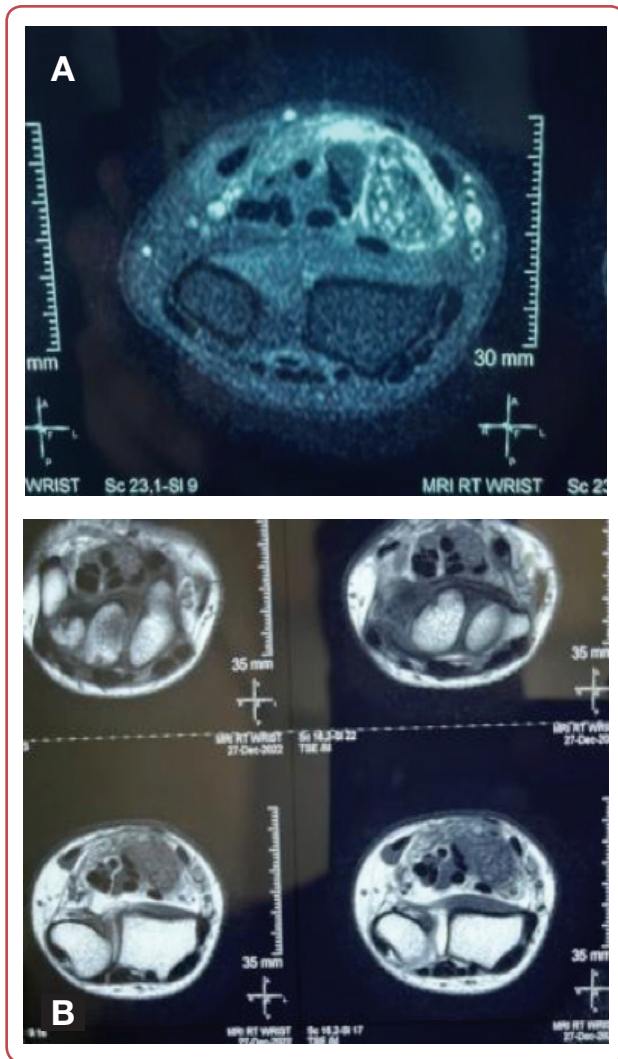
Magnetic resonance imaging (MRI) study of the wrist joint revealed thickened and enlarged segment of the median nerve at the level of the wrist joint with a maintained fibrillar pattern. Fat con-

tent was seen in the lesion on T1 and T2 sequences. MRI scan on sagittal images showed a typical "spaghetti-like" appearance of the thickened median nerve at the level of the wrist (Figure 2: A, B).



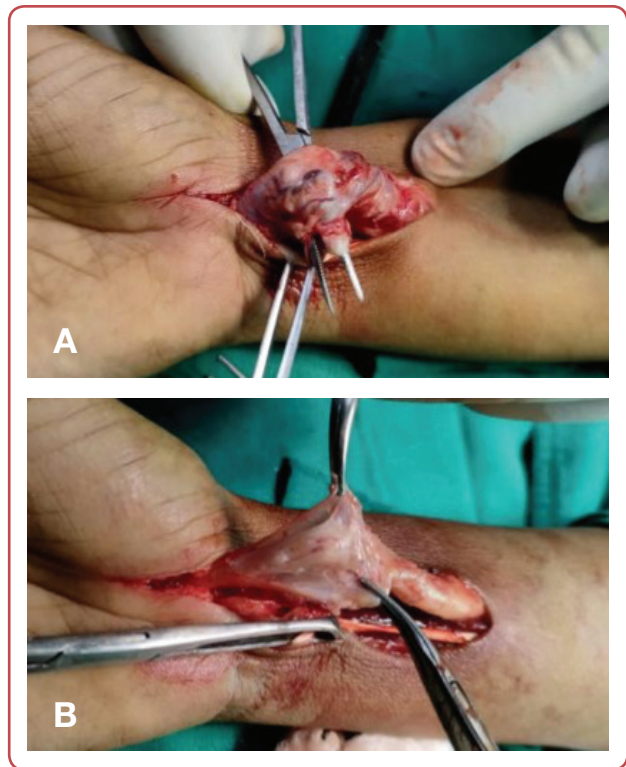
**Figure 2 (A, B):** Magnetic resonance imaging (MRI) scan. Sagittal short tau inversion recovery (STIR) images showing typical "spaghetti-like" appearance of the thickened median nerve at the wrist level. Surrounding oedema was seen due to pressure effects

MRI scan on axial short tau inversion recovery (STIR) images showed a "cable-like" appearance of the nerve fibres at level of the wrist with the thickened nerve and maintained fibrillar pattern. Surrounding oedema was seen due to pressure effects. MRI scan of T1 axial images showed fibrofatty intensity within the enlarged thickened nerve (Figure 3: A, B).

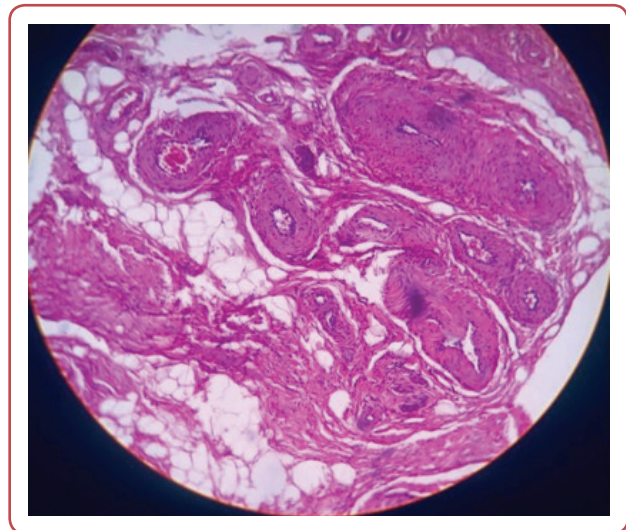


**Figure 3 (A, B):** Magnetic resonance imaging (MRI) scan. Axial sagittal short tau inversion recovery (STIR) images showing “cable-like” appearance of the nerve fibres at level of the wrist with the thickened nerve and maintained fibrillar pattern. Surrounding oedema was seen due to pressure effects. MRI scan of T1 axial images showing fibrofatty intensity within the enlarged thickened nerve

Based on the symptoms and investigations, a tentative diagnosis of “space occupying lesion causing severe carpal tunnel syndrome of right median nerve” was determined. Carpal tunnel release surgery was scheduled under general anaesthesia, placed tourniquet on the arm. The skin was cut off to remove the swelling. The distal section of the median nerve was discovered to be thickened and swollen intraoperatively. Multiple engorged veins were seen entangling the nerve (Figure 4A). After the tumour was debulked, the thickened median nerve was subjected to fascicular neurolysis (Figure 4B). It was decided to send a tissue biopsy for histological analysis. The histological analysis indicated mature adipose tissue and fibro-collagenous tissue infiltrating interlacing fas-



**Figure 4 (A, B):** Intra-operative view of the enlarged right median nerve with fibrofatty proliferation and a cluster of entangled blood vessels and intra-operative view of neurolysis of the right median nerve



**Figure 5:** Histopathology of the tissue biopsy showed interlacing nerve fascicles infiltrated by adipose tissue and fibrous tissue. Numerous thickened blood vessels were seen

cicles of nerve bundles in extra neuronal diffuse LFH. Additionally, several thickened blood vessels were seen (Figure 5). This supported the diagnosis of angiogenetic LFH of the median nerve. After a three months of following up, patient restored the sensory and muscular strength in the right thumb, index and middle finger.

## Discussion

A rare and benign fibro-fatty tumour called a LFH is characterised by the growth of mature adipocytes inside the peripheral nerves epineurium and perineurium. Although the exact aetiology of LFH is unknown, the great majority of the cases involve children, suggesting that it likely has a congenital origin.<sup>4</sup> Men are frequently affected to a greater extent than women. Macroductyly is more common in females.<sup>5</sup> In the third or fourth decade, symptoms often start to appear. MRI can be used to differentiate between plexiform neurofibroma and LFH as the findings from MRI indicate neuronal growth instead of fat. Both of the tumours might also differ in histology: although tumefaction is associated with neurofibromatosis, the formation of fibrofatty tissue that penetrates between nerve fibres is the main cause of LFH.

Radiography, ultrasound and MRI are some of the frequently utilised imaging modalities. An X-ray of the afflicted region may reveal soft tissue oedema. There may also be osteoarthritic alterations and bone enlargement in LFH. A fusiform tumour is seen on ultrasound as having longitudinal nerve bundles and alternating bands of hypoechoic and hyperechoic tissue. On the coronal section of the LFH MRI, the median nerve is enlarged in a fusiform or hourglass-shaped pattern and transverse section images reveal displacement of the flexor retinaculum. MRI appearances for LFH of the median nerve include “coaxial cable-like” on an axial plane and “spaghetti-like” on coronal or sagittal slices.<sup>6,7</sup> The flexor retinaculum and tendons are displaced and a large bulging mass in the carpal tunnel is shown on computed tomography (CT). The density of the bulk reveals fibroblastic elements.

Both the nerve conduction studies (NCS) and the electromyogram (EMG) of the median nerve exhibit abnormal results, such as reduced sensory and motor conduction, fibrillations in the muscles of the extremities, signs of chronic denervation and findings consistent with compressive neuropathy. Examining the tissue's histology reveals collagen interlacing, fibroblasts, mature adipocytes and sporadic capillaries that split nerve fascicles and colonise the region between the epineurium and the perineurium. No signs of myelin degradation, inflammation or abnormal looking nerve fibres exist. Routine nerve biopsy is not advised due to the possibility of functional impairment.

MRI provides pathognomonic characteristics that enable reliable lesion identification without requiring extra invasive procedures. Malignancy-suggestive traits may include an aggressively expanding firm mass and invasion of nearby structures. Malignant peripheral nerve sheath tumours are suspected when there are indications of central haemorrhage or necrosis, which show up as inhomogeneous intensity on an MRI.

The four main treatment objectives for LFH with or without macroductyly are function improvement, aesthetics, symptom prevention and symptomatic relief. There is no known treatment for LFH of the median nerve and the treatment of patients varies from case to case. Full tumour excision is traditionally carried out to completely remove the possibility of malignancy.<sup>8</sup> Patients frequently have painful neuromas along with debilitating deficiencies in sensations and powers. There is no importance for medical care management. Several authors described the neural sheaths decomposition and debulking.<sup>9,10</sup> Elbayer et al described median nerve carpal tunnel release plus covering the median nerve with dermal substitute and pronator quadratus flaps, an effective new modality of successful surgical management for LFH.<sup>10</sup>

## Conclusion

Angiogenetic LFH in the median nerve is extremely rare. Observation or prophylactic carpal tunnel release is recommended for big tumours in asymptomatic patients. Carpal tunnel decompression with or without neurolysis is one of the neurological indications.

## Acknowledgement

None.

## Conflict of interest

None.

## References

1. Verma A, Mukherjee M, Paul S, Yadav P, Mittal A, Mishra R, et al. Lipofibromatous hamartoma of median nerve: A review article. *Int J Orthop* 2021;7(4):845-50.
2. Marek T, Mahan MA, Carter JM, Amrami KK, Benarroch EE, Spinner RJ. Lipomatosis of nerve and overgrowth: is there a preference for motor (mixed) vs. sensory nerve involvement? *Acta Neurochir (Wien)* 2019 Apr;161(4):679-84.
3. Teles AR, Finger G, Schuster MN, Gobbato PL. Peripheral nerve lipoma: Case report of an intraneural lipoma of the median nerve and literature review. *Asian J Neurosurg* 2016 Oct-Dec;11(4):458. doi: 10.4103/1793-5482.181118.
4. Marek T, Spinner RJ, Syal A, Wahood W, Mahan MA. Surgical treatment of lipomatosis of nerve: a systematic review. *World Neurosurg* 2019 Aug;128:587-92.e2.
5. Walker FO, Cartwright MS, Alter KE, Visser LH, Hobson-Webb LD, Padua L, et al. Indications for neuromuscular ultrasound: Expert opinion and review of the literature. *Clin Neurophysiol* 2018 Dec;129(12):2658-79.
6. Marek T, Spinner RJ, Syal A, Mahan MA. Strengthening the association of lipomatosis of nerve and nerve-territory overgrowth: a systematic review. *J Neurosurg* 2019 Mar 29;132(4):1286-94.
7. Slouma M, Zarrouk Z, Maatoug F, Dhahri R, Amorri W, Gharsallah I, et al. Fibrolipoma of the median nerve: an overview. *Curr Rheumatol Rev* 2022;18(4):298-304.
8. Walker FO, Cartwright MS, Alter KE, Visser LH, Hobson-Webb LD, Padua L, et al. Indications for neuromuscular ultrasound: Expert opinion and review of the literature. *Clin Neurophysiol* 2018 Dec 1;129(12):2658-79.
9. Willinger ML, Henig A, Intravia JM, Ramirez DC, Edelman MC, Kenan S. Neurolipoma of the digit. *Hum Pathol* 2023 Mar 1;31:300685. doi: 10.1016/j.hpr.2022.300685.
10. Elbayer AM, Alharami S, Elhessy AH. Lipofibromatous hamartoma of the median nerve: a case report. *Cureus* 2023 Jan 8;15(1):e33516. doi: 10.7759/cureus.33516.