

# Computed tomographic characteristics of frontal sinus ossifying fibroma in a dog

Alice Birckhead<sup>1</sup>  | Ann Carstens<sup>1,2</sup>  | Erik Geiss<sup>3</sup> | Fui Yap<sup>3</sup> | Xander Huizing<sup>3</sup>

<sup>1</sup>School of Agricultural, Environmental and Veterinary Sciences, Charles Sturt University, Wagga, Australia

<sup>2</sup>Department of Companion Animal Clinical Studies, Faculty of Veterinary Sciences, University of Pretoria, Onderstepoort, South Africa

<sup>3</sup>The Austin Vet Specialists, Adelaide, Australia

## Correspondence

Alice Birckhead, School of Agricultural, Environmental and Veterinary Sciences, Charles Sturt University, Locked Bag 588, Wagga Wagga, NSW 2678, Australia.  
Email: [abirckhead@csu.edu.au](mailto:abirckhead@csu.edu.au)

## Abstract

A 10-year-old female spayed Kelpie cross was presented to The Austin Vet Specialists for further investigation of a mineralized, lobulated frontal sinus mass that had previously been detected radiographically. Computed tomography (CT) revealed a large, expansile, well-defined, heterogeneously mineral attenuating mass invading both frontal sinuses. The mass was surgically debulked via a frontal sinusotomy approach. Histopathology was consistent with ossifying fibroma. This is the first published report to describe frontal sinus ossifying fibroma in a dog, and the second to describe CT features of ossifying fibroma involving the cranium in a dog.

## KEYWORDS

canine, cranium, fibro-osseous lesions

## 1 | SIGNALMENT, HISTORY, AND CLINICAL FINDINGS

A 10-year-old spayed female Kelpie cross was presented to The Austin Vet Specialists for further investigation of a frontal sinus mass. She initially presented to the referring veterinary clinic a few weeks earlier with recent onset of a crusty to mucopurulent left-sided nasal discharge and left-sided conjunctivitis. Rhinoscopically, the nasal cavities were mildly inflamed, with no evidence of a mass or foreign body. Dorsoventral and lateral skull radiographs (Atomscope HF90/20, Australia) revealed a heterogeneously mineralized, lobulated frontal sinus mass (Figure 1). Differential diagnoses included a benign primary bone tumor such as an osteoma, a slow-growing malignant tumor such as multilobular tumor of bone or chondrosarcoma, and less likely mineralization associated with a fungal granuloma or a chronic foreign body.

The dog was referred for computed tomography (CT) of the head in order to further characterize the mass and explore surgical options. On presentation, additional clinical findings included mild left masticatory muscle atrophy and mild left enophthalmos.

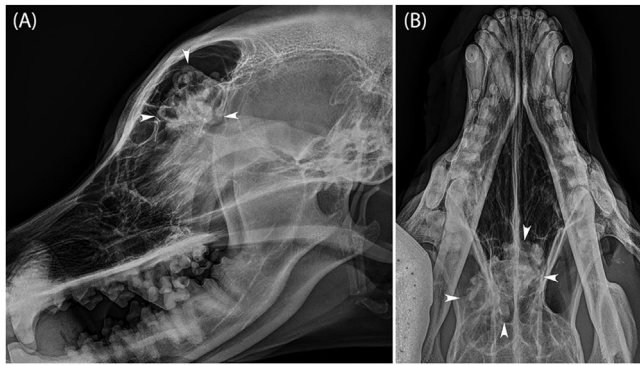
## 2 | IMAGING DIAGNOSIS AND OUTCOME

Computed tomography of the head was performed using a 64-slice scanner (Incisive, Philips Medical Imaging) with the patient anesthetized and positioned in sternal recumbency. Images were acquired in the transverse plane using the following image acquisition parameters: helical scan mode, 130 kVp, 120 mAs, 0.5 mm slice thickness, 0.75 s/rotation, pitch of 1.2 and 512 × 512 matrix. A postcontrast scan was performed 1 min after hand injection of 700 mg/kg of Iohexol (Omnipaque™ 300, GE Healthcare) into a cephalic vein. Images were reconstructed using soft tissue and bone algorithms and multiplanar reformatting was performed.

An approximately 18 mm high × 27 mm wide × 29 mm long, well-defined, lobulated, heterogeneously mineral attenuating mass arose from the base of the rostral sagittal septum of the frontal bone and extended into both frontal sinuses, particularly the right frontal sinus, filling almost half of its lumen (Figure 2). There was concurrent mild focal hyperostosis (up to 2 mm thick) of the right rostral calvarium, and mild ventral and caudal deviation of the calvarium and cribriform plate, with mild compression of the olfactory lobes. A smoothly marginated,

This is an open access article under the terms of the [Creative Commons Attribution-NonCommercial-NoDerivs](https://creativecommons.org/licenses/by-nc-nd/4.0/) License, which permits use and distribution in any medium, provided the original work is properly cited, the use is non-commercial and no modifications or adaptations are made.

© 2023 The Authors. *Veterinary Radiology & Ultrasound* published by Wiley Periodicals LLC on behalf of American College of Veterinary Radiology.

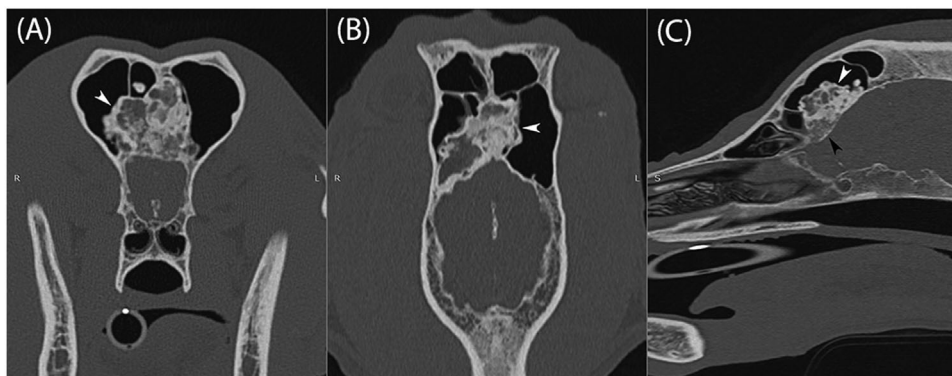

**FIGURE 1** Left to right lateral (A) and dorsoventral (B) skull radiographs revealed a lobulated, heterogeneously mineralized frontal sinus mass (arrows). B, Left is to the right of the image.

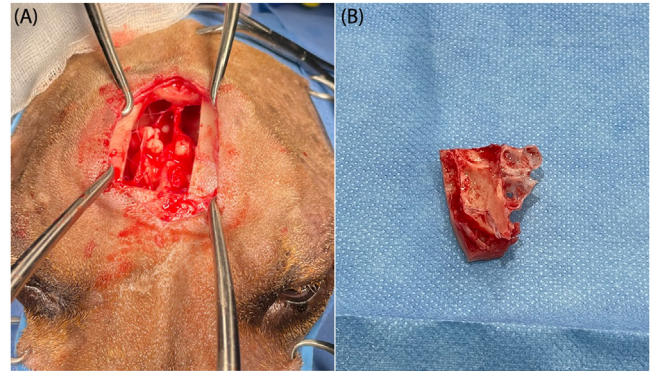
up to 4 mm thick mineral attenuating rim (ROI: 1000–2330 HU) surrounded the mass, and several mineral attenuating internal septations, up to 2 mm thick, were present. The mass contained areas of fat, fluid, and soft tissue attenuations (ROI: –100 to 90 HU) with scattered calcifications (up to 400 HU) throughout. No contrast enhancement was appreciated. The mass had a short transition zone and there was no evidence of invasion into the calvarium or nasal cavities. The imaging features were concluded to be relatively benign and the following differentials were considered: slow-growing benign neoplasia such as osteoma or osteochondroma, slow-growing primary malignant tumor such as chondrosarcoma, and an atypical granuloma.

Mild atrophy of the left masticatory muscles was observed, with normal contrast uptake. No evidence of trigeminal nerve pathology was noted. The rest of the head was unremarkable.

One month after the CT, the patient was anesthetized and the mass was surgically debulked using a frontal sinusotomy approach (Figure 3). Complete resection was not possible due to involvement of the rostral calvarium and cribriform plate. The patient recovered uneventfully. A piece of frontal bone with adherent mass and some central mass bone fragments were submitted for histopathological analysis. Fresh samples submitted for bacterial and fungal culture, were negative.



**FIGURE 2** Transverse (A), dorsal (B), and sagittal (C) bone-window survey CT images showing a large, well-defined, heterogeneously mineral attenuating, lobulated frontal sinus mass (white arrow). Mild ventral and caudal displacement of the underlying calvarium is seen (black arrow). A, B, Left is to the right of the image.



**FIGURE 3** A, Photograph of the head following frontal sinusotomy, with the lobulated frontal sinus mass visible. B, The corresponding piece of frontal bone that has some lobulated mass adhered to it. [Color figure can be viewed at [wileyonlinelibrary.com](http://wileyonlinelibrary.com)]

Histopathology (Gribbles Veterinary Pathology, Glenside, South Australia) revealed multiple trabeculae of recently mature bone that was variably lined by a layer of osteoblasts, adjacent to frontal sinus epithelium. Intervening bundles of densely cellular connective tissue were present and the tissue had a haphazard growth pattern. Flattened uniform nuclei with negligible mitotic activity were scattered sparsely throughout. Intertrabecular adipose tissue and areas of acute hemorrhage were observed. In one small fragment, a layer of plump uniform spindle cells, with low mitotic activity, lined the trabeculae.

The final histological diagnosis was ossifying fibroma with focal atypia. The focal atypia was considered most likely to be reactive but neoplasia could not definitively be excluded and monitoring was recommended.

### 3 | DISCUSSION

Ossifying fibromas are rare benign bone tumors of dogs, primarily found in the oral cavity.<sup>1</sup> They are classified as benign fibro-osseous lesions. Disorders within this group are characterized by a proliferative

fibrous matrix that replaces normal bone, with variable amounts of mineralization and ossification present.<sup>2</sup> Fibrous dysplasia is another example of a benign fibro-osseous lesion that is rarely diagnosed in dogs.<sup>1</sup> Ossifying fibromas most often affect the mandible and maxilla<sup>1,3</sup> and rarely other bones such as the parietal bone<sup>4</sup> and the os penis.<sup>5</sup> Based on our review of the literature, this report is the first to describe frontal sinus ossifying fibroma in a dog, and the second to describe CT features of ossifying fibroma involving the cranium in a dog.

Ossifying fibromas are slow-growing, expansile masses that are often clinically silent until they grow to a size that causes distortion, compression, or occlusion of adjacent structures.<sup>5-7</sup> They are described more in humans, and to a lesser extent horses, especially in young horses, with mandibular involvement most common in both.<sup>8-10</sup> Sinonasal ossifying fibromas are uncommon, and in people, often incidental findings on imaging examinations.<sup>7,11</sup> Clinical signs in people include nasal obstruction, rhinorrhea, epistaxis, facial swelling, proptosis, vision impairment, and headache.<sup>7,8</sup> Horses may present with chronic nasal discharge, facial deformity, respiratory distress,<sup>6,12</sup> and rarely blindness.<sup>13</sup> In this current case, the dog had chronic left-sided nasal discharge. It also had incidental mild left-sided masticatory muscle atrophy, with no evidence of trigeminal nerve pathology on CT. Trigeminal nerve neuropathy was a differential; a full neurological exam and MRI would provide more information.<sup>14</sup>

Ossifying fibromas must be differentiated from other bony masses of the mandible, maxilla, and craniofacial bones, including osteomas, low-grade osteosarcomas, osteitis/osteomyelitis, fibrous osteodystrophy, and multilobular tumor of bone.<sup>1,2</sup> Imaging features can be used to help a pathologist distinguish between ossifying fibromas and fibrous dysplasia within the oral cavity when histopathology alone is inconclusive. For instance, Soltero-Rivera et al.<sup>1</sup> reviewed canine biopsy specimens of benign fibro-osseous lesions in conjunction with imaging findings, and six of nine cases that had originally been diagnosed as ossifying fibroma were re-classified as either fibrous dysplasia or low-grade osteosarcoma. A key imaging feature of ossifying fibromas is clearly defined margins, whereas fibrous dysplasia typically has poorly defined margins.<sup>1</sup> Osteosarcomas usually show more aggressive features, including lysis and a spiculated periosteal reaction.<sup>1,15</sup> Osteomas are well-circumscribed masses and typically of homogeneous bone opacity; however, immature forms may exhibit a greater soft tissue component.<sup>1,16,17</sup>

In the few cases of mandibular and maxillary ossifying fibroma described in dogs, CT features include an expansile, mixed attenuating mass with well-defined margins. Some had associated bone thinning or destruction and teeth resorption. Bone destruction is considered secondary to pressure atrophy rather than active lysis.<sup>1,3</sup> The single case of ossifying fibroma of the left parietal bone in a dog was described as a large, lobulated, and primarily proliferative and ossifying mass, that extended into the frontal sinuses and extradural space of the brain. In contrast to the previously described cases, it had irregular and relatively poorly defined margins.<sup>4</sup>

The well-defined lobulated appearance of the ossifying fibroma in this current case, is different to that previously reported in dogs. Inter-

estingly, these features are described in human cases of paranasal ossifying fibroma.<sup>8,18,19</sup> Conventional and juvenile ossifying fibroma subtypes are recognized in people,<sup>19</sup> and unique imaging features of each subtype have been published.<sup>20</sup> CT features include an expansile, well-defined, mixed attenuating, corticated mass with central calcifications that may be irregularly scattered throughout or have a "ground glass" appearance, depending on the subtype.<sup>18-20</sup> Secondary aneurysmal bone cysts may be present.<sup>8,19</sup> Displacement of adjacent structures is common, and with the juvenile subtypes, bone thinning or destruction may be seen.<sup>8,18,19</sup>

The CT features of sinonasal ossifying fibromas in horses are similar to those already described: large, expansile, heterogeneous mass with well-defined margins, variable degrees of ossification and internal zones of calcification, and often with associated bone thinning or lysis.<sup>6,12,13,21</sup> Poorly defined margins were reported in one case; however, a complete radiological description was not provided.<sup>9</sup>

The CT findings in the current case were important for surgical planning, consistent with previous reports.<sup>6</sup> Complete surgical resection is the treatment of choice, to prevent recurrence.<sup>4,5,9,19</sup> This was not possible in this current case, as the mass was involving the cribriform plate. Frontal sinus osteotomy provided good surgical exposure to debulk the mass and obtain samples for histopathology and bacterial and fungal culture. Radiation therapy is an additional treatment option that may be considered in cases of ossifying fibroma that cannot be completely surgically resected.<sup>1,9</sup>

In conclusion, this is the first published report of frontal sinus ossifying fibroma in a dog and demonstrates how CT can aid in the diagnosis and surgical planning of such a case. Ossifying fibromas of the frontal sinus in dogs may appear as a clearly defined, lobulated, heterogeneously mineralized mass.

## ACKNOWLEDGMENTS

The authors acknowledge the veterinary staff at The Austin Vet Specialist for assistance with image acquisition, and Barossa Veterinary Service, South Australia for the initial diagnostic work-up. The authors also acknowledge William Barkman for formatting the images. The authors also acknowledge funding support received from the Australian Government Research Training Program Scholarship.

Open access publishing facilitated by Charles Sturt University, as part of the Wiley - Charles Sturt University agreement via the Council of Australian University Librarians.

## LIST OF AUTHOR CONTRIBUTIONS

### Category 1

- (a) Conception and design: Birckhead
- (b) Acquisition of data: Huizing, Yap, Geiss
- (c) Analysis and interpretation of data: Birckhead, Huizing, Carstens

### Category 2

- (a) Drafting the article: Birckhead
- (b) Revising article for intellectual content: Birckhead, Carstens, Huizing, Yap, Geiss

### Category 3

- (a) Final Approval of the Completed Article: Birckhead, Carstens, Huizing, Yap, Geiss

### Category 4

- (a) Agreement to be accountable for all aspects of the work ensuring that questions related to the accuracy or integrity of any part of the work are appropriately investigated and resolved: Birckhead, Carstens, Huizing, Yap, Geiss

### CONFLICT OF INTEREST STATEMENT

The authors declare no conflict of interest.

### PREVIOUS PRESENTATION OR PUBLICATION

#### DISCLOSURE

None.

### REPORTING CHECKLIST DISCLOSURE

No EQUATOR network checklist or other reporting checklist was used.

### ORCID

Alice Birckhead  <https://orcid.org/0009-0002-5644-4236>

Ann Carstens  <https://orcid.org/0000-0002-2462-4323>

### REFERENCES

- Soltero-Rivera M, Engiles JB, Reiter AM, et al. Benign and malignant proliferative fibro-osseous and osseous lesions of the oral cavity of dogs. *Vet Pathol.* 2015; 52(5):894-902. doi:10.1177/0300985815583096
- D'Aout C, Renfrew H, Dobromylskij M, et al. Intranasal proliferative fibro-osseous dysplasia in a domestic longhair cat. *JFMS Open Rep.* 2020; 6(1):2055116920917839. doi:10.1177/2055116920917839
- Miller MA, Towle HAM, Heng HG, et al. Mandibular ossifying fibroma in a dog. *Vet Pathol.* 2008; 45(2):203-206. doi:10.1354/vp.45-2-203
- Bordelon JT, Rochat MC. Use of a titanium mesh for cranioplasty following radical rostral tentorial craniectomy to remove an ossifying fibroma in a dog. *J Am Vet Med Assoc.* 2007; 231(11):1692-1695. doi:10.2460/javma.231.11.1692
- Mirkovic TK, Shmon CL, Allen AL. Urinary obstruction secondary to an ossifying fibroma of the os penis in a dog. *J Am Anim Hosp Assoc.* 2004; 40(2):152-156. doi:10.5326/0400152
- Cilliers I, Williams J, Carstens A, et al. Three cases of osteoma and an osseous fibroma of the paranasal sinuses of horses in South Africa. *J S Afr Vet Assoc.* 2008; 79(4):185-193. doi:10.4102/jsava.v79i4.271
- Manes RP, Ryan MW, Batra PS, et al. Ossifying fibroma of the nose and paranasal sinuses. *Int Forum Allergy Rhinol.* 2013; 3(2):161-168. doi:10.1002/alr.21067
- Yang BT, Wang YZ, Wang XY, et al. Imaging study of ossifying fibroma with associated aneurysmal bone cyst in the paranasal sinus. *Eur J Radiol.* 2012; 81(11):3450-3455. doi:10.1016/j.ejrad.2012.05.010
- Nottle BF, Tatarniuk DM, Caldwell FJ, et al. Fibro-osseous lesions of the craniofacial complex in horses: 30 Cases (2001-2019). *Vet Surg.* 2021; 50(2):383-392. doi:10.1111/vsu.13559
- Morse CC, Saik JE, Richardson DW, et al. Equine juvenile mandibular ossifying fibroma. *Vet Pathol.* 1988; 25(6):415-421.
- Appiani MC, Verillaud B, Bresson D, et al. Ossifying fibromas of the paranasal sinuses: diagnosis and management. *Acta Otorhinolaryngol Ital.* 2015; 35(5):355-361. doi:10.14639/0392-100X-533
- Turek B, Górski K, Drewnowska O, et al. Ossifying fibroma in the nasal cavity of a 2-year-old horse. *Animals.* 2021; 11(2):317. doi:10.3390/ani11020317
- Madrigal RG, Friedemann MC, Vallone JM, et al. Ossifying fibroma as a cause of blindness in a 5-year-old Quarter Horse gelding. *Equine Vet Educ.* 2020; 32(3):125-131. doi:10.1111/eve.12944
- Milodowski EJ, Amengual-Batle P, Beltran E, et al. Clinical findings and outcome of dogs with unilateral masticatory muscle atrophy. *J Vet Intern Med.* 2019; 33(2):735-742. doi:10.1111/jvim
- Toledo GN, Moreira PRR, Roleberg DS, et al. Intranasal osteosarcoma in a dog—a case report. *Top Companion Anim Med.* 2018; 33(2):35-39. doi:10.1053/j.tcam.2018.04.001
- Johnson KA, Cooley AJ, Darien DL. Zygomatic osteoma with atypical heterogeneity in a dog. *J Comp Pathol.* 1996; 114(2):199-203. doi:10.1016/s0021-9975(96)80009-0
- Galiazzo G, Pietra M, Tinto D, et al. A rare case of nasal osteoma in a dog: a case report. *Vet Med.* 2017; 62(11):614-619. doi:10.17221/30/2017-VETMED
- Han MH, Chang KH, Lee CH, et al. Sinonasal psammomatoid ossifying fibromas: cT and MR manifestations. *Am J Neuroradiol.* 1991; 12(1):25-30.
- Chrcanovic BR, Gomez RS. Juvenile ossifying fibroma of the jaws and paranasal sinuses: a systematic review of the cases reported in the literature. *Int J Oral Maxillofac Surg.* 2020; 49(1):28-37. doi:10.1016/j.ijom.2019.06.029
- Owosho AA, Hughes MA, Prasad JL, et al. Psammomatoid and trabecular juvenile ossifying fibroma: two distinct radiologic entities. *Oral Surg Oral Med Oral Pathol Oral Radiol.* 2014; 118(6):732-738. doi:10.1016/j.oooo.2014.09.010
- Cissell DD, Wisner ER, Textor J, et al. Computed tomographic appearance of equine sinonasal neoplasia. *Vet Radiol Ultrasound.* 2012; 53(3):245-251. doi:10.1111/j.1740-8261.2011.01913.x

**How to cite this article:** Birckhead A, Carstens A, Geiss E, Yap F, Huizing X. Computed tomographic characteristics of frontal sinus ossifying fibroma in a dog. *Vet Radiol Ultrasound.* 2023;64:E60–E63. <https://doi.org/10.1111/vru.13285>