

Parathyroid adenoma and angina pectoris

¹Valentina Velkoska Nakova, ²Gordana Kamcheva Mihailova, ²Slavica Jordanova, ³Aleksandar Stojmenov, ³Aleksandar Dimitrovski, ¹Vesna Ushinova

¹Department of internal diseases, Clinical Hospital, Stip, R.N.Macedonia

²Department of cardiology, Clinical Hospital, Stip, R.N.Macedonia

³PZU d-r Zlatko Stojmenov, Stip, R.N.Macedonia

Introduction. A parathyroid adenoma (PA) is a benign tumor ; the most common reason of primary hyperparathyroidism (PHPT) is PA. **Aim. To showed a male patient with PA without typical symptoms of PHPT, presented with chest pain** and positive coronary stress test (CST), but normal coronary arteriography.

Case presentation. A 44-year-old man with positive CST, after normal coronary arteriography was transferred to the endocrinologist because of a nodule found in the left lobe of the thyroid gland. Nifedipine relieved the angina.

On the neck ultrasound, **the patient had two-hypoechoic nodules (1.1x1.4x1.7 and 0.7x0.8x10cm) under the left lobe of the thyroid gland** without symptoms of primary hyperparathyroidism (Picture 1-4). Clinical investigations showed: **osteoporosis** (Tscore on the L1-L4 vertebrae= -3.1, and left distal radius = -4.4SD) (Picture 5-6), **high total and ionized serum calcium (3.0 and 1.57 mmol/L, respectively) and intact PTH (320 pg/mL). Sesta-mibi scanning revealed PA of the left inferior parathyroid gland** (Picture 7). After conservative management, PA was surgically excided, and serum calcium and intact PTH normalized. Patohistologic result showed PA (0.6x1.2x1.6cm) with attached parathyroid gland on the periphery of the PA.

During 2-years, follow-up, postoperative controls of calcium and neck ultrasound were normal and **he has had no angina.**

Preoperatively*

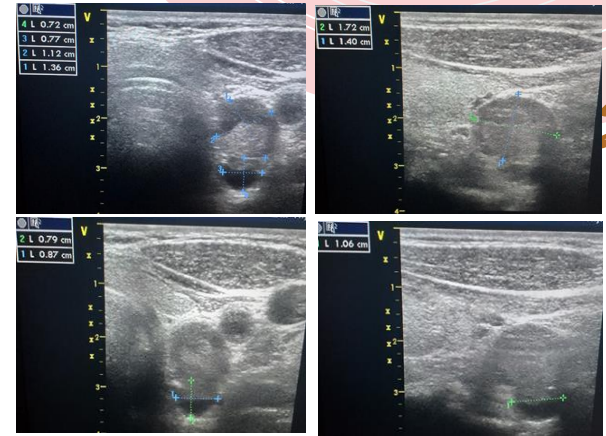
- low 25(OH)D levels should be repleted.
- patients should stay well-hydrated.
- genetic testing in young patients (<30 years) and multiglandular disease at any age should be performed.

Postoperatively*


- to define cure of PHPT after parathyroidectomy, normocalcaemia should last minimum of 6 months;
- annual evaluation of calcium should be performed;
- if hypercalcemia emerges, PTH measurement is warranted;

Conclusion. Hypercalcemia due to PHPT may be reason for chest pain and ECG changes resulting with positive CST. Physicians should evaluate electrolyte and consider PHPT in patients presented with chest pain, EKG changes, positive CST but normal coronary arteriography.

Picture 1-4. Ultrasound of the left inferior parathyroid adenoma



Picture 5,6. DXA scan



Picture 7. Sesta-MIBI scanning revealed PA of the left inferior parathyroid gland

