



**University of
Zurich** ^{UZH}

**Zurich Open Repository and
Archive**

University of Zurich
University Library
Strickhofstrasse 39
CH-8057 Zurich
www.zora.uzh.ch

Year: 2023

Infection of the metacarpal interosseus ligament within the metacarpal interosseus space as a complication of open fracture of the fourth metacarpal bone in 5 horses

Attiger, Jeannette ; Ohlerth, Stefanie M ; Jackson, Michelle Amanda

DOI: <https://doi.org/10.21836/PEM20230303>

Posted at the Zurich Open Repository and Archive, University of Zurich

ZORA URL: <https://doi.org/10.5167/uzh-254677>

Journal Article

Published Version

Originally published at:

Attiger, Jeannette; Ohlerth, Stefanie M; Jackson, Michelle Amanda (2023). Infection of the metacarpal interosseus ligament within the metacarpal interosseus space as a complication of open fracture of the fourth metacarpal bone in 5 horses. *Pferdeheilkunde*, 39(3):231-239.

DOI: <https://doi.org/10.21836/PEM20230303>

Infection of the metacarpal interosseus ligament within the metacarpal interosseus space as a complication of open fracture of the fourth metacarpal bone in 5 horses

Jeannette Attiger¹, Stefanie M. Ohlerth² and Michelle A. Jackson¹

Clinic for Equine Surgery¹ and Clinic of Diagnostic Imaging², Vetsuisse Faculty, University of Zurich, Winterthurerstrasse 260, 8057 Zurich, Switzerland

Summary: Open splint bone fractures are at increased risk of osteomyelitis and/or sequestrum formation. Infection is not always restricted to bony structures but may also affect the surrounding ligamentous structures including the interosseous ligament. This case series describes 5 horses with infection of the metacarpal interosseus space, including the metacarpal interosseus ligament, as a complication of an open fracture of the fourth metacarpal bone. All described horses had been presented to the equine department, Vetsuisse Faculty, University of Zurich, between July 2017 and October 2021 and fulfilled the following criteria: radiographic diagnosis of an acute fracture of second metacarpal (MCII)/metatarsal bone (MTII) or the fourth metacarpal (MCIV)/metatarsal bone (MTIV); the fracture was classified as open because of a wound in the affected metacarpal/metatarsal region; the presence of radiographic signs of osteomyelitis in the interosseus metacarpal/metatarsal space. Five horses fulfilled the inclusion criteria, and all had an open fracture of MCIV. Lameness at the walk varied from mild to severe. Wound secretion was present in 3 of the 5 horses. Radiography was done in all 5 cases and computed tomography was also used in 4 cases. Three different surgical treatments combined with antibiotics and nonsteroidal anti-inflammatory drugs were used: bone curettage, partial ostectomy and segmental ostectomy. All 5 cases made a complete recovery and returned to their intended use within 2.5 months to 2 years after surgery. In horses with persistent lameness and/or persistent wound secretion as a consequence of an open splint bone fracture, the adjacent metacarpal interosseus space should be assessed. Computed tomography appears superior to radiography for the presurgical staging of osteomyelitis because of its higher spatial and contrast resolution. The prognosis after extensive surgical and medical treatment appears to be good.

Keywords: horse, splint bone fracture, osteitis, osteomyelitis, metacarpal interosseus space

Citation: Attiger J., Ohlerth S., Jackson M. A. (2023) Infection of the metacarpal interosseus ligament within the metacarpal interosseus space as a complication of open fracture of the fourth metacarpal bone in 5 horses. *Pferdeheilkunde* 39, 231–239; DOI 10.21836/PEM20230303

Correspondence: Dr. Michelle Jackson, Clinic for horses, Vetsuisse Faculty Zurich, Winterthurerstrasse 260, 8057 Zurich, Switzerland; mjackson@vetclinics.uzh.ch

Submitted: March 20, 2023 | **Accepted:** April 6, 2023

Introduction

Fractures of the second metacarpal (MCII)/metatarsal bone (MTII) or the fourth metacarpal (MCIV)/metatarsal bone (MTIV) (splint bones, vestigial metacarpal/metatarsal bones) are frequently seen in horses and may be self-inflicted or caused by a kick from another horse (Jackson et al. 2007, Jackson and Auer 2019). Splint bone fractures occur more often on the lateral side and frequently involve the hind limbs (Bowman and Fackelman 1982, Walliser and Feige 1993, Jackson et al. 2007, Mageed et al. 2018). The proximal, middle or distal third of the splint bone may be affected, and the fracture may be accompanied by an open wound (Allen and White 1987, Jackson et al. 2007). Recommended treatment for fractures of the distal third is the surgical removal of the distal bone fragment with osteotomy of the most distal part of the proximal fragment (Bowman and Fackelman 1982, Jackson and Auer 2019). Conservative treatment has also been described for distal fractures (Verschooten et al. 1984). Closed and open mid-body or proximal fractures can be treated conservatively (Walliser and Feige 1993, Jackson et al. 2007, Sherlock and Archer 2008), but surgery

has been suggested for open as well as displaced fractures (Jenson et al. 2004). The two surgical techniques described are partial ostectomy with removal of the distal fragment and osteotomy of the most distal part of the proximal fragment (partial ostectomy, Allen and White 1987, Jackson and Auer 2019) and segmental ostectomy of the fractured bone (Allen and White 1987, Jenson et al. 2004). In fractures of the proximal part, additional internal fixation of the proximal fragment is needed because removal of more than the distal two-thirds of the splint bones results in instability of the remaining bone (Bowman and Fackelman 1982, Peterson et al. 1987). Complete removal of MTIV has been described (Baxter et al. 1992), but subsequent instability or luxation of the tarsometatarsal joint is a risk, which can be prevented by the application of a full-length cast post-operatively (Jackson and Auer 2019). Open fractures stabilised with plates and/or screws have a significantly higher risk of infection than closed fractures and therefore this method must be carefully considered (Allen and White 1987). Open fractures have a higher incidence of osteomyelitis and sequestrum formation than closed fractures even when internal fixation is not used (Allen and White 1987, Jackson et al. 2007).

The diagnostic work-up of bone infection includes radiography and/or computed tomography (CT) (Kessler and Lingg 1998, Goodrich 2006); the latter is considered a more sensitive and accurate method of visualising osteolytic lesions (Wisner et al. 1991, Walde et al. 2005, Lean et al. 2018), particularly in the early stages of disease (Malcius et al. 2009). In the authors' clinical experience, infection of a splint bone is not always restricted to the bony structures. It can also affect the surrounding ligamentous structures including the metacarpal/metatarsal interosseous ligament, which serves to connect MCIII/MTIII and the adjacent splint bone. The metacarpal/metatarsal interosseous ligament consists of firm connective tissue and irregular non-symmetrically distributed ossification spots mainly in the proximal and middle part of the ligament (Jackson et al. 2005).

To our knowledge, CT imaging, treatment and outcome of osteomyelitis of the splint bones and concurrent infection of the metacarpal/metatarsal interosseous ligament have not been reported. Therefore, the aim of this case series was to describe the clinical features, results of conventional radiography and CT, treatment and outcome of horses with infection of the metacarpal/metatarsal interosseous ligament as a consequence of an open splint bone fracture.

Materials and methods

The medical records of horses presented to the Equine Department, Vetsuisse Faculty, University of Zurich, between July 2017 and October 2021, were reviewed. Criteria for inclusion in the study were the following: radiographic diagnosis of an acute fracture of MCII/MTII or MCIV/MTIV; the fracture was classified as open because of a wound in the affected metacarpal/metatarsal region; the presence of radiographic signs of osteomyelitis in the metacarpal/metatarsal interosseous space.

Data obtained from the medical records included signalment (sex, breed, age and bodyweight), history, clinical findings, results of diagnostic imaging, surgical treatment, postsurgical management, type and duration of antimicrobial and non-steroidal anti-inflammatory drug (NSAID) treatment and the results of laboratory analyses and long-term follow-up.

Lameness at the walk was graded as absent, mild, moderate or severe. The American Association of Equine Practitioners (AAEP) scale (grade 1–5) was used to score lameness at the trot. Radiographic examination was done in all 5 cases, ultrasonography in 3 and CT in 4. Of the latter, CT was done preoperatively in 3 cases (11 days – 4 weeks after injury) and postoperatively in 1 (4 months after initial surgery). All radiographic studies were carried out with a digital system (FCR Profect CS, Fujifilm, Switzerland, Zurich) and included oblique (dorsolateral-palmaromedial oblique, dorsomedial-palmarolateral oblique, dorsolateral-plantaromedial oblique and dorsomedial-plantarolateral oblique), dorso-palmar/dorsoplantar and lateromedial views. A 40-slice scanner (Somatom Sensation Open, Siemens Medical Solutions, Zurich, Switzerland) was used for helical CT with the horses under general anaesthesia. The settings were 120KV, 100 mAs, 1 s tube rotation, a pitch of 0.65 and a 2 mm

slice collimation with an increment of 2 mm reconstructed to 0.75 mm images by applying a medium-frequency image reconstruction algorithm (soft tissue) and a high-frequency image reconstruction algorithm (bone). Dedicated software was used for reviewing the radiographic and CT images (OsiriX Open Source™ 5.0.2, OsiriX Foundation, Geneva, Switzerland). For evaluation of the CT images, multiplanar imaging (dorsal, transverse, sagittal planes) and a bone window (window width, 3000 Hounsfield units; window level, 500 Hounsfield units) were applied. All diagnostic images were reviewed by the same radiologist (SO), at the Clinic for Diagnostic Imaging, Vetsuisse Faculty of Zurich, Switzerland.

A long-term follow up was done via a telephone interview of the owners 7 months to 4.5 years postoperatively.

Results

History

Five horses fulfilled the inclusion criteria, and all had an open fracture of MCIV. The signalment of the horses is listed in Table 1. All 5 horses were kept in herds, and all fractures were the result of being kicked by another horse. In case 1, the MCIV of the left forelimb and in cases 2 to 5, the MCIV of the right forelimb were affected. The fracture was located at the transition from the proximal to the middle part of MCIV in all 5 horses. Four horses were presented to the clinic 10 days to 4 weeks after the injury because of mild to severe lameness at the walk (cases 1, 3, 4 and 5) and a chronic wound (cases 4 and 5). One horse was referred to the clinic on the day of the injury because of severe lameness (case 2). All 5 horses (except case 2, referred on the day of the injury) had received antibiotics and nonsteroidal anti-inflammatory drugs prior to admission. Two horses (cases 2 and 3) were sedated with detomidine (0.1 mg/kg bwt i.v.)¹ and butorphanol (0.1 mg/kg bwt i.v.)² followed by detomidine CRI (0.03 mg/kg/h i.v.)¹ for mechanical debridement and flushing of the wound with a disinfectant solution (octenidin).³ This treatment was carried out before infection of the metacarpal interosseus ligament became radiographically visible.

Preoperative diagnostic imaging

In all 5 cases, mild to moderate osteomyelitis involving osseous structures surrounding the metacarpal interosseus space adjacent to the fractures was diagnosed radiographically 10 days to 4 weeks after the injury. In all cases, cortices of MCIII and MCIV adjacent to the metacarpal interosseus space showed mild to severe abnormalities with new bone formation and permeative cortical lysis. In 4 cases, moderate to severe irregular periosteal reactions were also seen abaxially along MCIV (cases 1, 3, 4 and 5), and permeative medullary lysis of MCIV was seen in cases 1, 4 and 5 (Figures 1–3). When radiographic changes within the metacarpal interosseus space were first diagnosed, lameness ranged from mild to severe and wound secretion varied from none to purulent (Table 1). Ultrasonographic examination in 3

Table 1 Summary of 5 horses with fracture of the fourth metacarpal bone and infection of the metacarpal interosseus ligament within the metacarpal interosseus space. | Zusammenfassung von 5 Pferden mit Fraktur des Os metacarpale IV und Infektion des Ligamentum metacarpeum interosseum im Spatium metacarpeum interosseum.

| Case number | Age (years) | Breed | Sex F = female M = male | Body weight (kg) | Fracture Localisation | Time from injury to detection of radiographic changes of the ipsilateral metacarpal interosseus space | Grade of lameness at time of detection of radiographic changes of the ipsilateral metacarpal interosseus space | Wound secretion at time of detection of radiographic changes of the ipsilateral metacarpal interosseus space | Surgical therapy | Convalescence (time between first surgery and start of training) | Complete recovery |
|-------------|-------------|------------|-------------------------------|------------------|------------------------------------------------------|-------------------------------------------------------------------------------------------------------|----------------------------------------------------------------------------------------------------------------|--------------------------------------------------------------------------------------------------------------|------------------------------------------------------------------------------------------------------------------------------------------------|------------------------------------------------------------------|-------------------|
| 1 | 16 | Icelandic | F | 350 | Left MCIV, transition from proximal to middle third | 4 weeks | Moderate at the walk | Wound healed, no exudate | Bone curettage under general anaesthesia | 4 months | Yes |
| 2 | 20 | Icelandic | F | 380 | Right MCIV, transition from proximal to middle third | 10 days | Severe at the walk | Small amount of serous exudate | Segmental ostectomy under general anaesthesia | 2.5 months | Yes |
| 3 | 11 | Icelandic | F | 370 | Right MCIV, transition from proximal to middle third | 3 weeks | Moderate to severe at the walk | No exudate | Bone curettage under general anaesthesia | 5 months | Yes |
| 4 | 1 | Warm-blood | F | 460 | Right MCIV, transition from proximal to middle third | 4 weeks | Mild at the walk | Small amount of serous exudate | Partial ostectomy under general anaesthesia followed by wound revision using standing sedation and wound debridement under general anaesthesia | 2 years | Yes |
| 5 | 6 | Warm-blood | F | 610 | Right MCIV, transition from proximal to middle third | 10 days | Mild at the walk, grade 3/5 at the trot | Purulent exudate | Partial ostectomy under general anaesthesia followed by wound revision using standing sedation | 5 months | Yes |

horses (cases 2, 3 and 4) showed that the suspensory ligament was normal. Preoperative CT, done 11 days after the injury in case 2 and 4 weeks after the injury in cases 1 and 3, confirmed the radiographic findings. Furthermore, the extent and localisation of lytic foci and the severity of new bone formation could be determined more precisely using CT compared with radiography (Figure 2).

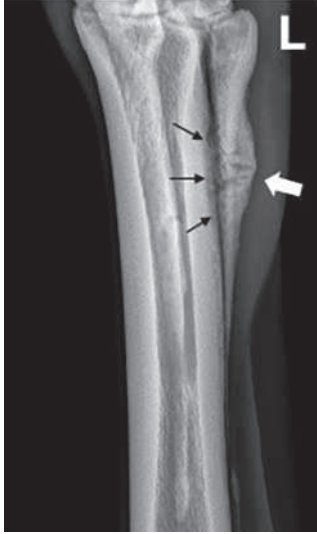

Fig. 1 Dorsolateral-palmaromedial-oblique radiographic view of the left fourth metacarpal bone (MCIV) in case 1 (4 weeks after injury): There is focal mild soft tissue swelling with moderate smooth periosteal reactions (white arrow) involving the abaxial aspect of the proximal part of MCIV. The fracture lines are still visible in MCIV. Despite progressive fracture healing abaxially, mild irregular new bone formation with permeative lysis of the cortices of MCIII and MCIV is seen in the metacarpal interosseus space indicative of osteomyelitis (black arrows). | *Röntgenologische dorsolaterale-palmaromediale Schrägaufnahme des linken Os metacarpale IV (MCIV) des Fall 1 (4 Wochen nach der Verletzung): Es bestehen eine fokale, leichtgradige Weichteilschwellung sowie mittelgradige, ruhige periostale Reaktionen (weißer Pfeil) im abaxialen Bereich des proximalen Abschnittes des MCIV. Die Frakturlinien innerhalb des MCIV sind immer noch sichtbar. Trotz der abaxial stattfindenden progressiven Frakturheilung bestehen leichtgradige, unregelmäßige Knochenzubildungen sowie permeative Lyse im Bereich der zum Spatium metacarpeum interosseum angrenzenden Kortizes des Os metacarpale III (MCIII) und MCIV, welche auf eine Osteomyelitis hinweisen (schwarze Pfeile).*

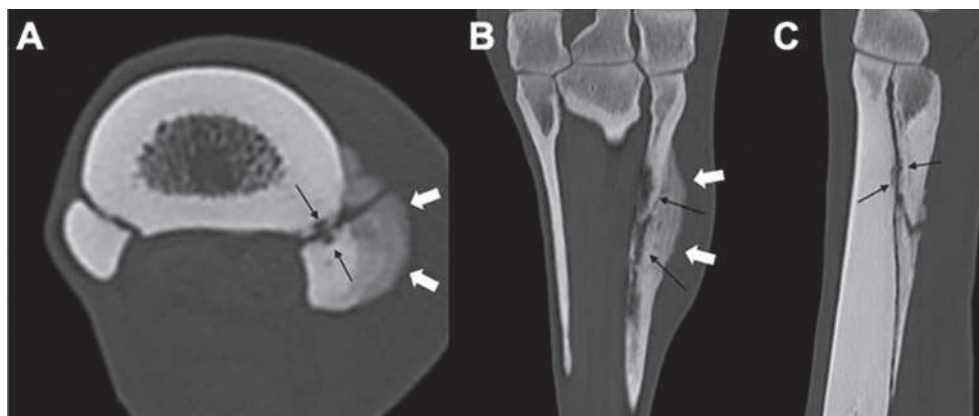


Fig. 2 Computed tomography (CT) images of the left forelimb in case 1 (4 weeks after injury). (A) transverse, (B) dorsal and (C) sagittal views. The CT scans confirmed the radiographic findings (moderate smooth to mildly irregular periostitis of the MCIV [white arrows], new bone formation and permeative lysis in the metacarpal interosseus space [black arrows]) but overall provided better images of the extent and degree of the pathological changes. | *Computertomographische (CT) Aufnahme des linken Vorderbeins des Fall 1 (4 Wochen nach der Verletzung): (A) Transverse, (B) dorsale und (C) sagittale Ansicht. Die CT-Aufnahmen bestätigen die röntgenologischen Befunde (mittelgradige, ruhige bis leicht unregelmäßige Periostitis des MCIV [weiße Pfeile], Knochenzubildungen sowie permeative Lyse im Bereich des Spatium metacarpeum interosseum [schwarze Pfeile]), wobei die Ausbreitung und der Schweregrad der pathologischen Veränderungen besser dargestellt werden.*

Treatment and postsurgical management

All 5 cases were treated surgically under general anaesthesia (Table 3). Cases 1 and 3 underwent thorough curettage of the pathological changed tissue. Segmental ostectomy of MCIV combined with curettage of MCIII and the metacarpal interosseous ligament were carried out in case 2. Cases 4 and 5 underwent partial resection and curettage of the periosteal reactions, the lytic bone and the metacarpal interosseus ligament. A drain (Easy-Flo)⁴ was placed in the distal aspect of the wound in cases 2, 3, 4 and 5; the wound cavity was flushed with a disinfectant solution (octenidin)³, and the deep layer of the soft tissues and the subcutis were closed separately using a simple continuous suture pattern (Polysorb 0)⁵. The skin was closed with surgical staples (Manipler AZ - 35W)⁶. A sterile non-adhesive dressing was applied to the wound, and a cotton bandage was applied to the limb. All horses received peri- and postoperative antibiotics and NSAIDs (Table 2). The bandages were changed every 2 to 5 days, and the drains were removed 2 to 3 days postoperatively (cases 2, 3, 4 and 5).

Case 4 developed postoperative infection of the surgical site, which extended to the bone surface. This was managed by repeated standing debridement and flushing of the infected area and antibiotic treatment (Table 2).

Lameness improved within several days after surgery in all the horses, and they were discharged from the clinic 1 to 6 weeks postoperatively. The owners were instructed to provide stall rest for a few days to 7 weeks, followed by turnout in a small paddock and/or hand walking for another 5 to 8 weeks. Three of the horses (cases 1, 2 and 3) could be ridden after the restricted exercise regimen. Two horses (cases 4 and 5) were readmitted to the clinic because of progressively worsening lameness.

Case 4 was readmitted 15 weeks after surgery because of worsening lameness and progressive swelling of the metacarpus of the affected limb. Radiographs showed a single well-defined radiolucent area in the metacarpal interosseus space concerning the abaxial cortex of MCIII and an exuberant amount of spiculated irregular periosteal bone formation, extending axially and abaxially on the remaining part

of MCIV (Figure 4). Conservative treatment failed to cause improvement after 3 weeks, and therefore a second surgery was planned. Preoperative CT imaging confirmed the radiographic findings, but showed that the extent and localisation of the lesions were more severe than depicted by conventional radiographs. The surgery included thorough curettage and debridement of all the infected tissues. The horse received peri- and postoperative antibiotics and NSAIDs (Table 2). Five days postoperatively, the horse developed an infection of the surgical site with purulent exudate, which prompted a change in antibiotic treatment to cefquinome

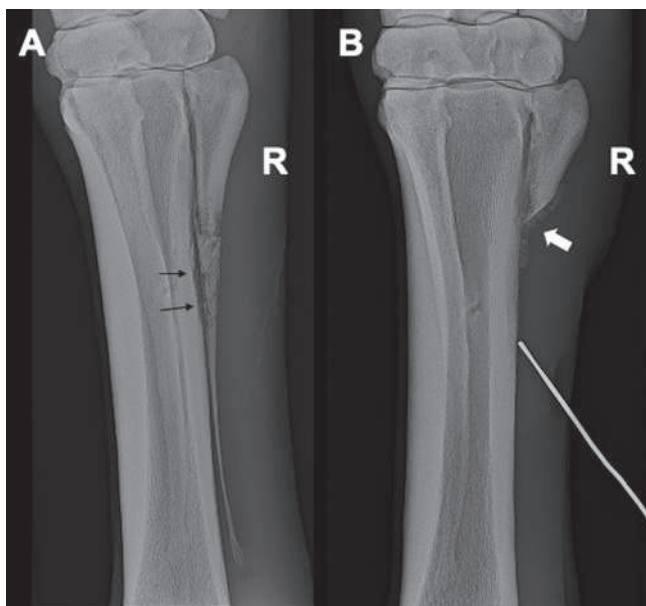


Fig. 3 (A) Dorsolateral-palmaromedial oblique radiographic view of the right MCIV in case 5 (10 days after injury). Moderate diffuse soft tissue swelling around MCIV and multiple faint fracture lines in MCIV are evident, and the overall bone opacity of the fractured area of MCIV is markedly reduced. Mild irregular new bone formation with permeative lysis of the cortices of MCIII and MCIV are apparent in the metacarpal interosseus space indicative of osteomyelitis (black arrows). (B) Dorsolateral-palmaromedial oblique radiographic view of the right MCIV in case 5 (6 weeks after surgery): Moderate soft tissue swelling and irregular palisading periosteal reactions along the abaxial contours of MCIII and MCIV are seen. Persistent irregular new bone formation with permeative lysis within the metacarpal interosseus space is indicative of osteomyelitis (white arrow). A metal probe has been inserted into a draining tract and points toward the distal margin of the periosteal reactions on MCIII. | (A) Röntgenologische dorsolaterale-palmaromediale Schrägaufnahme des rechten MCIV des Fall 5 (10 Tage nach der Verletzung): Mittelgradige, diffuse Weichteilschwellung um den MCIV sowie multiple, undeutliche Frakturlinien innerhalb des MCIV sind sichtbar und die gesamte Knochenichte im frakturierten Bereich des MCIV wirkt deutlich reduziert. Leichtgradige, unregelmäßige Knochenzubildungen sowie permeative Lyse im Bereich der zum Spatium metacarpeum interosseum angrenzenden Kortizes des MCIII und MCIV, welche auf eine Osteomyelitis hinweisen (schwarze Pfeile), sind sichtbar. (B) Röntgenologische dorsolaterale-palmaromediale Schrägaufnahme des rechten MCIV des Fall 5 (6 Wochen nach der chirurgischen Therapie): Mittelgradige Weichteilschwellung und unregelmäßige, palissadenartige periostale Reaktionen entlang der abaxialen Konturen des MCIII und MCIV sind sichtbar. Persistierende, unregelmäßige Knochenzubildungen sowie permeative Lyse im Bereich des Spatium metacarpeum interosseum sind hinweisend für Osteomyelitis (weißer Pfeil). Eine Metallsonde wurde in den Fistelkanal eingeführt und zeigt auf den distalen Rand der periostalen Reaktionen des MCIII.

(Table 2). Analgesic treatment was changed to phenylbutazone because of poor weight bearing on the right front limb (Table 2). Regional limb perfusion was carried out and systemic cefquinome was replaced with ceftiofur because of persistent purulent exudate (Table 2). Weight bearing progressively improved, the purulent exudate resolved, and the horse was discharged 5 weeks after reoperation. Stall rest was advised for 4 weeks followed by turnout in a paddock with other horses.

Case 5 was readmitted 6 weeks after surgery because of worsening lameness and persistent drainage from an opening in the skin that extended to the lateral aspect of MCIII of the right forelimb. Radiographic and ultrasonographic examination showed extensive irregular periosteal new bone formation on the palmar aspect of MCIII distal to the ostectomy site and on the abaxial aspect of the remnant of MCIV (Figure 3B). Ultrasonography also showed cellulitis and fluid accumulation adjacent to the periosteal new bone formation. Antibiotics and NSAIDs were administered (Table 2). Regional limb perfusion was done (Table 2), and the bandage was changed every 3 to 4 days until the wound had healed. The horse was discharged with instructions to provide stall rest for 1 week followed by stall rest with access to a small paddock for 4 weeks. The horse was then turned out on pasture for 2.5 months before being ridden.

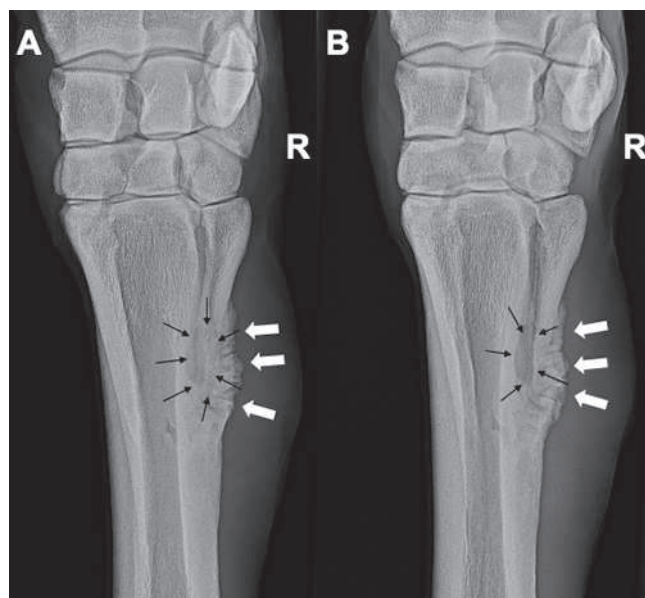


Fig. 4 Radiographic images of the right carpus showing the proximal part of MCVI, which was left in situ after partial ostectomy in case 4 (15 weeks after surgery). (A) Dorsopalmar and (B) dorsolateral-palmaromedial oblique views. An exuberant amount of spiculated irregular periosteal bone formation is evident on the remaining MCVI (white arrows). A well-defined radiolucent area in the metacarpal interosseus space between MCIII and MCIV is indicative of bone lysis (black arrows). | Röntgenologische Aufnahmen des rechten Karpus stellen den proximalen Abschnitt des MCIV dar, welcher bei Fall 4 während der partiellen Ostektomie in situ belassen wurde (15 Wochen nach der chirurgischen Therapie): (A) Dorsopalmar Aufnahme und (B) dorsolaterale-palmaromediale Schrägaufnahme. Eine übermäßige Menge an unregelmäßigen, gezackten periostalen Knochenzubildungen des verbliebenen MCIV-Abschnittes ist sichtbar (weiße Pfeile). Ein klar umschriebener, strahlendurchlässiger Bereich innerhalb des Spatium metacarpeum interosseum zwischen dem MCIII und MCIV weist auf Knochenlyse hin (schwarze Pfeile).

Table 2 Drugs used for peri- and postoperative treatment in 5 horses with an open fracture of the fourth metacarpal bone and infection of the metacarpal interosseus ligament within the metacarpal interosseus space. | *Medikamente verwendet für die peri- und postoperative Behandlung von 5 Pferden mit einer offenen Fraktur des Os metacarpale IV und Infektion des Ligamentum metacarpeum interosseum im Spatium metacarpeum interosseum.*

| | Active drug | Dosage | Duration | Cases |
|-------------|-----------------------------------------------------|----------------------------------------|-----------|---------------|
| Antibiotics | Sodium penicillin combined with Gentamicin | 30'000 IU/kg bwt. i.v. q. 6h | 1–7 days | 1, 4 and 5 |
| | | 10 mg/kg bwt. i.v. q10 | | |
| | Trimethoprim combined with Sulfonamide | 5 mg/kg bwt q. 12h | 6–14 days | 1 and 4 |
| | | 25 mg/kg bwt, p.o. q. 12h | | |
| | Doxycycline | 10 mg/kg bwt, p.o. q. 12h | | |
| | Marbofloxacin | 2–3 mg/kg bwt. i.v. or p.o. q. 12–24 h | 6–19 days | 2, 3, 4 and 5 |
| | Cefquinome | 4.5 mg/kg bwt, i.v. q. 12 h | 10 days | 4 |
| | Metronidazole | 25 mg/kg bwt, p.o. q. 12 h | 21 days | 4 |
| | Ceftiofur | 2 mg/kg bwt, i.v. q. 12–24 h | 9 days | 4 |
| Amikacin | 1000 mg as regional limb perfusion, every other day | 2–4 times | 4 and 5 | |
| NSAIDs | Flunixin meglumine | mg/kg bwt. i.v. or p.o. q. 12–24 h | 5–37 days | 1, 3 and 5 |
| | Suxibuzone | 1.5 mg p.o. q. 24 h | 12 days | 2, 4 |
| | Phenylbutazone | 0.5–1 mg p.o. q. 12–24 h | 20 days | 4 |

Table 3 Drugs used for general anaesthesia in 5 horses with an open fracture of the fourth metacarpal bone and infection of the metacarpal interosseus ligament within the metacarpal interosseus space. | *Medikamente verwendet für die Allgemeinanaästhesie von Pferden mit einer offenen Fraktur des Os metacarpale IV und Infektion des Ligamentum metacarpeum interosseum im Spatium metacarpeum interosseum.*

| | Active Drug | Dosage | Cases |
|------------------------------------------|-----------------------------------------|----------------------------------------------------------|------------------|
| Sedation | Acepromazine | 0.03 mg/kg bwt. i.m. or i.v. | 1, 2, 3, 4 and 5 |
| | Xylazine | 0.9–1.1 mg/kg bwt. i.v. | 1, 2, 3 and 4 |
| | Medetomidine | 7 µg/kg bwt. i.v. | 5 |
| Anaesthesia induction | Ketamine | 2.2 mg/kg bwt. i.v. | 1, 2, 3, 4 and 5 |
| | Diazepam | 0.02 mg/kg bwt. i.v. | 1, 2, 3, 4 and 5 |
| Anaesthesia maintenance | Xylazine | 0.55 mg/kg bwt. i.v. | 1, 2, 3 and 4 |
| | Ketamine | 1.1–1.2 mg/kg bwt. i.v. | 1, 2, 3 and 4 |
| | Isoflurane in 100% oxygen | | 1, 2, 3, 4 and 5 |
| | Xylazine - constant rate infusion (CRI) | 0.7 mg/kg bwt./h | 1, 2, |
| | Medetomidine - CRI | 3.5 µg/kg bwt./h | 3 and 5 |
| Additional medication during anaesthesia | Dobutamine - CRI | 0–0.5 µg/kg bwt./min | 1, 2, 3, 4 and 5 |
| | Ketamin-Topping | 0.08–0.13 mg/kg bwt. i.v. once to 4 times during surgery | 4 and 5 |
| | Thiopental-Topping | 0.01 mg/kg i.v. once during surgery | 4 |
| Fluid therapy during anaesthesia | Ringer's acetate | 10 ml/kg bwt./h | 1, 2, 3 and 4 |
| | Ringer's lactate | 10 ml/kg bwt./h | 4 and 5 |
| Recovery | Morphine | 0.1 mg/kg bwt. i.m. | 1, 2, 3, 4 and 5 |
| | Phenylephrine | 0.03 mg/kg bwt. intranasally | 1, 2, 3, 4 and 5 |
| | Xylazine | 0.3–0.8 mg/kg bwt. i.v. | 1, 2, 3, and 4 |
| | Medetomidine | 2.0 µg/kg bwt. i.v.) | 3 and 5 |
| | Acepromazine | 0.03 mg/kg bwt. i.m. | 4 |

Laboratory analysis

Swabs for bacteriological analysis at the Institute of Veterinary Bacteriology, Vetsuisse Faculty, University of Zurich, were collected from the infected areas preoperatively in case 3, intraoperatively in cases 2 and 5 and postoperatively after first and second surgery in case 4. Case 3 yielded no bacterial growth, and case 2 yielded mild growth of *Bacillus* sp. (no antibiogram available). Case 5 showed mild growth of *Streptococcus ovis*, *Clostridium perfringens* and *Staphylococcus delphini*; the latter was sensitive to all tested antibiotics. Case 4 had growth of multi-drug resistant *Escherichia coli* in both swab-samples.

Outcome

Long-term follow-up was done by a telephone interview of the owners 7 months (case 5), 1.5 years (case 3), 2.5 years (case 1), 3 years (case 4) and 4.5 years (case 2) postoperatively. Four horses were sound and had returned to their intended use as a sport horse (case 1) or leisure horse (cases 3 and 5) or were in training (case 4). Case 2 had returned to its former activity as a school horse but had to be euthanised because of other medical problems.

Discussion

This case series showed that infection of the metacarpal interosseus ligament can be a complication of an open fracture of MCIV. In all 5 cases, the splint bone fractures were caused by a kick from another horse, which is a common cause of fractures (Derungs et al. 2004). Kick injuries were the most frequent cause of fractures in horses presented to the Equine Department, Vetsuisse Faculty, University of Zurich, between 1990 and 2014 (Donati et al. 2018). Such fractures are usually accompanied by a laceration or a crush wound, and they predispose to localised infection (Derungs et al. 2004). Three of the 5 cases were Icelandic horses, which is noteworthy considering that Donati et al. (2018) reported that ponies and Icelandic horses were more likely to incur a fracture caused by a kick than Warmblood, Thoroughbred or Standardbred horses. A plausible reason is the fact that Icelandic horses and ponies are traditionally kept in herds, which increases the risk of kick injuries (Donati et al. 2018). The other 2 cases in the present study were also pastured with other horses. In all cases, MCIV of the right (4 cases) or left (1 case) forelimb was affected. This was in contrast to the findings of other studies, in which the hind limbs were shown to be at a higher risk of splint bone fractures caused by a kick from another horse (Bowman and Fackelman 1982, Walliser and Feige 1993, Donati et al. 2018, Mageed et al. 2018).

Radiography revealed osteomyelitis of the fractured MCIV and the lateral cortex of the adjacent MCIII indicating infection of the metacarpal interosseus ligament within the adjacent metacarpal interosseus space in all 5 cases even though all horses had received antibiotics once an open splint bone fracture was diagnosed. The development of osteomyelitis subsequent to an open splint bone fracture has been described (Allen and White 1987), but to the authors' knowledge, radiographic indications for infection of the metacar-

pal/metatarsal interosseus ligament within the metacarpal/metatarsal interosseus space has not been reported. The anatomy of the metacarpal and metatarsal interosseus ligaments is similar (Jackson et al. 2005), and therefore infection of the metatarsal interosseus ligament following an open splint bone fracture must also be considered in the hind limbs.

In dogs, similar radiographic changes have been described for the radioulnar space, where the radioulnar ligament connects the distal ends of the two antebrachial bones (Schmid et al. 2016). The osseous reaction seen in a dog was considered ischemic necrosis and referred to as radioulnar ischemic necrosis based on a history of a traumatic injury and the results of radiography, CT and histological examination (Schmid et al. 2016). These findings raise the question as to whether the changes in the metacarpal interosseus space in the present study represent ischemic osseous necrosis subsequent to trauma and vascular damage. Bacteriological evaluation of the infected site in 4 horses (cases 3, 2, 4 and 5) showed no or only mild bacterial growth in 3 cases (cases 3, 2 and 5) suggesting that infection is not the only factor leading to pathological changes in the interosseus space. Nevertheless, it is important to note that at least 1 of the 3 horses (case 5) had clinical signs of overt infection of the surrounding soft tissues that responded well to intensive antibiotic therapy. Therefore, the possibility of false-negative bacteriological culture results, especially after antibiotic treatment, must be considered. Histological examination of affected metacarpal interosseus ligaments and adjacent bone tissue is needed to differentiate infectious from sterile ischemic necrotic processes.

All the adult horses had a complete recovery and returned to their intended use. The one-year-old filly (case 4) was started under saddle 2 years postoperatively. All the horses had moderate to severe lameness at the time of admission and/or during treatment and required surgery under general anaesthesia, although the surgical treatments differed. The horses treated with partial resection (cases 4 and 5) had a complicated healing process and were readmitted to the clinic. In case 4, the remnant of MCIV as well as the adjacent MCIII, the metacarpal interosseus ligament in between and the surrounding soft tissues showed signs of infection. Bacteriological culture of a sample collected during the initial hospitalisation revealed multi-drug resistant *Escherichia coli*. However, the horse showed improvement with the initial choice of antibiotics and thus no changes were made (Baxter 1996). The sample collected during the second hospitalisation yielded the same bacteriological results suggesting that the antibiotics were unable to eliminate the infection entirely and therefore a treatment change was indicated. The reason for worsening lameness in case 5 was assumed to be the ongoing infection of the surgical site involving the adjacent soft tissues. The infection resolved after another course of antibiotics supplemented with regional limb perfusion. The initial surgery in cases 4 and 5 was done without a preoperative CT examination, which showed that conventional radiography and intraoperative evaluation were not sufficient to assess the complete extent of infection. This is in agreement with other studies that found CT to have a higher sensitivity and accuracy in the detection of osteolysis in several areas of the pelvis in humans (Walde et al. 2005) and in different anatomic locations in horses (Wisner et al. 1991, Lean et al. 2018) compared with conventional radiography. Further studies are warranted to in-

investigate whether CT is indeed superior to conventional radiography for detection of lesions of the splint bones and metacarpal interosseus space. A direct correlation between partial resection and complications in the healing process cannot be drawn based on the small number of cases.

Conclusions

Horses with persistent moderate to severe lameness and/or a chronic draining wound after an open splint bone fracture should undergo radiography of the adjacent metacarpal/metatarsal interosseus space. Surgical treatment with preoperative CT examination as well as aggressive antibiotic treatment are recommended in cases with radiographic evidence of lytic changes in the metacarpal interosseus space. Based on the results of this case series, the prognosis is good in horses that receive adequate treatment for infection of the metacarpal interosseus ligament within the metacarpal interosseus space after an open splint bone fracture.

Conflict of interest statement

No conflicts of interest have been declared.

Ethical animal research

Case report therefore no ethical approval needed.

Source of funding

No source of funding was required for this study.

Authorship

All authors have contributed to the study design, study execution, data analysis and interpretation and manuscript preparation and have reviewed and approved the final version.

Manufacturers' addresses

¹ Provet AG

² Streuli AG

³ Schülke & Mayr GmbH, Norderstedt, Germany

⁴ Dahlhausen, Cologne, Germany

⁵ Medtronic (Schweiz) AG, Münchenbuchsee BE, Switzerland

^{6B} Braun Medical AG, Sempach LU, Switzerland

References

Allen D., White N. A. (1987) Management of fractures and exostosis of the metacarpals and metatarsals II and IV in 25 horses. *Equine Vet. J.* 19, 326–330; DOI 10.1111/j.2042-3306.1987.tb01422.x

Baxter G. M., Doran R. E., Allen D. (1992) Complete Excision of a Fractured Fourth Metatarsal Bone in Eight Horses. *Vet. Surg.* 21, 273–278; DOI 10.1111/j.1532-950X.1992.tb00063.x

Baxter G. M. (1996) Instrumentation and techniques for treating orthopedic infections in horses. *Vet. Clin. North Am. Equine Pract.* 12, 303–335; DOI 10.1016/s0749-0739(17)30284-5

Bowman K. F., Fackelman G. E. (1982) Surgical Treatment of Complicated Fractures of the Splint Bones in the Horse. *Vet. Surg.* 11, 121–124

Derungs S., Fürst A. E., Hässig M., Auer J. A. (2004) Frequency, consequences and clinical outcome of kick injuries in horse: 256 cases (1992–2000). *Wien. Tierärztl. Mschr.* 91, 114–119

Donati B., Fürst A. E., Hässig M., Jackson M. A. (2018) Epidemiology of fractures: The role of kick injuries in equine fractures. *Equine Vet. J.* 50, 580–586; DOI 10.1111/evj.12819

Goodrich L. R. (2006) Osteomyelitis in horses. *Vet. Clin. North Am. Equine Pract.* 22, 389–417

Jackson M., Geyer H., Fürst A. (2005) Anatomy of the splint bones and their surrounding area particularly in consideration of fascial attachments. *Schweiz. Arch. Tierheilkd.* 147, 473–481; DOI 10.1024/0036-7281.147.11.473

Jackson M. A., Auer J. A. (2019) Chapter 94 - Vestigial Metacarpal and Metatarsal Bones. In: *Equine Surgery*, Eds: J. A. Auer, J. A. Stick, J. M. Kümmerle and T. Prange, W.B. Saunders, St. Louis, 5th edn., pp. 1636–1647; DOI 10.1016/B978-0-323-48420-6.00094-6

Jackson M. A., Fürst A., Hässig M., Auer J. A. (2007) Splint bone fractures in the horse: a retrospective study 1992–2001. *Equine Vet. Educ.* 19, 329–335; DOI

Jenson P. W., Gaughan E. M., Lillich J. D., Bryant J. E. (2004) Segmental ostectomy of the second and fourth metacarpal and metatarsal bones in horses: 17 cases (1993–2002). *J. Am. Vet. Med. Assoc.* 224, 271–274; DOI 10.2460/javma.2004.224.271

Kessler S., Lingg G. (1998) Osteomyelitis-imaging methods and their value. *Rofo.* 169, 105–114; DOI 10.1055/s-2007-1015059

Lean N. E., Perkins N. R., Ahern B. J. (2018) Comparison of conventional radiography and computed tomography as aids in the diagnosis of osteomyelitis in 11 foals. *Aust. Vet. J.* 96, 257–261; DOI 10.1111/avj.12710

Mageed M., Steinberg T., Drumm N., Stubbs N., Wegert J., Koene M. (2018) Internal fixation of proximal fractures of the 2nd and 4th metacarpal and metatarsal bones using bioabsorbable screws. *Aust. Vet. J.* 96, 76–81; DOI 10.1111/avj.12673

Malcius D., Jonkus M., Kuprionis G., Maleckas A., Monastyreckiene E., Uktveris R., Rinkevicius S., Barauskas V. (2009) The accuracy of different imaging techniques in diagnosis of acute hematogenous osteomyelitis. *Medicina (Kaunas)* 45, 624–631.

Peterson P. R., Pascoe J. R., Wheat J. D. (1987) Surgical management of proximal splint bone fractures in the horse. *Vet. Surg.* 16, 367–372; DOI 10.1111/j.1532-950x.1987.tb00969.x

Schmid L., Klang A., Katic N., Ansón A., Gumpenberger M., Kneissl S. (2016) Imaging Diagnosis-Radiography and Computed Tomography of Radioulnar Ischemic Necrosis in a Jack Russel Terrier. *Vet. Radiol. Ultrasound* 59, E7–e11; DOI 10.1111/vru.12448

Sherlock C. E., Archer R. M. (2008) A retrospective study comparing conservative and surgical treatments of open comminuted fractures of the fourth metatarsal bone in horses. *Equine Vet. Educ.* 20, 373–379; DOI 10.2746/095777308X329163

Verschooten F., Gasthuys F., De Moor A. (1984) Distal splint bone fractures in the horse: an experimental and clinical study. *Equine Vet. J.* 16, 532–536; DOI 10.1111/j.2042-3306.1984.tb02011.x

Walde T. A., Weiland D. E., Leung S. B., Kitamura N., Sychterz C. J., Engh C. A. Jr., Claus A. M., Potter H. G., Engh C. A., Sr. (2005) Comparison of CT, MRI, and radiographs in assessing pelvic osteolysis: a cadaveric study. *Clin. Orthop. Relat. Res.* 437, 138–144; DOI 10.1097/01.bl.0000164028.14504.46

Walliser U., Feige K. (1993) The conservative therapy of the proximal open splint bone fracture. *Pferdeheilkunde* 9, 107–111; DOI 10.21836/PEM19930204

Wisner E. R., O'Brien T. R., Pool R. R., Pascoe J. R., Koblick P. D., Hornoff W. J., Poulos P. W. Jr. (1991) Osteomyelitis of the axial border of the proximal sesamoid bones in seven horses. *Equine Vet. J.* 23, 383–389; DOI 10.1111/j.2042-3306.1991.tb03743.x