



Hoigné's syndrome, an uncommon mimicker of anaphylaxis: Systematic literature review

Danilo Consolascio^{a, #}, Gabriel Bronz^{b, #}, Pietro F. Lardelli^a, Gregorio P. Milani^{c, d}, Sebastiano A.G. Lava^{e, f}, Benedetta Terziroli Beretta Piccoli^{g, h, i, *}, Mario G. Bianchetti^a, Marcel M. Bergmann^{i, j, 1}, Mattia Rizzi^{b, i, k, 1}

^a Family medicine, Faculty of Biomedical Sciences, Università della Svizzera Italiana, Lugano, Switzerland

^b Pediatric Institute of Southern Switzerland, Ente Ospedaliero Cantonale, Bellinzona, Switzerland

^c Pediatric Unit, Fondazione IRCCS Ca' Granda Ospedale Maggiore Policlinico, Milan, Italy

^d Department of Clinical Sciences and Community Health, Università degli Studi di Milano, Milan, Italy

^e Pediatric Cardiology Unit, Department of Pediatrics, Centre Hospitalier Universitaire Vaudois and University of Lausanne, Lausanne, Switzerland

^f Clinical Pharmacology and Therapeutics Group, University College London, London, United Kingdom

^g Epatocentro Ticino, Lugano, Switzerland

^h Faculty of Life Sciences & Medicine, King's College London, King's College Hospital, London, United Kingdom

ⁱ Faculty of Biomedical Sciences, Università della Svizzera Italiana, Lugano, Switzerland

^j Pediatric Allergy Unit, Department of Pediatrics, Gynecology and Obstetrics, University Hospitals of Geneva, Geneva, Switzerland

^k Pediatric Oncology/Hematology Unit, Department of Women-Mother-Child, Centre Hospitalier Universitaire Vaudois and University of Lausanne, Lausanne, Switzerland

ARTICLE INFO

Keywords:

Adverse drug reaction

Anaphylactic reaction

Hoigné's syndrome

Panic attack

Penicillins

Pseudo-anaphylactic reaction

ABSTRACT

The term Hoigné's syndrome denotes a mimicker of anaphylaxis, which occurs immediately after the parenteral administration of a drug and is likely caused by non-thrombotic pulmonary and systemic drug micro-embolization. It has so far been documented uniquely in case reports and small case series. Because this condition has never been systematically evaluated, we performed a structured literature review (pre-registered as CRD42023392962). The search was carried out in Excerpta Medica, National Library of Medicine, and Google Scholar. Cases with features consistent with anaphylaxis, urticaria, angioedema, asthma, syncope, anxiety, or panic attack triggered by needle phobia, and local anesthetic systemic toxicity were excluded. For the final analysis, we retained reports published between 1951 and 2021, which presented 247 patients with Hoigné's syndrome: 37 children and 211 adults with a male: female ratio of 2.1 : 1.0. The patients presented within 1 min after parenteral administration of a drug (intramuscular penicillin in 90 % of the cases) with chest discomfort, shortness of breath, fear of death, psychomotor agitation, and auditory or visual hallucinations and impairment. Recovery occurred within 30 min.

The diagnosis of Hoigné's syndrome was also established in five patients 66–91 years of age with pre-existing cardiovascular or pulmonary diseases, who suddenly died after the administration of penicillin despite not exhibiting the aforementioned symptoms. It was therefore speculated that pulmonary drug micro-embolization induced a lethal cardiovascular compromise in these individuals. Histologic investigations supporting this hypothesis were performed in only one case. The diagnosis of Hoigné's pulmonary drug micro-embolization was established also in five patients with pre-existing cardiovascular or pulmonary diseases, who suddenly died after the administration of penicillin despite not exhibiting the afore mentioned symptoms. Histologic investigations supporting this hypothesis were performed in only one case. In conclusion, Hoigné's syndrome is an uncommon non-immune-mediated reaction. This report seeks to promote broader awareness and knowledge regarding this alarming mimicker of anaphylaxis. Diagnosis relies solely on clinical evaluation.

* Corresponding author. Epatocentro Ticino, Lugano, Switzerland.

E-mail address: benedetta.terziroli@hin.ch (B. Terziroli Beretta Piccoli).

Equally contributed, co-first authors.

¹ Equally contributed, co-last authors.

1. Introduction

Anaphylaxis is an acute multisystem syndrome resulting from the sudden release into bloodstream of mast cell- and basophil-derived mediators [1,2]. While the majority of cases stem from immunoglobulin E-mediated response to insect stings, foods, or medications, it can also be triggered through non-immunologic mechanisms capable of inducing degranulation of mast cells or basophils [1,2]. Anaphylaxis triggered by medication occurs minutes to hours after administration and is characterized by the onset of typical skin and mucosal manifestations together with respiratory compromise, cardiovascular involvement, or gastrointestinal symptoms [1,2].

Common disorders that mimic anaphylaxis include urticaria, angioedema, asthma, syncope, and especially panic attack triggered by needle phobia [1–4]. Textbooks and reviews do not or only marginally mention Hoigné's syndrome, a further mimicker of anaphylaxis. It is unanticipated and usually occurs immediately after the intramuscular administration of a drug, frequently a penicillin depot formulation such as penicillin G procaine [5,6]. Affected patients characteristically present with acute onset of chest discomfort, shortness of breath, fear of death, psychomotor agitation, auditory or visual hallucinations and impairment, which typically rapidly abate. Hoigné's syndrome has so far been documented in original case reports and in small cases series. Because it has never been categorized or comprehensively reviewed, we performed a structured literature review.

2. Methods

Institutional Review Board approval was not a prerequisite for this literature study. The review was pre-registered at the International Prospective Register of Systematic Reviews (PROSPERO CRD42023392962) and carried out following the second edition of the Preferred Reporting Items for Systematic Reviews and Meta-Analyses guidelines in accordance with the Joanna-Briggs Manual [7].

2.1. Data collection

The search was carried out between August and October 2022 in Excerpta Medica, National Library of Medicine, and Google Scholar [8] without any publication date or language restriction and repeated before submission (September 8, 2023). The search strategy included the terms Hoigné's syndrome, pseudo-anaphylactic reaction, and acute non-allergic reaction.

2.2. Inclusion criteria

Based on a preliminary draft published approximately 15 years ago [5] and on our experience [6], three provisional diagnostic criteria were proposed in a consensus development conference among the authors of this report. The diagnosis of Hoigné's syndrome is made if all three following criteria are met: 1) sudden onset of chest discomfort, shortness of breath, fear of death, psychomotor agitation, hallucinations (auditory, gustatory, somatic, or visual), auditory or visual disturbances; 2) symptoms arise within 5 min after the parenteral administration of a drug; and 3) exclusion of anaphylaxis, mimickers of anaphylaxis including urticaria, angioedema, asthma, syncope, panic attack triggered by needle phobia [1–4], and local anesthetic systemic toxicity [9].

2.3. Definition of symptoms and signs - data extraction

The clinical features were classified as depicted in Table 1. For the present study, we meticulously extracted for each case following ten variables: 1. age, 2. sex, 3. incriminated drug, 4. history of past injections of the same drug, 5. administration route, 6. time latency, 7. clinical features (Table 1), 8. acute pharmacological management, 9. duration of symptoms, and 10. clinical outcome. Temporal relationships

were addressed as follows: latency (in minutes) was defined as the time from drug administration to symptoms onset; duration (in minutes) was defined as the period from event initiation to conclusion. Two authors (D.C., G.B.) separately performed the literature search, the data extraction, and the comprehensiveness evaluation of each retained case in duplicate. Disagreements were discussed, and a senior author (M.G. B.) was involved for any remaining discrepancy. One author (D.C.) entered the data into a pre-defined worksheet and the second author (G. B.) verified the accuracy of data entry.

2.4. Analysis

Comprehensiveness of each reported case was judged using the aforementioned ten variables. Each extracted variable was rated as 1 if the feature was adequately addressed, and 0 if it was not. The reporting comprehensiveness [10] was graded according to the sum as excellent (≥ 8), good (6–7), or satisfactory (4–5). Categorical variables are shown as counts (with percentage), numerical variables as median (with interquartile range). GraphPad Prism 10.1.1 (GraphPad Software, San Diego, California, United States of America) was used for statistics.

3. Results

3.1. Search results

The literature search process is summarized in Fig. 1. For the final analysis, we retained 71 reports [6,11–80] published between 1951 and 2021 in English (N = 31), Polish (N = 11), German (N = 9), French (N = 7), Czech (N = 2), Hebrew (N = 2), Italian (N = 2), Serbian (N = 2), Slovak (N = 2), Croatian (N = 1), Danish (N = 1), Dutch (N = 1) and Spanish (N = 1). They had been reported from the following continents: 48 from Europe (Poland, N = 13; Germany, N = 7; France, N = 5; Switzerland, N = 4; United Kingdom, N = 4; Slovakia, N = 3; Italy, N = 2; Netherland, N = 2; Serbia, N = 2; Croatia, N = 1; Czech Republic, N = 1; Denmark, N = 1; Hungary, N = 1; Spain, N = 1; Sweden, N = 1), 12 from America (United States, N = 12), five from Asia (Israel, N = 3; India, N = 1; Türkiye, N = 1), three from Africa (Cameroon, N = 1;

Table 1

Classification of clinical features utilized for the present analysis. The term used in the original report without further specification was also retained (for instance the term altered level of consciousness was used even if reported without any specification).

-
- Abnormal heart rate: heart beating increased, decreased, or irregular, sudden cessation of cardiac activity (arrest).
 - Altered level of consciousness: reduced alertness or inability to arouse due to low awareness of the environment.
 - Anxiety: feeling of unease, such as excessive worry or fear.
 - Auditory or visual impairment: hearing or vision limitation.
 - Chest discomfort: pain, pressure, tightness, or other discomfort in the chest.
 - Confusion: acute onset of disordered attention with diminished speed, clarity, and coherence of thought.
 - Dizziness: feeling faint, woozy, weak, or unsteady.
 - Elevated blood pressure: increase in blood pressure.
 - Fear of death: acute onset of fear of death.
 - Hallucinations (auditory, gustatory, somatic, or visual): false perceptions occurring in the absence of a real sound, taste, touch or visual stimulus.
 - Impaired voluntary movements: weakness or loss of muscle function.
 - Pain: unpleasant sensation associated with, or resembling that associated with, actual or potential tissue damage including headache and head pressure (chest pain was not included).
 - Psychomotor agitation: state of motor restlessness and mental tension, including violence.
 - Seizure: sudden, irregular, involuntary movements of the body.
 - Sensory disturbances (hyperesthesia, hypoesthesia or paresthesia): abnormal increase in sensitivity to stimuli of the sense, reduced sense of touch or sensation, or abnormal touch sensation such as burning or pricking.
 - Shortness of breath: air hunger, difficulty breathing, breathlessness or a feeling of suffocation.
 - Troubles speaking: difficult verbal communication.
-

Morocco, N = 1; Nigeria, N = 1), and three from Oceania (Australia, N = 1; French Polynesia, N = 1; Papua New Guinea, N = 1). The mentioned reports addressed 252 patients with Hoigné’s syndrome: 247 who fulfilled the characteristic features and five who suddenly died after intramuscular drug administration.

Reporting comprehensiveness was excellent in 175 (69 %), good in 66 (26 %), and satisfactory in the remaining 11 (4.3 %) cases.

3.2. Findings

- Characteristic cases

The features of the 247 patients fulfilling our diagnostic criteria and the offending drugs are presented in Table 2: approximately 90 % of cases occurred in adults, were temporally associated with the intramuscular administration of penicillin G (alone, or more frequently, combined with procaine) and occurred with a latency of 1 min or less. The drug implicated in the reaction had been previously administered in more than 90 % of cases. Finally, the duration was 30 min or less in about 90 % of cases. The clinical presentation is depicted in Fig. 2. Fear of death, auditory hallucinations, abnormal heart rate, psychomotor

agitation, and visual hallucinations were reported in one third or more of cases. Between 15 and 30 % of patients presented with dizziness, elevated blood pressure, shortness of breath, visual impairment, anxiety, altered level of consciousness, sensory disturbances (such as hyperesthesia, hypoesthesia, paresthesia), and confusion. Two hundred and forty-seven (98 %) cases recovered uneventfully.

A pharmacologic intervention was implemented in no more than 67 (27 %) of the 247 patients: benzodiazepines (N = 26), barbiturates (N = 17), antipsychotic drugs (N = 2), corticosteroids (N = 18), positive inotropic drugs (N = 6), antihistamines (N = 4), or bronchodilators (N = 3).

Recurrence was observed in four cases (two females and two males, aged 18, 33, 44, and 59 years). Among them, one recurred with the previously administered medication, namely, intravenous ceftriaxone [74], while the remaining three cases recurred with different drugs [31, 33,40].

- Lethal cases

Five patients [26,76] with pre-existing chronic cardiovascular or pulmonary diseases suddenly died immediately after the intramuscular

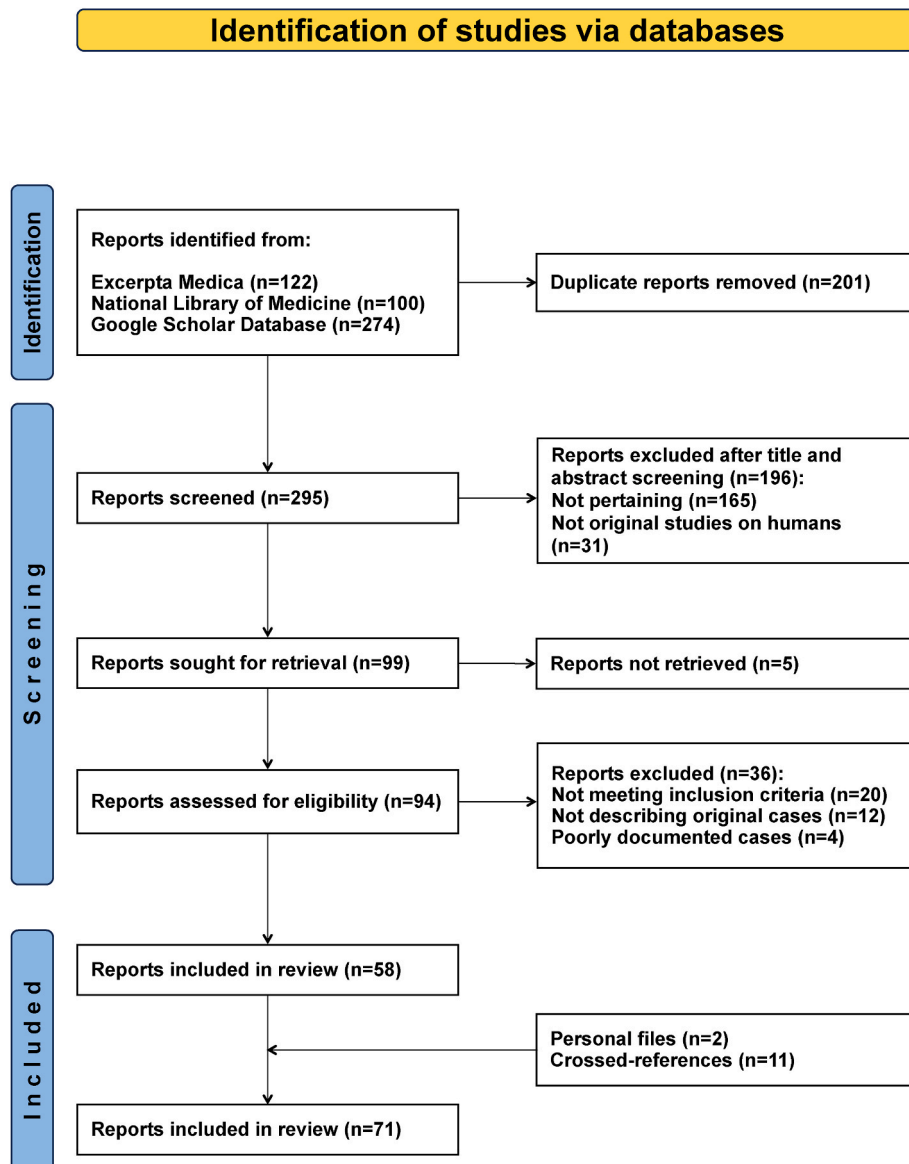


Fig. 1. Hoigné’s syndrome: systematic literature review. Flowchart of the literature search.

Table 2

Characteristics of 247 patients (0–93 years of age) with Hoigné's syndrome. Results are presented as frequency (with percentage) or as median (with inter-quartile range).

Demographics, N = 232	
Male: female ratio	2.1 : 1.0
Age	
years	40 25–56]
≥18 years of age, N (%)	211 (91)
First administration, N = 213	16 (7.5)
Administration route ^a , N = 251	
Intramuscular	240 (97)
Subcutaneous	8 (3.1)
Intravenous	3 (1.2)
Incriminated drug ^a , N = 251	
Procaine penicillin G	193 (77)
Antihistamine-penicillin G combination	20 (8.0)
Penicillin G	15 (6.0)
Benzathine penicillin G	8 (3.1)
Triamcinolone	3 (1.1)
Ceftriaxone	2 (0.8)
Lidocaine	2 (0.8)
Further drugs*	8 (3.1)
Time latency, N = 225	
≤1 min	195 (87)
2–5 min	30 (13)
Duration of symptoms, N = 177	
minutes	15 [5–20]
≤30 min, N (%)	152 (86)

^a Including the four cases of recurrence; *each one case with cefotaxime, N-methylglucamine antimoniate, penicillin G procaine plus streptomycin, penethamate plus streptomycin sulphate, prednisolone, procaine, streptomycin sulphate, triamcinolone plus lidocaine.

administration of benzathine penicillin (Table 3). These patients did not meet our diagnostic criteria for Hoigné's syndrome. Post-mortem studies, performed in only one case, disclosed the existence of a diffuse non-thrombotic pulmonary drug micro-embolization and did not find any further explanation for sudden death [26]. The impressive and close temporal link between administration of penicillin and sudden death convinced the authors of the original reports that death was caused by Hoigné's micro-embolization in all cases.

4. Discussion

Hoigné's syndrome is a mimicker of anaphylaxis that was initially reported in 1951 by Batchelor [11], in 1953 by Sohval [12], in 1957 by Lewis [13], and in 1959 by Randazzo [15]. The most comprehensive descriptions [14,17], however, were made by Rolph Hoigné (1923–2004), a Swiss internist and allergologist [81]. This systematic review of the literature indicates that Hoigné's syndrome occurs in young and middle-aged adults (and sometimes also in children) with a male preponderance. The syndrome typically manifests immediately (1 min or less) after the intramuscular injection of penicillin G, often in association with a local anesthetic such as procaine or lidocaine, and rapidly spontaneously remits.

The pathophysiological mechanisms underlying Hoigné's syndrome remain speculative. However, the current assumption, dating back to the second half of the last century, posits that Hoigné's syndrome results from the unintended intravenous injection of the offending drug, leading to micro-embolization in the lungs and subsequent dissemination to other organs, including the brain [11,21]. Histopathological data support this hypothesis [26]. This assumption is further substantiated by the fact that most cases follow the administration of a depot-penicillin formulation with low water solubility, potentially resulting in the formation of micro-emboli with diameters ranging from 30 to 60 µm [19]. The features noted in the patients included in our review (on the one hand: chest discomfort or shortness of breath; on the other hand:

auditory, visual, somatic or gustatory hallucinations, visual or auditory impairment, sensory disturbances, seizures or troubles speaking) strongly reinforce this hypothesis. Hoigné's syndrome typically spontaneously and fully recovers within 30 min.

The diagnosis of Hoigné's syndrome was established in five patients with pre-existing cardiovascular or pulmonary diseases, who died immediately after the administration of penicillin despite not exhibiting any of our diagnostic criteria. While post-mortem findings supported the diagnosis of Hoigné's syndrome in only one case, we speculate that Hoigné's pulmonary micro-embolization may lead to lethal cardiovascular compromise in individuals with cardiovascular or pulmonary conditions.

In our opinion, the challenges with Hoigné's syndrome lie in its diagnosis rather than its treatment and in its prevention. Since there is not a specific treatment, the primary focus of management entails supportive measures such as excluding an anaphylactic reaction, a panic attack, and local anesthetics systemic toxicity, while focusing on cardiorespiratory monitoring. Therefore, prevention is crucial. When considering intramuscular administration of a drug, careful evaluation is necessary. Aspirating the syringe before injections is often advised to ensure the needle tip remains within the muscle [6,82]. The upper outer gluteal quadrant, the deltoid region, and the thigh should be the preferred injection sites as they contain fewer major blood vessels [6, 82].

It has been stated the Hoigné's syndrome typically occurs following intramuscular (or, less commonly, subcutaneous) drug administration, while it is not associated with intravenous drug administration [82]. Nevertheless, we have incorporated two cases where patients exhibited the distinctive features of Hoigné's syndrome after receiving intravenous antihistamine-penicillin G [21] or ceftriaxone [74]. These observations suggest that intravenously injected drugs such as for instance the concurrent administration of ceftriaxone and calcium salts, might occasionally result in the development of micro-emboli [74,83].

In addition to anaphylactic reactions [1,2], also panic attacks [3,4] and local anesthetics systemic toxicity [9] share some clinical features with Hoigné's syndrome. However, there are notable differences. Local anesthetics systemic toxicity presents with features such as perioral numbness, metallic taste, altered mental status or anxiety, visual changes, muscle twitching, and especially seizures [9]. Hallucinations are unique to Hoigné's syndrome and are not observed in local anesthetics systemic toxicity [9], anaphylactic reactions or panic attacks [3, 4]. Finally, contrary to what is observed in a panic attack [3,4], the features of Hoigné's syndrome do not occur prior to drug administration.

The terms Hoigné's syndrome and that of antibiomania have occasionally been interchanged [5,84]. The latter term refers to the gradual onset of neurobehavioral changes several days after initiating an oral antimicrobial medication such as quinolones or macrolides [85].

Currently, the prevailing assumption is that Hoigné's syndrome is a consequence of unintentional administration through the intravenous route, whereas Nicolau's syndrome is triggered by the injection of a drug directly into an artery [6,82,86]. The pathophysiology underlying the two diseases is likely similar and related to drug-induced micro-embolism. Hoigné's syndrome has rarely been described in the third millennium, unlike Nicolau's syndrome, which has been associated with several new high molecular weight drugs, including subcutaneous glatiramer [87] or even vaccines [88]. Considering the micro-embolic nature of both Nicolau's and Hoigné's syndrome, we speculate that new high molecular weight drugs such as monoclonal antibodies might also induce Hoigné's syndrome.

In clinical practice, distinguishing between anaphylaxis or panic attacks triggered by needle phobia and Hoigné's syndrome can be challenging [1–4]. Crucial diagnostic factors include the temporal relationship between intramuscular medication and symptom onset, as well as the clinical presentation. Panic attack symptoms typically begin before medication, whereas symptoms of anaphylaxis and Hoigné's

Hoigné’s syndrome – clinical features of 247 cases

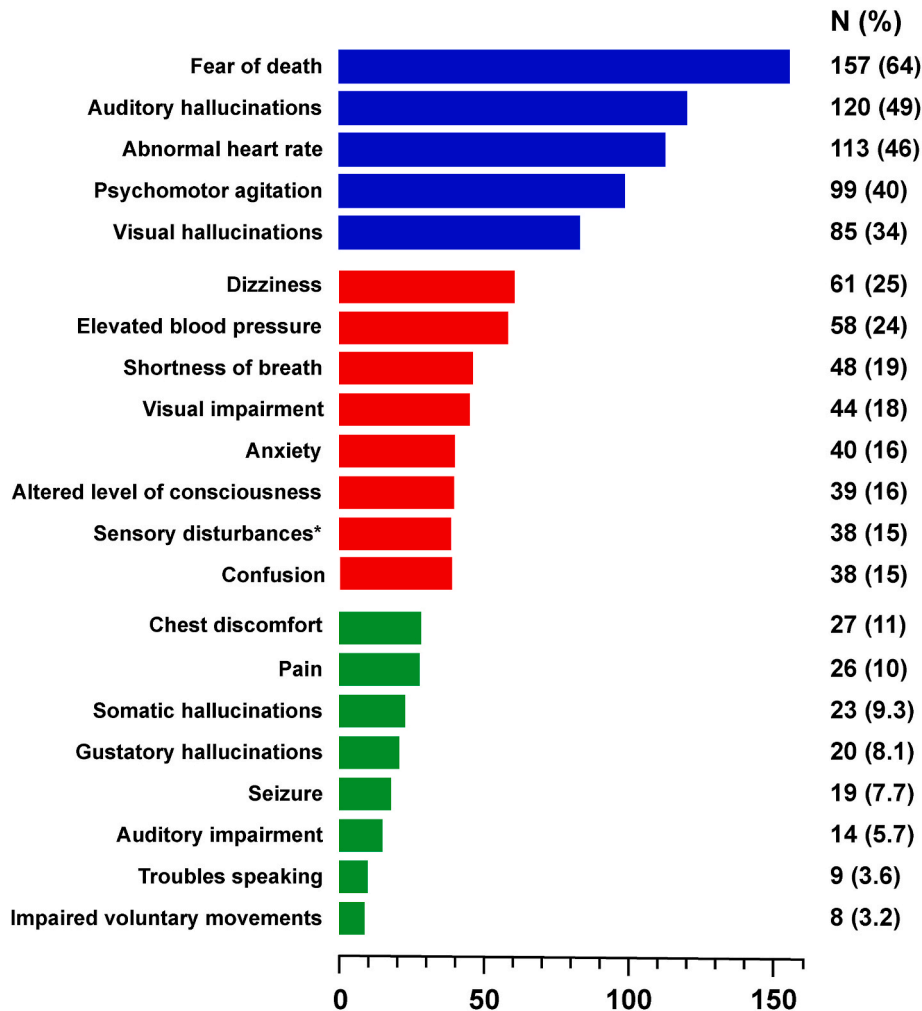


Fig. 2. Clinical features in 247 patients fulfilling the characteristic diagnostic criteria for Hoigné’s syndrome reported in the literature. The features are presented in decreasing order of frequency: blue color: >30 % of cases; red color: 15–30 % of cases; <15 % of cases. * Hyperesthesia, hypoesthesia, paresthesia.

Table 3

Characteristics of five patients chronic cardiovascular or pulmonary diseases [26,76], who died immediately after the intramuscular administration of benzathine penicillin G (in four cases diluted with lidocaine).

Patient number	1	2	3	4	5
Age, years	66	70	77	79	91
Sex	Male	Female	Female	Female	Female
Pre-existing conditions	Arterial hypertension, atrial fibrillation, heart failure, valvular heart disease, malignant lymphoma	Atrial fibrillation, heart failure, valvular heart disease	Arterial hypertension, atrial fibrillation, heart failure, peripheral vascular disease, type 2 diabetes, valvular heart disease	Heart failure, peripheral vascular disease, chronic obstructive pulmonary disease	Arterial hypertension (with left ventricular hypertrophy), atrial fibrillation, ischemic heart disease, chronic obstructive pulmonary disease, dementia
Underlying acute disease	Erysipelas	Erysipelas	Erysipelas	Pneumonia	Erysipelas

syndrome manifest afterward. Anaphylaxis is characterized by skin and mucosal lesions (itchy wheals or non-pitting swelling, predominantly around the eyes and lips), cardiovascular symptoms (increased or weak heartbeats and low blood pressure), and respiratory symptoms (increased respiratory rate, shortness of breath, and wheezing lung

sounds). In contrast, in Hoigné’s syndrome and panic attack there is no skin involvement. In these non-immune-mediated reactions, chest discomfort, shortness of breath, fear of death, psychomotor agitation, and sensory impairments are frequently experienced. Hallucinations are common in Hoigné’s syndrome but relatively rare in panic attacks.

The study has several limitations that should be acknowledged. First, over the years, the approach and the management of Hoigné's syndrome have likely demonstrated heterogeneity due to the development in medical knowledge and technology. Second, cases with positive outcome are more likely to be published (selection bias). Third, the quality in reporting individual cases varied, which could have influenced the overall reliability of the results. Despite these limitations, this review remains valuable in synthesizing existing evidence and providing insights into Hoigné's syndrome.

5. Conclusions

Hoigné's syndrome is an uncommon non-immune-mediated reaction, which presents immediately after intramuscular drug administration. Most cases occur in adults with a latency of less than 1 min after drug administration and typically resolve within 30 min. This report seeks to promote broader awareness and knowledge regarding this relatively uncommon and alarming condition, whose presentation may be confused with systemic anaphylaxis and panic attack. Diagnosis relies solely on clinical evaluation.

Statements and declarations

Declaration of Interest: None.

Funding

This research did not receive any specific grant from funding agencies in the public, commercial, or not-for-profit sectors.

References

- Cardona, I.J., Ansotegui, M., Ebisawa, Y., El-Gamal, M., Fernandez Rivas, S., Fineman, M., Geller, A., Gonzalez-Estrada, P.A., Greenberger, M., Sanchez Borges, G., Senna, A., Sheikh, L.K., Tanno, B.Y., Thong, P.J., Turner, M., Worm, World allergy organization anaphylaxis guidance 2020, *World Allergy Organ J* 13 (10) (2020) 100472, <https://doi.org/10.1016/j.waojou.2020.100472>.
- M.S. Motosue, J.T. Li, R.L. Campbell, Anaphylaxis: epidemiology and differential diagnosis, *Immunol Allergy Clin North Am* 42 (1) (2022) 13–25, <https://doi.org/10.1016/j.iac.2021.09.010>.
- D. Abadie, A. Essilini, V. Fulda, A. Gouraud, M. Yéléhé-Okouma, J. Micallef, F. Montastruc, J.L. Montastruc, Drug-induced panic attacks: analysis of cases registered in the French pharmacovigilance database, *J. Psychiatr. Res.* 90 (2017) 60–66, [10.1016/j.jpsychires.2017.02.008](https://doi.org/10.1016/j.jpsychires.2017.02.008).
- J. McLenon, M.A.M. Rogers, The fear of needles: a systematic review and meta-analysis, *J. Adv. Nurs.* 75 (1) (2019) 30–42, [10.1111/jan.13818](https://doi.org/10.1111/jan.13818).
- I. Hoigné-Löpfe, M. Jöhr, Psychiatric symptoms after anesthesia: antimaniomania or Hoigné's syndrome? *Paediatr. Anaesth.* 16 (4) (2006) 498–499, <https://doi.org/10.1111/j.1460-9592.2006.01861.x>.
- D. Consolascio, G. Bronz, P.F. Lardelli, G.P. Milani, S.A.G. Lava, M.G. Bianchetti, Un caso mai dimenticato, *Trib Med Tic* 86 (1–2) (2021) 15–16.
- M.J. Page, J.E. McKenzie, P.M. Bossuyt, I. Boutron, T.C. Hoffmann, C.D. Mulrow, L. Shamseer, J.M. Tetzlaff, E.A. Akl, S.E. Brennan, R. Chou, J. Glanville, J. M. Grimshaw, A. Hróbjartsson, M.M. Lalu, T. Li, E.W. Loder, E. Mayo-Wilson, S. McDonald, L.A. McGuinness, L.A. Stewart, J. Thomas, A.C. Tricco, V.A. Welch, P. Whiting, D. Moher, The PRISMA 2020 statement: an updated guideline for reporting systematic reviews, *J. Clin. Epidemiol.* 2021134 (2021) 178–189, [10.1016/j.jclinepi.2021.03.001](https://doi.org/10.1016/j.jclinepi.2021.03.001).
- N.R. Haddaway, A.M. Collins, D. Coughlin, S. Kirk, The Role of Google Scholar in evidence reviews and its applicability to grey literature searching, *PLoS One* 10 (9) (2015) e0138237, [10.1371/journal.pone.0138237](https://doi.org/10.1371/journal.pone.0138237).
- F. Vasques, A.U. Behr, G. Weinberg, C. Ori, G. Di Gregorio, A review of local anesthetic systemic toxicity cases since publication of the American Society of Regional Anesthesia recommendations: to whom it may concern, *Reg. Anesth. Pain Med.* 40 (6) (2015) 698–705, [10.1097/AAP.0000000000000320](https://doi.org/10.1097/AAP.0000000000000320).
- S.A. Vismara, A. Ridolfi, P.B. Faré, M.G. Bianchetti, S.A.G. Lava, S. Renzi, B.T. B. Piccoli, G.P. Milani, L. Kottanattu, COVID-19, coronavirus vaccines, and possible association with Lipschütz vulvar ulcer: a systematic review, *Clin. Rev. Allergy Immunol.* (2023), <https://doi.org/10.1007/s12016-023-08961-5>. Epub ahead of print.
- R.C. Batchelor, G.O. Horne, H.L. Rogerson, An unusual reaction to procaine penicillin in aqueous suspension, *Lancet* 2 (6675) (1951) 195–198, [10.1016/s0140-6736\(51\)91439-0](https://doi.org/10.1016/s0140-6736(51)91439-0).
- A.R. Sohval, Severe immediate constitutional reaction to penicillin, *J. Am. Med. Assoc.* 152 (15) (1953) 1430–1431, [10.1001/jama.1953.63690150004009c](https://doi.org/10.1001/jama.1953.63690150004009c).
- G.W. Lewis, Acute immediate reactions to penicillin, *Br. Med. J.* 1 (5028) (1957) 1153–1157, [10.1136/bmj.1.5028.1153](https://doi.org/10.1136/bmj.1.5028.1153).
- R. Hoigné, K. Schoch, Anaphylactic shock and acute nonallergic reactions following procaine-penicillin, *Schweiz. Med. Wochenschr.* 89 (1959) 1350–1356.
- S.D. Randazzo, G. Diprima, Acute hallucinatory psychoses caused by procaine penicillin in aqueous suspension, *Minerva Dermatol* 34 (6) (1959) 422–428.
- A. Björnberg, J. Selstam, Acute psychotic reaction after injection of procaine penicillin. A report of 33 cases, *Acta Psychiatr. Scand.* 35 (2) (1960) 129–139, [10.1111/j.1600-0447.1960.tb09472.x](https://doi.org/10.1111/j.1600-0447.1960.tb09472.x).
- R. Hoigné, Acute side-reactions to penicillin preparations, *Acta Med. Scand.* 171 (1962) 201–208.
- H. Dennig, W. Schwoerer, Acute procaine poisoning following the use of depot penicillin, *Dtsch. Med. Wochenschr.* 88 (1963) 532–537, <https://doi.org/10.1055/s-0028-1111976>.
- J. Bredt, Acute non-allergic reactions in the use of depot-penicillin, *Dtsch. Med. Wochenschr.* 90 (1965) 1559–1563, [10.1055/s-0028-1113375](https://doi.org/10.1055/s-0028-1113375).
- K. Bornemann, E. Schulz, R. Heinecker, Acute, non-allergic reactions following i.m. administration of clemizole-penicillin G and streptomycin, *Munch Med. Wochenschr.* 108 (15) (1966) 834–837.
- G. Clauberg, Resuscitation in embolic and toxic complication caused by intravascular administration of a depot-penicillin, *Anaesthesist* 15 (8) (1966) 284–285.
- P.M. Utley, J.B. Lucas, T.E. Billings, Acute psychotic reactions to aqueous procaine penicillin, *South. Med. J.* 59 (11) (1966) 1271–1274, [10.1097/00007611-196611000-00005](https://doi.org/10.1097/00007611-196611000-00005).
- R. Tompsett, Pseudoanaphylactic reactions to procaine penicillin G, *Arch. Intern. Med.* 120 (5) (1967) 565–567.
- B. Kunde, J. Wirth, A condition to the Hoigné-syndrome in the out-patient department, *Dtsch. Gesundheitswesen* 24 (43) (1969) 2046–2047, 23.
- M. Ondrejčka, D. Holý, I. Duris, Hoigné syndrome-nonallergic reaction to depot penicillin, *Bratisl. Lek. Listy* 52 (6) (1969) 703–708.
- G. Ernst, E. Reuter, Nicht-allergische tödliche Zwischenfälle nach Depot-Penicillin, *Dtsch. Med. Wochenschr.* 95 (1–26) (1970) 618–622.
- Y. Moene, G. Aimard, M.T. Perrenin, G. Rambaud, Acute psychotic reaction after injection of procaine penicillin, *J. Med. Lyon* 52 (215) (1971) 1323–1325.
- T.F. Downham, Non-allergic adverse reactions to aqueous procaine penicillin G, *Mich. Med.* 72 (9) (1973) 223–227.
- E. Müller, Hoigné's syndrome-like side effects following intralesional injection of triamcinolone crystalline suspension, *Arch. Klin. Exp. Dermatol.* 237 (1) (1973) 184.
- H.E. Menke, L. Peplinkhuizen, Letter: acute non-allergic reaction to aqueous procaine penicillin, *Lancet* 2 (7882) (1974) 723–724, [https://doi.org/10.1016/s0140-6736\(74\)93303-0](https://doi.org/10.1016/s0140-6736(74)93303-0).
- J. Dry, F. Leynadier, C. Damecour, A. Pradalier, D. Herman, Réaction pseudo-anaphylactique à la procaine-penicilline G (1976) Pseudo-anaphylactic reaction to procaine-penicillin G. 3 cases of Hoigne's syndrome, *Nouv. Presse Med.* 5 (22) (1976) 1401–1403.
- M. Calková, J. Vacek, Hoigné syndrome, *Cesk Psychiatr* 72 (3) (1976) 211–217.
- R. Kitzes, L. Cohen, J. Rosenfeld, Pseudoanaphylactic reaction to procaine penicillin G, *Harefuah* 90 (6) (1976) 276–277.
- S. Laskowski, W. Ratajski, Hoigné syndrome, *Wiad. Lek.* 29 (13) (1976) 1161–1164.
- J.A. Bronstein, Brulefert D. Thevenot, Pseudo-anaphylactic reactions to procaine penicillin G, *Nouv. Presse Med.* 6 (8) (1977) 653.
- B. Dowbor, J. Chmielewska, J. Cieslak-Drazkowska, Hoigné syndrome. Non-allergic reaction to sustained-action penicillin, *Wiad. Lek.* 30 (6) (1977) 433–437.
- L. Peplinkhuizen, H.E. Menke, The Hoigné syndrome, a little known side effect of procaine penicilline in aqueous solution, *Ned. Tijdschr. Geneesk.* 121 (15) (1977) 609–611.
- H. Sawa, A. Balcár-Boroń, E. Kucharski, S. Olijewski, J. Slowik, Hoigné syndrome: a non-allergic complication during penicillin administration, *Pediatr. Pol.* 52 (11) (1977) 1285–1287.
- A. Sawicki, T. Peterlejtner, Hoigné's syndrome, *Pol. Przegl. Chir.* 49 (9) (1977) 849–853.
- A. Kiejna, A. Krakiewicz, Mental disorders in the course of procaine penicillin treatment (Hoigné's syndrome), *Psychiatr. Pol.* 12 (2) (1978) 277–280.
- V. Dolezalová, Hoigné syndrome, adverse reaction following intramuscular administration of depot penicillin, *Cesk Oftalmol* 35 (1) (1979) 56–59.
- M. Kaplicki, H. Rusek-Licznar, Hoigne's syndrome, *Wiad. Lek.* 32 (11) (1979) 747–751.
- L. Kryst, H. Wanyura, Hoigné's syndrome-its course and symptomatology, *J. Maxillofac. Surg.* 7 (4) (1979) 320–326, [https://doi.org/10.1016/s0301-0503\(79\)80058-2](https://doi.org/10.1016/s0301-0503(79)80058-2).
- A. Duniewski, A. Chwilowicz, W. Potoczek-Dolińska, D. Eylmes, Case of Hoigné's syndrome in the treatment of a mandibular fracture, *Czas. Stomatol.* 33 (12) (1980) 1123–1126.
- D.J. Eggleston, Procaine penicillin psychosis, *Br. Dent. J.* 148 (3) (1980) 73–74, <https://doi.org/10.1038/sj.bdj.4804379>.
- B. Metodiev, S. Talevski, P. Bogdanov, L. Simonovska, Acute pseudoanaphylactic reaction to procaine penicillin G (PPG), *Plucne Bolesti Tuberk* 33 (2–3) (1981) 153–156.
- W. Bortkiewicz, M. Sliwińska-Kowalska, The syndrome of Hoigné in a child aged 10 years, *Otolaryngol. Pol.* 36 (1) (1982) 57–60.
- D.L. Lankin, G.M. Jewell, H.T. Grinvalsky, D.L. Fye, Psychotic-like reaction to procaine penicillin G, *Ann. Emerg. Med.* 12 (8) (1983) 507–509, [10.1016/s0196-0644\(83\)80650-7](https://doi.org/10.1016/s0196-0644(83)80650-7).

- [49] C. Graudal, T. Mortensen, Hoigné's syndrom. Hoigné's syndrome. A possible cause of collapse following parenteral administration of penicillin, *Ugeskr Laeger* 146 (28) (1984) 2095–2096.
- [50] B.J. Landis, L. Dunn, Adverse toxic reaction to aqueous procaine penicillin G, *Nurse Pract* 9 (11) (1984), 36,41–42,44.
- [51] S. Oren, Psychotic like reaction to procaine penicillin G, *Harefuah* 106 (8) (1984) 363–386.
- [52] E.O. Jalbert, Seizures after penicillin administration, *Am. J. Dis. Child.* 139 (11) (1985) 1075, 0.1001/archpedi.1985.02140130013013.
- [53] S. Press, Hoigne's syndrome, *Am. J. Dis. Child.* 139 (11) (1985) 1073–1074, 10.1001/archpedi.1985.02140130011009.
- [54] I.G. Télessy, Hoigne's syndrome, *Am. J. Dis. Child.* 140 (1) (1986) 6–7, 10.1001/archpedi.1986.02140150008004.
- [55] J.L. Cummings, C.F. Barritt, M. Horan, Delusions induced by procaine penicillin: case report and review of the syndrome, *Int. J. Psychiatr. Med.* 16 (2) (1987) 163–168, 10.2190/knqt-ueu4-gaq2-5716.
- [56] R. Rockney, A variant of Hoigne's syndrome following intramuscular cefoxitin sodium? *Am. J. Dis. Child.* 141 (5) (1987) 475–476, 10.1001/archpedi.1987.04460050017007.
- [57] T. Silber, L. D'Angelo, Doom anxiety and Hoigne's syndrome, *Am. J. Psychiatr.* 144 (10) (1987) 1365, 10.1176/ajp.144.10.1365b.
- [58] J. Kocur, J. Caban, A. Kuzitowicz-Pabich, Various central determinants of Hoigné's syndrome, *Wiad. Lek.* 41 (19) (1988) 1322–1324.
- [59] K. Pavithran, Hoigné's syndrome following benzathine penicillin, *Indian J. Sex. Transm. Dis.* 9 (1988) 74–75.
- [60] T.E. Martyak, L.M. Connelly, Pseudoanaphylaxis: two case studies, *Mil. Med.* 153 (2) (1988) 96–97.
- [61] S.T. Ilechukwu, Acute psychotic reactions and stress response syndromes following intramuscular aqueous procaine penicillin, *Br. J. Psychiatry* 156 (1990) 554–559, 10.1192/bjp.156.4.554.
- [62] G. Phelps, M. Nixon, A case of pseudoanaphylactic reaction to intramuscular procaine penicillin G (Hoigne's syndrome), *PNG Med J* 33 (2) (1990) 159–160.
- [63] C. Schmied, E. Schmied, J. Vogel, J.H. Saurat, Hoigné's syndrome or pseudoanaphylactic reaction to procaine penicillin G: a still current classic, *Schweiz. Med. Wochenschr.* 120 (29) (1990) 1045–1049.
- [64] P.O. Behan, A.M. Bakheit, Association of amyotrophic lateral sclerosis, Hoigne's syndrome and residence in Guam, *J. Neurol. Neurosurg. Psychiatry* 54 (1) (1991) 90–91, 10.1136/jnnp.54.1.90.
- [65] J. Blonska-Rudny, Hoigné syndrome and psychopathological issues, *Psychiatr. Pol.* 28 (5) (1994) 627–634.
- [66] E.M. Einterz, R.M. Einterz, Immediate nonallergic psychotic reaction to intramuscular procaine penicillin, *Int. J. Dermatol.* 34 (9) (1995) 627–629, 10.1111/j.1365-4362.1995.tb01089.x.
- [67] V. Vlahek, Hoigné's syndrome, acute toxic reaction to intramuscular penicillin G, *Pharma* 3 (4) (1995) 213–222.
- [68] P. Humbert, P. Girardin, F. Aubin, Fear of dying after intra-keleoid injection of triamcinolone acetonide and lidocaine: Hoigne's syndrome, *Ann. Dermatol. Venereol.* 128 (6–7) (2001) 762.
- [69] P. Gaig, M.J. Paniagua, Hoigne's syndrome, *Allergol. Immunopathol.* 33 (1) (2005) 57–58, 10.1157/13070611.
- [70] J. Cinová, D. Magurová, Syndróm Hoigné, *Molisa Med Listy Sarisa* 1 (2006) 9–11.
- [71] K. Mjahed, S.Y. Alaoui, S. Salam, B. Lhoucine, Acute paraplegia and pulmonary edema after benzathine penicillin injection, *Am. J. Emerg. Med.* 26 (2) (2008) 250.e1–250.e5, 10.1016/j.ajem.2007.04.013.
- [72] K. Krysta, A. Paliga, J. Leszczynska, I. Oberda, Chronic anxiety disorders after acute non-allergic reaction to penicillin, *Postepy Psychiatr i Neurol* 20 (3) (2011) 217–219.
- [73] R. Baran, Proximal nail fold intralesional steroid injection responsible for Hoigné syndrome, *J. Eur. Acad. Dermatol. Venereol.* 28 (11) (2014) 1563–1565, 10.1111/jdv.12283.
- [74] A. Landais, N. Marty, D. Bessis, M. Pages, J.M. Blard, Hoigné syndrome following an intravenous injection of ceftriaxone: a case report, *Rev. Med. Interne* 35 (3) (2014) 199–201, 10.1016/j.revmed.2013.02.027.
- [75] T.M. Thompson, J.L. Theobald, Hoigne syndrome: a little-known adverse effect of lidocaine, *Am. J. Emerg. Med.* 34 (3) (2016) 679, <https://doi.org/10.1016/j.ajem.2015.06.058>, e3-4.
- [76] M. Berkovitch, L. Ashkenazi-Hoffnung, I. Youngster, D. Shaniv, D. Dil-Nahlieli, E. Gorelik, M. Schäublin, R. Stoller, N. Karra, E. Schwartzberg, Fatal and Near-Fatal non-allergic reactions in patients with underlying cardiac disease receiving benzathine penicillin G in Israel and Switzerland, *Front. Pharmacol.* 8 (2017) 843, 10.3389/fphar.2017.00843.
- [77] C. Guarneri, G. Tchernev, U. Wollina, T. Lotti, Hoigné syndrome caused by intralesional meglumine antimoniato, *Open Access Maced J Med Sci* 5 (4) (2017) 483–485, 10.3889/oamjms.2017.136.
- [78] I. Wojciechowska, K. Jędrzyczak, T. Pawłowski, Chronic anxiety disorders after acute non-allergic reaction to procaine penicillin – case study, *Adv Psychiatrij Neurol* 26 (3) (2017) 179–183, 10.5114/ppn.2017.70549.
- [79] H. Gönüllü, S. Karadaş, M.C. Aykaç, T. Tombulb, Hoigné's syndrome following the injection of repeating benzathine penicillin G: a case report, *J. Exp. Clin. Med.* 35 (2) (2018) 45–47, 10.5835/jecm.omu.35.02.004.
- [80] D. Veličković, B. Cvetković, V.P. Petrović, Syndroma Hoigné - nealergijska reakcija nakon primene penicilina: prikaz slučaja, *Apoll Med Aesc* 18 (4) (2020) 38–41.
- [81] U.R. Müller, Professor Rolf Hoigné – ein Nachruf, *Allergo J.* 14 (2005) 102–104, 10.1007/BF03370415.
- [82] V. Saputo, G. Bruni, Nicolau syndrome caused by penicillin preparations: review of the literature in search for potential risk factors, *Pediatr. Med. e Chir.* 20 (2) (1998) 105–123.
- [83] E. Steadman, D.W. Raisch, C.L. Bennett, J.S. Esterly, T. Becker, M. Postelnick, J. M. McKoy, S. Trifilio, P.R. Yarnold, M.H. Scheetz, Evaluation of a potential clinical interaction between ceftriaxone and calcium, *Antimicrob. Agents Chemother.* 54 (4) (2010) 1534–1540, 10.1128/AAC.011111-09.
- [84] H.J. Przybyło, J.H. Przybyło, A. Todd Davis, C.J. Coté, Acute psychosis after anesthesia: the case for antibiomania, *Paediatr. Anaesth.* 15 (8) (2005) 703–705, 10.1111/j.1460-9592.2004.01525.x.
- [85] S.K. Munjampalli, D.E. Davis, Medicinal-induced behavior disorders, *Neurol. Clin.* 34 (1) (2016) 133–169, 10.1016/j.ncl.2015.08.006.
- [86] P.F. Lardelli, L.M.M. Jermini, G.P. Milani, G.G.A.M. Peeters, G.P. Ramelli, L. Zraggen, I. Terrani, M.G. Bianchetti, F. Vanoni, P.B. Faré, S.A.G. Lava, Nicolau syndrome caused by non-steroidal anti-inflammatory drugs: systematic literature review, *Int. J. Clin. Pract.* 74 (10) (2020) e13567, 10.1111/ijcp.13567.
- [87] S. Ciprian, S.A.G. Lava, G.P. Milani, M.G. Bianchetti, D. Consolascio, P.F. Lardelli, Nicolau syndrome caused by Glatiramer, *Mult Scler Relat Disord* 57 (2022) 103365, 10.1016/j.msard.2021.103365.
- [88] A.K. Kienast, D. Mentze, P.H. Hoeger, Nicolau's syndrome induced by intramuscular vaccinations in children: report of seven patients and review of the literature, *Clin. Exp. Dermatol.* 33 (5) (2008) 555–558, 10.1111/j.1365-2230w.2008.02861.x.