

## ORIGINAL ARTICLE

# Laser fetoscopy ablation for twin–twin transfusion syndrome may reduce the risk of ROP

José Luis García-Serrano<sup>1</sup>  | Elisabeth Fernández-Marín<sup>2</sup>  | Teresa Domech-Serrano<sup>1</sup>  | Benjamin Robert Stevens<sup>3</sup>  | José Uberos Fernández<sup>2</sup> 

<sup>1</sup>Department of Surgery, University of Granada, Ophthalmology Service, San Cecilio Clinical Hospital, Granada, Spain

<sup>2</sup>Neonatal Intensive Care Unit, Medicine Faculty, San Cecilio Clinical Hospital, Granada, Spain

<sup>3</sup>University of Manchester, Manchester, UK

## Correspondence

José Luis García-Serrano, Department of Surgery and his specialties, University of Granada, Avenida de la Investigación, 11, 18016 Granada, Spain.  
Email: [w7461322@ugr.es](mailto:w7461322@ugr.es)

## Funding information

Funding for open access charge: University of Granada /CBUA

## Abstract

**Purpose:** Twin–twin transfusion syndrome (TTTS) is a condition wherein monochorionic twins share a common placenta with placental anastomoses between the two foetal circulations. Most infants who survive TTTS are born prematurely. This study aimed to determine whether fetoscopic laser ablation (FLA) can reduce the risk of retinopathy of prematurity (ROP) and whether TTTS was a risk factor for ROP.

**Methods:** This single-centre, retrospective, comparative study included 32 monochorionic twins with TTTS matched for gestational age, birthweight and sex to premature twins and singletons without TTTS ( $n=68$ ; twins,  $n=34$ ; and singletons,  $n=34$ ) born between 2003 and 2022. A single ophthalmologist recorded the fundus findings. FLA was performed using Solomon's technique to separate the vascular systems of the twins with TTTS.

**Results:** The gestational age and weight of premature infants with TTTS treated with FLA were significantly higher than those of untreated infants ( $p=0.001$  and  $p=0.001$ , respectively); however, the hyaline membrane grade was lower ( $p=0.004$ ). A significant increase in weight (g/day) ( $p=0.002$ ) and lesser avascular area in the peripheral temporal retina ( $p=0.045$ ) was observed at postnatal week 4. The risk of ROP in the FLA group was 2.6 times (13.3% vs. 35.3%) lower than that in the non-FLA group; however, this difference was not significant. The incidence of any stage of ROP (25% vs. 18%) and treatment for ROP type 1 (6.25% vs. 5.9%) did not differ significantly between monochorionic twins with TTTS and premature infants without TTTS.

**Conclusion:** The gestational age of premature infants with TTTS treated with FLA was higher than that of untreated infants. Moreover, a reduction in complications of prematurity was also observed. Laser fetoscopy in twin–twin transfusion syndrome may reduce the risk of ROP, but the difference was not statistically significant in this small study.

## KEYWORDS

avascular retina, laser therapy, monochorionic twins, retinopathy of prematurity, twin–twin transfusion syndrome

## 1 | INTRODUCTION

The incidence of monochorionic diamniotic (MCDA) spontaneous twins accounts for 1 in 300 pregnancies (Lewi, 2020). Twin–twin transfusion syndrome (TTTS) is a condition wherein monochorionic twins share a common placenta with placental arteriovenous anastomoses

between the two foetal circulations (Ryan et al., 2022). TTTS is usually detected between 15 and 25 weeks of gestation. A large amount of blood is transferred through the shunt, leading to an imbalance that causes hypovolaemia in the donor foetus and hypervolaemia in the recipient foetus (Rotar et al., 2020). Oliguria and oligohydramnios are observed in the donor, whereas polyuria

This is an open access article under the terms of the [Creative Commons Attribution-NonCommercial-NoDerivs](https://creativecommons.org/licenses/by-nc-nd/4.0/) License, which permits use and distribution in any medium, provided the original work is properly cited, the use is non-commercial and no modifications or adaptations are made.

© 2023 The Authors. *Acta Ophthalmologica* published by John Wiley & Sons Ltd on behalf of Acta Ophthalmologica Scandinavica Foundation.

and polyhydramnios are observed in the recipient. TTTS is observed in 7.5%–15% of MCDA twins, and a mortality rate of 90% is observed in advanced cases that do not receive treatment (Ryan et al., 2022). Since its introduction over 30 years ago, laser surgery for TTTS has increased the survival rates of infants with TTTS. However, most survivors are born prematurely, with the gestational age at birth ranging from 24 to 32 weeks in 60% of monochorionic twins with TTTS (Lopriore et al., 2022).

TTTS can cause systolic and diastolic dysfunction in both twins, leading to a cardiovascular pathology that results in the death of one or both twins (Rotar et al., 2020). Fetoscopic laser ablation (FLA) of the placental vessels performed during the window period to separate the two foetal circulations increases the survival rate and reduces the risk of severe necrotising enterocolitis (grade 2) and cerebral injury (Gibbone et al., 2022; Halvorsen et al., 2012; Lopriore et al., 2022; Ryan et al., 2022).

The relationship between TTTS and the incidence of retinopathy of prematurity (ROP) is not well known, and contradictory results have been reported in the literature (Gschließer et al., 2015; Tollenaar et al., 2021). Therefore, this study aimed to determine whether FLA for TTTS reduces the risk of ROP and whether TTTS is a risk factor for ROP.

## 2 | MATERIALS AND METHODS

### 2.1 | Study population

In this single-centre, retrospective, comparative study, 100 premature infants born between 2003 and 2022 were retrospectively studied in accordance with our hospital's protocol for ROP (Ferrer Novella et al., 2013). This study (0586-N-21) was approved by the Ethics Committee of the University of Granada, Spain.

### 2.2 | Ophthalmologic examination

The inclusion criteria were as follows: (1) infants with a gestational age of  $\leq 30$  weeks and/or birthweight of  $\leq 1500$  g and (2) infants with a birthweight of  $< 2000$  g or gestational age of  $\geq 32$  weeks who were categorised as being at risk of ROP by the attending neonatologist (Ferrer Novella et al., 2013; Fierison et al., 2018). All premature monozygotic twins with TTTS and monozygotic twins without TTTS were included. In addition, an adjusted group comprising the subsequent two singletons born after monozygotic twins with TTTS was also included in the analysis.

All preterm infants were examined by the same paediatric ophthalmologist at postnatal week 4 (Chaves-Samaniego et al., 2020; Pérez et al., 2018). The avascular area of the retina was measured in optic disc diameters (DD), quantified and recorded with differences of 0.5 DD. The group value was the mean of the values of the avascular area in the temporal retina observed at postnatal week 4. Follow-up examinations of the retinae of preterm infants were performed according to the 'International Classification of Retinopathy of

Prematurity Revisited (ICROP, 2005)'. The infants were followed up from inclusion in the ROP protocol until discharge with full retinal vascularisation or regression of ROP after treatment with laser and/or intravitreal bevacizumab (Fierison et al., 2018).

#### 2.2.1 | Categorisation of the risk factors for ROP

The presence or absence of ROP was considered the dependent variable. The predictive factors included the avascular area of the temporal retina measured in DD (Bayramoglu & Sayin, 2022; Chaves-Samaniego et al., 2020) (Padhi et al., 2022; Pérez et al., 2018), gestational age (weeks), birthweight of the preterm infant (g), duration of mechanical ventilation (MV; days), duration of CPAP, duration of nasal cannula usage, weight gain (g/day) at 4 weeks, bronchopulmonary dysplasia, sepsis, requirement for transfusions (Uberos et al., 2023; Van Sorge et al., 2014), apnoea, the presence of ductus arteriosus, caesarean delivery, median Apgar score at 1 and 5 min, maternal age, maternal gestational diabetes, maternal hypertension, sex and degree of cerebral haemorrhage.

#### 2.2.2 | Categorisation of the risk factors for ROP in TTTS

The independent factors studied were donor twins, recipient twins and surviving twins (when only one of the twins survived). Other variables studied included TAPS, fetoscopic surgery performed to separate the anastomoses, and intrauterine week at the time of surgery. TAPS is diagnosed postnatally in patients with an inter-twin haemoglobin difference  $> 8.0$  g/dL (Tollenaar et al., 2021). Discordant growth (%) was defined as the difference between the estimated foetal weight of the larger and smaller twins divided by the weight of the larger twin (Lewi, 2020).

The stages on the Quintero scale were used as a prognostic clinical marker of TTTS. (Quintero et al., 1999; Chimenea et al., 2022,  $n=50$ ). Stage I Quintero corresponded to the lowest severity, whereas stage V Quintero corresponded to the death of one or both foetuses. Surgical intervention is required to separate the two circulatory systems in TTTS. However, surgery is contraindicated for stage-I Quintero in asymptomatic women with normal cervical length and gestational age of  $> 28$  weeks. Fetoscopic laser surgery is considered the best available treatment option for advanced stages of TTTS (stage  $\geq$  II Quintero). Fetoscopic laser surgery was performed using Solomon's technique to facilitate the complete separation of the anastomoses (Gibbone et al., 2022; Kanazawa et al., 2021; Spruijt et al., 2020).

### 2.3 | Statistical analysis

All values are expressed as the mean and standard deviation (SD). The Kolmogorov–Smirnov test was used

to determine the normality of the data distribution. Student's *t*-test and ANOVA were used for normally distributed data. The study population was analysed using the Kruskal–Wallis and Mann–Whitney *U* tests, which do not assume the normality of the data. Spearman's correlation and binary logistic regression analysis were performed to determine the predictive factors for the development of ROP if the risk factors were not normally distributed. Univariate analysis was performed using Statistical Package for the Social Sciences (SPSS 28.0, Inc., Chicago, IL, USA). TTTS and the remaining significant independent variables that modified the risk of ROP were studied. Only the risk factors with *p* values of <0.05 were considered significant. The odds ratio (OR) and 95% confidence intervals (CIs) of each predictor were calculated using a bivariate model. A binary logistic regression analysis was performed by studying the association between ROP and significant risk factors in the univariate analysis.

### 3 | RESULTS

#### 3.1 | Participant characteristics | Monochorionic twins with TTTS versus premature infants without TTTS

A total of 100 preterm infants were included in this retrospective study, and comparisons were performed between the groups of monochorionic twins with TTTS (*n*=32), without TTTS (*n*=34) and those born via simple labour (*n*=34). The groups were adjusted for gestational age, birthweight and sex (Table 1).

The percentage of monochorionic twins with TTTS delivered via caesarean section was higher than the percentage of premature infants without TTTS delivered via caesarean section (*p*=0.037). The following risk factors showed no significant differences between monochorionic twins with TTTS and premature infants without TTTS: bronchopulmonary dysplasia, ductus arteriosus, CPAP (days), weight gain (g/day) and Apgar

scores of 1 and 2 (score) (Table 1). The incidence of any stage of ROP (25% vs. 18%) and treatment for ROP type 1 (6.2% vs. 5.9%) did not differ significantly between monochorionic twins with TTTS and premature infants without TTTS. None of the patients had stage 4 or stage 5 ROP.

#### 3.2 | Univariate analysis of the association between TTTS and ROP

The predictive factors associated with an increased risk of ROP (*n*=100) in univariate analysis were avascular area of the temporal retina (papillary diameter), duration of MV (days), a greater grade of hyaline membrane (*p*=0.001), low gestational age (weeks), longer duration of CPAP (days), sepsis, the presence of apnoea, a greater number of transfusions, longer duration of nasal cannula usage (days), the presence of ductus arteriosus and weight gain (g/day) (Table 2). The non-significant variables included the presence of TTTS, Apgar scores of 1 and 2, degree of brain haemorrhage, sex and low birthweight (which was a collinear variable with gestational age).

The multivariate model for the binary logistic regression analysis of ROP and the risk factors revealed two significant variables (Nagelkerke's  $R^2=61\%$ , *p*<0.001; OR for avascular area in DD: 2.7, 95% CI: 1.6–4.5, *p*=0.001; OR for MV time in days: 1.13, 95% CI: 1.02–1.24, *p*=0.015).

#### 3.3 | Comparison between the groups of twins with TTTS: Donors, recipients and survivors

This series included 37 monozygotic twins with TTTS. The group mortality rate was 14%, that is, 5 of 37 (4 pre-natal and 1 postnatal death). Survival of at least one twin was observed in 86% of cases, whereas survival of both twins was observed in 72% of cases. Thirty-two preterm infants with TTTS, comprising 14 recipient twins, 13

**TABLE 1** Characteristics of the compared study groups. Monochorionic twins with TTTS, monochorionic twins without TTTS and singletons.

Total	Monochorionic twins with TTTS <i>n</i> = 32	Premature without TTTS <i>n</i> = 68	Monochorionic twins no TTTS <i>n</i> = 34	Singletons (no TTTS) <i>n</i> = 34	<i>p</i> Value
Gestational age (w)	29.86±2.27	29.89±1.84	29.47±2	30.31±1.7	0.73
Birthweight (g)	1227±363	1272±309	1246±378	1297±23	0.55
Sex (female)	50%	48.5%	56%	41%	0.82
Avascular area (DD)	2.34±2.2	1.72±1.4	1.68±1.3	1.76±1.33	0.15
Any ROP disease	8/32 (25%)	12/68 (17.6%)	8/34 (23.5%)	4/34 (11.8%)	0.74
ROP treatment	2/32 (6.2%)	4/68 (5.9%)	2/34 (5.9%)	2/34 (5.9%)	0.94
Intubation (days)	5.3±14	4.8±9	4.8±10	4.7±8	0.84
Caesarean section	91%*	72%	62%	82%	<b>0.03</b>
Comorbidity number	11.1±3.1*	9.4±3.4	10.2±3.8	8.5±3	<b>0.02</b>
Nasal cannula (days)	14.3±17	13.3±13.8	10±15.4	16.6±11‡	0.77

Note: All values are expressed in mean value (SD), w (weeks), g (grams), DD (papillary disk diameter), d (days), g/d (weight gain in grams/day) and *n/N* (%). *p* values: \**p*≤0.05 (significant) (monochorionic twins with TTTS vs. premature without TTTS). ‡*p*≤0.05 (significant) (monochorionic twins no TTTS vs. singletons no TTTS).

**TABLE 2** Risk factors for the development of ROP.

Risk factors	Odds ratio (95% CI)	<i>p</i> Value	<i>R</i> <sup>2</sup> Nagelkerke
Avascular area (papillary diameter)	2.96 (1.8–4.7)	0.000	50.1%
Days of intubation	1.17 (1.07–1.29)	0.001	34.8%
Degree of hyaline membrane	2.15 (1.4–3.3)	0.001	22.5%
Gestational age (weeks)	0.61 (0.47–0.8)	0.001	21.4%
Days treated with CPAP	1.08 (1.03–1.14)	0.003	13.8%
Sepsis	4.69 (1.68–13.1)	0.003	13.0%
Apnoea	18.3 (1.9–174)	0.011	12.7%
Transfusion	3.7 (1.4–10.2)	0.011	10.3%
TTTS (yes/no)	1.4 (0.5–3.9)	0.5	0.7%
Days treated with nasal cannula	1.03 (1.004–1.07)	0.03	7.6%
Ductus arteriosus	3.3 (1.17–10.1)	0.03	7.4%
Weight gain (g/day)	0.92 (0.84–1.0)	0.049	6.8%

**TABLE 3** Distinct groups of TTTS: recipients, donors, survivors and donors + recipients.

	TTTS recipients <i>n</i> = 14	TTTS donors <i>n</i> = 13	TTTS survivors <i>n</i> = 5	Donors + recipients <i>n</i> = 27	<i>p</i> Value
Total <i>n/N</i> (%)					
Gestational age (w)	30.3±2	30.3±2	27.1±2	30.3±1.9	<b>0.02</b>
Birthweight (g)	1410±317‡	1155±309‡	935±195	1281±349	<b>0.01</b>
Sex (female/male)	50% (7/14)	46% (6/13)	60% (3/5)	48% (13/27)	0.59
Avascular area (DD)	1.29±1.34	2.54±2.48	4.8±0.9	1.89±2	<b>0.004*</b>
Any stage ROP <i>n/N</i> (%)	3/14 (21%)	3/13 (23%)	2/5 (40%)	6/27 (22%)	0.4
ROP treatment	0%	2/13 (15%)	0%	2/27 (7.5%)	0.08
Intubation (days)	6.38±14	1.93±2.3	11.8±19	4.1±13	0.4
Bronchopulmonary dysplasia	16.7%	10.3%	8.8%	11.7%	0.37
Ductus arteriosus	23%	19.1%	20.6%	17.6%	0.63
Caesarean section	93%	92%	100%	92.5%	0.53
Transfusion (yes)	36%	31%	100%	<b>33%</b>	<b>0.01</b>
CPAP (days)	7±9.4	4.5±5.8	19.4±14.2	5.8±7.8	0.1
Nasal cannula (d)	10.8±7.7	14.1±24.3	25±13.2	12.4±17.5	0.11
Weight gain (g/day)	16.4±8.8	17.3±8.5	13.5±6.5	16.9±8.8	0.35
Apgar 1 (score)	5.2±2.7	5.8±2.6	4.8±2.9	5.5±2.6	0.64
Apgar 2 (score)	8.1±1.7	7.6±2	7±2.1	7.8±1.8	0.41

Note: \**p*≤0.05 (significant) is the comparison between survivors TTTS versus donors + recipients TTTS. ‡*p*≤0.05 (significant) calculated between groups (recipients TTTS vs. donors TTTS).

donor twins and 5 surviving twins, were included in the screening for ROP.

The gestational age in the TTTS survivors group was significantly lower than that in the TTTS donors + recipients group (27.1±2 weeks vs. 30.3±1.9 weeks; *p*≤0.02). The birthweight in the TTTS survivors group was significantly lower than that in the TTTS donors + recipients group (935±195 g vs. 1281±349 g (*p*≤0.01)). The rate of transfusions in the TTTS survivors group was higher than that in the TTTS donors + recipients group (*p*<0.01) (Table 3). At the same gestational age, the birthweight of TTTS recipients was significantly higher than that of TTTS donors (1410 g vs. 1155 g; *p*<0.05) (Table 3).

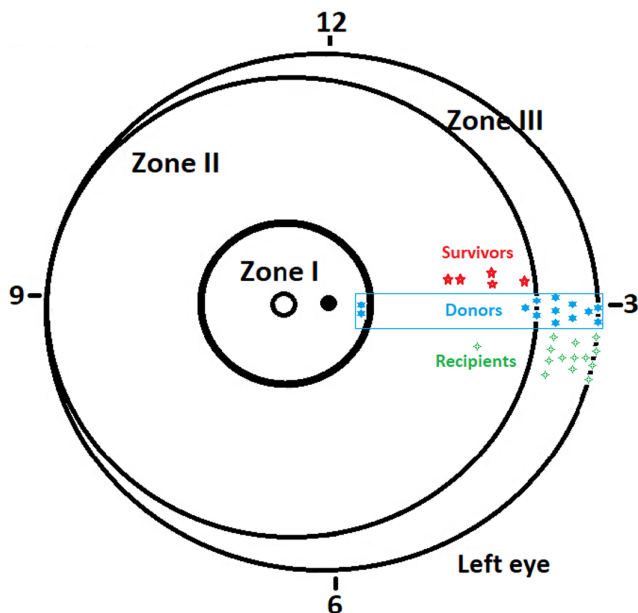
The avascular area of the temporal retina at postnatal week 4 was 4.8±0.97 DD, 2.54±2.48 DD and 1.29±1.34

DD in TTTS survivors, TTTS donors, and TTTS recipients respectively. The avascular area in TTTS survivors was significantly higher than that in TTTS recipients (*p*<0.01) and TTTS donors (*p*<0.05).

At the first ophthalmologic examination, all TTTS recipients were in Zone III, except for one who was in Zone II; all TTTS survivors were in Zone II; and TTTS donors, 10, 1 and 2 of TTTS donors were in Zones III, II and I respectively (Figure 1).

Only two TTTS donors in Zone I (2/32, 6%) were treated for type I ROP with a diode laser. They were two discordant twins with inter-twin weight discordances of 52% and 42%. The birthweights of the two treated twins were 816 and 625 g, whereas those of the untreated twins were 1713 and 1070 g.





**FIGURE 1** The avascular area in survivors versus donors versus recipients is significantly greater than those in the other two groups ( $*p < 0.05$ ,  $**p < 0.01$ ,  $***p < 0.001$ ). The stars on the right indicate the limit of the vascular/avascular area in each premature twin with twin–twin transfusion syndrome ( $n = 32$ ).

**TABLE 4** In our premature infants with TTTS, this table compares the characteristics of patients treated with fetoscopy laser ablation (FLA) versus non-FLA.

	Fetoscopy laser ablation	Non-FLA	<i>p</i> Value
<b>Total</b>	<i>n</i> = 15	<i>n</i> = 17	
Gestational age (w)	31.2 ± 2.1	28.7 ± 1.8	0.001
Birthweight (g)	1454 ± 348	1051 ± 240	0.001
Weight gain (g/day)	21.7 ± 8.5	12.2 ± 5.8	0.002
Hyaline membrane			
Grade 0–2	15/15	8/17	
Grade ≥3	0/15	9/17	0.004
Avascular area (DD)	1.47 ± 2.2	3.02 ± 2	0.045
Any ROP	2/15 (13.3%)	6/17 (35.3%)	0.15
Type 1 ROP treatment	1/15 (6.7%)	1/17 (5.9%)	0.9

### 3.4 | Solomon's laser fetoscopy technique

Among the 32 premature infants who survived, FLA was performed using Solomon's technique to separate the vascular anastomoses in 15 (Table 4). FLA was not performed in the remaining 17 infants. The mean gestational age at the time of surgery was  $20.5 \pm 2.7$  weeks, with a lower limit of 18 weeks and an upper limit of 26.6 weeks. Preterm infants were born  $10.7 \pm 3$  weeks after FLA (min, 5.3 weeks; max, 13.5 weeks). The age at birth of those who were and were not treated with FLA were  $31.2 \pm 2.1$  weeks and  $28.7 \pm 1.8$  weeks respectively. The gestational age at birth of infants treated with FLA was significantly higher than that of those who were not ( $p < 0.001$ ).

Premature infants with TTTS treated with LFA had a significantly higher gestational age ( $p < 0.001$ ), higher birthweight ( $p < 0.001$ ) and lower-grade hyaline membrane ( $p < 0.004$ ). Moreover, they gained significantly

more weight (g/day) ( $p < 0.002$ ) and had a smaller avascular area in the peripheral temporal retina (DD) at postnatal week 4 ( $p < 0.045$ ). The risk of ROP was 2.6 times (13.3%/35.3%) lower in the FLA group than in the non-FLA; however, this difference was not significant (Table 4). These significant differences disappeared after adjusting for gestational age.

## 4 | DISCUSSION

The relationship between ROP and TTTS is not well known. TTTS has a low incidence of approximately 1 in 2000 live births. Thus, conducting epidemiological studies with a large number of cases of TTTS is difficult. The risk of ROP was 20% in this sample ( $n = 100$ ), which screened premature infants at a gestational age of 29.9 weeks, and the results were obtained from a referral centre. El Emrani et al. (2023) reported the same percentage of ROP in TTTS in a multicentre study ( $n = 294$ ). Performing FLA for the treatment of TTTS resulted in an increase in the gestational age and birthweight in the present study. This may have affected the results when studying the association between TTTS and ROP, as the twins born following treatment with FLA were more mature than those who were born without treatment (Duy Anh et al., 2022,  $n = 12$  LFA). This may have affected the overall result.

Nallasamy et al. (2009,  $n = 5$ ) reported that foetal surgery performed for the treatment of TTTS appeared to increase the incidence of ROP and threshold ROP development. Gschließer et al. (2015,  $n = 17$ ) reported that TTTS is a risk factor for ROP. No increased risk for ROP was observed in premature infants with TTTS ( $n = 32$ ) in the present study. Sommer et al. (2018) reported that the risk of ROP in monochorionic TTTS twins treated with FLA ( $n = 13$ ) was similar to that of dichorionic twins without TTTS in both groups.

The low number of patients with TTTS in many of these studies, including the present study, makes it difficult to draw a definitive conclusion regarding whether TTTS is a risk factor for ROP, especially when two confounding factors are introduced: (a) for every weekly decrease in gestational age, there was a median of 1.4 times the odds of developing ROP (Yu et al., 2022). In the present study and the study by El Emrani et al., wherein the gestational age at birth was 29.9 and 29.6 weeks, respectively, the risk of ROP in TTTS was 20%. In the studies by Gschließer et al. and Sommer et al., wherein the gestational age at birth was 27 and 26.4 weeks, respectively, the risk of ROP was 82% and 70%. (b) FLA reduced mortality and modified the natural history of TTTS.

No relationship was observed between the risk of severe ROP ( $\geq$ stage 3) and TTTS, with incidences of 6% to 42% respectively (Gschließer et al., 2015; Halvorsen et al., 2012). The incidence of ROP requiring treatment was similar between patients with and without TTTS (Sommer et al., 2018). No difference was observed in the need for treating ROP in patients with and without TTTS. The treatment of ROP in TTTS with laser is mostly related to the degree of prematurity (Gibbone et al., 2022) and TTTS donors (El Emrani et al., 2023).

The most significant risk factor for ROP in the present study was the avascular area in the peripheral temporal retina at postnatal week 4. However, the sample size of the present study was small, and no differences were observed among survivors, donors and recipients in terms of the risk of ROP. The area of the avascular region in TTTS survivors was larger than that in TTTS donors + recipients. This finding is justified as caesarean section is performed early given the high vital risk of TTTS survivors, and they are born at a lower gestational age. However, El Emrani et al. (2023) ( $n=294$ ) reported that TTTS donors have a twofold increased risk of ROP and severe ROP compared with TTTS recipients. This finding may be attributed to the ischaemic area in the retina in donors being greater than that in recipients at the same gestational age. However, this finding needs to be corroborated by other studies. Further studies must be conducted to determine whether this difference exists in other vascular beds (Krispin et al., 2023) and whether it has an impact on the risk of neurological morbidity (D'Antonio et al., 2023). A larger retinal avascular area is significantly associated with a greater risk of ROP requiring treatment (Chaves-Samaniego et al., 2020).

Solomon's technique (Ling et al., 2023) is an FLA technique that enables the complete separation of the foetal circulation in monozygotic twins with TTTS. Cauterisation of the visible anastomoses is performed in this technique, followed by laser cauterisation from one edge of the placenta to the other and the vascular equator (Spruijt et al., 2020). Patients with TTTS treated with FLA versus those who were not treated with FLA had significantly higher gestational ages and birthweights (Cruz-Martínez et al., 2023), with lower grades of hyaline membranes. Moreover, the daily weight gain was higher, the avascular area was smaller and the risk of ROP was lesser in the 4th week of gestation. However, after adjusting for gestational age, these significant differences disappeared. FLA facilitates a longer duration of gestation without mortality. A more mature preterm child has reduced morbidity at birth. It decreases the risk of severe morbidity and increases survival (Kanazawa et al., 2021; Lopriore et al., 2022; Mustafa et al., 2022). Despite statistically non-significant results in our small study, laser fetoscopy ablation may behave as a protective factor against the risk of ROP because it allows a greater number of weeks in utero. This allows the development of a more physiological intrauterine vascularisation of the retina.

But there are weaknesses in our study such as small number of cases of treated TTTS, small numbers of type 1 ROP, uncertainty regarding the reliability of 0.5 DD measurements in a retrospective study and the unmasked nature of fundus examinations with possible observer bias. TTTS monochorionic occurs at a low incidence but is associated with a significant number of complications in premature infants. Fetoscopy laser ablation separates the circulation of both twins, making them behave like diamniotic twins. This procedure allows gestation to continue further than if not separated. The primary outcome of this procedure was increased gestational period (31.7 weeks vs. 28.7 weeks if untreated), with the reduction in complications of prematurity being the

'secondary' outcome. Our reference sample is one of the larger ones in the literature on preterm infants treated with FLA who have followed the retinopathy of prematurity protocol. The strengths of this study lie in the fact that FLA modifies the natural course of TTTS and allows the birth of more mature premature infants and may therefore lower the risk of ROP. At 4 weeks postnatal age, donor twins have a greater ischaemic area of the retina than recipient twins.

#### AUTHOR CONTRIBUTIONS

JLGS designed the data analysis and interpretation of the results, co-wrote the manuscript and critically reviewed its contents. J L G-S and E F-M conceived and designed the study. J L G-S, E F-M and T D-S analysed the data. J L G-S performed ophthalmological examinations. J L, G-S, E F-M, T D-S and J U wrote the manuscript. J L G-S, E F-M, T D-S, J U and B R S critically revised the manuscript. All authors have read and approved the final manuscript. This article contains parts of Fernández-Marín's thesis.

#### ACKNOWLEDGEMENTS

The authors thank the participants of this study, the nursing staff of the neonatal unit. The authors also thank Molina-García FS for their invaluable collaboration in this study.

#### FUNDING INFORMATION

Funding for open access charge: University of Granada / CBUA.

#### ETHICS STATEMENT

The study protocol (0586-N-21) was approved by the Biomedical Research Ethics Committee of Granada Province (CEIM/CEI Granada, Spain), and all current regulations regarding data confidentiality were respected.


#### INFORMED CONSENT

Informed consent was obtained from the parents or caregivers of the preterm infants.

#### ORCID

José Luis García-Serrano  <https://orcid.org/0000-0002-3798-1186>

Elisabeth Fernández-Marín  <https://orcid.org/0000-0002-8595-8730>

Teresa Domech-Serrano  <https://orcid.org/0000-0001-9887-2496>

Benjamin Robert Stevens  <https://orcid.org/0000-0001-6650-586X>

José Uberos Fernández  <https://orcid.org/0000-0002-3519-6678>

#### REFERENCES

- Bayramoglu, S.E. & Sayin, N. (2022) Inter-eye comparison of retinal vascular growth rate and angiographic findings following unilateral bevacizumab treatment. *European Journal of Ophthalmology*, 32(3), 1430–1440.
- Chaves-Samaniego, M.J., García Castellón, M., Chaves-Samaniego, M.C., Solans Perez Larraya, A., Ortega Molina, J.M., Muñoz Hoyos, A. et al. (2020) Risk calculator for retinopathy of

- prematurity requiring treatment. *Frontiers in Pediatrics*, 8, 529639. Available from: <https://doi.org/10.3389/fped.2020.529639>
- Chimenea, A., García-Díaz, L. & Antiñolo, G. (2022) Mode of delivery, perinatal outcome and neurodevelopment in uncomplicated monochorionic diamniotic twins: a single-center retrospective cohort study. *BMC Pregnancy and Childbirth*, 22(1), 89.
- Cruz-Martínez, R., Gil-Pugliese, S., Enciso-Meraz, J.M., Villalobos-Gómez, R., López-Briones, H., Martínez-Rodríguez, M. et al. (2023) Management of late a twin-to-twin transfusion syndrome beyond 26 weeks: comparison between fetoscopic laser therapy vs. *Traditional Management*. *Fetal Diagn Ther*, 50, 464–471. Available from: <https://doi.org/10.1159/000533202>
- D'Antonio, F., Marinceu, D., Prasad, S., Eltaweel, N. & Khalil, A. (2023) Outcome of twin-twin transfusion syndrome complicated by selective fetal growth restriction: systematic review and meta-analysis. *Ultrasound in Obstetrics & Gynecology*, 62, 320–327. Available from: <https://doi.org/10.1002/uog.26252>
- Duy Anh, N., Duy An, N., Huyen Thuong, P.T., Thu Ha, N.T., Sim, N.T., Sy Hung, H. et al. (2022) The efficacy of fetoscopic laser surgery in twin-twin transfusion syndrome: a preliminary Vietnamese study. *La Clinica Terapeutica*, 173(3), 265–273.
- El Emrani, S., Groene, S.G., Spekman, J.A., Slaghekke, F., van der Meeren, L.E., Schalijs-Delfos, N.E. et al. (2023) Increased risk of retinopathy of prematurity in donors with twin-to-twin transfusion syndrome: a cohort study. *Fetal Diagnosis and Therapy*, 50(3), 187–195. Available from: <https://doi.org/10.1159/000530729>
- Ferrer Novella, C., González Viejo, I., Pueyo Royo, V., Martínez Fernández, R., Galdós Iztueta, M., Peralta Calvo, J. et al. (2013) Screening program for retinopathy of prematurity in Spain. *Archivos de la Sociedad Española de Oftalmología*, 88(5), 184–188.
- Fierison, W.M., American Academy of Pediatrics Section on Ophthalmology, American Academy of Ophthalmology, American Association for Pediatric Ophthalmology and Strabismus & American Association of Certified Orthoptists. (2018) Screening examination of premature infants for retinopathy of prematurity. *Pediatrics*, 142(6), e20183061.
- Gibbone, E., Campos, R.V., Calero, A.J., Lucena, P.C. & Molina-García, F.S. (2022) Perinatal and long-term outcome of endoscopic laser surgery for twin-twin transfusion syndrome with and without selective fetal growth restriction: a retrospective cohort study. *Prenatal Diagnosis*, 42(11), 1438–1447.
- Gschließer, A., Stifter, E., Neumayer, T., Moser, E., Papp, A., Dorner, G. et al. (2015) Twin-twin transfusion syndrome as a possible risk factor for the development of retinopathy of prematurity. *Graefes Archive for Clinical and Experimental Ophthalmology*, 253(1), 151–156.
- Halvorsen, C.P., Ek, S., Dellgren, A., Grunewald, C., Kublickas, M., Westgren, M. et al. (2012) Survival and neonatal outcome after fetoscopic guided laser occlusion (FLOC) of twin-to-twin transfusion syndrome (TTTS) in Sweden. *Journal of Perinatal Medicine*, 40(5), 533–538.
- International committee for the classification of retinopathy of prematurity. (2005) The international classification of retinopathy of prematurity revisited. *Archives of Ophthalmology*, 123, 991–999.
- Kanazawa, S., Ozawa, K., Muromoto, J., Sugibayashi, R., Wada, Y., Wada, S. et al. (2021) Risk profiling of the Solomon technique versus selective technique of fetoscopic laser surgery for twin-twin transfusion syndrome. *Twin Research and Human Genetics*, 24(1), 42–48.
- Krispin, E., Mustafa, H.J., Espinoza, J., Nassr, A.A., Sanz Cortes, M., Donepudi, R. et al. (2023) Prediction of dual survival following fetoscopic laser photocoagulation for twin-twin transfusion syndrome. *Ultrasound in Obstetrics & Gynecology*, 61(4), 511–517.
- Lewi, L. (2020) Monochorionic diamniotic twins: what do I tell the prospective parents? *Prenatal Diagnosis*, 40(7), 766–775.
- Ling, D., Phelps, A., Tate, T., Adefisoye, J., Mehra, S. & Prazad, P. (2023) Perinatal and neonatal outcomes for fetoscopic laser ablation for the treatment of twin transfusion syndrome at a single center. *Journal of Perinatology*, 43(2), 147–154.
- Lopriore, E.A., Slaghekke, F., Verweij, E.J., Haak, M.C., Middeldorp, A.J.M. & Lopriore, E. (2022) Neonatal outcome in twin-to-twin transfusion syndrome not treated with fetoscopic laser surgery. *Twin Research and Human Genetics*, 25(1), 45–49.
- Mustafa, H.J., Javinani, A., Goetzinger, K. & Turan, O.M. (2022) Single fetal demise following fetoscopic ablation for twin-to-twin transfusion syndrome-cohort study, systematic review, and meta-analysis. *American Journal of Obstetrics and Gynecology*, 227, 550–551.
- Nallasamy, S., Davidson, S.L., Howell, L.J., Hedrick, H., Flake, A.W., Crombleholme, T.M. et al. (2009) The effects of fetal surgery on retinopathy of prematurity development. *Ophthalmol Eye Dis*, 1, 13–19.
- Padhi, T.R., Bhusal, U., Padhy, S.K., Patel, A., Kelgaonker, A., Khalsa, A. et al. (2022) The retinal vascular growth rate in babies with retinopathy of prematurity could indicate treatment need. *Indian Journal of Ophthalmology*, 70(4), 1270–1277.
- Pérez, S., de Larraya, A.M., Ortega Molina, J.M., Fernández, J.U., Escudero Gómez, J., Salgado Miranda, A.D. et al. (2018) Retinal vascular speed <0.5 disc diameter per week as an early sign of retinopathy of prematurity requiring treatment. *European Journal of Ophthalmology*, 28(4), 441–445.
- Quintero, R.A., Morales, W.J., Allen, M.H., Bornick, P.W., Johnson, P.K. & Kruger, M. (1999) Staging of twin-twin transfusion syndrome. *Journal of Perinatology*, 19(8 Pt 1), 550–555.
- Rotar, I.C., Zaharie, G., Staicu, A., Preda, A. & Mureşan, D. (2020) Fetal cardiovascular alterations in twin-to-twin transfusion syndrome. *Med Pharm Rep*, 93(1), 5–11.
- Ryan, G.A., Finnegan, C., McAuliffe, F.M., Malone, F.D., Müllers, S.M., Corcoran, S. et al. (2022) Fetoscopic laser ablation for twin-to-twin transfusion syndrome: a 15-year review of perinatal survival. *Irish Medical Journal*, 115(5), 595.
- Sommer, J., Nuyt, A.M., Audibert, F., Dorval, V., Wavrant, S., Altit, G. et al. (2018) Outcomes of extremely premature infants with twin-twin transfusion syndrome treated by laser therapy. *Journal of Perinatology*, 38(11), 1548–1555.
- Spruijt, M.S., Lopriore, E., J., Steggerda, S.J., Slaghekke, F. & Van Klink, J.M.M. (2020) Twin-twin transfusion syndrome in the era of fetoscopic laser surgery: antenatal management, neonatal outcome and beyond. *Expert Review of Hematology*, 13(3), 259–267.
- Tollenaar, L.S.A., Slaghekke, F., Lewi, L., Colmant, C., Lanna, M., Weingertner, A.S. et al. (2021) Spontaneous twin anemia polycythemia sequence: diagnosis, management, and outcome in an international cohort of 249 cases. *American Journal of Obstetrics and Gynecology*, 224(2), 213.e1–213.e11.
- Uberos, J., Fernández-Marín, E., Campos-Martínez, A., Ruiz-López, A. & García-Serrano, J.L. (2023) Blood products transfusion and retinopathy of prematurity: a cohort study. *Acta Ophthalmologica*, 101(3), e294–e301.
- Van Sorge, A., Kerkhoff, F., Halbertsma, F.J. & Schalijs-Delfos, N. (2014) Severe retinopathy of prematurity in twin-twin transfusion syndrome after multiple blood transfusions. *Acta Ophthalmologica*, 92(2), e167–e168.
- Yu, C.W., Popovic, M.M., Dhoot, A.S., Arjmand, P., Muni, R.H., Tehrani, N.N. et al. (2022) Demographic risk factors of retinopathy of prematurity: a systematic review of population-based studies. *Neonatology*, 119(2), 151–163.

**How to cite this article:** García-Serrano, J.L., Fernández-Marín, E., Domech-Serrano, T., Stevens, B.R. & Uberos Fernández, J. (2023) Laser fetoscopy ablation for twin-twin transfusion syndrome may reduce the risk of ROP. *Acta Ophthalmologica*, 00, 1–7. Available from: <https://doi.org/10.1111/aos.16608>