

Anatomical variation of the branching of the Celiac Trunk: case report

Variação anatômica da ramificação do Tronco Celíaco: relato de caso

DOI:10.34119/bjhrv5n6-071

Recebimento dos originais: 11/10/2022

Aceitação para publicação: 14/11/2022

Letícia de Oliveira Botelho

Graduanda em Medicina

Institution: Faculdade de Ciências Médicas de Minas Gerais

Address: Alameda Ezequiel Dias, 275, Centro, CEP 30130-10, Belo Horizonte - MG, Brasil

E-mail: lebotelho99@gmail.com

Larissa Couto Castro

Graduanda em Medicina

Institution: Faculdade de Ciências Médicas de Minas Gerais

Address: Alameda Ezequiel Dias, 275, Centro, CEP: 30130-10, Belo Horizonte - MG, Brasil

E-mail: lebotelho99@gmail.com

Maria Luiza de Alvarenga Pires

Graduanda em Medicina

Institution: Faculdade de Ciências Médicas de Minas Gerais

Address: Alameda Ezequiel Dias, 275, Centro, CEP: 30130-10, Belo Horizonte - MG, Brasil

E-mail: lebotelho99@gmail.com

Raquel Cristina Villar Barroso

Doutora em Medicina Molecular

Faculdade Ciências Médicas de Minas Gerais

Institution: Faculdade de Ciências Médicas de Minas Gerais

Address: Alameda Ezequiel Dias, 275, Centro, CEP: 30130-10, Belo Horizonte - MG, Brasil

E-mail: lebotelho99@gmail.com

ABSTRACT

Introduction: The celiac trunk originates from the descending abdominal aorta and, after a short course of one to three centimeters, divides into the left gastric, common hepatic and splenic arteries. **Methods:** We performed the dissection of the abdomen of an adult male cadaver from the Department of Anatomy, Faculdade de Ciências Médicas de Minas Gerais (CMMG). **Result:** An unusual pattern of branching of the arteries of the celiac trunk was identified, which appears to give rise to four branches: the left gastric, splenic, common hepatic and gastroduodenal arteries. **Discussion:** Due to the high miscegenation in Brazil, the frequency of anatomical variations may be different from other literature, being important studies on cadavers in this country. Knowing the anatomical variations present in the branches of the celiac trunk contributes to reducing morbidity and mortality in procedures in region, being the performance of angiotomography or angioresonance, for prior knowledge of the anatomical variations, extremely important in major surgeries. **Conclusion:** Anatomical variations in the celiac trunk are common and their knowledge is essential to avoid complications in abdominal surgical procedures.

Keywords: anatomical variations, Celiac Trunk.

RESUMO

Introdução: O tronco celíaco origina da aorta descendente abdominal e, após um trajeto curto de um a três centímetros, divide-se em artérias gástrica esquerda, hepática comum e esplênica. **Métodos:** Realizou-se a dissecação do abdome de cadáver adulto do sexo masculino do Departamento de Anatomia da Faculdade de Ciências Médicas de Minas Gerais (CMMG). **Resultado:** Identificou-se um padrão incomum de ramificação das artérias do tronco celíaco, a qual aparece dando origem a quatro ramos: as artérias gástrica esquerda, esplênica, hepática comum e gastroduodenal. **Discussão:** Devido à alta miscigenação no Brasil, a frequência das variações anatômicas podem ser diferentes das demais literaturas, sendo importante estudos em cadáveres nesse país.^{1,2} Saber das variações anatômicas presentes nos ramos do tronco celíaco contribui para reduzir a morbimortalidade em procedimentos na região, sendo a realização de angiotomografia ou angiorressonância, para conhecimento prévio das variações anatômicas, extremamente importante em cirurgias de grande porte. **Conclusão:** Variações anatômicas no tronco celíaco são comuns e seu conhecimento é fundamental para evitar complicações em procedimentos cirúrgicos abdominais.

Palavras-chave: variações anatômicas, Tronco Celíaco.

1 INTRODUCTION

The celiac trunk arises from the descending abdominal aorta at the level of the twelfth thoracic vertebra just after the aortic hiatus. Its direct branches are: left gastric artery, which supplies the lesser curvature of the stomach, common hepatic artery, and splenic artery, which supplies the spleen. This trifurcation is present in about 89% of individuals, regardless of gender.³

The common hepatic artery follows the upper border of the pancreas towards the first part of the duodenum, where it gives off the right gastric artery and gastroduodenal artery, then becomes the hepatic artery proper. This, in turn, branches into the right and left hepatic artery at the hepatic hilum. The right gastric artery travels to the lesser curvature of the stomach to anastomose with the left gastric artery. The gastroduodenal artery gives rise to a supraduodenal artery, small retroduodenal branches and divides into the right gastro-omental and anterior superior pancreaticoduodenal.⁴

However, there may be anatomical variations in these branches, even leading to implications for surgical approaches. Celiac trunk trifurcation is present in 89% of cases in the literature, bifurcation occurs in 11% and absence of this trunk occurs in 0.2%. The most described variations of the celiac trunk in the literature are: hepatosplenic trunk with left gastric artery arising directly from the aorta in 8.3% of cases and hepatogastric trunk with splenic artery

also arising from the aorta in 1.7% of cases. The absence of the celiac trunk is rare in the literature.²

The quadrifurcation of the celiac trunk most described in the literature is the presence of the gastroduodenal artery as the fourth branch in 6.74% of cases.⁵

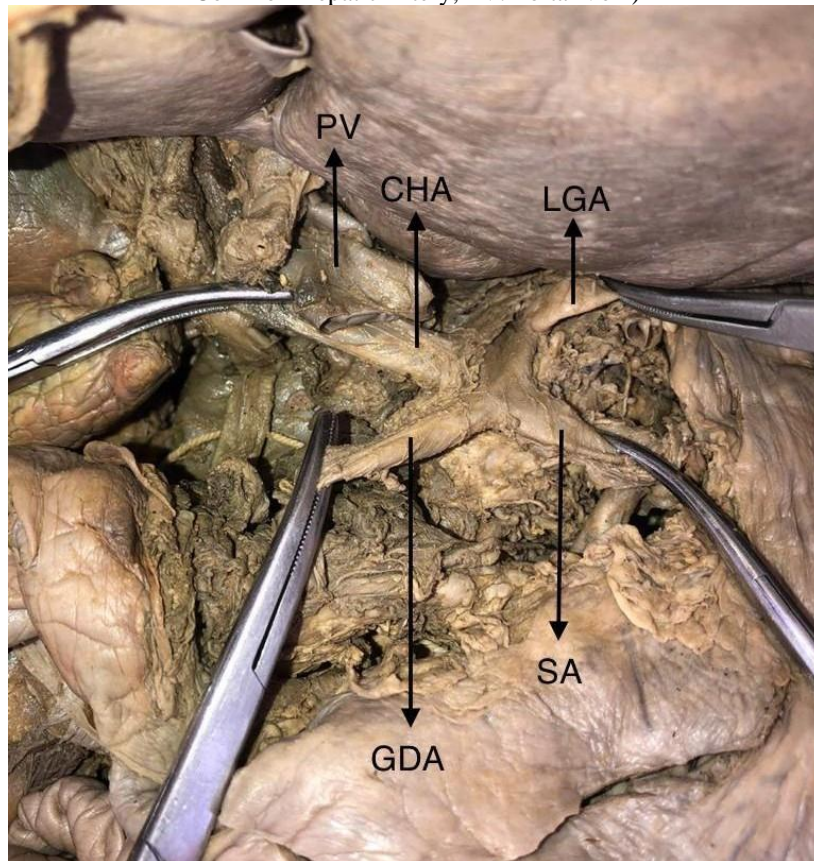
The most common anatomical variation of the hepatic arterial system was the anomalous location of the right hepatic artery in 8.5% of the cases, originating from the superior mesenteric artery in 5.1% of the cases and from the celiac trunk in 3.4% of the cases.²

The present study reports the quadrifurcation of the celiac trunk with the presence of the gastroduodenal artery as an extra branch and discusses its prevalence and importance in abdominal surgeries.

2 CASE REPORT

The dissection of the abdomen of an adult male cadaver from the Department of Anatomy of the Faculdade de Ciências Médicas de Minas Gerais (CMMG) in 2019 showed a different branching pattern of the celiac trunk artery, which presents itself as originating four direct branches, instead of three. The branches found were the left gastric, splenic, common hepatic and gastroduodenal arteries (figure 1), with the presence of the gastroduodenal artery as a direct branch of the celiac trunk being considered an anatomical variation. As expected, the left gastric artery proceeds to supply the lesser curvature of the stomach, while the splenic artery takes its usual course to the left to supply the spleen. The common hepatic artery exits directly from the celiac trunk, bifurcating into the right hepatic artery and the left hepatic artery at 3 cm from its origin. This artery forms the portal triad together with the portal vein and the common bile duct. The right gastric artery, classically a branch of the proper hepatic artery, is not visible. In this cadaver, the gastroduodenal artery exits directly from the celiac trunk, rather than originating from the common hepatic artery. The superior mesenteric artery was located isolated, below the celiac trunk, as usual. This was the only variation found in the cadaver under study. Clinical history and cause of death are unknown.

Figure 1- Celiac Trunk (LGA: Left Gastric Artery; SA: Splenic Artery; GDA: Gastroduodenal Artery; CHA: Common Hepatic Artery; PV: Portal Vein)



3 DISCUSSION

Anatomical variations in the abdominal arterial system are frequent and widely explored in the literature. Changes in the celiac trunk can be found in 25 to 75% of the population^{3,6} and variations in the hepatic arterial system can be present in between 20 and 50% of the population.^{7,8,9,10}

Thus, it is essential that these variations are studied and known, especially for surgical procedures and intra-abdominal interventional examinations.¹

Another point to be considered is that, due to miscegenation, the Brazilian anatomical variation indices may differ from the international literature, so that case reports, such as the one presented here, are fundamental to compose the range of evidence regarding variations in abdominal arteries. in this population.^{1,2}

Many authors, over time, sought to describe these variations and classify them. Some examples are the Song and Sureka classifications for different conformations of the celiac trunk,^{11,12} being recognized, according to Brasil et al., 15 types of anatomical variations for this structure.¹ Regarding the hepatic arterial system, the most common classification

widespread is that of Michels, which idealizes 10 types of possible variations for these arteries.^{1,9,13,14,15}

According to Petrella et al., four primitive ventral branches arise in the abdominal aorta and are interconnected by an anastomotic canal during embryogenesis and it is the growth or regression of these canals that lead to the different variations in the celiac trunk and superior mesenteric artery. This complex process, influenced by multiple factors, no classification has been able to address all variations, as there are numerous possibilities for variations in these structures.¹³

The variation presented here is an example of quadrifurcation of the celiac trunk, an uncommon condition, with Santos et al. found a prevalence of 8.33% of this variation in their systematic review³ and Marco-Clement et al. found approximately 0.8% in their study in 43 cadavers and 596 CT scans.¹⁶ Examples of extra branches found in the literature were gastroduodenocolic trunk, accessory hepatic artery, right hepatic artery, dorsal pancreatic artery, middle colic artery and junction of the celiac trunk with the superior mesenteric artery, forming a celiac-mesenteric trunk.^{5,6,8,16} The case in question, in which the extra artery found was the gastroduodenal artery, appears in the analyzed literature with a maximum prevalence of 6.7%, but other authors have already demonstrated prevalences of 3.6%, 2.5% and 1.6%.^{5,12} Other possible origins of the gastroduodenal artery found, in addition to the classic one, in the common hepatic artery, were right and left hepatic artery and superior mesenteric artery.^{9, 12}

Regarding the practical importance of the variation studied, it is believed that the greater the knowledge about arterial anatomical variations in the abdominal region, the better the technical operative planning, such as the identification of the best suture to be performed and the choice of the best location to make the incision. In addition, the risk of injury to structures and consequent complications is lower, contributing to a reduction in the occurrence of peri- and postoperative bleeding.¹⁵

The knowledge of this variation gains great relevance in robotic and laparoscopic surgeries, given the limited surgical field of these modalities,^{1,2} as well as in pancreas and hepatobiliary surgeries, since the direct visualization of the structures in these surgeries is complex, especially in obese patients and patients with previous surgeries.⁵

Therefore, knowing the arrangement of these arterial branches helps to reduce morbidity and mortality rates in endovascular procedures, radiological interventions such as celiacography and chemoembolization of liver tumors, abdominal surgeries and transplants, especially liver and pancreas.^{1,3} Therefore, performing CT angiography and angioresonance

for surgical planning are of great value in major surgeries,^{1,9} especially cholecystectomy, gastrectomy, pancreatoduodenectomy and liver transplant surgeries.

4 CONCLUSION

Anatomical variations of the celiac trunk are common and therefore it is important to know the frequency of each one. In order to prevent iatrogenic complications such as bleeding in surgical procedures performed in the supramesocolic region, abdominal surgeons should familiarize themselves with the anatomical variations, such as the one described. Especially due to the fact that it is a large caliber and of great importance in the irrigation of epigastric organs.

REFERENCES

Brasil, Ivelise Regina Canito et al. Computed tomography angiography study of variations of the celiac trunk and hepatic artery in 100 patients. *Radiologia Brasileira*. 2018, v. 51, n. 1 [Acessado 24 Agosto 2022] , pp. 32-36. Disponível em: <<https://doi.org/10.1590/0100-3984.2016.0179>>

Araujo, Severino Aires et al. Anatomical variations of the celiac trunk and hepatic arterial system: an analysis using multidetector computed tomography angiography* * Study developed at Universidade Federal da Paraíba (UFPB), João Pessoa, PB, Brazil. *Radiologia Brasileira*. 2015, v. 48, n. 6 [Acessado 24 Agosto 2022] , pp. 358-362. Disponível em: <<https://doi.org/10.1590/0100-3984.2014.0100>>

SANTOS, Priscele Viana dos et al. ANATOMICAL VARIATIONS OF THE CELIAC TRUNK: A SYSTEMATIC REVIEW. *ABCD. Arquivos Brasileiros de Cirurgia Digestiva (São Paulo)*. 2018, v. 31, n. 04 [Acessado 24 Agosto 2022] , e1403. Disponível em: <<https://doi.org/10.1590/0102-672020180001e1403>>

Gardner Ernest. *Anatomia: Estudo Regional do Corpo Humano*. 4th ed. Rio de Janeiro: Guanabara Koogan; 1998.

Petrella Selma, Rodriguez Celio Fernando de Sousa, Sgrott Emerson Alexandre, Fernandes Geraldo José Medeiros, Marques Sergio Ricardo, Prates José Carlos. Anatomy and Variations of the Celiac Trunk. *Int. J. Morphol.* 2007 June [cited 2021 Mar 28] ; 25(2):249-257. Available from: https://scielo.conicyt.cl/scielo.php?script=ci_arttext&pid=S0717-95022007000200002&lng=en. <http://dx.doi.org/10.4067/S0717-95022007000200002>.

BERTEVELLO, Pedro Luiz e CHAIB, Eleazar. Variações do sistema arterial hepático e sua aplicabilidade na bipartição do fígado: estudo anatômico em cadáveres. *Arquivos de Gastroenterologia*. 2002, v. 39, n. 2 [Acessado 24 Agosto 2022] , pp. 81-85. Disponível em: <<https://doi.org/10.1590/S0004-28032002000200003>>

Andraus, Wellington et al. Reconstrução arterial no transplante hepático: a melhor reconstrução para variação da artéria hepática direita. *ABCD. Arquivos Brasileiros de Cirurgia Digestiva (São Paulo)*. 2013, v. 26, n. 1 [Acessado 24 Agosto 2022] , pp. 62-65. Disponível em: <<https://doi.org/10.1590/S0102-67202013000100014>>

BALZAN, Silvio Marcio Pegoraro et al. PREVALENCE OF HEPATIC ARTERIAL VARIATIONS WITH IMPLICATIONS IN PANCREATODUODENECTOMY. *ABCD. Arquivos Brasileiros de Cirurgia Digestiva (São Paulo)*. 2019, v. 32, n. 03 [Acessado 24 Agosto 2022], e1455. Disponível em: <<https://doi.org/10.1590/0102-672020190001e1455>>

Sebben, Geraldo Alberto et al. Variações da artéria hepática: estudo anatômico em cadáveres. *Revista do Colégio Brasileiro de Cirurgiões*. 2013, v. 40, n. 3 [Acessado 24 Agosto 2022] , pp. 221-226. Disponível em: <<https://doi.org/10.1590/S0100-69912013000300010>>

Soares, Renato Vianna et al. Anatomia da artéria hepática em doadores e receptores de transplante hepático intervivos. *Revista do Colégio Brasileiro de Cirurgiões*. 2006, v. 33, n. 2 [Acessado 24 Agosto 2022] , pp. 63-67. Disponível em:

<<https://doi.org/10.1590/S0100-69912006000200002>>

Song SY, Chung JW, Yin YH, Jae HJ, Kim HC, Jeon UB, Cho BH, So YH, Park JH. Celiac axis and common hepatic artery variations in 5002 patients: systematic analysis with spiral CT and DSA. *Radiology*. 2010 Apr;255(1):278-88. doi: 10.1148/radiol.09090389.

Sureka B, Mittal MK, Mittal A, Sinha M, Bhambri NK, Thukral BB. Variations of celiacaxis, common hepatic artery and its branches in 600 patients. *Indian J Radiol Imaging*. 2013 Jul;23(3):223-33. doi: 10.4103/0971-3026.120273.

FONSECA-NETO, Olival Cirilo Lucena da et al. ANATOMIC VARIATIONS OF HEPATIC ARTERY: A STUDY IN 479 LIVER TRANSPLANTATIONS. *ABCD. Arquivos Brasileiros de Cirurgia Digestiva (São Paulo)*. 2017, v. 30, n. 1 [Acessado 24 Agosto 2022] ,pp. 35-37. Disponível em: <<https://doi.org/10.1590/0102-6720201700010010>>

MICHELS, Nicholas A. Newer anatomy of the liver and its variant blood supply and collateral circulation. *The American Journal of Surgery*, [S. l.], v. 112, n. 3, p. 337-347, 1set. 1966.

SILVA, L. V. ; SOUZA, V. J. V. ; HONORATO, A. A. ; RIBEIRO, C. V. ; BALBI FILHO, W. ; SILVA, M. L. F. L. E. ; BARREIROS, L. L. ; SILVA, G. T. G. ; FERNANDES, E. T. ; ANDRADE, F. M. . VARIAÇÕES ANATÔMICAS DA IRRIGAÇÃO EXTRA-HEPÁTICA: abordagem para a educação continuada. *Revista Científica FAGOC Saúde* , v. 3, p. 80-86, 2018.

Marco-Clement I, Martinez-Barco A, Ahumada N, Simon C, Valderrama JM, Sanudo J, Arrazola J. Anatomical variations of the celiac trunk: cadaveric and radiological study. *Surg Radiol Anat*. 2016 May; 38(4):501-10. doi: 10.1007/s00276-015-1542-4.

Wang BG, Fröber R. Accessory extrahepatic arteries: Blood supply of a human liver by three arteries A case report with brief literature review. *Ann Anat*. 2009 Nov;191(5):477-84.doi: 10.1016/j.aanat.2009.06.006. Epub 2009 Jul 18. PMID: 19679454.