

## Treatment of atrophic jaw fracture: systematic review

### Tratamento de fratura em mandíbula atrófica: revisão sistemática

DOI:10.34117/bjdv9n5-102

Recebimento dos originais: 10/04/2023

Aceitação para publicação: 12/05/2023

#### **Victor Rodrigues Franco de Godoi**

Specialization in Residency in Oral and Maxillofacial Surgery and Traumatology

Institution: HFC Saúde

Address: Avenida Barão de Valença, 716, Piracicaba – SP, CEP: 13405-233

E-mail: godoi.victor@gmail.com

#### **Lucas Cavalieri Pereira**

Specialization in Residency in Oral and Maxillofacial Surgery and Traumatology

Institution: HFC Saúde

Address: Avenida Barão de Valença, 716, Piracicaba – SP, CEP: 13405-233

E-mail: dr.lucasmaxilofacial@hotmail.com

#### **ABSTRACT**

Atrophic jaw fractures are common in the elderly population. Edentulous jaws have greater structural fragility due to bone resorption caused after tooth loss. The major cause of these fractures is falling from one's own height, since these patients have a greater cognitive deficit, physiologically inherent to senility. The treatment of these fractures becomes a challenge for the Oral and Maxillofacial surgeon, because the absence of teeth and the lack of anatomical landmarks, disfavor the reduction of the fracture. Other aggravating comorbidities may interfere with bone repair or choice of treatment. Therefore, the surgeon must take into account the age, systemic condition and the degree of mandibular atrophy for the correct conduction. This work aims to carry out a systematic review in which the treatment methods and epidemiological data on the subject were surveyed, including case reports and case series, which contemplate the degree of mandibular atrophy, specify the treatment method and follow-up minimum of 3 months. Through these data, a qualitative analysis of the studies was carried out, highlighting the forms of treatment for this condition.

**Keywords:** mandibular fractures, edentulous arch, oral and maxillofacial surgery, atrophic mandible.

#### **RESUMO**

Fraturas de mandíbulas atróficas são comuns na população idosa. Mandíbulas edêntulas possuem maior fragilidade estrutural devido a reabsorção óssea ocasionada após as perdas dentárias. A maior causa dessas fraturas é a queda da própria altura, uma vez que esses pacientes possuem maior déficit cognitivo, fisiologicamente inerente da senilidade. O tratamento dessas fraturas, torna-se um desafio para o cirurgião Buco-Maxilo-facial, pois a ausência de dentes e a carência de marcos anatômicos, desfavorecem a redução da fratura. Outras comorbidades agravantes podem interferir no reparo ósseo ou escolha do tratamento. Sendo assim, o cirurgião deve levar em consideração a idade, condição sistêmica e o grau de atrofia mandibular para a correta condução. Este trabalho, tem por

objetivo, a realizar uma revisão sistemática na qual realizou-se o levantamento dos métodos de tratamento e dados epidemiológicos a respeito do tema, incluindo relatos de casos e séries de casos, que contemplem o grau da atrofia mandibular, especifiquem o método de tratamento e follow-up mínimo de 3 meses. Através desses dados, foi realizado uma análise qualitativa dos estudos, destacando as formas de tratamento para esta condição.

**Palavras-chave:** fraturas mandibulares, arcada edêntula, cirurgia oral, maxilofacial, mandíbula atrófica.

## 1 INTRODUCTION

The mandible is one of the strongest bones in the face, yet this bone is frequently fractured. When compared to fractures in other parts of the body, these are no different in general principles of treatment. However, in the mandible, dental occlusion determines and guides fracture reduction. (MANGANELLO & LUZ, 2018).

The causes of mandibular fractures have changed over the years, the main ones being motor vehicle accidents, violence, falls, sports-related fractures and others (FONSECA & WALKER, 2015). Falling from one's own height is usually due to mobility difficulties inherent to age. Reductions for these fractures should be as accurate as possible due to their aesthetic-functional implications. Gaps between bone fragments are unacceptable in the mandible (ELLIS&PRICE, 2008).

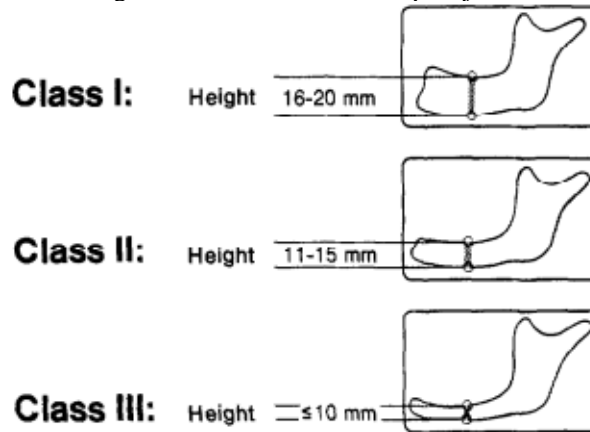
In diagnosing mandibular fractures, the type and direction of trauma can be extremely helpful. Fractures caused by motor vehicle accidents are different from those caused by interpersonal violence. Since the modulus of force can be much greater, victims of car and motorcycle accidents tend to have multiple, compound and comminuted mandibular fractures, whereas patients who are victims of physical aggression may have a single fracture, without displacement. The direction of force can help the clinician diagnose concomitant fractures: an anterior blow directly to the chin can result in bilateral condylar fractures, and an angled blow to the parasymphysis can cause a contralateral condyle fracture or an angle fracture. .

A fractured mandible can have compromised movements, change in facial arch and facial contour, lacerations, bruises, ecchymosis and tooth loss. To complete the diagnosis, imaging tests are necessary, as well as panoramic radiography, oblique lateral radiography, anteroposterior radiography, Towne, among other complementary radiographic measurements, and computed tomography, which is the gold standard for diagnosis (FONSECA & WALKER, 2015 ).

The treatment of these fractures follows basic principles for both dentate and edentulous mandibles, which refers to the reduction and fixation of these fractures. It can be considered that the mandible is formed by two components: the mandible itself and the alveolar mandible, the alveolar process exists only in the presence of teeth, with tooth loss this component disappears in the edentulous mandible. When it comes to elderly patients, we find a bone that is more debilitated and more predisposed to fractures, in the case of the edentulous mandible, this structural weakness is aggravated by the mandibular atrophy resulting from alveolar resorption after tooth loss. In the elderly, the mandibular body region can be reduced to half its height. Open reduction requires detachment of the periosteal surface, which subsequently inhibits osteogenesis. Closed reduction using a denture held in place by circummandibular cerclage offers a more conservative approach that is likely to improve the clinical condition. If open reduction is required, supplemental bone grafting at the fracture site should be considered in addition to minimal periosteal detachment. In edentulous and severely atrophic ridges, open reduction with primary bone grafting may be indicated, because proper alignment of fractured bone ends may be impossible because of the small cross-sectional diameter of the mandibular body. a supplemental bone graft at the fracture site should be considered in addition to minimal periosteal detachment. In edentulous and severely atrophic ridges, open reduction with primary bone grafting may be indicated, because proper alignment of fractured bone ends may be impossible because of the small cross-sectional diameter of the mandibular body. a supplemental bone graft at the fracture site should be considered in addition to minimal periosteal detachment. In edentulous and severely atrophic ridges, open reduction with primary bone grafting may be indicated, because proper alignment of fractured bone ends may be impossible because of the small cross-sectional diameter of the mandibular body.

Thinking about the best method for treating these fractures and with the aim of facilitating the surgical approach based on mandibular atrophy, Luhr, Reidick, Merten (1996) classified mandibular atrophy according to the height of the remnant. Being considered Class I (jaws with atrophy between 16 and 20 mm), Class II (from 11 to 15 mm) and Class III (less than or equal to 10 mm) (Figure 1). That said, Novelli et al. (2012) proposed the fixation of CL I and II mandibles with 2.0 mm devices, as for CL III atrophies, with devices of the 2.4 mm system.

Figure 1: Classification of atrophic jaws



Source: Jesus (2018)

## 2 METHODOLOGY

This study is a systematic review of the literature, carried out through a descriptive study with a qualitative approach. This study followed the six steps proposed by Mendes, Silveira and Galvão (2008): a) Formulation of a hypothesis or research question and definition of a problem to prepare the review; b) Selection of criteria for inclusion and exclusion of studies or scientific samples; c) Definition of the information to be extracted from the selected studies, during the collection of information; d) Critical analysis of the studies resulting from the research; e) Comparison and interpretation of samples, for discussion of results; and f) Presentation of the review in a detailed and easy-to-understand manner.

The search in this research was formulated from the PICo strategy, an acronym used to select a Population: “patients”; an Intervention: “atrophied jaws”; Comparison: “edentulous arch”, as required by the PRISMA protocol (Preferred Reporting Items for Systematic Reviews).

For this purpose, a survey of data was carried out in electronic databases: Virtual Health Library (VHL); Scientific Electronic Library Online – Electronic Scientific Online Library (SCIELO); Nursing Database (BDENF); Spanish Bibliographical Index in Health Sciences (IBECS); Cumulative Index to Nursing And Allied Health Literature (CINAHL); Cochrane and Latin American and Caribbean Literature on Health Sciences (LILACS). The following descriptors were used to search for articles: “mandibular fractures”, “edentulous arch”, “oral surgery”, “maxillofacial”, “atrophic mandible”, taken from descriptors in health sciences (DeCs).

Articles from 1975 to 2022 were reviewed in order to observe, in addition to current fixation devices, the evolution of treatment methods. Articles available in full text,

available in full for free and online, in Portuguese and English. Health guides, reviews, articles available only in abstracts, duplicate materials, theses, monographs, dissertations and articles not related to the researched theme or not contemplating the specific objective of this review were excluded.

The selection of articles took place in three steps: 1) reading the title, 2) reading the abstracts and 3) reading the full text. After reading and evaluating based on the eligibility criteria, articles that did not meet the research objectives were excluded.

Inclusion criteria for clinical case reports or case series were: minimum follow-up period of 3 months after surgical intervention, presentation of the degree of mandibular atrophy to fit the Classification of mandibular atrophy proposed by Luhr, Reidick and Merten in 1996. Specification of the fixation systems used was also an inclusion criterion.

When reported, data such as the success rate of osteosynthesis or other proposed treatment, fixation system used for the fractured mandible, etiology and epidemiological data were captured.

The following exclusion criteria for the systematic review were defined: literature reviews, monographs, articles that do not have a minimum follow-up of 3 months, articles that do not specify the fixation system used, articles that do not involve an atrophic mandible, articles with a focus on in condylar fractures of atrophic mandible, articles that present isolated fractures of the genial tubercle and articles that do not present the degree of atrophy of the mandible. Only studies involving humans were included.

The failure/success rate of the proposed treatments, failures of the fixation system, biological complications, age and gender of the patients when they suffered the fracture and the etiology of the fracture were measured. For each included study, the following data were collected using a specially designed data abstraction form: authors' names, year of publication, title, study design, number and demographic profile, data of patients treated, degree of atrophy of the fractured mandible (Luhr classification), fixation system used (type of osteosynthesis material), follow-up period and details of the results (success rate of the proposed treatment and reported complications). The methodological quality of observational studies was assessed using the Newcastle-Ottawa scale.

In the data extraction process of the included articles, we sought to identify methodological similarities between the articles regarding clinical analysis instruments that would make possible a meta-analysis of the data to quantitatively infer the effects of different types of treatment for atrophic mandible fracture. However, some factors made it impossible for the data to be grouped in order to carry out data statistics, which were

the following: some case report articles, despite having used similar methodological instruments for evaluation, such as radiographs and CT scans, reported the effects of treatment only descriptively (VERZOLA et al., 2015; NETO et al., 2022; CARVALHO et al., 2020; PEREIRA et al., 2017; ZIDE, DUCIC, 2003; GAUR et al., 2022); case series articles, despite reporting some quantitative measures, did not report standardization in the intervention and evaluation process, in addition to being heterogeneous among themselves (CLAYMAN, ROSSI, 2012; HACHLEITNER et al., 2013; NOVELLI et al., 2012; KORPI et al., 2012).

### 3 SYSTEMATIC REVIEW

After the applicability of the mentioned methodology, some articles were selected to compose the study, and that met the research criteria, as shown in Table 1.

Table 1 -Distribution of selected articles

Author/Date	Title	Goal	Methodology	Results
Carvalho, E. F; et al. 2020.	Computer-aided surgical simulation in severe atrophic mandibular fractures: A new method for guided reduction and temporary stabilization prior to fixation	To report a new, low-cost technique, in which VSP and computer-assisted fabrication of a positioning guide were applied to a 72-year-old female patient with bilateral fractures in her Luhr CL III atrophic mandible.	Case report.	The surgical procedure was performed without complications resulting in the precise fit of the pre-bent 2.4 mm system reconstruction plate and guide. Postoperative CT scan showed good condylar position, fracture reduction and hardware adaptation. The follow-up of approximately 2 years showed that the patient was successfully rehabilitated with the dental prosthesis. Therefore, virtual planning is a valuable tool to obtain a predictable result in the treatment of atrophic mandible fracture, with reduced operative time, acceptable accuracy in fracture reduction and low cost.

<p>Neto, JLO; et al. 2022.</p>	<p>Treatment of atrophic mandible fracture approached by transcervical approach: case report</p>	<p>To describe a clinical case of Luhr CL II atrophic mandible fracture in a 73-year-old male patient after an accident with an animal.</p>	<p>Case report</p>	<p>Good results were seen in the treatment of atrophic mandible fractures, with the 2.4 mm titanium reconstruction system associated with individualization of the fracture with 2.0 mm system miniplates and Lag Screw screws. It is concluded that the fractures of atrophic mandibles presented a complex treatment, which presents good execution, if well planned, executing the correct techniques, being fundamental that the Oral and Maxillofacial surgeon is qualified for this type of approach. The patient was followed up for 3 months, with no complications observed.</p>
<p>Verzola, MHA; et al. 2015.</p>	<p>Treatment of atrophic mandibular fracture related to implant placement in an oral bisphosphonate user: a case report</p>	<p>Atrophic mandibular fractures associated with the placement of dental implants are an uncommon condition and, to the best of our knowledge, this event in an oral bisphosphonate user has never been described before.</p>	<p>Case report</p>	<p>Fracture fixation using a 2.0 mm reconstruction system plate proved to be effective in the treatment of atrophic mandible fractures in users of oral bisphosphonates, without the occurrence of complications such as osteonecrosis. In addition, oral rehabilitation with a prosthesis under the remaining implants showed satisfactory results.</p>
<p>Gaur, V.; Doshi, A.G; Bengani, AKS 2022.</p>	<p>Management of Mandibular Nonunion Fracture with SinglePiece Implant - A Case Report</p>	<p>To present the treatment of an uninfected edentulous mandible fracture accompanied by a Luhr class I fracture.</p>	<p>Case report.</p>	<p>The fracture was treated by means of basal cortical implants and installation of a prosthesis on the implants, maintaining the stability of the fracture. After two years, the panoramic radiograph showed complete unification of the fracture line and adaptation of the callus. The authors propose a new treatment option for the correction of nonunion mandibular fractures.</p>



<p>Clayman, L.; Rossi, E. 2012.</p>	<p>Fixation of Atrophic Edentulous Mandible Fractures by Bone Plating at the Lower Border</p>	<p>To report the results of this treatment with the placement of plates on the lower border of the mandible of 16 patients with fractures of the mandibular body (Luhr CL III).</p>	<p>Case report.</p>	<p>All patients achieved clinical healing of their fractures. Two cases of fibrous union did not achieve ossification up to 5 months after surgery. The hardware removal rate was 13.6% and the prolonged infection/inflammation rate was 13.6%. There was 1 case of malunion. Those patients who used prostheses were able to return to using the prosthesis postoperatively.</p>
<p>Hachleitner, J.; et al. 2013.</p>	<p>The role of the titanium functionally dynamic bridging plate for the treatment of the atrophic mandible fractures</p>	<p>Understand the role of the functionally dynamic titanium bridge plate and how it can act in the treatment of atrophic fractures of the mandible in patients.</p>	<p>Case report.</p>	<p>All patients who wore dentures before suffering the fracture were able to wear their dentures again 3 weeks after surgery. There were no serious complications. A high proportion of bone healing with a low rate of complications has been observed with the use of a titanium functionally dynamic bridging plate (TFDBP) in the treatment of severely atrophic mandibular fractures. TFDBP is an excellent alternative to conventional lining of the severely atrophic mandible.</p>



<p>Korpi, JT; et al. 2012.</p>	<p>Tent-Pole Approach to Treat Severely Atrophic Fractured Mandibles Using Immediate or Delayed Protocols: Preliminary Case Series</p>	<p>To investigate the outcomes of patients with severely resorbed fractured mandibles who were treated with a modified brace procedure.</p>	<p>Case report.</p>	<p>The postoperative course and healing of the 4 patients were uneventful, with no unconsolidated fracture. The mean standard deviation of alveolar enlargement was 7.5x1.17 mm (range 6.6 to 9.0 mm). There was no bone resorption around any of the endosseous implants at follow-up. All 4 patients wore their implant-supported dentures comfortably.</p>
<p>Pereira, RS; et al. 2017.</p>	<p>Surgical treatment of atrophic mandible fracture using the AO technique: case report</p>	<p>To demonstrate a clinical case of mistreated atrophic mandible fracture and correction using a 2.4 mm system reconstruction plate and autogenous bone graft from the anterior iliac crest.</p>	<p>Case report.</p>	<p>After 1 and 7 months, it was concluded that, despite having used a more "aggressive" technique, it provided more satisfactory and predictable results.</p>

Novelli, G.; et al. 2012.	Surgical Treatment of the Atrophic Mandibular Fractures by Locked Plates Systems: Our Experience and a Literature Review	To evaluate the results of the treatment of atrophic mandibular fractures and compare the results of different plate systems used for stabilization.	Case report.	The large 2.0 mm locking plate is thinner, exposes soft tissue less often and is much easier to shape and adapt to the mandibular anatomy. However, the 2.4mm locking plate system still represents the hardware of reference in the condition of severe bone atrophy.
Zide, MF; Yadranko, D. 2003.	Fibula microvascular free tissue reconstruction of the severely comminuted atrophic mandible fracture— case report	To describe the favorable experience with the use of a microvascular free tissue transfer from the fibula for the treatment of a severe injury.	Case report.	Microvascular free tissue transfer from the fibula provides a large amount of vascularized bone to allow for rigid fixation, progression to implant union and rehabilitation in the severely atrophic comminuted fracture. It seems to represent a treatment alternative in selected individuals.
Oliveira, HC; et al. 2015.	Treatment of Atrophic Mandibular Fractures with the Pencilboneplate: Report of 2 Cases	Report 2 cases of fractured atrophic mandibles treated with pencilboneplate, 2.0 mm titanium, 8 or 10 holes with reinforcement in its middle portion, highlighting important considerations about its use.	Case report.	The pencilboneplate appears to be a valuable option for the treatment of atrophic mandibular fractures, especially by an intraoral approach, and warrants further biomechanical studies and clinical.

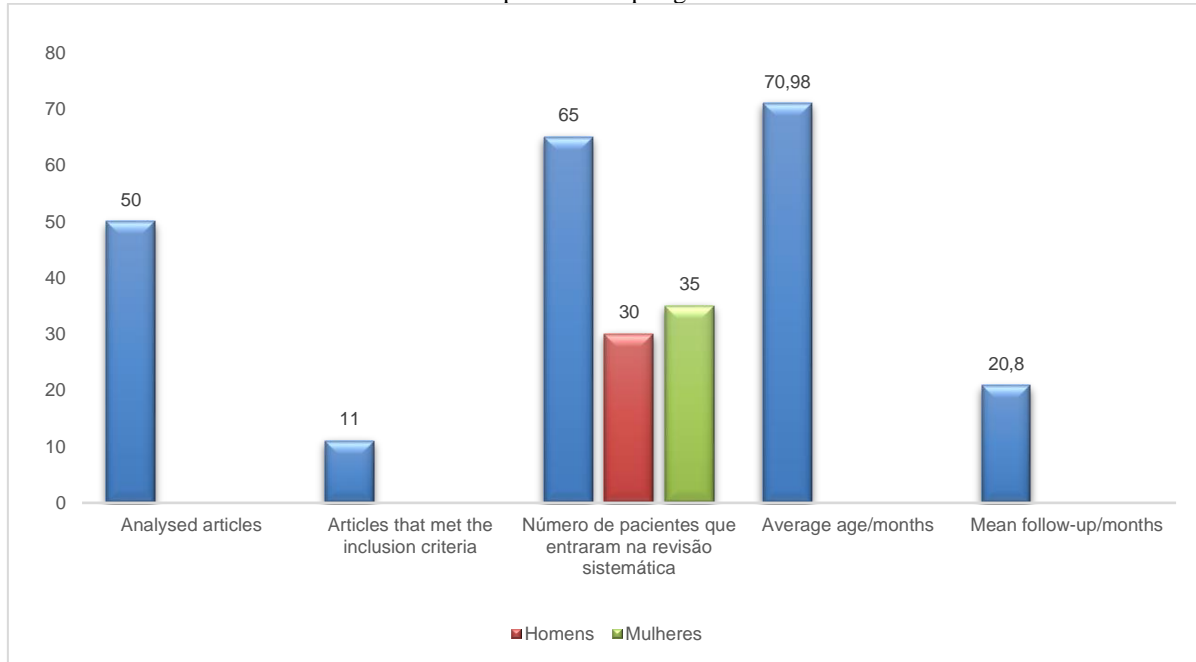
Source: Research Data (2022)

#### 4 RESULTS

A total of 50 articles were analyzed, 11 of which met the inclusion criteria, totaling 65 patients with atrophic mandible fractures, 35 women (53.84%) and 30 men (46.15%). The average follow-up of the 65 patients was 20.8 months and the average age was 70.98 years (Graph 1). 5 studies showed the etiology of the reported fractures and associated them with gender, having a total of 20 patients with identified etiology: 4 interpersonal

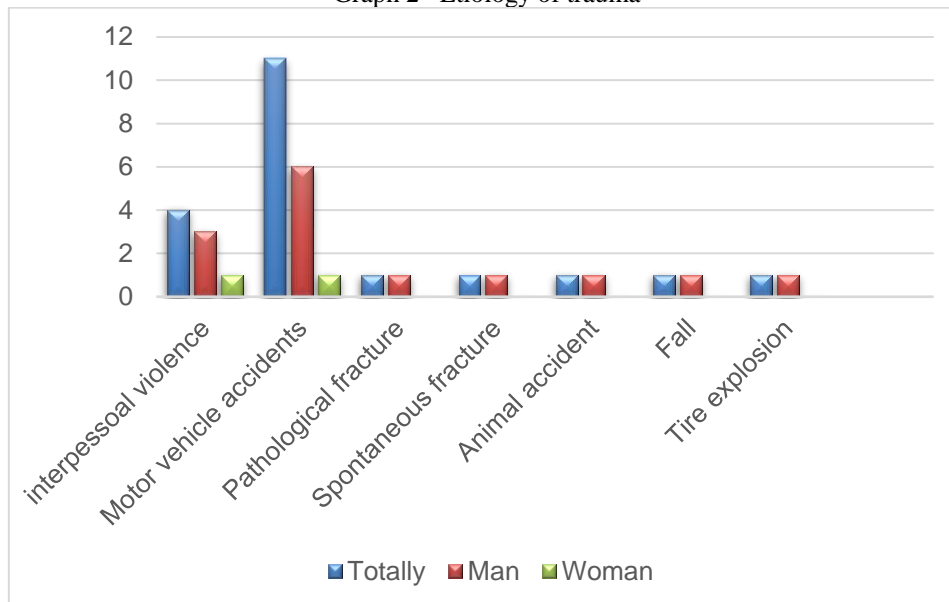
violence (3 men and 1 woman), 11 car accidents (5 women and 6 men), 1 pathological fracture (1 man), 1 spontaneous fracture during chewing (1 man), 1 animal accident (1 man), 1 fall (1 man) and 1 tire explosion (1 man) (Graph 2).

Graphic 1- Sampling



Source: Research Data (2022)

Graph 2- Etiology of trauma

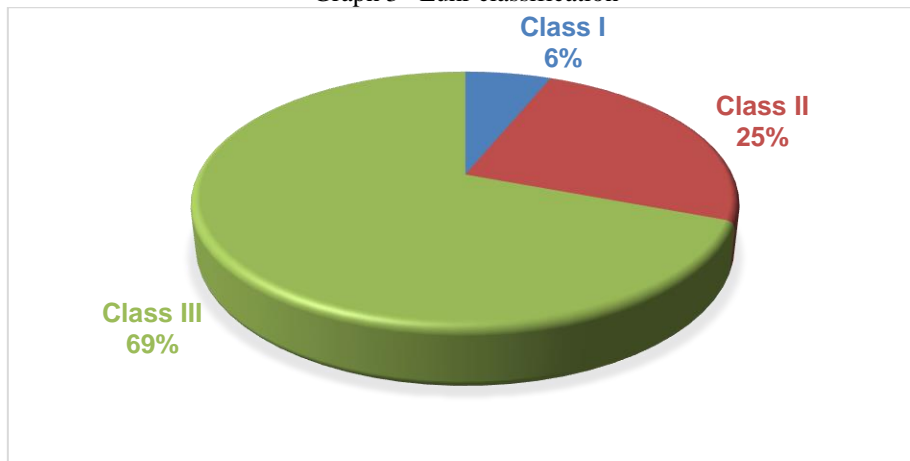


Source: Research Data (2022)

Taking into account the Classification proposed by Luhr, 4 patients (6.15%) were CL I, 16 (24.61%) were CL II and 45 (68.23%) were CL III (Graph 3). Treatment methods

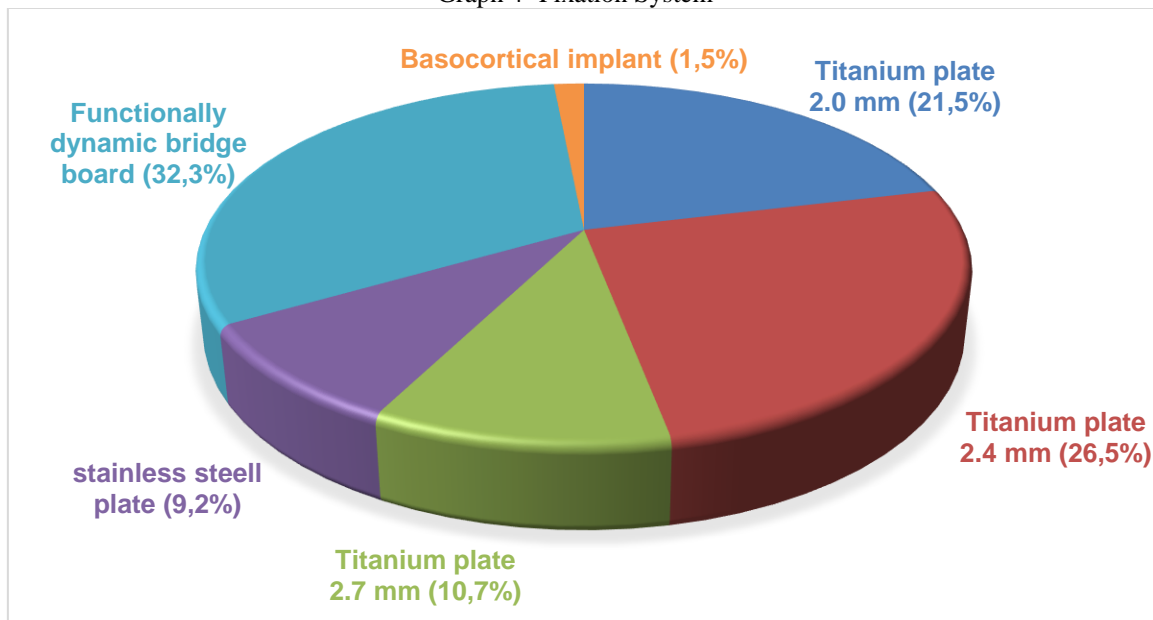
were also accounted for by associating them with the number of patients treated (65). There were 14 plates of the 2.0 mm system (21.53%), 17 plates of the 2.4 mm system (26.56%), 7 plates of the 2.7 mm system (10.76%), 6 stainless steel plates (9.23%), 21 functionally dynamic bridge plates (32.30%) and 1 patient was treated using a prosthesis on basocortical implants (1.53%) (Graph 4)

Graph 3- Luhr classification



Source: Research Data (2022)

Graph 4- Fixation System

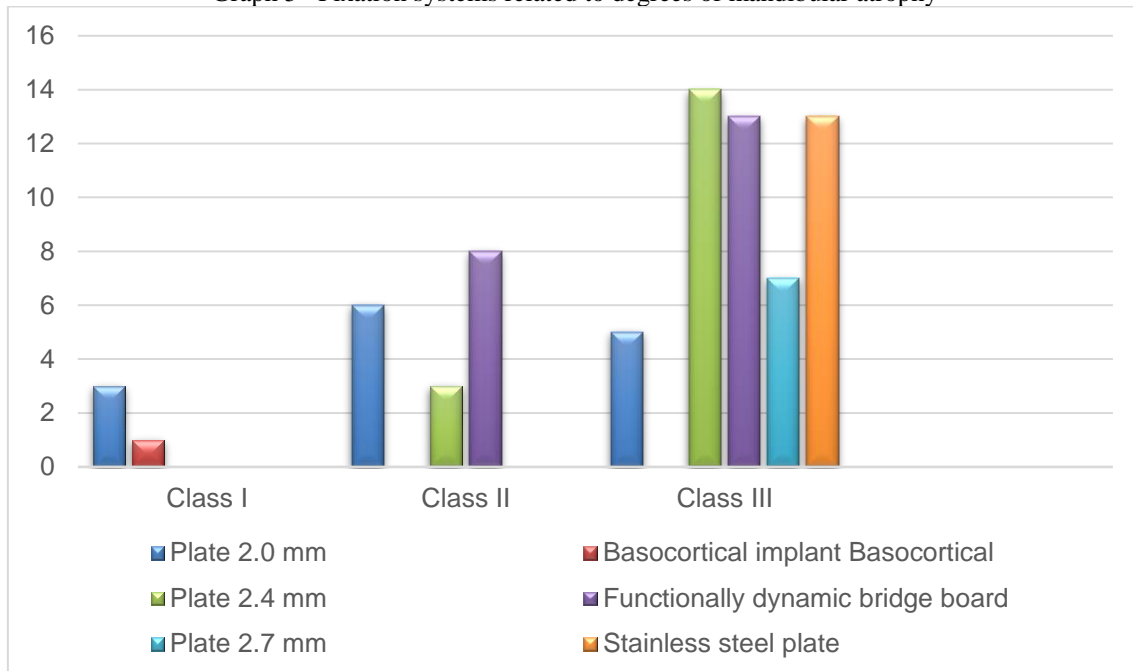


Source: Research Data (2022)

Relating the fixation systems to the degrees of mandibular atrophy, of Luhr's CL I patients, 3 (75%) were treated with plates of the 2.0 mm Lock system and 1 (25%) had its fracture treated using a prosthesis on basocortical implants. Of Luhr CL II patients, 3 (18.75%) were treated with 2.4 mm system plates, 6 (37.5%) were treated with 2.0 mm

system plates, of which 5 were Lock system and 1 was 1 miniplate so-called reinforced (pencilnplate) and 8 (50%) of these were treated with functionally dynamic bridge plate. As for Luhr CL III patients, 14 (31.11%) were treated with plates of the 2.4 mm system, 5 (11.11%) were treated with plates of the 2.0 mm system, and of these, 4 were 2.0 Lock and 1 was a reinforced miniplate (pencilnplate), 6 (13.33%) were treated with stainless steel plates, 13 (28,

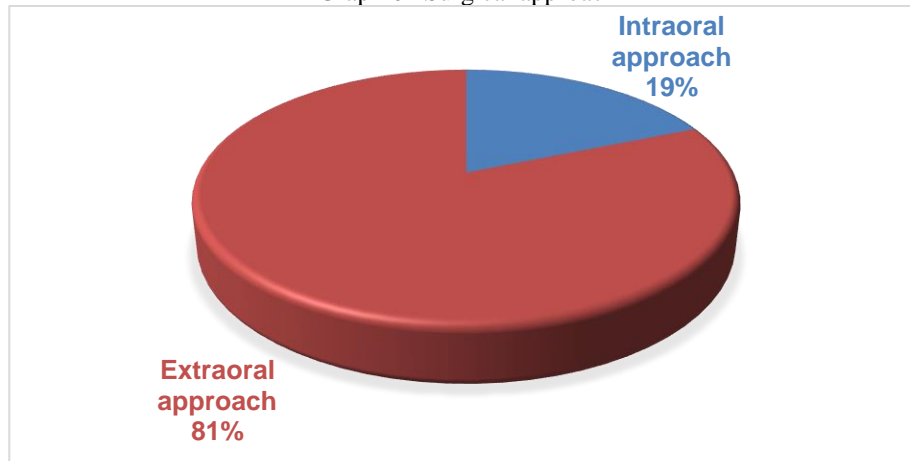
Graph 5– Fixation systems related to degrees of mandibular atrophy



Source: Research Data (2022)

As a form of surgical approach, there were a total of 64, 52 of which were extraoral accesses (81.25%), 12 intraoral accesses (18.75%) and one case treated with prosthesis on implant, without flap (Graph 6). Three studies reported the use of grafts in mandibular reconstructions, totaling 6 patients, 5 of which used microparticulate grafts from the iliac crest (4 posterior iliac crest and 1 anterior iliac crest) and 1 microvascular graft from the fibula). All well conducted, with no reported complications.

Graph 6– Surgical approach



Source: Research Data (2022)

In all, 47 complications were reported (Chart 6).

Table 6 -Complications

3 Exhibitions of osteosynthesis material	1 transcutaneous exposure 2 Intraoral dehiscence
4 Removal of osteosynthesis material	1 2.7 mm fixed by extraoral access; 2 stainless steel plates fixed by extraoral access; 1 functionally dynamic bridge plate (surgical access not specified).
4 infections	3 associated with extraoral access; 1 Access not specified.
26 Sensory Disorders	11 paresthesias (8 temporary and 2 permanent. 15 hypoesthesias
4 Inability to use the prosthesis	2 associated with the 2.7 mm system and 2 associated with a stainless steel plate.
3 Persistent hardening	1 associated with the 2.7 mm system 1 associated with stainless steel system 1 associated with the 2.4 mm system. All were fixed by extraoral access.

Although the functionally dynamic bridge plate was the most prevalent in this study, the number of patients represented in the study in question must be taken into account. On the other hand, this device was used by only one author, while the 2.4 mm system plate was used in 7 papers presented, showing the highest prevalence among the authors.

In all cases, the fractures were reduced without maxillomandibular locking, anatomical reduction was chosen for all cases, except for Carvalho et al 2020, who made the mandibular reduction guide through virtual planning.

## 5 DISCUSSION

Novelli et al. (2012) mention that for an adequate choice of treatment plan, some variables must be taken into account, such as the fracture reduction technique (open or closed), the surgical approach (intraoral or extraoral), tissue dissection technique (subperiosteal or supraperiosteal) and the choice of fixation device. To determine whether a treatment will be conservative or surgical, consideration is given to the health of the patient and the reduction in blood supply due to mandibular atrophy.

According to Friedenbergl and French (1952) and Bradley (1975), the main source of vascularization in mandibles, especially atrophic ones, comes from adhered surrounding soft tissues, which would discourage the open treatment of fractures in these cases. Predominating this idea, in 1970 the closed treatment was the gold standard. However, open treatment with internal fixation can be considered the gold standard for this type of fracture, which was corroborated by Ellis and Price (2008), who showed the effectiveness of open treatment, with good surgical results, mainly referring to healing of fractures. Which is consistent with the results of this systematic review.

As for the type of surgical approach, this review showed a prevalence of the extraoral approach. However, the individuality of each case must be taken into account for the treatment of mandibular fractures. Luhr, Reidick, Merten (1996) advocate the intraoral approach for fractures in an atrophic mandible, while Bruce and Ellis (1993) advocate the extraoral approach.

This systematic review showed a prevalence of infections in patients in whom extraoral accesses were performed, but one should take into account the limited number of studies that met the inclusion criteria of the review and the disparity between intraoral and extraoral access.

With the use of an extraoral approach, despite the scar and the risk of injury to the facial nerve, it is easier to manipulate, reduce and apply the fixation devices in atrophic mandibles, which favors the final result of the surgical treatment. Furthermore, the extraoral approach may provide less periosteal wear. Corroborating with Ellis and Price (2008), this systematic review showed a greater use of extraoral accesses for the treatment of this type of fracture.

According to Clayman and Rossi (2012), the level of risk of injury to the inferior alveolar nerve is acceptable and the external scar rarely presents cosmetic difficulty for these patients. The most common complication has been the need to remove a screw or plate due to loosening. Sensory disorders were the most prevalent complications in this



study, however, this type of situation is common in facial trauma, making it difficult to relate which disorders were due to trauma and which were due to surgery.

Neto et al. (2022) describes the transcervical access as the gold standard in the management of these fractures. Extraoral accesses allow better visualization and manipulation of the fracture, compared to intraoral accesses, by facilitating the application of the internal fixation system and reducing the rate of infection.

Bradley (1975) and Luhr, Reidick and Merten (1997) consider a suprapariosteal dissection, based on preserving the blood supply. However, this idea can be refuted, since the periosteal blood supply comes from the soft tissues that connect to the periosteum. That said, it is believed that suprapariosteal dissection leads to disconnection of the soft tissues attached to the periosteum, which contradicts the idea of “maintaining the blood supply”. Rucker et al. (2005) describe that instrumentation of the fracture can be hampered by the suprapariosteal approach, since it is necessary to visualize the ends of the fracture, which would be impeded by the periosteum. Furthermore, fixation devices could interrupt the blood supply provided to the periosteum. In this case, locking fixation devices could be considered so that there is no compression of the periosteum, however, even so, it would be difficult to apply these devices without viewing the ends of the fracture, in addition to the difficulty in adapting bone grafts. All works in this systematic review performed subperiosteal dissections, showing a high success rate in the methodology.

Novelli et al. (2012) consider the use of plates from the 2.0 mm Lock system for fractures in atrophic mandibles CL I and II, showing efficacy in the indication. Oliveira (2012) considered the use of reinforced miniplates from the 2.0 system in a CL III atrophic mandible fracture, also showing efficacy in the indication, and in bilateral fractures, the reinforced miniplate was associated with the reconstruction plate of the 2.4 mm system.

Considering the lower forces generated in an atrophic mandible, it was suggested that less rigid systems could be used to treat this type of fracture. However, it is believed that in atrophic mandibles, if treated by miniplates, the bone is subjected to forces from several directions, which can lead to fatigue and consequent fracture of the conventional miniplate (SIKES, SMITH, MUKHERJEE, 2000), as reported by Philip & David 2003.

The lack of knowledge and experience with biomechanics is a factor that increases the complications of fractures in atrophic mandibles, and malunion and infection of bone stumps may occur, for example. Therefore, for the proper management of this type of

condition, anatomical knowledge of the craniofacial skeleton and fixation systems is necessary, in order to minimize postoperative complications and establish the best treatment and prognosis for the patient (NETO et al. 2022) .

In the dentate, healthy mandible, the muscular forces are counterbalanced, generating neutrality. In the absence of teeth there is no possibility of sharing occlusal loads, which are transmitted from the occlusal area to the plates. A second miniplate could favor the consolidation and stability of the fracture, but this would depend on the minimum bone height, which cannot be observed in atrophic mandibles (ELLIS & PRICE, 2008).

According to Chilli et al. (1998) for atrophic mandibles, the load-bearing 2.4 mm Lock system is used for fracture fixation. A material is needed to support all the muscle load imposed on the mandible, taking into account the typical phrase “the smaller the bone, the greater the plate must be”, as it must support all the muscle load exerted on the mandible. Corroborating with Novelli et al. (2012), Lewes and Clayman (2012), Carvalho et al. (2020) and Neto et al. (2022) and with the results of this systematic review.

The development of locked fixation plates was advantageous for the treatment of atrophic mandible fractures, because this type of device eliminates the need for intimate contact with the fractured bone (CIENFUEGOS et al. 2012). Corroborating this idea, most of the works in this review showed effectiveness in Lock-type fixation systems.

According to Ellis and Price (2008) the 2.0mm Lock system reconstruction plate is a good alternative to 2.4mm system plates. Because it is thinner, there is less chance of the plaque becoming palpable or exposed. Corroborating with Verzola et al. (2015), Novelli et al. (2012) also considered the use of plates from the 2.0 mm Lock system, having a precise indication for CLI and II atrophies. In addition, it is easier to bend and adapt than the 2.4mm system plate, which would save surgical time. This systematic review showed a prevalence in the use of 2.4 mm system plates when compared to 2.0 mm system plates, however, in both situations, there were no failures in the fixation materials, showing the effectiveness in the correct indication for the use of each one. .

The introduction of the 2.0 locked plates also represented a milestone in the treatment of this type of fracture, which are more resistant than the plates of the conventional 2.0 system, being thinner and therefore easier to mold when compared to the 2.4 mm system. Its lower profile favors adaptation to the mandibular contour (CIENFUEGOS et al., 2012). However, 2.4 mm locking plates continue to be the main reference for the treatment of fractures in mandibles with severe atrophy (NOVELLI et

al., 2012). Corroborating the result of the review, which showed prevalence in the use of the 2.4 mm plate when compared to the 2.0 mm plate.

Sometimes, the use of bone grafts is necessary. In atrophic mandibles bone grafting techniques can be launched as a result of rehabilitation with dental implants (BELL et al., 2002). Following this reasoning, Korpi et al. (2012) treated 4 cases of atrophic mandibular fracture, associated with the delayed and immediate tentpole technique, with microparticulate bone grafts from the iliac crest. But structural reestablishment may also be necessary as a result of a comminuted fracture and a bone poor in vascularization, as described by Zide, Ducic (2003) who used a microvascular graft from the fibula for mandibular reconstruction. However, according to this review, the use of a graft does not seem to be essential in most cases for the success of the proposed treatment.

## **6 CONCLUSION**

Reconstruction plates, in general, have shown good results and low complication rates, as long as their indication is precise. The 2.4 mm plate continues to be the gold standard in the fixation of severely atrophic mandibles, as it presents an intermediate degree of stiffness between the 2.0 mm and 2.7 mm plates, being sufficient for load bearing, presenting a low rate of prosthetic interference. The preferential access for these fractures is the extraoral access, with subperiosteal dissection, as it sufficiently exposes the mandibular arch and allows correct fixation of the fracture. Due to the degree of rigidity of the reconstruction plates, the biomodels help in the pre-folding of the plates, which minimizes surgical time.

## REFERÊNCIAS

AGOCHUKWU, N. B.; MAUS, J., WANG, D.; *et al.* Use of the MatrixWAVE™ system with dentures to establish maxillomandibular fixation in edentulous patients. **Br J Oral Maxillofac Surg**, v. 56, n. 4, p. 343-345, 2018.

ALBUQUERQUE, L. H.L.; NOGUEIRA, R.V.B.; MIKAMI, J.R.; *et al.* Fratura em mandíbula atrófica: relato de caso. **Ciência, Clínica e Diagnóstico**, v. 1, n. 1, 2018.

ALMEIDA NETO, L. F.; MARCELINO, K. P.; SOUZA, J. A. N. de.; *et al.* Tratamento cirúrgico de fratura de mandíbula atrófica severamente deslocada: relato de caso. **Research, Society and Development**, v. 9, n. 9, 2020.

BELL, R. B.; BLAKEY G. H.; WHITE RP.; *et al.* Staged reconstruction of the severely atrophic mandible with autogenous bone graft and endosteal implants. **J Oral Maxillofac Surg**, v. 60, p. 1135-1141, 2002.

BENECH, A.; NICOLOTTI, M.; BRUCOLI, M.; *et al.* Intraoral extra-mucosal fixation of fractures in the atrophic edentulous mandible. **Int J Oral Maxillofac Surg**, v. 42, n. 4, p. 460-3, 2013.

BRADLEY, J. C. Uma investigação radiológica sobre as mudanças de idade da artéria dentária inferior. **Br J Oral Surg**, v. 13, p. 82, 1975.

BRUCE, R. A.; ELLIS, E. The second Chalmers J. Lyons Academy Study of fractures of the edentulous mandible. **J oral Maxillofac Surg**, v. 51, n. 8, p. 904-11, 1993.

BRASIL, R. P. S. L.; DE OLIVEIRA, A.R.; DAS NEVES, G.F.; DE OLIVEIRA, E.B.; PAULA, E.D.L; TINO, M.T. Desafios no tratamento de fraturas mandibulares atróficas: série de casos. **Brazilian Journal of Surgery and Clinical Research**, v. 34, n. 2, p. 4-18, 2021.

BRUCOLI, M.; BOFFANO, P.; ROMEO, I.; *et al.* Management of mandibular condylar fractures in patients with atrophic edentulous mandibles. **J Stomatol Oral Maxillofac Surg**, v. 121, n. 3, p. 226-232, 2020.

BURNETT, P. J.; NIXON, P. P.; ROGERS, S. N. Spontaneous fracture of the genial tubercles: a case report. **Dent Update**, v. 39, n. 1, p. 63-4, 2012.

CARVALHO, E. F. C.; ALKMIN PAIVA, G.L.; YONEZAKI, F.; *et al.* Computer-aided surgical simulation in severe atrophic mandibular fractures: A new method for guided reduction and temporary stabilization prior to fixation. **American Association of Oral and Maxillofacial Surgeons**, 2020.

CHILLI, W. **Fraturas mandibulares**. In: Prein J. Manual de Fixação Interna no Esqueleto Crânio-Facial: Técnicas Recomendadas pelo Grupo AO/ASIF Maxilofacial. Nova York: Springer; 1998.

CHRCANOVIC, B. R.; CUSTÓDIO, A. L. Mandibular fractures associated with endosteal implants. **Oral Maxillofac Surg**, v. 13, n. 4, p. 231-8, 2009.

CIENFUEGOS, R. CMF mandíbula— compartilhamento de carga versus suporte de carga—diferentes níveis de distribuição de força—referência AO Surgery. **Fundação AO**, 2012.

CLAYMAN, L.; ROSSI, E. Fixation of Atrophic Edentulous Mandible Fractures by Bone Plating at the Inferior Border. **American Association of Oral and Maxillofacial Surgeons**, 2012.

COPE, M. R. Spontaneous fracture of an atrophic edentulous mandible treated without fixation. **British Journal of Oral Surgery**, v. 20, n. 1, p. 22-30, 1982.

COSTA, B. E.; BUENO, C. R. ; MOMESSO, N. R. .; *et al.* Management for the rehabilitation of atrophic mandible fracture: case using a conservative approach and short implants. **Research, Society and Development**, v. 11, n. 4, 2022.

ELLIS, E.; PRICE, C. Treatment protocol for fractures of the atrophic mandible. **J Oral Maxillofac Surg**, v. 66, n. 3, p. 421-35, 2008.

FONSECA, R. J.; WALKER, R. V. **Trauma Bucomaxilofacial**. 4. ed. Rio de Janeiro. Elsevier, 2015.

FRIEDENBERG, Z. B.; FRENCH, G. O efeito das forças de compressão conhecidas na consolidação da fratura. **Surg Gynecol Obstet**, v. 94, p. 743, 1952.

GAUR, V.; DOSHI, A. G.; BENGANI, A. K. S. Management of Mandibular Nonunion Fracture with Single-Piece Implant - A Case Report. **Annals of Maxillofacial Surgery**, 2022.

GERMANO, A. R.; FREIRE FILHO, F.W.V.; CORTEZ, A.L.V; *et al.* Tratamento das fraturas em mandíbulas atroficas – relato de caso. **Rev Int Cir Traumatol Bucomaxilofacial**, v. 3, n 9, p. 5-11, 2005.

HACHLEITNER, J; ENZINGER, S.; BRANDTNER, C.; *et al.* The role of the titanium functionally dynamic bridging plate for the treatment of the atrophic mandible fractures. **Journal of Cranio-Maxillo-Facial Surgery**, 2013.

JAMES, D. R. Atrophy of the mandible: reconstruction following fracture. **Br J Oral Surg**, v. 14, n. 2, p. 156-62, 1976.

JEON, J-H.; LEE, J-G.; YUN, P-Y.; *et al.* Atrophic mandible fracture due to dental implant: case report. **Journal Of Dental Implant Research**, v. 40, n. 3, p. 85-89, 2021.

KORPI, J. T.; KAINULAINEN, V.T.; SÁNDOR, G.K.; *et al.* Tent-Pole Approach to Treat Severely Atrophic Fractured Mandibles Using Immediate or Delayed Protocols: Preliminary Case Series. **American Association of Oral and Maxillofacial Surgeons**, 2012.

KREGER, T. M.; SAMIT, A. M. Management of bilateral fractures three weeks after mandibular skin graft vestibuloplasty. **J Oral Maxillofac Surg**, v. 41, n. 5, p. 329-31, 1983.

LIMA, L. B.; Tratamento cirúrgico de fratura em mandíbula atrofica. **ROBRAC**, v. 23, n. 67, 2014.

LIMA E SILVA, H. C.; OLIVEIRA, M.T.F.; BATISTA, J.D.; *et al.* fratura em mandíbula atrofica: relato de caso. **Archives of Health Investigation**, v. 6, n. 1, 2017.

LOUIS, P.; HOLMES, J.; FERNANDES, R. Resorbable mesh as a containment system in reconstruction of the atrophic mandible fracture. **J Oral Maxillofac Surg**, v. 62, n. 6, p. 719-23, 2004.

LUHR, H. G.; REIDICK, T.; MERTEN, H. A. Results of treatment of fractures of the atrophic edentulous mandible by compression plating: a retrospective evaluation of 84 consecutive cases. **J Oral Maxillofac Surg**, v. 54, n. 3, p. 250-4, 1996.

MADSEN, M. J.; HAUG, R. H. Uma comparação biomecânica de 2 técnicas para reconstruir fraturas edêntulas atroficas de mandíbula. **J Oral Maxillofac Surg**, v. 64, p. 457-465, 2006.

MANGANELLO, L.C.S.; LUZ, J.G.C. **Tratamento cirúrgico do trauma bucomaxilofacial**. 4. ed. São Paulo: Quintessence, 2018.

MARDONES, M. M.; NAVIA, G.E.; BRAVO, A.R. & MAYER, O.C. Tratamiento de fracturas en mandíbulas atroficas: Presentación de dos casos clínicos. **Int. J. Odontostomat**, v. 5, n. 2, p. 126-132, 2011.

MATOS, J. D. M.; LOPES, G.D.R.S.; PINTO, A.D.; *et al.* Reabilitação de fratura complexa de mandíbula atrofica com placa tipo locking relato de caso. **Full dent. sci**, v. 9, n. 36, p. 50-56, 2018.

MEIJER, H. J. A.; RAGHOEBAR, G. M.; VISSER, A. Mandibular Fracture Caused by Peri-Implant Bone Loss: Report of a Case. **J Periodontol**, v. 74, n. 7, p. 1067-70, 2003.

MENDONÇA, J. C. G.; JARDIM, E.C.G.; MANRIQUE, G.R.; *et al.* Surgical Treatment of Fracture in Atrophic Jaw. Surgical Treatment of Fracture in Atrophic Jaw. **J Biotechnol Biomaterial**, v. 2, 2012.

MINUCCI, M. S.; SOL, I.; SANTOS, D.M. Tratamento cirúrgico de fratura bilateral de mandíbula atrofica. **Relatos de Casos Cirúrgicos**, 2018.

NAVEGANTES, L. J. Fratura de mandíbula edentula atrofica: relato de caso. **Revista Fluminense de Odontologia**, n. 52, 2019.

NETO, J. L. O.; CORAL, A. J.; GODOI, V. R. F. DE.; *et al.* Treatment of atrophic jaw fracture approached by transcervical access: case report. **Brazilian Journal of Health Review**, v. 5, n. 6, p. 22322-22334, 2022.

NORKUS, R. G.; WHITE, N.S.; THOMAS, R.F.; *et al.* Application of a lateral compression clamp in the management of mandibular fractures. **Oral Surg Oral Med Oral Pathol**, v. 39, n. 1, p. 2-13, 1975.



NOVELLI, G.; SCONZA, C.; ARDITO, E.; *et al.* Surgical Treatment of the Atrophic Mandibular Fractures by Locked Plates Systems: Our Experience and a Literature Review. **Craniomaxillofacial Trauma and Reconstruction**, v. 5, n. 2, 2012.

OLIVEIRA, J. P. M. S.; CORSO, P.L.D.; OLIVEIRA, J.C. Atrophic Jaw Fracture And Predictability In Oral Rehabilitation: Case Report. **Brasilian Dental Science**, v. 23, n. 3, 2020.

OLIVEIRA, M. M. M.; ALMEIDA, A. C. de; LAUAND, G. A.; *et al.* Surgical treatment of bilateral fracture of atrophic mandibula: Case report. **Research, Society and Development**, v. 10, n. 1, 2021.

OLIVEIRA, E. O. M.; NETO, A.G.O.; TOMES, C.R.; *et al.* Tratamento cirúrgico em fratura de mandíbula atrofica: uma revisão de literatura. **International Journal of Science Dentistry**, v. 2, n. 58, p. 135-145, 2022.

PEREIRA, R. S.; BONARDI, J. P.; DA SILVA, J. R.; *et al.* Tratamento cirúrgico da fratura de mandibula atrofica pela técnica AO: relato de caso. **Archives of Health Investigation**, v. 6, n. 3, 2017.

PHILIP, L.; DAVID, R. Spontaneous mandibularfracture in a partially edentulous patient: case report. **J can dent assoc**, v. 69, n. 7, p. 428-30, 2003.

RAGHOEBAR, G. M.; STELLINGSMA, K.; BATENBURG, R.H.; *et al.* Etiology and management of mandibular fractures associated with endosteal implants in the atrophic mandible. **Oral Surg Oral Med Oral Pathol Oral Radiol Endod**, v. 89, n. 5, p. 553-9, 2000.

ROSA, E. L. S. Correção de Fratura em Mandibula Atrófica com Auxílio da Prototipagem Rápida. **Revista Brasileira de Cirurgia Buco-Maxilo-Facial**, v. 11, n. 1, p. 23-28, 2011.

RÜCKER, M. Redução da falha de perfusão do periósteo facial médio por dissecção subperiosteal versus supraperiosteal. **J Oral Maxillofac Surg**, v. 63, p. 87, 2005.

SEPER, L.; JOOS, U.; MEYER, U. Treatment of fractures of the atrophic mandible in the elderly. **J Am Geriatr Soc**, v. 52, n. 9, p. 1583-4, 2004.

SHOHAT, I.; SHOSHANI, Y.; TAICHER, S. Fracture of the genial tubercles associated with a mandibular denture: a clinical report. **J Prosthet Dent**, v. 89, n. 3, p. 232-3, 2003.

SIDRAMESH, M.; CHATURVEDI, P.; CHAUKAR, D.; *et al.* Spontaneous bilateral fracture of the mandible: a case report and review of literature. **J Cancer Res Ther**, v. 6, n. 3, p. 324-6, 2010.

SIGNORINI, L.; *et al.* Fratura bilateral de mandíbula atrofica. **Revista Sul-Brasileira de Odontologia**, v. 3, n. 2, p. 32-36, 2006.

SIKES, J. W JR.; SMITH, B. R.; MUKHERJEE, D. P. Um estudo in vitro do efeito do reforço ósseo na força de fixação de um modelo de mandíbula desdentada atrofica fraturada. **J Oral Maxillofac Surg**, v. 58, p. 56-61, 2000.



SINDEL, A.; ÖZALP, Ö.; BILGIN, B. Extraoral approach to a bilateral unfavourable mandibular fracture under local anaesthesia: A case report. **Gerodontology**, v. 38, n. 2, p. 228-231, 2021.

TIWANA, P. S.; ABRAHAM, M.S.; KUSHNER, G. M.; *et al.* Management of atrophic edentulous mandibular fractures: the case for primary reconstruction with immediate bone grafting. **J Oral Maxillofac Surg**, v. 67, n. 4, p. 882-7, 2009.

VAN LEEUWEN, A. C.; VAN DER MEIJ, E. H. VISSCHER, J. G. 2014 - FRACTURE OF THE GENIAL tubercles of the mandible: case report and review of the literature. **J Oral Maxillofac Surg**, v. 72, n. 10, 2014.

VERZOLA, M. H. A.; OLIVEIRA, G.J.P.L.; SOUZA, J.A.C.; *et al.* Treatment of atrophic mandibular fracture related to implant placement in an oral bisphosphonate user: a case report. **Rev Odontol Bras Central**, 2015.

WONGCHUENSOONTORN, C.; LIEBEHENSCHER, N.; SCHWARZ, U.; *et al.* Application of a new chair-side method for the harvest of mesenchymal stem cells in a patient with nonunion of a fracture of the atrophic mandible--a case report. **J Craniomaxillofac Surg**, v. 37, n. 3, p. 155-61, 2009.

YAMAMOTO, K.; MATSUSUE, Y.; HORITA, S.; *et al.* A mandibular body fracture related to mouth-opening training in a dialysis patient. **Dent Traumatol**, v. 27, n. 4, p. 318-20, 2011.

ZIDE, M. F. & DUCIC, Y. Fibula microvascular free tissue reconstruction of the severely comminuted atrophic mandible fracture— case report. **Journal of Cranio-Maxillofacial Surgery**, v. 31, p. 296-298, 2003.