

Paracoccidioidomycosis 40 years after renal transplantation: a case-report

Paracoccidioidomicose 40 anos após transplante renal: um relato de caso

DOI:10.34117/bjdv8n12-019

Recebimento dos originais: 28/11/2022

Aceitação para publicação: 01/12/2022

Kátia de Paula Farah

PhD in Tropical Medicine, Federal University of Minas Gerais
Institution: Universidade Federal de Minas Gerais (UFMG)
Address: Avenida Professor Alfredo Balena, 190, Santa Efigênia, Belo Horizonte – MG, CEP:30130-100
E-mail: katiafarah@gmail.com

Érica Cristina Vieira

Master Infectious Diseases and Tropical Medicine
Institution: Universidade Federal de Minas Gerais (UFMG)
Address: Alameda Vereador Álvaro Celso, 55, Santa Efigênia, Belo Horizonte – MG
CEP:30150-260
E-mail: vieira.ERICA@gmail.com

Stanley de Almeida Araújo

Master in Medicine from the Federal University of Minas Gerais (UFMG)
Institution: Universidade Federal de Minas Gerais (UFMG)
Address: Avenida Professor Alfredo Balena, 190, Santa Efigênia, Belo Horizonte - MG,
CEP: 30130-100
E-mail: stanleyaa@gmail.com

Milena Soriano Marcolino

Postdoctoral Fellowship in Infectious and Tropical Medicine
Institution: Universidade Federal de Minas Gerais (UFMG)
Address: Avenida Professor Alfredo Balena, 190 sala 246, Santa Efigênia, Belo Horizonte – MG, CEP:30130-100
E-mail: milenamarc@gmail.com

Marcelo Grossi Araújo

PhD in Sciences Applied to Adult Health, Federal University of Minas Gerais (UFMG)
Institution: Universidade Federal de Minas Gerais (UFMG)
Address: Alameda Vereador Álvaro Celso, 55, Santa Efigênia, Belo Horizonte - MG,
CEP: 30150-260
E-mail: grossimar@gmail.com

ABSTRACT

Paracoccidioidomycosis is a systemic mycotic disease caused by thermic-dimorphic fungi from the *Paracoccidioides sp* complex, which are endemic in Brazil and over 90% of cases are presented in the chronic form. It is a rare and severe infection in patients that

underwent organ transplantation, according to few reported cases in literature. Our aim is to report a rare occurrence of paracoccidioidomycosis in a renal transplant recipient, diagnosed over 40 years after the procedure and to draw attention to the importance of considering the diagnosis in immunosuppressed patients from endemic areas.

Keywords: Paracoccidioidomycosis, kidney transplantation, immunosuppression therapy, case report.

RESUMO

A Paracoccidioidomicose é uma doença micótica sistêmica causada por fungos termodimórficos do complexo *Paracoccidioides* sp, que são endêmicos no Brasil e mais de 90% dos casos são apresentados sob a forma crônica. É uma infecção rara e grave em doentes que foram submetidos a transplante de órgãos, de acordo com poucos casos relatados na literatura. O nosso objectivo é relatar uma ocorrência rara de paracoccidioidomicose num receptor de transplante renal, diagnosticada mais de 40 anos após o procedimento e chamar a atenção para a importância de considerar o diagnóstico em doentes imunossuprimidos de áreas endêmicas.

Palavras-chave: Paracoccidioidomicose, transplante renal, terapia imunossupressora, relato de caso.

1 INTRODUCTION

Paracoccidioidomycosis (PMC) is a systemic fungal disease prevalent in Latin America, with the majority of cases found in Brazil ^{1,2}. It is caused by thermally dimorphic fungi from *Paracoccidioides brasiliensis* (*P. brasiliensis*) and *Paracoccidioides lutzii* (*P. lutzii*) complexes, with the last one being described in Brazil's North and Midwest regions. The fungus most commonly affects previously healthy young men ¹.

Although the condition is considered rare in solid organ transplants (SOT), the disease's severity potential is high, considering high mortality rates in this situation ². Besides the difficulty in diagnosing paracoccidioidomycosis, the small number of cases reported in immunosuppressed, reinforces the challenge of early diagnosis ²⁻³.

We report a case of paracoccidioidomycosis in a renal transplant recipient diagnosed over 40 years after the procedure, which is probably the latest occurrence described in literature.

2 CASE HISTORY

Caucasian, male, aged 63, from the state of Minas Gerais (Brazil), began his work life in the pelletizing process of iron mining, and had fishing as a hobby. He underwent living-donor (sister, no relevant health conditions) renal transplantation in January 1967.

In 2015 presented worsening in his general state, with hyporexia, progressive weight loss (approximately 15 kgs within a year) and intermittent diarrhea, developing along six months, with no initial respiratory tract symptoms.

During hospitalization in 2016, diarrhea propedeutics were made, following negative results, as well as abdominal ultrasonography, that showed no relevant alterations. The upper digestive endoscopy showed mild erosive esophagitis. At the same time, colonoscopy exhibited not-specified moderate intensity colitis and rectitis, associated with an active colonic ulcer, besides descending colon and sigmoid diverticular disease. According to the histological analysis of the colonic ulcer fragment and polyp, there were no signs of malignancy and the search for fungi and protozoans was negative. During ambulatory follow-up, the patient presented persistent dry-cough and daily nocturnal fever, with no complaints of dyspnea or ventilatory-dependent thoracic pain.

Skin lesions characterized by erythematous papules with development of central crusts and erosion in the back and on the nose were noticed (Figure 1). A new thoracic computerized tomography (CT) showed an expansive injury in the right lung 's middle lobe, with ground-glass opacity areas surrounded by bilateral parenchymal micronodules and extensive mediastinal lymphadenopathy (Figure 2). At bronchoscopy, an infiltrative injury in right lung superior and middle lobe bronchi and lesion implants in terminal trachea were presented. Pulmonary biopsy identified round structures that suggested the presence of *Paracoccidioides sp* in the trachea and in bronchoalveolar lavage (Figure 3A). Granulomatous dermatitis with structures compatible with *Paracoccidioides sp*. (Figure 3B and 3C) were observed in the patient 's skin. The, bronchoalveolar's lavage sputum was negative for acid-alcohol-fast bacilli investigation and there was no culture fungal growth.

Figure 1 – erythematous papule, and lesion with central crust and erosion, and elevated edges, located on the back

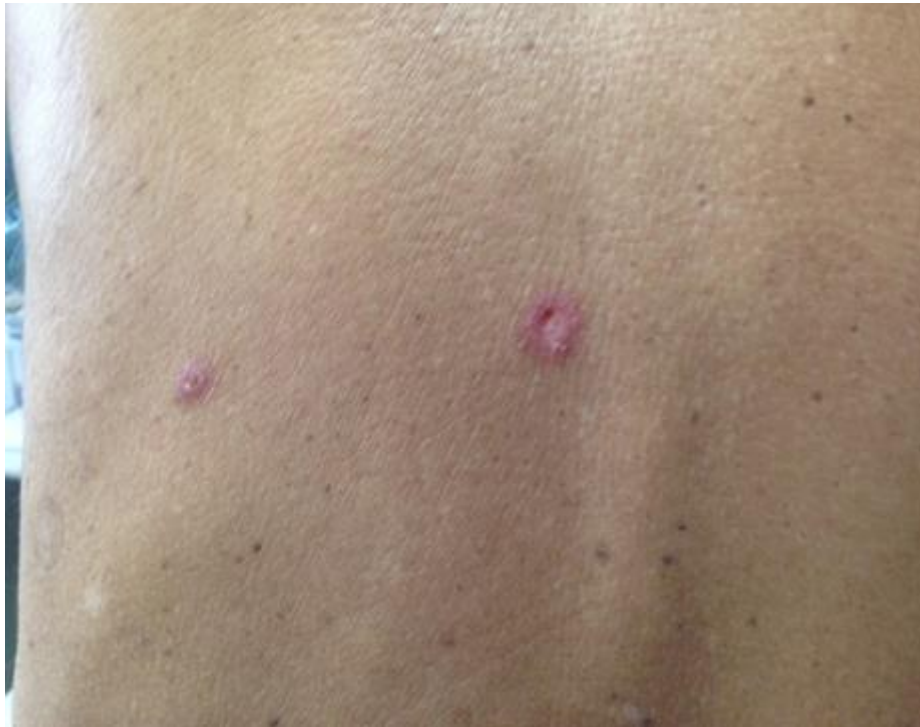

Figure 2 - Expansive injury on the right lung's middle lobe, with ground-glass opacity areas and bilateral micronodules in the parenchyma, as well as mediastinal lymphadenopathy

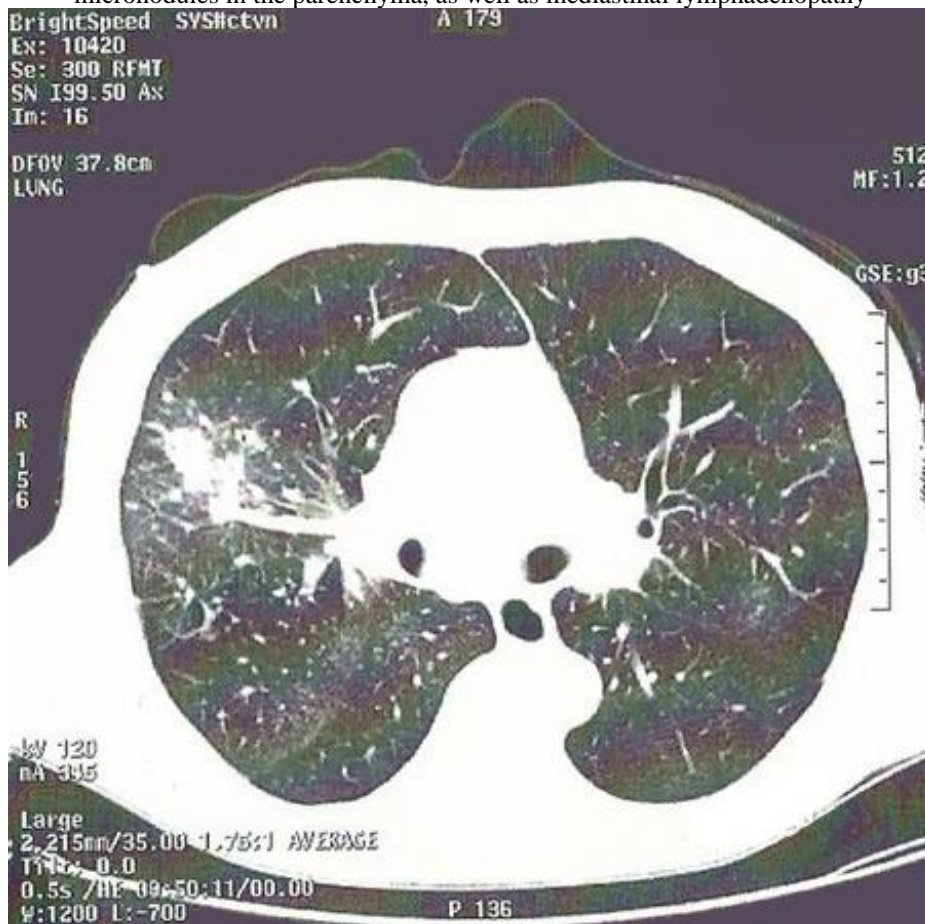
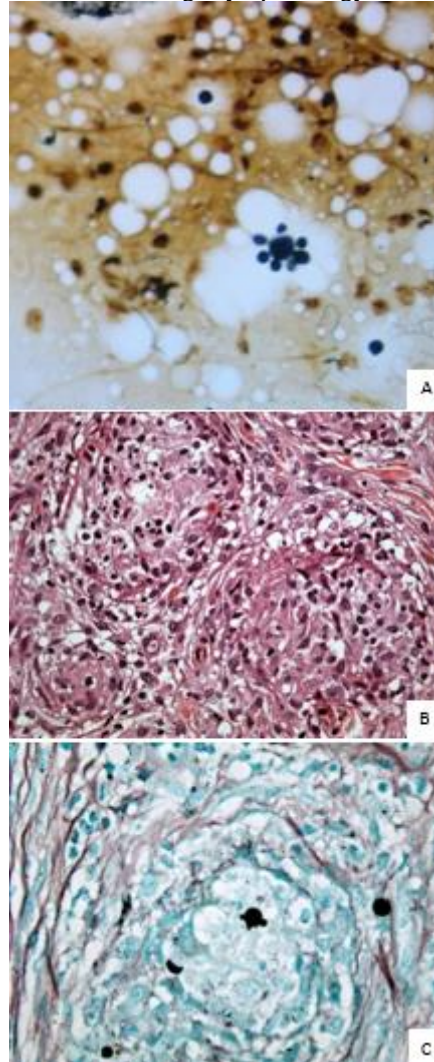


Figure 3 - Bronchial lavage cytopathology and skin biopsy



- A) A “mariner’s” wheel structure stained in Grocott-Gomori from tracheal sputum (100x).
- B) Dermis granulomatous reaction, with neutrophils intermingled with eosinophils (stains of hematoxylin-eosin 40X)
- C) Center of a dermis granuloma, colored in Grocott-Gomori, with argyrophilic and round structures with buds (100X).

In March 2016, treatment with Itraconazole was initiated. Renal function remained stable, nevertheless, Tacrolimus dose was reduced, due to its known interaction with azole antifungals. The patient showed signs of improvement in respiratory and skin lesion symptoms, however hyporexia was maintained. During ambulatory follow-up, the patient was diagnosed with Addison’s disease, with great response to clinical treatment, improving previous conditions, such as hyperkalemia, hyponatremia, asthenia, fatigue and weight loss. Abdominal and pelvic CT did not show any adrenal injuries, and a progressive reduction of the expansive injury was observed in thoracic CT, as well as a depletion in ground-glass opacity areas. The last CT, performed 19 months later,

presented fibrosis and atelectasis, besides a calcified parenchymatous nodule. During this period, renal function got worse, leading to graft loss and, later on, death.

3 DISCUSSION

PMC is one of the emergent fungal infections in patients that underwent SOT. Although the prevalence is higher in kidney transplantations, liver and lung receivers are at higher risk^{2,4,5}. A Brazilian study collected 102 autopsy samples from renal transplants and found the PMC in four individuals, being the described cause of death in one of them⁶. The condition is also described in immunosuppressed patients from HIV and cancer³. Even with the increased numbers of immunosuppressants, there are few reported cases of PMC in immunosuppressed patients from endemic areas, however, mortality from the condition is high^{3,7}.

From twelve diagnosis in living patients described in literature, three were from liver receivers, meanwhile the other nine were from patients who received kidney grafts^{2,5,6,7,8,9,10,11}. Opposedly to what is observed in other mycoses, such as cryptococcosis, histoplasmosis and blastomycosis, most cases of PMC happened between one and five years after transplantation, with one diagnosis after eleven years of the procedure and another after fourteen years among SOT^{2,5,8}. Also, only one case was described during induction therapy⁶. Besides that, one of the cases found in literature, from the same region as the present case report, happened five years after the second renal transplant and a three-drug suppression scheme was seen as a promoter for the infection⁸.

The present case describes the latest diagnosis of PMC in a SOT patient found in literature. According to the living-donor and to the patient's previous histories, it is possible that the condition was caused by a reactivation of a late infection, probably from the times when the patient worked in mining, since soil management activities predominate in literature¹. Nonetheless, the possibility of recent infection may not be discharged, since the patient would usually go fishing in rural areas. Amongst renal transplanted patients, lung, skin and oral mucosa were the most frequently affected sites of infection^{2,5,8}.

During the follow up the patient developed adrenal insufficiency that was attributed to PMC, even though the CT did not show anatomic alterations of the glands. Adrenal impairment is described in up to 80% of autopsies, in which 3,5% of patients presented Addison's disease, requiring hormone replacement therapy¹. The small number of PMC cases within less than a year of transplantation can be explained by the

prophylaxis therapy with Sulfamethoxazole and Trimethoprim during the acute induction phase ⁷. Even with the recommendation for using liposomal Amphotericin B in severe cases ^{1,8}, Itraconazole was chosen for patient treatment in order to avoid renal impairment aggravation on a graft that already presented radiological signs of kidney damage (hydronephrosis) and progressive reduction of the glomerular filtration rate.

Although there is no recommended screening for PMC in donors and SOT candidates, some studies suggest an algorithm based on image studies and serologies in the pre-transplantation phase ^{5,12}. In SOT recipients it is fundamental to advise and follow-up focusing on primary prevention and on the early diagnosis of opportunist mycosis, especially PMC in endemic regions.

Abbreviations

CT	Computerized tomography
PMC	Paracoccidioidomycosis
SOT	Solid organ transplants

REFERENCES

1. Shikanai-Yasuda MA, Mendes RP, Colombo AL, Queiroz-Telles F, Kono ASG, Paniago AMM, et al. Brazilian guidelines for the clinical management of paracoccidioidomycosis. *Rev Soc Bras Med Trop.* 2017 Sep-Oct;50(5):715-740. doi: 10.1590/0037-8682-0230-2017
2. Peçanha-Pietrobon PM, Falqueto A, Rodrigues Gandarella AD, Moyzès JV, Rangel KA, Miranda LB, et al. Case Report: Paracoccidioidomycosis in Solid Organ Transplantation: Disseminated Disease in a Liver Recipient and Literature Review. *Am J Trop Med Hyg.* 2019 Nov;101(5):1100-1106. doi: 10.4269/ajtmh.18-1008
3. de Almeida JN Jr, Peçanha-Pietrobon PM, Colombo AL. Paracoccidioidomycosis in Immunocompromised Patients: A Literature Review. *J Fungi (Basel).* 2018 Dec 26;5(1):2. doi: 10.3390/jof5010002
4. Shoham S, Dominguez EA; AST Infectious Diseases Community of Practice. Emerging fungal infections in solid organ transplant recipients: Guidelines of the American Society of Transplantation Infectious Diseases Community of Practice. *Clin Transplant.* 2019 Sep;33(9):e13525. doi: 10.1111/ctr.13525
5. Valentim FO, Tsutsui GM, Abbade LPF, Marques SA. Disseminated paracoccidioidomycosis in a liver transplant patient. *An Bras Dermatol.* 2021 May-Jun;96(3):346-348. doi: 10.1016/j.abd.2020.07.011
6. Reis MA, Costa RS, Ferraz AS. Causes of death in renal transplant recipients: a study of 102 autopsies from 1968 to 1991. *J R Soc Med.* 1995 Jan;88(1):24-7.
7. Radisic MV, Linares L, Afeltra J, Pujato N, Vitale RG, Bravo M, et al. Acute pulmonary involvement by paracoccidioidomycosis disease immediately after kidney transplantation: Case report and literature review. *Transpl Infect Dis.* 2017 Apr;19(2):1-2. doi: 10.1111/tid.12655
8. Felipe CRA, Silva AD, Penido MGG. Disseminated paracoccidioidomycosis in a Kidney transplant recipient. *Cureus.* 2021; 13(10): e19007. doi: 10.7759/cureus.19007
9. Shikanai-Yasuda MA, Duarte MI, Nunes DF, Lacaz CS, Sabagga E, Abdala E, et al. Paracoccidioidomycosis in a renal transplant recipient. *J Med Vet Mycol.* 1995 Nov-Dec;33(6):411-4. doi: 10.1080/02681219580000781
10. Pontes AM, Borborema J, Correia CR, de Almeida WL, Maciel RF. A rare paracoccidioidomycosis diagnosis in a kidney transplant receptor: case report. *Transplant Proc.* 2015 May;47(4):1048-50. doi: 10.1016/j.transproceed.2015.03.006
11. Góes HF, Durães SM, Lima Cdos S, Souza MB, Vilar EA, Dalston MO. Paracoccidioidomycosis In A Renal Transplant Recipient. *Rev Inst Med Trop Sao Paulo.* 2016;58:12. doi: 10.1590/S1678-9946201658012
12. Batista MV, Sato PK, Pierrotti LC, de Paula FJ, Ferreira GF, Ribeiro-David DS, Nahas WC, et al. Recipient of kidney from donor with asymptomatic infection by *Paracoccidioides brasiliensis*. *Med Mycol.* 2012 Feb;50(2):187-92. doi: 10.3109/13693786.2011.574237