

Complication of acute Otitis media in pediatrics: a case report

Complicação de Otite média aguda em pediatria: um relato de caso

DOI:10.34117/bjdv8n11-352

Recebimento dos originais: 28/10/2022

Aceitação para publicação: 29/11/2022

Bruno Rocha Silva Setta

Professional Masters in Urban and Environmental Engineering by Pontifícia Universidade Católica do Rio de Janeiro (PUC-RJ), Master of Science pela Technische Universität Braunschweig

Institution: Centro Universitário de Volta Redonda (UNIFOA)
Address: Rua 165, N° 155, Vila Santa Cecília, Volta Redonda - RJ
E-mail: brunosetta@hotmail.com

Mayra Rozália Loureiro Novaes

Graduate Student of Medicine

Institution: Centro Universitário de Volta Redonda (UNIFOA)
Address: Rua Paulo Mendes, 271, Monte Castelo, Volta Redonda - RJ
E-mail: mayraloureironovaes@gmail.com

Rider Santiago Alcoba Júnior

Graduate Student of Medicine

Institution: Centro Universitário de Volta Redonda (UNIFOA)
Address: Rua Eval Mury Glória, N° 242, São João Batista, Volta Redonda - RJ
E-mail: ridersantiago@gmail.com

Luiza Moraes Dias Pereira

Medical Graduating Student

Institution: Centro Universitário de Volta Redonda (UNIFOA)
Address: Rua Benedito Vitalino, N° 494, Santa Cruz, Volta Redonda - RJ
E-mail: luiza.diasp@gmail.com

Nathalia Chinellato de Lima Oliveira

Graduated in Medicine

Institution: Hospital Municipal Dr. Munir Rafful
Address: Av. Jaraguá, N° 1020, Retiro, Volta Redonda - RJ
E-mail: nathaliachinellato@hotmail.com

Priscila Ramalho Oliveira

Specialist in Otorhinolaryngology

Institution: Centro Universitário de Volta Redonda (UNIFOA)
Address: Rua 26, N° 36, Vila Santa Cecília, Volta Redonda - RJ
E-mail: prirobarreiros@gmail.com

Luciano Rodrigues Costa

Professional Master's in Teaching in Health and Environmental Sciences
Institution: Centro Universitário de Volta Redonda (UNIFOA)
Address: Rua Albert Sabin, Nº 60, Vila Mury, Volta Redonda - RJ
E-mail: lukamedcosta@gmail.com

ABSTRACT

The acute otitis media (AOM) is a frequent bacterial infection in Pediatrics. Despite the advance of antibiotic therapy in the treatment of this infection, there is the possibility of a rare complication, Gradenigo Syndrome (GS). This is a serious complication that should be suspected in a patient with abducens nerve paralysis, pain in the trigeminal innervation area and AOM. The objective of this work was to describe a case report in pediatric regarding to Gradenigo's Syndrome and reinforce the importance of early diagnosis in the treatment. In addition, a literature review of articles in journals indexed in the following databases was carried out: Pubmed, Lilacs and Scielo. The case report presented is a 7-year-old girl, presenting a typical clinical of GS that evolved satisfactorily with the management based on broad-spectrum antibiotic therapy, without the need for a subsequent surgical approach. Thus, it is clear that the identification of the classic triad of GS, in addition to performing imaging tests, allows for an early diagnosis of the disease, favoring a conservative approach with antibiotic therapy.

Keywords: Gradenigo's Syndrome, pediatrics, complications of otitis media.

RESUMO

A otite média aguda (OMA) é uma infecção bacteriana frequente em Pediatria. Apesar do avanço da antibioticoterapia no tratamento dessa infecção, existe a possibilidade de uma complicação rara, a Síndrome de Gradenigo (SG). Esta é uma complicação grave que deve ser suspeitada em um paciente com paralisia do nervo abducente, dor na área de inervação trigeminal e OMA. O objetivo deste trabalho foi descrever um relato de caso em pediatria referente à Síndrome de Gradenigo e reforçar a importância do diagnóstico precoce no tratamento. Além disso, foi realizada a revisão da literatura de artigos em periódicos indexados nas seguintes bases de dados: Pubmed, Lilacs e Scielo. O relato de caso apresentado é de uma menina de 7 anos de idade, apresentando um quadro clínico típico de SG que evoluiu satisfatoriamente com o manejo baseado em antibioticoterapia de amplo espectro, sem necessidade de abordagem cirúrgica posterior. Assim, fica claro que a identificação da tríade clássica da SG, além da realização de exames de imagem, permite o diagnóstico precoce da doença, favorecendo uma abordagem conservadora com antibioticoterapia.

Palavras-chave: Síndrome de Gradenigo, pediatria, complicação de otite media.

1 INTRODUCTION

Otitis media is an infection of the middle ear that can affect patients of any age. Its clinical course can be short, due to the response of the immune system and the sensitivity of the germ to the antibiotic used, but a small number of patients can present complications¹. Among some of these, there is Gradenigo Syndrome (GS) or Apical

Petrositis. Primarily described in 1907 by Guisepe Gradenigo, this syndrome is characterized by the classic triad of otitis media complicated with purulent otorrhea, pain in the area of innervation of the first or second branch of the trigeminal nerve and paralysis of the abducens nerve².

For the diagnosis of GS, a good clinical evaluation is necessary, associated with physical examination and imaging tests, especially computed tomography (CT) and magnetic resonance imaging (MRI). The use of these imaging methods is both essential for performing differential diagnoses and for the therapeutic and surgical approach³.

With the use of antibiotic therapy, the incidence and prevalence of GS have decreased, and it is currently considered a rare, potentially fatal pathology, more frequent in adulthood². However, in developing countries, where access and quality of health services are a great public health challenge¹, some complications may arise, as this case presented, and extend to an intratemporal and intracranial location.

Therefore, this paper describes a case report in pediatrics of Gradenigo Syndrome as a rare complication of acute suppurative otitis media (ASOM).

2 METHODOLOGY

This article was developed from one clinical case experienced in the pediatric ward of the Hospital Municipal Dr. Munir Rafful, in the municipality of Volta Redonda-RJ.

A contemporary review of the literature was conducted searching for articles published in Pubmed, Lilacs and Scielo databases, using the following algorithm: Gradenigo's Syndrome, pediatrics and complications of acute otitis media, from 2018 to 2022.

Consent: This case report is under the scope of the "Project of Education at Work for Health at the University Center of Volta Redonda - PET-UniFOA", registered at Certificate of Presentation of Ethical Appreciation (CPEA) under the number 30457714.1.0000.5237. The free and clarified consent term was signed by the guardians of the minor described in this research.

3 CASE PRESENTATION

A 7-year-old girl, black, who was admitted with her father to the Pediatric Emergency (PE), at Hospital Municipal Dr. Munir Rafful (HMMR), located in the Municipality of Volta Redonda - RJ, with the clinical of inappetence, body aches and

headache on 03/01/2022. A symptomatic medication was prescribed for the pain, with improvement of the condition at the same day. However, the child returned with her father, on 03/08/2022, with asthenia and headache. Blood tests were performed on this day, without relevant changes and they left the hospital with anti-inflammatory drugs to go home.

Five days after the last attendance, the child returned again with her father to the PE, presenting headache and asthenia, in addition to gait alteration (ataxia), decreased visual acuity and marked hearing loss in the left ear. In addition, the father mentioned that her's eyes presented "strabismus" sometimes and she threw up. Then, it was decided to hospitalize the child for investigation.

During the first two days of hospitalization, the child had severe headache in the left frontal region, and difficulty for walking and balancing. On the physical examination, she was in a regular general condition, apathetic, afebrile, and presented pain in the area of innervation of the ophthalmic branch of the trigeminal nerve on the left and horizontal nystagmus (limitation marked by abduction of the eyes due to cranial nerve VI paresis). The use of venous acyclovir was initiated, due to the suspicion of viral encephalitis.

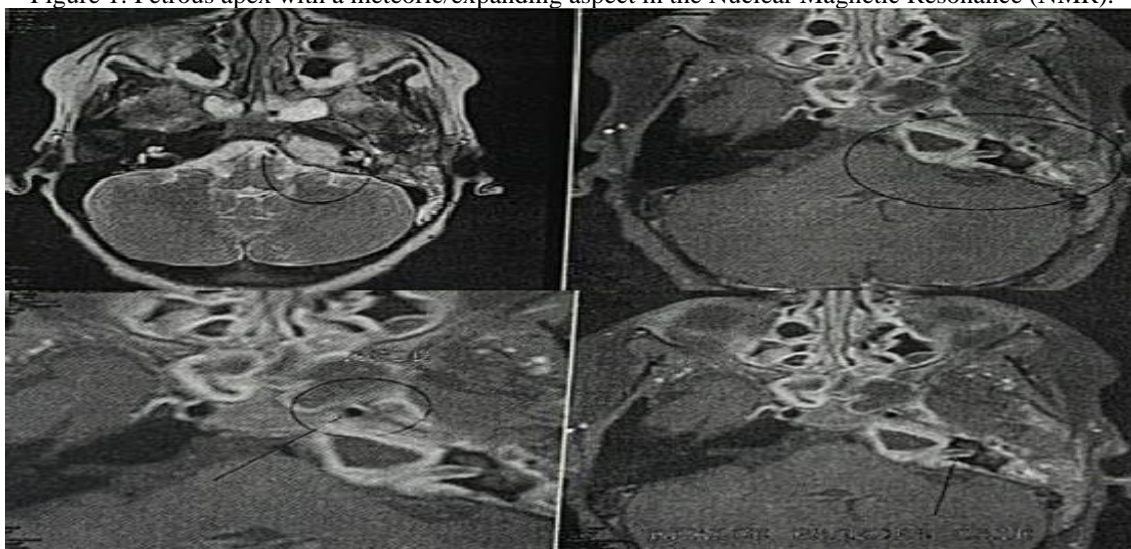
On the third day of hospitalization, on the physical examination, there were no phlogistic signs in the mastoids and the right otoscopy was normal, but the left otoscopy showed purulent exudate and tympanic membrane hyperemia. Then, the use of acyclovir was discontinued and intravenous antibiotic use was initiated: vancomycin, oxacillin and metronidazole, due to the suspicion of complicated acute otitis media.

With the alteration identified in the left ear, a technical opinion was requested to the otorhinolaryngologist of the HMMR, who asked the investigation of Gradenigo's Syndrome (GS) by means of a computed tomography (CT) of the mastoids, indicated intravenous antibiotic therapy with ceftriaxone, vancomycin and metronidazole, in addition to assess the need for a surgical approach. Thus, oxacillin was replaced by ceftriaxone, associated with metronidazole and vancomycin, and the treatment was maintained for 21 days.

During the attendance by the otorhinolaryngology team, the need for a surgical approach with mastoidectomy was evaluated. However, they chosed to maintain antibiotic therapy and performed a myringotomy with placement of a ventilation tube in the left ear, as there was no longer any purulent secretion in the external auditory canal and tympanic cavity during the surgery.

The patient did a cranial nuclear magnetic resonance (NMR), according to figure 1, on the fifth of hospitalization, which identified petrous apex with a meteoric/expanding aspect, filled with protein content/purulent material, thickening of the posterior face of the petrous/mastoid portion temporal bone and no signs of dural sinus thrombosis. In the mastoid CT, performed on 03/14/2022 as request by the orinolaryngologist, acute left otomastoiditis and sphenoid maxillary sinusopathy were identified. Based on the clinical findings, imaging exams and physical exam, the diagnosis of Gradenigo's Syndrome (GS) was made.

Figure 1: Petrous apex with a meteoric/expanding aspect in the Nuclear Magnetic Resonance (NMR).



On the seventh day of antibiotic therapy, there was regression of headache, asthenia and improvement in ambulation. After twelve days, there was improvement in horizontal nystagmus and left hearing loss. Laboratory tests during hospitalization did not show important changes.

With the end of intravenous antibiotic therapy and evident clinical improvement, remaining a total of twenty-five days hospitalized in the HMMR, the patient was discharged with oral clavulin 875 mg/125 mg for 10 days (medication delivered at the time of discharge). The parents were also instructed not to wet the left ear, use cotton with vaseline in the bath and to return when the clinical condition worsens. In addition, the child was referred for outpatient follow-up with the otorhinolaryngologist who assisted in the care during hospitalization, and with the pediatric service of the same hospital. The review consultation with the otolaryngologist took place 7 days after her's discharge, with no complaints and no changes in the physical examination.

4 DISCUSSION

This is a 7-year-old female patient, with low socioeconomic status, who initially did not show classic signs and symptoms of Gradenigo's Syndrome (the triad). In addition, as it is a pathology that is not very prevalent in medical practice², at the first moment of the attendance at the PE of the HMMR, the patient's present clinic did not allow an early diagnosis of the pathology.

The etiopathogenesis can be understood by describing the anatomy of the petrous portion of the temporal bone. From the moment the process enters into the cranial cavity, several lesions, which are combined in many ways, can occur without an order of appearance of symptoms, but the interval time between the suppurative process of the middle ear and the involvement of the apex petrosus is 1-12 weeks⁴. In this clinical report, 12 days has passed since the beginning of the symptoms to the sixth nerve palsy.

The patient's symptoms started with headache, which occurs due to edematous infiltration of the Gasserian Ganglion (seat of nerve cells whose dendrites constitute the sensory portion of the trigeminal)⁴. Left earache was a late symptom, being intense and deep, and could radiate to the temporoparietal, retroocular or mandibular region⁵. This aspect alerts to the need for a well performed anamnesis.

The patient had pain in the area of innervation of the ophthalmic branch of the trigeminal on the left, with horizontal nystagmus, due to the proximity of the abducens nerve and the ophthalmic branch of the trigeminal. Infectious propagation commonly affects these nerves causing, respectively, abducens paralysis and retroorbital hyperalgesia, reported by Gradenigo⁶.

The typical mastoid CT findings are: opacification of the air cells of the mastoid and middle ear, with possible bone destruction, sinus gas and formation of a dural, intracranial or extradural abscess⁷. The patient underwent a CT scan of the mastoids, in which acute left otomastoiditis and maxillary sphenoid sinus disease were observed. In addition, she had previously performed a cranial NMR, which identified the petrous apex with characteristics of an infectious process at the site, but without signs of thrombosis. Such imaging tests were essential both for the characterization of the lesion extension and involvement of adjacent structures, as well as for the therapeutic direction to be used.

In the case presented, the treatment with broad spectrum antibiotic therapy was started empirically, as indicated by the scientific literature⁸, with ceftriaxone, metronidazole and vancomycin. It is worth noting that at the beginning of the disease, as the condition of viral encephalitis was suspected, we used acyclovir until the

otorhinolaryngologist approach. The same antibiotic regimen used in this work was also performed by Carvalho et al. (2019) and Félix et al. (2003).

During the patient's hospitalization, the placement of a short-term ventilation tube was necessary to promote drainage of the purulent secretion present in the left ear, the same technique was used in the work by Carvalho et al. (2019). From this procedure, it is possible to analyze the microbiology present in the infectious site, but in this work this analysis was not performed, due to the patient's previous manipulation of systemic antibiotics, it would lose its practical value, since the microbial flora already would be changed. The most common microbiological agents in GS are *Streptococcus pneumoniae*, *Haemophilus influenzae* and *Moraxella catarrhalis*, and the least frequent are *Staphylococcus aureus*, *Pseudomonas aeruginosa* and *Proteus*⁹.

Due to the patient's good clinical response to antibiotic therapy, more aggressive treatment with mastoidectomy was not necessary. This therapy is reserved for cases that are refractory to antibiotics, with worsening of the clinical course or that ones which demonstrate signs of chronic process¹⁰.

Other intracranial complications may be associated with GS, such as meningitis, venous sinus thrombophlebitis, and brain abscess¹⁰, further ophthalmologic complications such as IV cranial nerve palsy, papilledema and Horner's syndrome¹¹. In this case presented, the patient did not present any other complication associated with GS.

5 CONCLUSION

The Gradenigo's Syndrome, despite the rare occurrence after the emergence of antibiotics, should always be considered when there is facial pain and abducens nerve palsy in a condition of acute otitis media or after it. Its classic approach consisted of an aggressive surgical intervention. However, recent reports demonstrate good results with conservative treatment, like this work, reserving surgery for specific cases that do not respond well to the initial conservative approach.

It is also recommended that after hospital discharge, especially in the case of pediatric patients, parents are properly oriented regarding post-discharge care and that patients are referred to specialists, so that audiometric, vestibular or neurological assessments can be performed routinely and, thus, avoid possible complications.

FUNDING ACKNOWLEDGEMENTS

This research received no specific grant from any funding agency in the public, commercial, or not-for-profit sectors.

CONFLICT OF INTEREST STATEMENT

The authors declare no conflict of interest in preparing this article.

REFERENCES

Oña GC, Oña CC, Santana DM, Supe PM, Espin SO, Cando CT, Córdova MV. Gradenigo syndrome about a clinical case. *Venezuelan Archives of Pharmacology and Therapeutics* 2020; v. 39, n. 4, p. 427-429.

Carvalho F, Silva C, Ferreira M, Areias C, Romão J, Miguéis MC, Silva L. Gradenigo syndrome: treatment and sequels. *Portuguese Journal of Otorhinolaryngology and Head and Neck Surgery* 2019; 57(1), 37-40.

Vitale M, Amrit M, Arora R, Lata, J. Gradenigo's syndrome: A common infection with uncommon consequences. *American Journal of Emergency Medicine* 2017; Sep; 35(9):1388. e1-1388.e2.

Dimatos D, Cunha R, Dimatos DC, Bolan RS, Dimatos SC. Rbdomiossarcom causing Gradenigo Syndrome in a 7-year-old child. *Santa Catarina Medical Archives* 2005; v. 34, n. 2.

Souza FS, Chaves MF, Mada MS, Ladeia IA, Mendes TS, Rivelli AM. Gradenigo syndrome associated with recurrent otitis and sigmoid sinus thrombosis: case report. *Brazilian Journal of Health Review* 2020; v. 3, n. 6, p. 17601-17607.

Felix F, Olivaes MCD, Gismondi RAOC, Belmont H, Felix JAP. Conservative treatment of Gradenigo syndrome. *Brazilian Journal of Otorhinolaryngology* 2003; v. 69, n.2, p. 256-259.

González-Barrón JA, Guerra-Gómez CA. Gradenigo syndrome, a rare complication in adults: a case report. *Mexican Journal of Family Medicine* 2021; v. 8, p. 97-101.

Kantas I, Papadopoulou A, Balatsouras DG, Aspris A, Marangos N. Therapeutic approach to Gradenigo's syndrome: a case report. *Journal of Medical Case Reports* 2010; n.4, p. 151.

Methol G, García L, Giachetto G. Gradenigo's syndrome: an infrequent complication of acute otitis media. *Archives of Pediatrics of Uruguay* 2016; v. 87, n. 1, p. 44-48.

Pelegrín-Hernández JP, Díaz-Manzano JA, Menasalvas-Ruiz AI, Hellín-Meseguer D. Gradenigo syndrome and cavernous sine thrombosis secondary to acute otitis media. *Journal of the Otorhinolaryngological Society of Castilla and León, Cantabria and La Rioja* 2012; 3 (10): 99-106.

Suzich KL, Adelson S, Choi CS. An Interesting Case of Gradenigo Syndrome. *Journal of Binocular Vision and Ocular Motility* 2019; v. 69, n. 1, p. 1-2.