

A retrospective study of canine cutaneous mast cell tumor: correlation between clinical, histological and molecular characteristics

Um estudo retrospectivo de mastócitos cutâneos caninos: correlação entre características clínicas, histológicas e moleculares

DOI:10.34117/bjdv6n12-501

Recebimento dos originais:15/11/2020

Aceitação para publicação:20/12/2020

Ingrid Mayara Sales Cavalcante

Mestrado (MSc), Pós graduação em Oncologia Veterinária

Instituição de atuação atual: Faculdade de Ciências Farmacêuticas, Universidade Estadual de Campinas (UNICAMP), Campinas, SP, Brazil; OncoVida Centro de Oncologia Veterinária
Endereço :Rua Cândido Portinari, 200 - Cidade Universitária, Campinas - SP, 13083-871

E-mail: cavalcantemedvet@gmail.com

Fernanda Cristina Leme Bernardes

Pós graduação em oncologia - Unesp Jaboticabal

Instituição de atuação atual: OncoVida Centro de Oncologia Veterinária
Endereço: Rua Coronel Manuel Moraes, 158, Jardim Brasil- Campinas SP, 13073-022

E-mail: fernandaveterinariaonco@gmail.com

Bruna Silva Freire

Graduação em Medicina Veterinária

Instituição de atuação atual: OncoVida Centro de Oncologia Veterinária
Endereço: Rua Coronel Manuel Moraes, 158, Jardim Brasil- Campinas SP, 13073-022

E-mail: soaresb632@gmail.com

Rafael Cuconati

Médico veterinário especializado pelo Instituto Bioethicus

Instituição de atuação atual: OncoVida Centro de Oncologia Veterinária
Endereço: Rua Coronel Manuel Moraes, 158, Jardim Brasil- Campinas SP, 13073-022

E-mail: rafaelcuconati@gmail.com

Jaqueline Munhoz

Graduação em Farmácia

Instituição de atuação atual: Faculdade de Ciências Farmacêuticas, Universidade Estadual de Campinas (UNICAMP), Campinas, SP, Brasil

Endereço: Rua Cândido Portinari, 200 - Cidade Universitária, Campinas - SP, 13083-871

E-mail: jlima.munhoz@gmail.com

Catarina Rapôso

Pós doutorado (PhD)

Instituição de atuação atual: Faculdade de Ciências Farmacêuticas, Universidade Estadual de Campinas (UNICAMP), Campinas, SP, Brazil

Endereço: Rua Cândido Portinari, 200 - Cidade Universitária, Campinas - SP, 13083-871

E-mail: raposo@g.unicamp.br

ABSTRACT

Mast cell tumor (MCT), or mastocytoma, the second most common skin tumor in dogs, is characterized by neoplastic transformations and abnormal proliferation of mast cells from cutaneous or visceral origins. Mutations in the proto-oncogene *c-kit* are present in 15% of dogs with MCT and up to 35% in high-grade tumors. In the clinical management of the disease, some characteristics, such as anatomical occurrence, histological grading, clinical staging, age and breed, are important parameters to better drive the treatment and predict the prognosis of each patient. However, it is not clear the correlations between *c-kit* mutation and clinical/epidemiological data, demonstrating the necessity of new studies. In this study, 78 clinical cases of canine patients with MCT were analyzed in Campinas - SP, Brazil, at Oncovida - Veterinary Oncology Center, in the period of 2017 to 2019, to determine the frequency, prevalence and correlations between molecular, clinical and epidemiological aspects. Results presented here shows that mixed breed dogs (51%) were the most affected, followed by Labrador (17%) and Boxer (16%). Most dogs were female (67%), aged 6 to 10 years (62%); 42% of the animals had tumors located in the pelvic limb and 17% had nodules in the chest. The most used method for diagnosis was histopathology, totalizing 60% of cases, followed by aspirative cytology (26%) and immunohistochemistry (8%). Regarding histological variables, 3 patients had grade I (11.8%), 47 had grade II (61%) and 15 had grade III (19%) and, according to KIUPEL et al. (2011) classification, 77 % of the cases presented low grade and 23% were high grade. The survival of these patients was also analyzed, demonstrating that animals presenting grade I and grade II (low grade) had longer survival (68%) in relation to grade III (high grade) (16%) The variables showed a significant correlation between histological grade and *c-kit* mutation with breed, age, localization of the tumor, diagnostic, chosen treatment and survival, indicating that they are both decisive to the outcome of the disease. Only sex was not correlated, suggesting that both the grade of the tumor and the *c-kit* mutation were not found to contribute to a different development of the tumor in male or female. These results demonstrate important data on the clinical behavior of MCT in the region of Campinas-SP, presenting relevant knowledge that can be used in the future in the clinical manage of the patients with this disease and demonstrating the necessity of further studies on the epidemiology of MCT in each region of Brazil.

Keywords: Mastocytoma, dogs; survival, histological grade, *c-kit*; correlation, prognosis.

RESUMO

O tumor de mastócitos (MCT), ou mastocitoma, o segundo tumor de pele mais comum em cães, é caracterizado por transformações neoplásicas e proliferação anormal de mastócitos de origem cutânea ou visceral. As mutações no kit proto-oncogene *c-* estão presentes em 15% dos cães com MCT e até 35% em tumores de alta qualidade. Na gestão clínica da doença, algumas características, tais como ocorrência anatômica, classificação histológica, estadiamento clínico, idade e raça, são parâmetros importantes para melhor conduzir o tratamento e prever o prognóstico de cada paciente. Contudo, não é clara a correlação entre a mutação *c-kit* e os dados clínicos/epidemiológicos, demonstrando a

necessidade de novos estudos. Neste estudo, 78 casos clínicos de pacientes caninos com MCT foram analisados em Campinas - SP, Brasil, no Oncovida - Centro de Oncologia Veterinária, no período de 2017 a 2019, para determinar a frequência, prevalência e correlações entre os aspectos moleculares, clínicos e epidemiológicos. Os resultados aqui apresentados mostram que os cães de raça mista (51%) foram os mais afetados, seguidos por Labrador (17%) e Boxer (16%). A maioria dos cães eram fêmeas (67%), com idades entre 6 a 10 anos (62%); 42% dos animais tinham tumores localizados no membro pélvico e 17% tinham nódulos no peito. O método mais utilizado para o diagnóstico foi a histopatologia, totalizando 60% dos casos, seguido pela citologia aspirativa (26%) e imunohistoquímica (8%). Relativamente às variáveis histológicas, 3 pacientes tinham grau I (11,8%), 47 tinham grau II (61%) e 15 tinham grau III (19%) e, segundo a classificação de KIUPEL et al. (2011), 77% dos casos apresentavam grau baixo e 23% tinham grau alto. A sobrevivência destes pacientes foi também analisada, demonstrando que os animais que apresentavam grau I e grau II (grau baixo) tinham uma sobrevivência mais longa (68%) em relação ao grau III (grau alto) (16%). As variáveis mostraram uma correlação significativa entre o grau histológico e a mutação c-kit com a raça, idade, localização do tumor, diagnóstico, tratamento escolhido e sobrevivência, indicando que ambos são decisivos para o resultado da doença. Apenas o sexo não foi correlacionado, sugerindo que tanto o grau do tumor como a mutação c-kit não contribuíram para um desenvolvimento diferente do tumor em macho ou fêmea. Estes resultados demonstram dados importantes sobre o comportamento clínico do MCT na região de Campinas-SP, apresentando conhecimentos relevantes que podem ser utilizados no futuro na gestão clínica dos pacientes com esta doença e demonstrando a necessidade de mais estudos sobre a epidemiologia do MCT em cada região do Brasil.

Palavras-chave: Mastocitoma, cães, sobrevivência, grau histológico, c-kit, correlação, prognóstico.

1 INTRODUCTION

Mast cell tumor (MCT), or mastocytoma, is the second most common skin neoplasms diagnosed in dogs (*Canis lupus familiaris*) (DALECK et al., 2008; WITHROW et al, 2012). This tumor is characterized by neoplastic transformations and abnormal proliferation of mast cells and may be of cutaneous or visceral origins (KRAEGEL & MADEWELL et al, 2000). Belonging to the group of neoplasms known as round cell tumors, this neoplasm has also been reported in humans (ORKIM & SCHWARTZMAN, 1959) and in many domestic species, among which canines and felines show the greater prevalence.

The incidence of MCT is higher in elderly dogs, with an average age of 9 years, however the disease can occur in young animals. This neoplasm can affect both mixed breed dogs (MBD) and defined breed dogs, such as: Boxer, Golden Retriever, Labrador, Boston Terrier, Cocker Spaniel, Shnauzer, Beagle, Sharpei, among other breeds (PETERS, 1969; GOLDSCHMIDT & SHOFER, 1992). The incidence by sex in canines has not yet been reported, however, in cats the incidence is higher in males (DALECK et al., 2008). Also, prognosis is variable, as MCTs can exhibit various biological behaviors, from benign to extremely aggressive, leading to metastasis and, eventually, death.

Canine prognosis and treatment options are affected by patient clinical signs, tumor anatomical location, growth rate, size, gross appearance (e.g. ulceration), metastasis, post-surgical recurrence, clinical stage and tumor histological grade (BLACKWOOD et al., 2012; MULLINS et al., 2006).

One of the most important prognostic factors is the histological grade of the neoplasm. Total surgical removal of grade I tumor (well differentiated) usually promotes healing, whereas dogs with grade III tumor (poorly differentiated) often become complicated due to recurrences or metastasis in a few months. The location of the neoplasm is also important in predicting the prognosis: tumors in the inguinal and perineal region, in the snout and in the oral and nasal cavities usually cause metastasis (KIUPEL et al, 2005; DALECK & DENARDI, 2016).

Clinical management and prediction of prognosis (metastasis prediction, for example), is assisted by molecular diagnosis (BLACKLOCK et al., 2018). The proto-oncogene c-kit plays a critical role in the development of MCTs. Mutations in the c-kit gene are present in 15% of dogs with MCT and up to 35% in high-grade tumors (THAMM et al., 2019; MARCONATO et al., 2014). It is not clear, however, whether the correlation between the c-kit mutation and the prognosis is an independent factor or whether it is correlated with the histological grade, which is a less expensive method compared to detecting the c-kit mutant by PCR (polymerase chain reaction). However, the c-kit mutation is a more objective measure than histological classification, representing a more accurate and method of diagnosis (THAMM et al., 2019).

Therefore, due to the large casuistry of dogs with cancer, with MCT being the highest prevalence, it is important to know the factors that influence the prognosis, such as clinical manifestations, histological grading and molecular profile, to establish a better therapeutic approach individually. Although there are some studies in this context, Brazil is a country with a large territorial extension and, consequently, with a diverse epidemiological condition, which results in a lack of studies that represent the reality of each region (MACHADO et al., 2018). The present study aimed to evaluate the cases of MCTs treated at Oncovida - Center for Veterinary Oncology of Campinas / SP, Brazil, in the period from 2017 to 2019, evaluating the incidence of this neoplasm and correlating the cases with: race, sex, age, anatomic region, methods used for diagnostic, histological grade, molecular profile, and survival.

2 METHODOLOGY

This is an observational retrospective study. A survey of cases of cutaneous mastocytoma in dogs attended at Oncovida - Center for Veterinary Oncology of Campinas, São Paulo, was conducted. The medical records were provided and their use was authorized by the clinic; the digital medical

records covered the patients attended in the period from 2017 to 2019. 78 clinical cases with diagnosis of canine mast cell tumor were found, and data on race, gender, age, affected body region, diagnostic methods, histological variables, molecular profile and their survival from the diagnosis were obtained and correlated. When the patient was discharged and survival was not recorded, tutors were contacted by phone. The period from diagnosis to death or last visit to the clinic was considered for analysis.

The methods used for diagnosis were fine-needle aspiration cytology (FNAC), histopathology (HP) and for detection of KIT mutation (9 clinical cases), immunohistochemistry (IHC) (8 patients); PCR c-kit detection (3 patients) or both IHC and PCR (2 patients) were performed. Regarding the histological classification, the description of Patnaik et al. (1984) in grade I, II and III, and the more recent classification of Kiupel et al. (2011), which divides the tumors into high and low grade, were followed.

Patients with unfilled medical records and/or incomplete data were excluded from this study. Data were expressed in absolute values or percentage and demonstrated using graphs and tables. For statistical analysis, the data for each variable were grouped into categories and described in terms of absolute and relative frequency. To study the association between variables, the Chi-square test was applied. The level of significance was 5% ($p < 0.05$) and the software used was GraphPad Prism (version 2.0). The significance is represented by $p < 0,0001$ ****, $p < 0,001$ ***, $p < 0,01$ **, $p < 0,05$ *

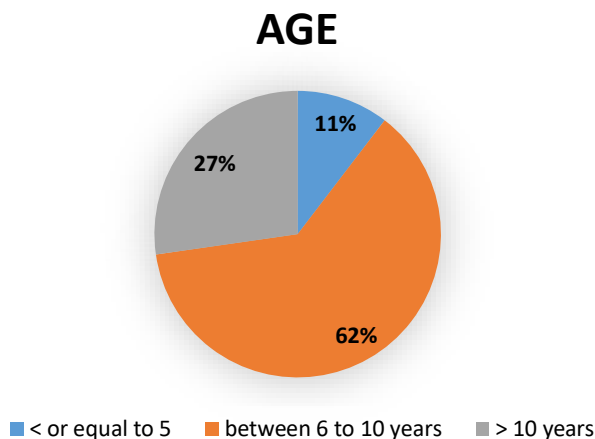
3 RESULTS

As showed in the Table 1, it was observed that MBD (mixed breed dogs) (n = 25, 51%) was the most affected breed, followed by Labrador (n = 8, 17%), Boxer (n = 8, 16%), Golden (12%) and Pinscher (4%). Most dogs were female (n = 52, 67%), against 33% (n =26) of male (Table 1), and the greater prevalence was in dogs aged 6 to 10 years (n = 48, 62%), followed by dogs older than 10 years (n = 21, 27%), and a minority was under 5 years old (n = 8, 11%), as showed in the Figure 1.

Table 1. Prevalence of cutaneous mast cell tumors by breed and sex, in dogs treated at Oncovida, from 2017 to 2019.

Variable		N	%
Breed	MBD	25	51%
	Labrador	8	17%
	Boxer	8	16%
	Golden	6	12%
	Pinscher	2	4%
Sex	Female	52	67%
	Male	26	33%

Figure 1. Prevalence of cutaneous mast cell tumors by age, in dogs treated at Oncovida, from 2017 to 2019.



Regarding the anatomic localization, 20 patients (42%) had tumors located in the pelvic limb and 8 (17%) had nodules in the chest; areas with minor commitment were perianal region (8%), abdomen, flank, mouth, mammary region (all together with 8% of prevalence) and inguinal region (4%), as demonstrated in Figure 2. Concerning the diagnostic method, 63 (60%) cases used histopathology, 27 (26%) were diagnosed by FNAC (combined or not with histopathology), immunohistochemistry was used in 8 cases (8%), and 6 tumors (6%) were diagnosed by c-kit (Figure 3). Table 2 shows the histological variables, which were classified as grade I (n = 3, 4%), grade II (n = 47, 61%) and grade III (n = 15, 19%) according to Patnaik et al. (1984); and following the classification of Kiupel et al. (2011), 50 cases (77%) were classified as low grade and 15 tumors (23%) as high grade. 12 cases were classified as “suggestive” since they were submitted only to FNAC.

Figure 2. Anatomic localization of cutaneous mast cell tumor treated at Oncovida, from 2017 to 2019.

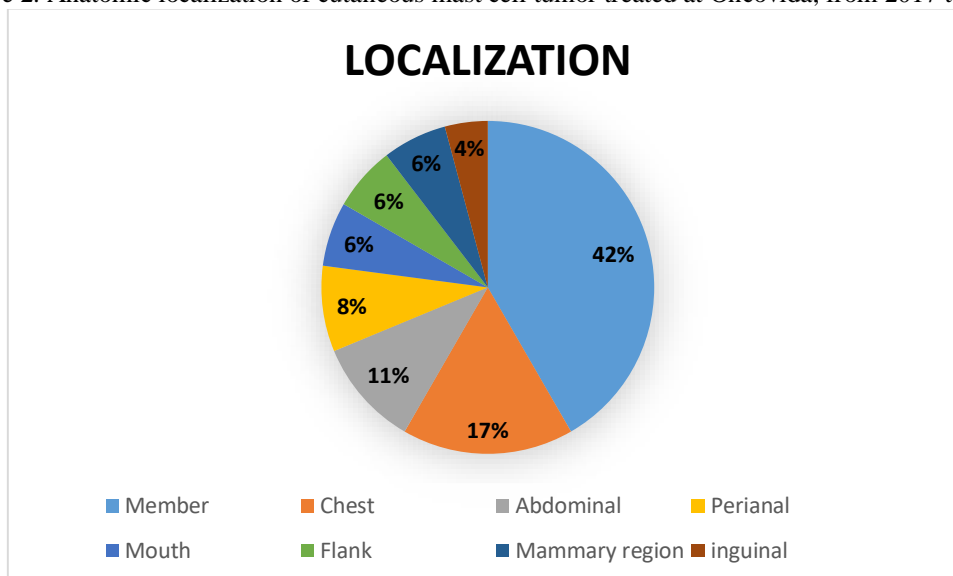


Figure 3. Methods used for diagnosis of cutaneous mast cell tumor in dogs treated at Oncovida, from 2017 to 2019.

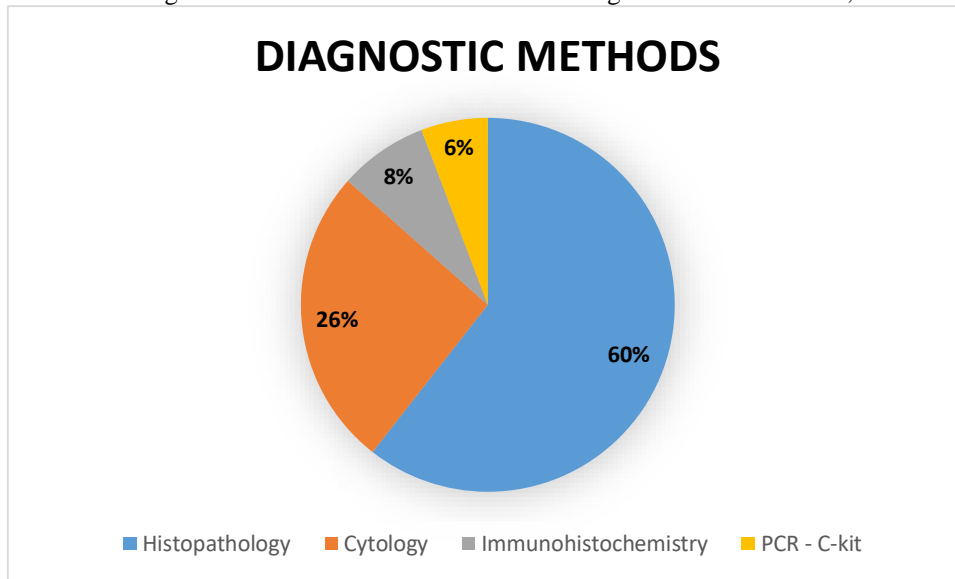


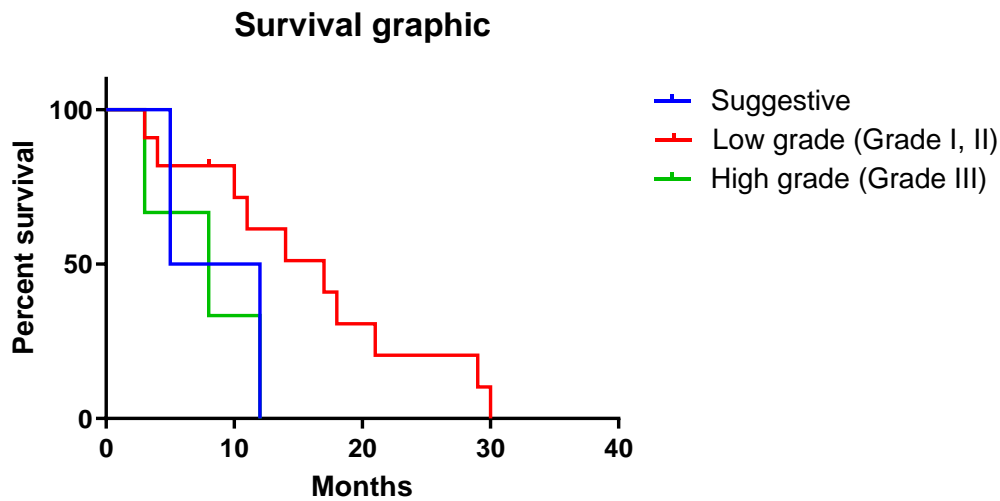
Table 2. Distribution of histological variables and methods used for diagnosis in absolute (n) and relative (%) numbers of dogs with cutaneous mast cell tumor treated at Clínica Veterinária Oncovida, from 2017 to 2019.

Variable		N	%
Histopathological grade according to Patnaik et al, 1984	I	3	4
	II	47	61%
	III	15	19%
Histopathological grade according to Kiupel et al, 2011	Low	15	23%
	High	50	77%
**Suggestive		12	16%

** Suggestive: Patients submitted to cytology only.

Figure 4 shows the graphic of survival in months depending on the histological classification. Is possible to note that the mean of survival for animals with low grade tumors are almost three times higher compared to animals with high grade tumors.

Figure 4. Graphic of survival, showing percentage of surviving dogs by months. The classifications: suggestive (patients submitted to FNAC only), low grade and high grade (histological classification) are demonstrated. Low grade has almost three times higher survival comparing with the other two classifications.



The Table 3 shows the correlation between different variables with histological grade, following the Patnaik et al. (1984) classification. The variables, breed, age, location, survival and diagnostic, were significantly correlated with histological grade. There was no significant correlation between sex (0,8780) and histological grade. Chi-square test was not applicable for the variables c-kit and treatment, since the cases could not be histologically classified in grade I or grade II using Patnaik criteria.

Table 3. Distribution of epidemiological and clinical variables in absolute (n) and relative (%) number of dogs with cutaneous mast cell tumor and treated at Oncovida, Campinas - SP, from 2017 to 2019, depending on Patnaik et al. (1984) classification (Chi-square test).

		Patnaik et al. 1984						Total		P value
		Grade I		Grade II		Grade III				
		n	%	n	%	n	%			
Breed	Basset	0	0	1	100	0	0	1	100	<0,0001****
	Boxer	0	0	6	100	0	0	6	100	
	Bulldog	0	0	1	100	0	0	1	100	
	French Bulldog	1	50	1	50	0	0	2	100	
	English Bulldog	0	0	1	100	0	0	1	100	
	Cocker	1	100	0	0	0	0	1	100	
	Dachshund	1	33	1	33	1	33	3	100	
	Dalmatian	0	0	1	100	0	0	1	100	
	Fox Paulistinha	0	0	1	100	0	0	1	100	
	Golden Retriever	0	0	4	80	1	20	5	100	
	Labrador	1	14	3	43	3	43	7	100	

	German Shepherd	0	0	0	0	1	100	1	100	
	Pastor Shetland	0	0	1	100	0	0	1	100	
	Pinscher	0	0	0	0	1	100	1	100	
	Pit bull	0	0	1	50	1	50	2	100	
	Pointer	0	0	0	0	1	100	1	100	
	Poodle	0	0	1	100	0	0	1	100	
	Pug	0	0	2	100	0	0	2	100	
	Shih-tzu	0	0	1	100	0	0	1	100	
	MBD	0	0	15	71	6	29	21	100	
	Yorkshire	0	0	2	100	0	0	2	100	
Sex	Female	2	5	30	71	10	24	42	100	0,8780
	Male	1	4	17	74	5	22	23	100	
Age (year)	1-5	0	0	5	100	0	0	5	100	<0,0001****
	6-10	1	2	30	73	10	24	41	100	
	10 -17	2	17	5	42	5	42	12	100	
Location	Abdominal	0	0	3	100	0	0	3	100	<0,0001****
	Axillary	0	0	1	50	1	50	2	100	
	Mouth	0	0	2	67	1	33	3	100	
	Breast Chain	0	0	2	67	1	33	3	100	
	Cervical	0	0	1	50	1	50	2	100	
	Digit	0	0	1	100	0	0	1	100	
	Back	1	100	0	0	0	0	1	100	
	Flank	0	0	2	100	0	0	2	100	
	Pre-scapular lymph node	0	0	1	100	0	0	1	100	
	Member	0	0	15	79	4	21	19	100	
	Ear	0	0	2	100	0	0	2	100	
	Perianal	0	0	0	0	2	100	2	100	
	Nasal sinus	0	0	1	100	0	0	1	100	
Testicle	0	0	0	0	2	100	2	100		
Chest	0	0	5	83	1	17	6	100		
Survival (month)	1-4	0	0	4	36	7	64	11	100	<0,0001****
	5-10	0	0	8	80	2	20	10	100	
	11-20	1	6	15	88	1	6	17	100	
	21-30	1	10	9	90	0	0	10	100	
Diagnostic	FNAC	0	0	7	58	5	42	12	100	<0,0001****
	HP	3	5	45	74	13	21	61	100	
	IH	0	0	7	88	1	13	8	100	
	PCR c-kit	0	0	8	89	1	11	9	100	

C = Chemoterapy, D = Diet, R = Radiotherapy, S = Surgery; FNAC = Fine-needle aspiration cytology, HP = Histopathology, IH = Immunohistochemistry; ****Chi-square test, p<0,0001.

Correlations of histological grade (Kiupel et al., 2011) with clinical and epidemiological variables were done using Chi-square test. As showed in Table 4, the variables breed, age, location, survival, c-kit mutation and treatments ($p < 0,0001$ ****) were significantly correlated with histological classification. On the other hand, sex (0,7368) and diagnostic (0,1281) were not significantly correlated (Table 4).

Table 4. Distribution of epidemiological and clinical variables in absolute (n) and relative (%) number of dogs with cutaneous mast cell tumor and treated at Oncovida, Campinas - SP, from 2017 to 2019, depending on Kiupel et al. (2011) classification (Chi-square test).

		Kiupel et al. 2011						P value		
		Low Grade		Hight Grade		Total				
		n	%	n	%	n	%			
Breed	Basset	1	100	0	0	1	100	<0,0001****		
	Boxer	6	100	0	0	6	100			
	Bulldog	1	100	0	0	1	100			
	French Bulldog	2	100	0	0	2	100			
	English Bulldog	1	100	0	0	1	100			
	Cocker	1	100	0	0	1	100			
	Dachshund	2	67	1	33	3	100			
	Dalmatian	1	100	0	0	1	100			
	Fox Paulistinha	1	100	0	0	1	100			
	Golden Retriever	4	80	1	20	5	100			
	Labrador	4	57	3	43	7	100			
	German Shepherd	0	0	1	100	1	100			
	Pastor Shetland	1	100	0	0	1	100			
	Pinscher	0	0	1	100	1	100			
	Pit bull	1	50	1	50	2	100			
	Pointer	0	0	1	100	1	100			
	Poodle	1	100	0	0	1	100			
	Pug	2	100	0	0	2	100			
	Shih-tzu	1	100	0	0	1	100			
	MBD	15	71	6	29	21	100			
	Yorkshire	2	100	0	0	2	100			
	Sex	Female	32	76	10	24	42		100	0,7368
		Male	18	78	5	22	23		100	
	Age (year)	1-5	5	100	0	0	5		100	<0,0001****
		6-10	31	76	10	24	41		100	
		10 -17	7	58	5	42	12		100	

Location	Abdominal	3	100	0	0	3	100	<0,0001****
	Axillary	1	50	1	50	2	100	
	Mouth	2	67	1	33	3	100	
	Mammary region	2	67	1	33	3	100	
	Cervical	1	50	1	50	2	100	
	Digit	1	100	0	0	1	100	
	Back	1	100	0	0	1	100	
	Flank	2	100	0	0	2	100	
	Pre-scapular lymph node	1	100	0	0	1	100	
	Member	15	79	4	21	19	100	
	Ear	2	100	0	0	2	100	
	Perianal	0	0	2	100	2	100	
	Nasal sinus	1	100	0	0	1	100	
	Testicle	0	0	2	100	2	100	
	Chest	5	83	1	17	6	100	
Survival (months)	1-4	4	36	7	64	11	100	<0,0001****
	5-10	8	80	2	20	10	100	
	11-20	16	94	1	6	17	100	
	21-30	10	100	0	0	10	100	
Diagnostic	FNAC	48	79	13	21	61	100	0,1281
	HP	7	88	1	13	8	100	
	IH	8	89	1	11	9	100	
	PCR c-kit	8	89	1	11	9	100	
c-kit mutation	KIT 1	7	100	0	0	7	100	<0,0001****
	KIT 2	1	50	1	50	2	100	
Treatment	D	2	100	0	0	2	100	<0,0001****
	C	5	83	1	17	6	100	
	R	1	100	0	0	1	100	
	S	9	90	1	10	10	100	
	D + S	1	100	0	0	1	100	
	C + S	9	82	2	18	11	100	
	R + S	1	100	0	0	1	100	
	C + R + S	5	83	1	17	6	100	

C = Chemoterapy, D = Diet, R = Radiotherapy, S = Surgery; FNAC = Fine-needle aspiration cytology, HP = Histopathology, IH = Immunohistochemistry; ****Chi-square test, p<0,0001.

In addition to histological grade correlations, the analysis by Chi-square test showed that breed, age, location, treatment and diagnostic were significantly correlated with survival. However, sex was not correlated (p<0,0595), following the same standard as for the other correlations.

Table 5. Distribution of epidemiologic and clinical variables in absolute (n) and relative (%) number of dogs with cutaneous mast cell tumor and treated at Oncovida, Campinas - SP, from 2017 to 2019, depending on survival (Chi-square test).

		SURVIVAL										P Value
		1-4		5-10		11-20		21-30		Total		
		n	%	n	%	n	%	n	%	n	%	
Breed	Basset	1	100	0	0	0	0	0	0	1	100	<0,0001****
	Boxer	0	0	0	0	2	50	2	50	4	100	
	Bulldog	0	0	1	100	0	0	0	0	1	100	
	French Bulldog	0	0	0	0	0	0	1	100	1	100	
	Dachshund	0	0	1	100	0	0	0	0	1	100	
	Dalmatian	0	0	0	0	2	67	1	33	3	100	
	Fox Paulistinha	1	50	0	0	1	50	0	0	2	100	
	Golden retriever	2	40	0	0	3	60	0	0	5	100	
	Labrador	2	29	1	14	3	43	1	14	7	100	
	Pastor Shetland	1	50	0	0	0	0	1	50	2	100	
	Pinscher	0	0	1	100	0	0	0	0	1	100	
	Pit bull	0	0	1	50	0	0	1	50	2	100	
	Pointer	0	0	0	0	1	100	0	0	1	100	
	Poodle	0	0	0	0	1	100	0	0	1	100	
	Pug	0	0	0	0	1	100	0	0	1	100	
	MBD	8	38	6	29	4	19	3	14	21	100	
	Yorkshire	0	0	0	0	2	100	0	0	2	100	
Sex	Female	7	21	8	24	13	38	6	18	34	100	0,0595
	Male	5	31	2	13	5	31	4	25	16	100	
Age (Years)	1-5	0	0	1	20	0	0	4	80	5	100	<0,0001****
	6-10	11	32	6	18	14	41	3	9	34	100	
	10 -17	0	0	4	33	6	50	2	17	12	100	
Location	Abdominal	0	0	1	25	3	75	0	0	4	100	<0,0001****
	Axillary	1	50	1	50	0	0	0	0	2	100	
	Mouth	1	33	1	33	1	33	0	0	3	100	
	Mamaria region	1	100	0	0	0	0	0	0	1	100	
	Cervical	0	0	0	0	1	100	0	0	1	100	
	Digit	0	0	0	0	1	100	0	0	1	100	
	Back	0	0	0	0	2	67	1	33	3	100	
	Flank	0	0	0	0	1	50	1	50	2	100	
	lymph node	2	67	0	0	1	33	0	0	3	100	
	Member	3	21	4	29	3	21	4	29	14	100	
	Ear	0	0	1	100	0	0	0	0	1	100	
	Perianal	0	0	1	100	0	0	0	0	1	100	
	nasal sinus	1	100	0	0	0	0	0	0	1	100	
	Testicle	1	100	0	0	0	0	0	0	1	100	
	Chest	2	25	0	0	5	63	1	13	8	100	
Treatment	D	0	0	0	0	1	50	1	50	2	100	<0,0001****

	C	1	33	1	33	1	33	0	0	3	100	
	R	0	0	0	0	1	100	0	0	1	100	
	S	1	25	0	0	2	50	1	25	4	100	
	D+ S	0	0	0	0	0	0	1	100	1	100	
	C + S	4	36	2	18	4	36	1	9	11	100	
	R+ S	0	0	1	100	0	0	0	0	1	100	
	C + R + S	0	0	1	50	0	0	1	50	2	100	
Diagnostic Method	FNAC	10	50	4	20	5	25	1	5	20	100	<0,0001****
	HP	9	19	11	23	18	38	9	19	47	100	
	IH	0	0	2	29	3	43	2	29	7	100	
	PCR c-kit	0	0	2	25	4	50	2	25	8	100	

C = Chemoterapy, D = Diet, R = Radiotherapy, S = Surgery; FNAC = Fine-needle aspiration cytology, HP = Histopathology, IH = Immunohistochemistry; ****Chi-square test, p<0,0001.

The last correlation analyzed was the c-kit mutation with the other parameters. Considering all the clinical cases (n = 78), only 9 animals were diagnosed by PCR for the c-kit mutation. The Table 6 shows the statistical analysis of different variables in these cases. All the correlations were significant by Chi-square test, except sex, keeping the same pattern observed for the other correlations.

Table 6. Distribution of epidemiologic and clinical variables in absolute (n) and relative (n) number of dogs with cutaneous mast cell tumor and treated at Oncovida, Campinas - SP, from 2017 to 2019, depending on detection of KIT mutation (Chi-square test).

		c-kit Mutation						P Value
		KIT 1		KIT 2		Total		
		n	%	n	%	N	%	
Breed	Boxer	1	100	0	0	1	100	<0,0001*** *
	Golden retriever	1	100	0	0	1	100	
	Labrador	0	0	2	100	2	100	
	Pastor Shetland	1	100	0	0	1	100	
	Poodle	1	100	0	0	1	100	
	MBD	3	100	0	0	3	100	
Sex	Female	4	80	1	20	5	100	0,3972
	Male	3	75	1	25	4	100	
Age (Years)	1-5	0	0	1	100	1	100	<0,0001*** *
	6-10	4	100	0	0	4	100	
	10 -17	3	75	1	25	4	100	
Location	Mouth	1	100	0	0	1	100	<0,0001*** *
	Pre-scapular lymph node	1	100	0	0	1	100	
	Member	1	50	1	50	2	100	
	Ear	2	100	0	0	2	100	

	Chest	0	0	1	100	1	100	
Treatment	S	2	100	0	0	2	100	<0,0001*** *
	C + S	2	67	1	33	3	100	
	D	1	100	0	0	1	100	
	R+ S	1	100	0	0	1	100	
	C + R + S	0	0	1	100	1	100	
Survival (months)	5-10	1	50	1	50	2	100	<0,0001*** *
	11-20	3	75	1	25	4	100	
	21-30	2	100	0	0	2	100	
Diagnostic Method	FNAC	3	100	0	0	3	100	<0,0001*** *
	HP	7	78	2	22	9	100	
	IHC	5	71	2	29	7	100	
Kiupel et al. (2011)	low	7	100	0	0	7	100	<0,0001*** *
	high	1	50	1	50	2	100	

C = Chemoterapy, D = Diet, R = Radiotherapy, S = Surgery; FNAC = Fine-needle aspiration cytology, HP = Histopathology, IH = Immunohistochemistry; ****Chi-square test, p<0,0001.

4 DISCUSSION

Mastocytomas are frequently diagnosed in dogs and some characteristics, such as anatomical occurrence, histological grading, clinical staging, age and breed, are important prognostic parameters and determinants to choosing the best therapy (SLEDGE et al, 2016). Therefore, understanding and correlating these characteristics of the tumor is a fundamental issue to better drive the treatment and predict the prognosis of each patient. In this study, 78 clinical cases of canine patients with MCT were analyzed in Campinas - SP, Brazil, at Oncovida - Veterinary Oncology Center, to determine the frequency, prevalence and correlations of clinical and epidemiological aspects.

Comparing the results with the literature, in general, the data can be variable depending on some particularities of each region. Concerning breed, the present study found that MBD was the most affected, followed by Labrador, Boxer, Golden and Pinscher. In relation to prevalence, the tumor was more frequent in females than in males, as also reported by Souza et al., 2018; in contrast to studies from Brazil (COSTA-CASAGRANDE et al., 2008; MACHADO et al., 2018) and Europe (MILLER et al, 2014; ŠMIECH et al. 2017; LEIDINGER et al., 2014) whose reported that there is no gender predisposition in these regions. The data showed that MCT affect more dogs aged between 6 and 10 years, followed by those older than 10 years, and a minority was less than 5 years old. In agreement with the present results, studies from Brazil (COSTA-CASAGRANDE et al., 2008; SOUZA et al, 2018) and Europe (MILLER et al, 2014; ŠMIECH et al. 2017; LEIDINGER et al., 2014) have also

found a predisposition for similar age range, and Boxer and Labrador among the most predisposed breeds. Interesting, MDB was reported as the most affected breed by Souza et al. (2018) in Jaboticabal (Brazil), but the same proportion was not observed by Costa-Casagrande et al. (2008) in São Paulo (Brazil), cities localized in the same country and state. These data demonstrate that even in close regions it is possible to observed different epidemiologic profiles of the same disease, and consequently, the importance to collect information and generate studies about each region.

The present data showed that the most frequent location of this neoplasia was in the pelvic limb, followed by chest and abdominal region. The most used diagnostic method was HP (60% of cases), followed by FNAC (26%). A minority of cases were diagnosed by IHC (8%) and PCR - cKIT (6%). These data corroborate with Souza et al. (2018), who showed similar anatomic prevalence and HP and FNAC as the main methods of diagnostic in Jaboticabal (Brazil), a city very close Campinas, the region studied in the present work. Although FNAC is a relatively simple, inexpensive test and an excellent form of diagnosis, it should never be used as the only method of tumor analysis (ELMSLIE, 2003). HP is essential because it allows to analyze the classification of the tumor grade and to evaluate the tumor behavior and prognosis, which, together, will assist the clinician in choosing the best therapeutic approach, increasing survival (LONDON et al., 1999). FNAC is a form of preoperative screening and helps with surgical planning and the definition of the surgical margins. This test is normally used in 92 to 96% of cases (LONDON et al., 1999, BAKER-GABBY et al., 2003), what was not observed in the cases raised here. In the present study, histological analysis showed that the minority of patients had grade I (11.6%), most were classified as grade II (61%) and grade III (19%). Using the Kiupel et al. (2011), 77% of the cases were low-grade and 23% were high-grade. The survival of these patients was also analyzed, demonstrating that animals presenting grade I and grade II (low grade) had longer survival (68%) in relation to grade III (high grade) (16%), what is expected.

The analysis of correlations by Chi-square test showed that most of the parameters were statistically significant. The histopathological correlation of grades in the two different classifications demonstrated that only sex in both classifications was not correlated. However, the Patnaik et al. 1984 presented some limitations in the comparison. In general, MCTs classified as grade I were observed just in some few cases and, consequently, the parameters diagnostic and treatment were not possible to be evaluated by statistical analyses. Furthermore, the Kiupel et al. 2011 classification indicated that also diagnostic was not correlated with the histopathological grade ($p < 0,1281$). These results corroborate with the literature on the relevance of histopathological classification, since the grade of

the tumor seems to be decisive for important outcomes and epidemiological aspects, such as age, breed, anatomical location, chosen treatment and survival.

Correlations on survival were also statistically significant. Only sex was not correlated with this parameter. These data suggest that the survival of the patients was directly associated with age, breed, localization of the tumor, treatment and diagnostic. Even though represent valuable information about the epidemiology of the disease, these data cannot be interpreted as simple and isolated parameters of just two variables. In general, these factors are presented simultaneously in the same animal. Furthermore, each aspect has intrinsic variations not considered here, for example, most of MCT are found in the dermis and subcutaneous tissue and have a variable behavior and clinical manifestation, from simple lesions to aggressive systemic disease (STREFEZZI et al., 2009). Then, all of these analyzed factors have a complex influence on the clinical outcome of the patient and, consequently, on survival.

The correlations with c-kit mutations showed a similar profile of the other variables analyzed. The sex was not correlated, while all other analyzed parameters were correlated with the mutation. The performance of immunohistochemistry and PCR for c-kit aims to identify the expression of prognostic factors. Mutations in the c-kit proto-oncogene tyrosine kinase receptor are common molecular abnormalities involved in mast cell tumorigenesis and are associated with more malignant and lethal diseases. (LENNARTSSON & RONNSTRAND, 2012). The frequency of use of this method in clinical manage is low compared with the other methods of diagnostic (only 9 animals of the 78 analyzed). This reflects the higher cost of this diagnostic (PCR or IHC) when compared do cytology and histopathology. The significant correlation between the detection of c-kit mutation and survival shows that this method can directly predict the life expectancy of patients, representing important information that can be used to predict prognosis and guide the best approach by the clinician.

5 CONCLUSION

This study describes the clinical prevalence of mast cell tumor and the statistical correlations of the analyzed parameters, in dogs at Oncovida - Center for Veterinary Oncology of Campinas / SP, Brazil. The variables showed a significant correlation between histological grade and c-kit mutation with breed, age, localization of the tumor, diagnostic, presence of c-kit mutation, chosen treatment and survival, indicating that they are both decisive to the outcome of the disease. Only sex was not correlated, suggesting that both the grade of the tumor and the c-kit mutation were not found to contribute to a different development of the tumor in male or female. The results represent important information on the clinical behavior of MCT in the region of Campinas-SP, presenting relevant

knowledge that can be used in the future in the clinical manage of the patients with this disease. Some limitations of the study, such as the low number of cases in the c-kit mutation diagnostic, need to be consider and explored in further studies on MCT.

REFERENCES

- BAKER-GABBY, M.; et al. Soft tissue sarcomas and mast cell tumours in dogs; clinical behaviour and response to surgery. *Australian veterinary journal*, v. 81, n. 12, p. 732-738, 2003.
- BLACKLOCK, K. et al. Identification of molecular genetic contributants to canine cutaneous mast cell tumour metastasis by global gene expression analysis. *PLoS one*, v. 13, n. 12, p. e0208026, 2018.
- BLACKWOOD, L. et al. European consensus document on mast cell tumours in dogs and cats. *Veterinary and comparative oncology*, v. 10, n. 3, p. e1-e29, 2012.
- COSTA-CASAGRANDE, T.A et al. Retrospective study of canine mastocytoma in the small animal surgery service, Veterinary Hospital of the Faculty of Veterinary Medicine and Animal Science, University of São Paulo. *Arch. VET. SCI.* 13 (3): 176-183, 2008.
- DALECK, C.R.; DENARDI, A.B. *Oncology in Dogs and Cats*. 2nd ed. São Paulo: Roca, 2016.
- DALECK, C.R. et al. *Oncology in Dogs and Cats*. 1st ed. São Paulo: Roca, 2008. P. 11-29.
- ELMSLIE, R.E. *Veterinary Consultation in 5 Minutes: Canine and Feline Species - Mastocytoma*. Manole, Barueri. 2003. p.14-23. In: Tilley L.P. & Smith F.K. (Eds).
- GOLDSCHMIDT, M. H. et al. *Skin tumors of the dog and cat*. Pergamon Press Ltd, 1992.
- KIUPEL, M. et al. Proposal of a 2-tier histologic grading system for canine cutaneous mast cell tumors to more accurately predict biological behavior. *Veterinary pathology*, v. 48, n. 1, p. 147-155, 2011.
- KRAEGEL, A.S & MADEWELL, B.R. Tumors of the skin. In: Ettinger, JS; Feldman, CE. *Textbook of Veterinary Internal Medicine: diseases of the dog and cat*. Philadelphia: WB Saunders, 2000. p. 523-528.
- LEIDINGER, E. F. et al. Breed related odds ratio and anatomic distribution of canine mast cell tumours in Austria. *Tierärztliche Praxis Ausgabe K: Kleintiere/Heimtiere*, v. 42, n. 06, p. 367-373, 2014.
- LENNARTSSON, J. & RÖNNSTRAND, L. Stem cell factor receptor/c-Kit: from basic science to clinical implications. *Physiological reviews*, v. 92, n. 4, p. 1619-1649, 2012.
- LONDON, C. A. et al. Spontaneous canine mast cell tumors express tandem duplications in the proto-oncogene c-kit. *Experimental hematology*, v. 27, n. 4, p. 689-697, 1999.
- MACHADO, G. A. et al. Incidence of skin tumors in dogs in Salvador, Bahia state, Brazil (2007-2016). *Pesquisa Veterinária Brasileira*, v. 38, n. 11, p. 2139-2145, 2018.
- MARCONATO, L. et al. Concordance of c-kit mutational status in matched primary and metastatic cutaneous canine mast cell tumors at baseline. *Journal of veterinary internal medicine*, v. 28, n. 2, p. 547-553, 2014.

MILLER, R. L. et al. A retrospective review of treatment and response of high-risk mast cell tumors in dogs. 2014. article; *Veterinary and comparative Oncology magazine*.

MULLINS, M. N. et al. Evaluation of prognostic factors associated with outcome in dogs with multiple cutaneous mast cell tumors treated with surgery with and without adjuvant treatment: 54 cases (1998–2004). *Journal of the American Veterinary Medical Association*, v. 228, n. 1, p. 91-95, 2006.

ORKIN, M., & SCHWARTZMAN, R. M. A comparative study of canine and human dermatology. Cutaneous tumors: The mast cell and human mastocytoma. *Journal of Investigative Dermatology*, v. 32, n. 3, p. 451-466, 1959.

PATNAIK, A. K. et al. Canine cutaneous mast cell tumor: morphologic grading and survival time in 83 dogs. *Veterinary pathology*, v. 21, n. 5, p. 469-474, 1984.

PETERS, J. A. Canine mastocytoma: excess risk as related to ancestry. *Journal of the National Cancer Institute*, v. 42, n. 3, p. 435-443, 1969.

SLEDGE, D.G. et al. Canine cutaneous mast cell tumors: A combined clinical and pathologic approach to diagnosis, prognosis, and treatment selection. *The Veterinary Journal*, v. 215, p. 43-54, 2016.

ŚMIECH, A. et al. Epidemiological study of canine mast cell tumours according to the histological malignancy grade. *Polish journal of veterinary sciences*, 2017.

SOUZA, A. C. F. et al. Mastocitoma cutâneo canino: estudo retrospectivo dos casos atendidos pelo Serviço de Oncologia do Hospital Veterinário da FCAV-Unesp, Campus Jaboticabal, de 2005 a 2015. *Pesquisa Veterinária Brasileira*, v. 38, n. 9, p. 1808-1817, 2018.

STREFEZZI, Ricardo F. et al. Prognostic indicators for mast cell tumors. *differentiation*, v. 58, p. 81, 2009.

THAMM, D. H. et al. Prognostic and predictive significance of KIT protein expression and c-kit gene mutation in canine cutaneous mast cell tumours: A consensus of the Oncology-Pathology Working Group. *Veterinary and Comparative Oncology*, v. 17, n. 4, p. 451-455, 2019.

WITHROW, S.J. et al. *Small Animal Clinical Oncology*. 5th. Saunders, Philadelphia, USA, Nov. 2012.