

University of Groningen

Fabry disease with atypical phenotype identified by massively parallel sequencing in early-onset kidney failure

de Haan, Amber; Morel, Chantal F.; Eijgelsheim, Mark; de Jong, Margriet F.C.; Broekroelofs, Jan; Vogt, Liffert; Knoers, Nine V.A.M.; de Borst, Martin H.

Published in:
Clinical Kidney Journal

DOI:
[10.1093/ckj/sfac269](https://doi.org/10.1093/ckj/sfac269)

IMPORTANT NOTE: You are advised to consult the publisher's version (publisher's PDF) if you wish to cite from it. Please check the document version below.

Document Version
Publisher's PDF, also known as Version of record

Publication date:
2023

[Link to publication in University of Groningen/UMCG research database](#)

Citation for published version (APA):

de Haan, A., Morel, C. F., Eijgelsheim, M., de Jong, M. F. C., Broekroelofs, J., Vogt, L., Knoers, N. V. A. M., & de Borst, M. H. (2023). Fabry disease with atypical phenotype identified by massively parallel sequencing in early-onset kidney failure. *Clinical Kidney Journal*, 16(4), 722-726. <https://doi.org/10.1093/ckj/sfac269>

Copyright

Other than for strictly personal use, it is not permitted to download or to forward/distribute the text or part of it without the consent of the author(s) and/or copyright holder(s), unless the work is under an open content license (like Creative Commons).

The publication may also be distributed here under the terms of Article 25fa of the Dutch Copyright Act, indicated by the "Taverne" license. More information can be found on the University of Groningen website: <https://www.rug.nl/library/open-access/self-archiving-pure/taverne-amendment>.




Take-down policy

If you believe that this document breaches copyright please contact us providing details, and we will remove access to the work immediately and investigate your claim.

Downloaded from the University of Groningen/UMCG research database (Pure): <http://www.rug.nl/research/portal>. For technical reasons the number of authors shown on this cover page is limited to 10 maximum.

ORIGINAL ARTICLE

Fabry disease with atypical phenotype identified by massively parallel sequencing in early-onset kidney failure

Amber de Haan ¹, Chantal F. Morel², Mark Eijgelsheim¹,
Margriet F.C. de Jong¹, Jan Broekroelofs³, Liffert Vogt ⁴, Nine V.A.M. Knoers⁵
and Martin H. de Borst ¹

¹Department of Internal Medicine, Division of Nephrology, University Medical Center Groningen, University of Groningen, Groningen, The Netherlands, ²Fred A. Litwin Centre in Genetic Medicine, Department of Medicine, University Health Network and Mount Sinai Hospital, University of Toronto, Toronto, ON, Canada,

³Department of Internal Medicine, Medical Center Leeuwarden, Leeuwarden, The Netherlands, ⁴Department of Internal Medicine, Section Nephrology, Amsterdam Cardiovascular Sciences, Amsterdam University Medical Center, University of Amsterdam, Amsterdam, The Netherlands and ⁵Department of Genetics, University Medical Center Groningen, University of Groningen, Groningen, The Netherlands

Correspondence to: Martin H. de Borst; E-mail: m.h.de.borst@umcg.nl

ABSTRACT

Background. The cause of chronic kidney disease (CKD) remains unknown in ~20% of patients with kidney failure. Massively parallel sequencing (MPS) can be a valuable diagnostic tool in patients with unexplained CKD, with a diagnostic yield of 12%–56%. Here, we report the use of MPS to establish a genetic diagnosis in a 24-year-old index patient who presented with hypertension, nephrotic-range proteinuria and kidney failure of unknown origin.

Additionally, we describe a second family with the same mutation presenting with early-onset CKD.

Results. In Family 1, MPS identified a known pathogenic variant in *GLA* (p.Ile319Thr), and plasma globotriaosylsphingosine and α -galactosidase A activity were compatible with the diagnosis of Fabry disease (FD). Segregation analysis identified three other family members carrying the same pathogenic variant who had mild or absent kidney phenotypes. One family member was offered enzyme therapy. While FD could not be established with certainty as the cause of kidney failure in the index patient, no alternative explanation was found. In Family 2, the index patient had severe glomerulosclerosis and a kidney biopsy compatible with FD at the age of 30 years, along with cardiac involvement and a history of acroparesthesia since childhood, in keeping with a more classical Fabry phenotype.

Conclusion. These findings highlight the large phenotypic heterogeneity associated with *GLA* mutations in FD and underline several important implications of MPS in the work-up of patients with unexplained kidney failure.

Keywords: chronic kidney disease, Fabry disease, *GLA* gene, kidney failure, massively parallel sequencing

Received: 5.7.2022; Editorial decision: 9.12.2022

© The Author(s) 2022. Published by Oxford University Press on behalf of the ERA. This is an Open Access article distributed under the terms of the Creative Commons Attribution-NonCommercial License (<https://creativecommons.org/licenses/by-nc/4.0/>), which permits non-commercial re-use, distribution, and reproduction in any medium, provided the original work is properly cited. For commercial re-use, please contact journals.permissions@oup.com

INTRODUCTION

Chronic kidney disease (CKD) can be caused by a wide range of disorders, including acquired and inherited diseases. The cause of CKD remains unknown in around 20% of patients with kidney failure [1]. Establishing the underlying kidney disease can have important consequences, including therapeutic implications. Previous studies have shown that massively parallel sequencing (MPS), formerly known as next generation sequencing, can be a useful diagnostic tool in patients with unexplained CKD, particularly in younger patients [2, 3]. The diagnostic yield of exome sequencing, one specific form of MPS, in patients with unexplained CKD has been reported to vary between 12% and 56%, depending on the population and gene selection [2]. At the same time, MPS can also raise novel diagnostic challenges, among others the risk of incidental findings.

Here, we describe a patient presenting with nephrotic-range proteinuria and kidney failure of unknown origin without specific clinical symptoms. MPS unexpectedly identified a known pathogenic variant in the *GLA* gene predisposing for Fabry disease (FD, OMIM 301500) in the proband and three family members. Additionally, we describe the clinical presentation of a second family with the same pathogenic variant, with a Fabry phenotype more in keeping with classic FD and a similar early-onset kidney phenotype in one family member. We will discuss phenotypic heterogeneity in FD and address the potential role of MPS in patients with unexplained early-onset CKD

RESULTS

Family 1

A 24-year-old man without relevant medical history presented with frequent nocturia and excessive thirst for 2 months. Routine laboratory investigation showed an estimated glomerular filtration rate (CKD Epidemiology Collaboration)

of 9 mL/min/1.73 m². He denied any other health complaints, except for mild fatigue. He did not use any medication. Both the paternal and the maternal grandfather had unspecified kidney disease, he was not aware of other family members with CKD. His maternal grandfather also had a pacemaker (Fig. 1). Blood pressure was 179/114 mmHg, further physical examination revealed no abnormalities. Additional laboratory tests showed a serum creatinine of 701 µmol/L, body urea nitrogen 26 mmol/L, albumin 36 g/L, lactate dehydrogenase 2.72 µmol/L, C-reactive protein <1 mg/L, renal anemia (Hb 6.5 mmol/L), hematocrit 0.33 L/L, thrombocytes 247 × 10⁹/L, neutrophils 5.6 × 10⁹/L, lymphocytes 2.0 × 10⁹/L, monocytes 1.0 × 10⁹/L, basophils <0.1 × 10⁹/L, eosinophils 0.2 × 10⁹/L and hyperparathyroidism (parathyroid hormone 31 pmol/L). Urine analysis revealed nephrotic-range proteinuria (5.3 g/day) with minimal erythrocyturia (0–10 erythrocytes/µL). Auto-immune serology was negative. Electrocardiogram showed a sinus rhythm, PR interval of 162 ms and signs of left ventricular hypertrophy (LVH). This was confirmed by echocardiography (left ventricular mass 166 g/m²), which showed no additional abnormalities and normal ejection fraction. Kidney ultrasonography showed diffusely increased echogenicity, with the left kidney measuring 10.4 cm and right kidney 12.1 cm. The kidney biopsy consisted of the transition from cortex to medulla and contained no glomeruli. Microscopic analysis revealed extensive tubular atrophy with interstitial fibrosis, some tubular intraluminal calcium oxalate crystals, and some inflammatory infiltrate. A few foamy fibroblasts could be identified. Frozen material showed only four globally sclerosed glomeruli and no intact glomeruli. Immunofluorescence was negative.

The working diagnosis was kidney failure of unknown origin, with a differential diagnosis that included focal segmental sclerosis (FSGS), membranous nephropathy or immunoglobulin A (IgA) nephropathy. IgA nephropathy was considered less likely as the patient had only mild erythrocyturia and kidney

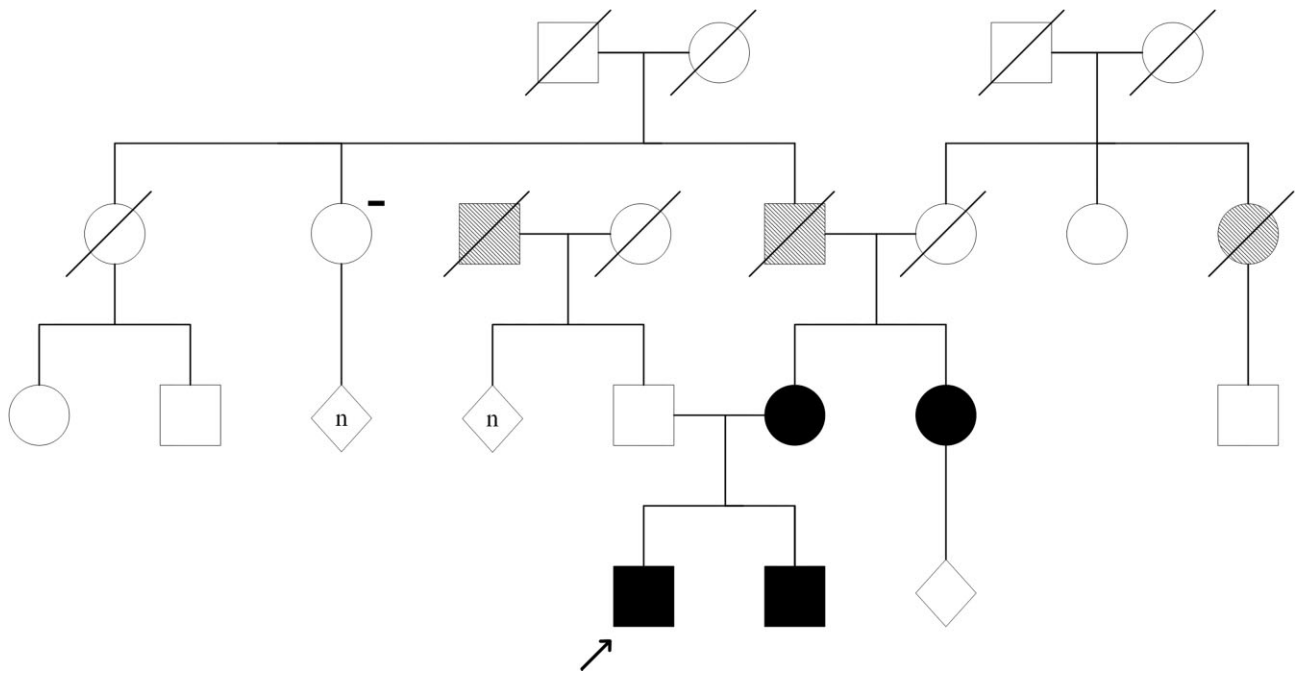


Figure 1: Pedigree of Family 1. The proband is indicated by the black arrow. Solid black symbols indicate family members with the p.Ile319Thr variant. The minus symbol (-) indicates that the family member does not carry the identified variant. A diamond with (n) specifies that the number of offspring is not shown. Squares and circle with a diagonal pattern represent patients with reported CKD.

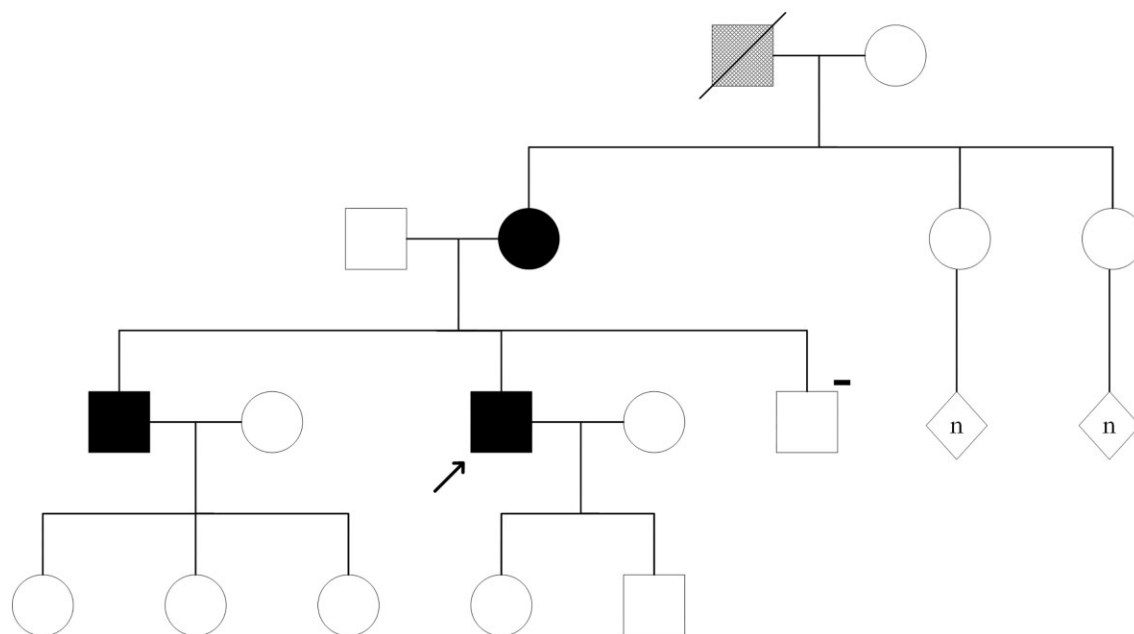


Figure 2: Pedigree of Family 2. The proband is indicated by the black arrow. Solid black symbols indicate family members with the p.Ile319Thr variant. The minus symbol (-) indicates that the family member does not carry the identified variant. A diamond with (n) specifies that the number of offspring is not shown. The hatched square represents a patient with reported anhidrosis.

immunofluorescence for IgA was negative. Given the severe hypertension upon presentation, thrombotic microangiopathy (TMA), for example due to hemolytic uremic syndrome (HUS) or thrombotic thrombocytopenic purpura, were also considered, but deemed unlikely based on the laboratory results. Two months after initial presentation, he was accepted for kidney transplantation. His mother, father and brother came forward as living donor candidates.

Considering the young age at presentation, the absence of a primary kidney disease diagnosis, positive family history and several related potential kidney donors, whole-exome sequencing was performed followed by variant filtering and analysis based on the CKD-young gene panel (v18.1, 141 genes) from the University Medical Center Utrecht. A known pathogenic missense variant [c.956T > C, p.(Ile319Thr)] in *GLA* was identified. Based on the identified pathogenic variant, medical history and physical examination were repeated with a focus on FD. The patient denied any FD-related symptoms, such as hypohidrosis, acroparesthesias, or heat and exercise intolerance. Physical examination showed no angiokeratomas or corneal opacities. Additional investigation showed a plasma globotriaosylsphingosine (LysoGb3) level of 10.4 nmol/L (normal ≤ 0.6 nmol/L), while α -galactosidase A (α -Gal A) activity was 0.5 nmol/h/mg (normal 32–70 nmol/h/mg). Cardiac magnetic resonance imaging (MRI) showed a left ventricular mass of 77 g/m² (reference value for men <40 years <60 g/m²), a reduced native septal T1 (900 ms) and no signs of fibrosis. Cerebral MRI revealed small white matter abnormalities in the right frontal lobe and white matter hyperintensity in the occipital lobe on both sides on FLAIR images. Based on these results, the patient was diagnosed with FD. Since kidney biopsy only contained globally sclerosed glomeruli, no podocytes could be examined and there was no material for electron microscopy. There may be some vacuolization present in interstitial cells, but this could unfortunately not be proven in the material available. Therefore, no histological

evidence could be provided that FD was the cause of kidney failure. However, there was also no histological evidence of another diagnosis explaining kidney failure. The patient was not considered eligible for enzyme therapy at this time, but this will be re-evaluated annually.

Upon referral to a clinical geneticist, segregation analysis identified three other family members carrying the same p.Ile319Thr pathogenic variant: his mother, brother and a maternal aunt (Fig. 1). His brother was asymptomatic, and his aunt turned out to have proteinuria. His mother had hypertension and cardiac arrhythmia, and MRI revealed cardiac fibrosis. She was offered the option for enzyme replacement therapy. The patient's father was selected as kidney donor and the pre-emptive kidney transplantation was successful.

Family 2

In Canada, a family with the same pathogenic variant was identified (Fig. 2). The proband of this family, a 46-year-old man, presented with sudden cardiac arrest at the age of 30 years. A pacemaker was inserted within 2 days of his acute presentation, and during the hospitalization he was found to have proteinuria and increased serum creatinine. The diagnosis of FD was confirmed by enzyme assay for α -galactosidase which was decreased at 4 nmol/h/mg (normal 13–38 nmol/h/mg). Genetic testing identified the pathogenic p.Ile319Thr variant in *GLA*. On history, he reported acroparesthesias which started at 12 years of age, gastrointestinal symptoms including chronic constipation and frequent headaches.

Four months after his initial presentation, he underwent a kidney biopsy which revealed a severe degree of glomerulosclerosis with moderate interstitial fibrosis and tubular atrophy. Vacuolization was present in podocytes and tubular epithelial cells. Immunofluorescence showed weak mesangial staining of IgM and C3. Electron microscopy revealed the presence of myelin

figures in cytoplasm of podocytes, consistent with FD and confirming the diagnosis Fabry nephropathy. He subsequently developed kidney failure and started renal replacement therapy at the age of 41 years. At 45 years of age, he underwent a successful renal transplant. At 46 years of age, his LVH (identified initially shortly after his diagnosis) continues to progress with an inter-ventricular septal thickness at end diastole (IVSD) now at 20 mm and posterior wall thickness also at 20 mm. He is being closely monitored from the cardiac perspective. He has been on treatment with agalsidase beta since 7 months following his cardiac arrest.

The brother of the proband, who is 2 years older, has the same pathogenic variant in *GLA*. He started developing CKD more recently with onset of proteinuria at the age of 47 years. His last 24 h urine collection shows proteinuria of 0.20 g/L/24 h and his creatinine is trending upward. He is known to have cardiac involvement, with low myocardial native T1 on MRI, IVSD of 13 mm, sinus bradycardia and voltage criteria for LVH. At 48 years of age he was started on migalastat in the hopes of slowing the progression of his FD. He has a α -Gal A activity of 6.0 nmol/h/mg (normal 13–38 nmol/h/mg). Their mother also has confirmed FD, but she was lost to follow-up. The maternal grandfather of the proband died young of suspected bowel obstruction and suffered from anhidrosis, but no diagnosis of FD was made while he was alive.

DISCUSSION

FD is a rare X-linked lysosomal storage disease caused by a mutation in *GLA*, leading to α -Gal A deficiency. In FD, deficiency of α -Gal A results in lysosomal accumulation of glycosphingolipids and globotriaosylceramide in various tissues throughout the body [4]. Men with classical FD usually present with characteristic symptoms, such as angiokeratoma, acroparesthesia, hypohidrosis and cornea verticillata. Over time, additional symptoms and complications including stroke, hypertrophic cardiomyopathy, cardiac arrhythmia and proteinuria, and kidney failure may develop [4].

The p.Ile319Thr variant identified in these families has been associated with both classical [5] and non-classical [6] phenotypes of FD, with the majority of patients presenting with a non-classical phenotype [7]. Patients with non-classical FD usually are 30–70 years old at first presentation, are generally less severely affected than those with classical FD, and have a more diverse disease course, with some patients having symptoms limited to a single organ [8]. Men with non-classical FD have lower plasma lysoGb3 values than men with classical FD and non-classical FD patients usually have residual α -Gal A activity [9]. In the proband of Family 1, the identified variant, the absence of characteristic FD symptoms, lysoGb3 value and some residual α -Gal A activity all match with non-classical FD. Some patients with non-classical FD have a renal variant, characterized by CKD without signs of classical FD [10]. However, a progressive decline in kidney function usually becomes evident between the fourth and fifth decade in male patients with non-classical FD [8]. Thus, the relatively early-onset of kidney failure in the proband of Family 1 raises the question whether FD is the (only) explanation. On the other hand, males with <1% of mean normal α -Gal A activity (as the proband of Family 1) are more likely to present with more severe kidney damage [11], and exome sequencing (including genes associated with atypical HUS and TMA) did not reveal an alternative genetic cause. Furthermore, various studies have shown variable genotype–phenotype correlations in patients with FD, even within the same family [12, 13]. This is

demonstrated in Family 2, where there is also a striking difference in severity of clinical presentation among family members. This family also illustrates that the p.Ile319Thr pathogenic variant can lead to a severe cardiac phenotype, early-onset FD nephropathy and can cause kidney failure. While α -Gal A activity and phenotype of the proband of Family 2 is more in keeping with classical FD, his older brother's presentation is of later onset and more in keeping with non-classical FD.

It is known that FD can coexist with several (primary) kidney diseases, including IgA nephropathy, membranous nephropathy, FSGS and crescentic glomerulonephritis. Several of these kidney diseases are also included in the differential diagnosis of the proband of Family 1 and could offer an alternative explanation for kidney failure in this patient. Only native kidney biopsy could help clarify renal involvement of FD or an alternative kidney disease. Unfortunately, renal biopsy was inconclusive in this patient and no kidney tissue of sufficient quality was available for further analysis. However, the fact that in the proband of Family 2 the same mutation did lead to biopsy-proven early onset of Fabry nephropathy makes it more plausible that this mutation also led to early-onset kidney failure in the proband of Family 1. In addition, the low T1 values on MRI could point towards cardiac involvement of FD. The left ventricular mass and T1 will be regularly assessed by MRI, especially since this variant seems to be associated with cardiac involvement of FD in both families.

Despite the remaining uncertainty regarding FD as the potential cause of kidney failure in the proband of Family 1, this case does demonstrate the relevance of genetic screening in young patients with kidney failure who are eligible for family transplantation as it guided donor selection. Two of the three potential donors had the same pathogenic variant as the proband. Awareness of potential genetic causes of CKD is particularly important in the transplant setting, as more than half of all living kidney donors are related to their recipient and related donors have a higher risk of developing kidney failure after donation, compared with unrelated donors [14]. In addition, the prevalence of hereditary kidney disease is 25% in all patients on the kidney transplant waitlist [15] and around 11% in patients with unexplained kidney failure on the kidney transplant waitlist [15, 16]. Genetic screening is therefore pivotal in young patients with unexplained kidney failure who have potential living-related donors. The genetic diagnosis in Family 1 had consequences for all four affected family members: younger family members have been counselled for family planning and all affected family members will be evaluated regularly for FD progression and eligibility for enzyme replacement therapy. Regular assessment of cardiac manifestations of FD could be important in all patients with the p.Ile319Thr variant, as almost all affected members of the two families described here display signs of cardiac involvement.

In conclusion, this report illustrates that the interpretation of MPS results in the context of the clinical phenotype can be challenging. At the same time, it highlights several important implications of a genetic diagnosis in patients with kidney failure of unknown origin.

STATEMENT OF ETHICS

This study has been approved by the institutional review board of the University Medical Center Groningen and is conducted in accordance with the Declaration of Helsinki. Written informed consent was obtained from all study participants.

AUTHORS' CONTRIBUTIONS

A.d.H. wrote the first draft of the manuscript. M.E., C.F.M., M.F.C.d.J., J.B., L.V., N.V.A.M.K. and M.H.d.B. gave feedback and contributed to manuscript revision. All authors read and approved the submitted version.

FUNDING

This work is co-funded by Sanofi Genzyme and the Dutch Ministry of Economic Affairs and Climate Policy by means of the PPP Allowance made available by the Top Sector Life Sciences & Health to stimulate public-private partnerships (grant number RVO/6320). None of the above funding sources or sponsors was involved in the conception, execution or analysis and interpretation of the data, and they had no role in drafting the manuscript.

DATA AVAILABILITY STATEMENT

The data underlying this article cannot be shared publicly due to concerns regarding the privacy of individuals that participated in this study. The data will be shared on reasonable request to the corresponding author.

CONFLICT OF INTEREST STATEMENT

N.V.A.M.K. reports a grant from Health Holland. L.V. reports consulting fees (all to employer) from Sanofi Genzyme. M.H.d.B. reports honoraria (all to employer) from Amgen, AstraZeneca, Bayer, Kyowa Kirin Pharma, Pharmacosmos, Sanofi Genzyme and Vifor Pharma, and grants from Sanofi Genzyme and Health Holland (grant numbers RVO/6320 and IMAGEN/LSHM20009). The other authors declare no competing interest.

REFERENCES

- Kramer A, Pippias M, Noordzij M et al. The European Renal Association – European Dialysis and Transplant Association (ERA-EDTA) Registry Annual Report 2016: a summary. *Clin Kidney J* 2019;**12**:702–20.
- de Haan A, Eijgelsheim M, Vogt L et al. Diagnostic yield of next-generation sequencing in patients with chronic kidney disease of unknown etiology. *Front Genet* 2019;**10**:1264.
- Snoek R, van Jaarsveld RH, Nguyen TQ et al. Genetics-first approach improves diagnostics of ESKD patients <50 years old. *Nephrol Dial Transplant* 2022;**37**:349–57.
- Germain DP. Fabry disease. *Orphanet J Rare Dis* 2010;**5**:30.
- Lukas J, Cimmaruta C, Liguori L et al. Assessment of gene variant amenability for pharmacological chaperone therapy with 1-Deoxygalactonojirimycin in Fabry Disease. *Int J Mol Sci* 2020;**21**:956.
- van der Tol L, Verhamme C, van Schaik IN et al. In patients with an α -Galactosidase A variant, small nerve fibre assessment cannot confirm a diagnosis of Fabry disease. *JIMD Rep* 2015;**95**:103.
- The Fabry Working Group Genotype-Phenotype Database (Fabry-Gen-Phen database) [Internet]. <http://fabrygenphen.com/> (28 November 2021, date last accessed).
- Arends M, Wanner C, Hughes D et al. Characterization of classical and nonclassical Fabry disease: a multicenter study. *J Am Soc Nephrol* 2017;**28**:1631–41.
- Smid BE, van der Tol L, Biegstraaten M et al. Plasma globotriaosylsphingosine in relation to phenotypes of Fabry disease. *J Med Genet* 2015;**52**:262–8.
- Nakao S, Kodama C, Takenaka T et al. Fabry disease: detection of undiagnosed hemodialysis patients and identification of a “renal variant” phenotype. *Kidney Int* 2003;**64**:801–7.
- Branton MH, Schiffmann R, Sabnis SG et al. Natural history of fabry renal disease. *Medicine (Baltimore)* 2002;**81**:122–38.
- Hirashio S, Kagawa R, Tajima G et al. A classic variant of Fabry disease in a family with the M296I late-onset variant. *CEN Case Rep* 2021;**10**:106–10.
- Rigoldi M, Concolino D, Morrone A et al. Intrafamilial phenotypic variability in four families with Anderson-Fabry disease. *Clin Genet* 2014;**86**:258–63.
- Wainright JL, Robinson AM, Wilk AR et al. Risk of ESRD in prior living kidney donors. *Am J Transplant* 2018;**18**:1129–39.
- Ottlewski I, Münch J, Wagner T et al. Value of renal gene panel diagnostics in adults waiting for kidney transplantation due to undetermined end-stage renal disease. *Kidney Int* 2019;**96**:222–30.
- Schrezenmeier E, Kremerskothen E, Halleck F et al. The underestimated burden of monogenic kidney disease in adults waitlisted for kidney transplantation. *Genet Med* 2021;**23**:1219–24.