

University of Groningen

Multicentre experience with valve-sparing aortic root replacement by means of combined remodelling and external aortic ring annuloplasty in patients with Marfan syndrome

Accord, Ryan E; Mecozzi, Gianclaudio; Aalberts, Jan J J; Nijs, Jan; Ter Weeme, Mimi; van Aarnhem, Egidius E H L; Mariani, Massimo A; van den Berg, Maarten P

Published in:
Interdisciplinary cardiovascular and thoracic surgery

DOI:
[10.1093/icvts/ivad200](https://doi.org/10.1093/icvts/ivad200)

IMPORTANT NOTE: You are advised to consult the publisher's version (publisher's PDF) if you wish to cite from it. Please check the document version below.

Document Version
Publisher's PDF, also known as Version of record

Publication date:
2023

[Link to publication in University of Groningen/UMCG research database](#)

Citation for published version (APA):

Accord, R. E., Mecozzi, G., Aalberts, J. J. J., Nijs, J., Ter Weeme, M., van Aarnhem, E. E. H. L., Mariani, M. A., & van den Berg, M. P. (2023). Multicentre experience with valve-sparing aortic root replacement by means of combined remodelling and external aortic ring annuloplasty in patients with Marfan syndrome. *Interdisciplinary cardiovascular and thoracic surgery*, 37(6), Article ivad200. <https://doi.org/10.1093/icvts/ivad200>

Copyright

Other than for strictly personal use, it is not permitted to download or to forward/distribute the text or part of it without the consent of the author(s) and/or copyright holder(s), unless the work is under an open content license (like Creative Commons).

The publication may also be distributed here under the terms of Article 25fa of the Dutch Copyright Act, indicated by the "Taverne" license. More information can be found on the University of Groningen website: <https://www.rug.nl/library/open-access/self-archiving-pure/taverne-amendment>.

Take-down policy

If you believe that this document breaches copyright please contact us providing details, and we will remove access to the work immediately and investigate your claim.

Downloaded from the University of Groningen/UMCG research database (Pure): <http://www.rug.nl/research/portal>. For technical reasons the number of authors shown on this cover page is limited to 10 maximum.

Cite this article as: Accord RE, Mecozzi G, Aalberts JJ, Nijs J, ter Weeme M, van Aarnhem EE.L. *et al.* Multicentre experience with valve-sparing aortic root replacement by means of combined remodelling and external aortic ring annuloplasty in patients with Marfan syndrome. *Interdiscip CardioVasc Thorac Surg* 2023; doi:10.1093/icvts/ivad200.

Multicentre experience with valve-sparing aortic root replacement by means of combined remodelling and external aortic ring annuloplasty in patients with Marfan syndrome

Ryan E. Accord ^{a,*}, Gianclaudio Mecozzi^a, Jan JJ. Aalberts^b, Jan Nijs ^c, Mimi ter Weeme^d, Egidius E.H.L. van Aarnhem^e, Massimo A. Mariani^a and Maarten P. van den Berg ^f

^a Department of Cardiothoracic Surgery, University of Groningen, University Medical Center Groningen, Groningen, Netherlands

^b Department of Cardiology, Reinier de Graaf Hospital, Delft, Netherlands

^c Department of Cardiac Surgery, University Hospital Brussels, Brussels, Belgium

^d Thorax Centrum Twente, Medisch Spectrum Twente, Enschede, Netherlands

^e Department of Cardiothoracic Surgery, University Medical Center Utrecht, Utrecht, Netherlands

^f Department of Cardiology, University of Groningen, University Medical Center Groningen, Groningen, Netherlands

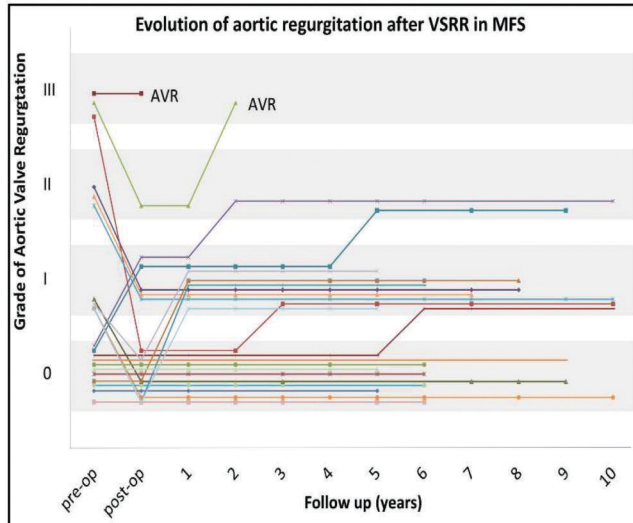
* Corresponding author. Department of Cardiothoracic Surgery, University of Groningen, University Medical Center Groningen, Hanzeplein 1, 9700 RB Groningen, Netherlands. Tel: +31-50-3617446; e-mail: r.e.accord@umcg.nl (R.E. Accord).

Received 27 June 2023; received in revised form 15 November 2023; accepted 8 December 2023

Remodeling Valve Sparing Root Replacement in Patients with Marfan Syndrome

Summary

In 22 patients with MFS, we evaluated the outcome of aortic root remodeling with ring annuloplasty and structured valve repair. There was no mortality and a low complication rate. Two patients (9%) with severe AR and extreme Ao diameters underwent AVR early after VSRR. This technique is safe, with good results in patients undergoing VSRR at recommended diameters and without severe AR.



Legend: MFS Marfan syndrome, VSRR Valve sparing root replacement, AR Aortic valve regurgitation, AVR Aortic valve replacement

Abstract

OBJECTIVES: The most recent valve-sparing root replacement technique combines the advantages of the reimplantation (David) and remodelling (Yacoub) techniques. The aortic root is reconstructed according to the remodelling technique, the aortic valve is repaired

according to the principle of effective height, and an external ring provides annular support. The purpose of this study was to evaluate operative and mid-term outcomes using this technique in patients with Marfan syndrome.

METHODS: Adult patients with Marfan syndrome who had an indication for aortic root surgery according to European Society of Cardiology guidelines and were operated on using this new root replacement technique were retrospectively evaluated. Follow-up was obtained from standard outpatient visits and included echocardiography.

RESULTS: The study group comprised 22 patients (mean age 36 years, 68% males). Mean follow-up was 7.5 years. There were no mortalities. Two patients required aortic valve replacement because of aortic regurgitation. In both patients, the aortic root was severely dilated (≥ 65 mm) preoperatively, with grade III aortic valve regurgitation and aortic valve cusps that were very fragile. Aortic regurgitation was grade ≤ 1 on follow-up in 18 of the remaining 20 patients.

CONCLUSIONS: Valve-sparing root replacement using remodelling combined with aortic-ring annuloplasty is safe in patients with Marfan syndrome. The mid-term outcome is promising in patients undergoing elective valve-sparing root replacement at recommended root diameters. However, in patients with extremely dilated aortic roots and already severe aortic regurgitation, the technique should be used cautiously as aortic cusps are fragile and might not be suitable for durable repair.

Clinical registration number: UMCG Research registry #11208

Keywords: Aortic root replacement · Aortic valve repair · Marfan syndromes

ABBREVIATIONS

AR	Aortic regurgitation
ESC	European Society of Cardiology
MFS	Marfan syndrome
STJ	Sinotubular junction
VSRR	Valve-sparing root replacement

INTRODUCTION

Marfan syndrome (MFS) is an autosomal dominantly inherited connective tissue disorder characterized by thin body habitus and long extremities, mitral valve prolapse and aortic (root) dilatation [1]. Prophylactic aortic root replacement is a cornerstone of the treatment of MFS, reducing morbidity and mortality related to aortic root dissection and rupture [2]. Furthermore, aortic root dilatation can result in aortic insufficiency requiring an intervention. Several surgical aortic root replacement techniques have been developed throughout the past 50 years, which can roughly be divided into an aortic valve replacement technique (Bentall and De Bono procedures) or valve-sparing root replacement (VSRR) techniques (David/reimplantation or Yacoub/remodelling techniques) [3–5]. Valve-sparing techniques are interesting since they do not require lifelong anticoagulation therapy, contrary to valve replacement with a mechanical valve prosthesis. Although technically demanding, the VSRR procedures have shown favourable long-term results compared to valve replacement strategies. They are emerging as the preferred procedure in young patients with connective tissue disease. The durability of the remodelling technique of VSRR, however, has been debated due to the lack of annular stability this procedure provides, especially in patients with connective tissue disease. An alternative approach was described by Lansac *et al.* [6], which combines the remodelling technique with an aortic annuloplasty with an expansible external subvalvular aortic ring. This study aimed to evaluate operative and mid-term outcomes using this technique, specifically in patients with MFS.

PATIENTS AND METHODS

Ethical statement

The study was approved by the Medical Ethical Review Board of the University Medical Center Groningen (UMCG) (ref. M23.314091; METCnr 2023/129). The need for patient consent was waived due to the study's retrospective nature.

Study population

Between August 2011 and October 2018, all patients with MFS who had an indication for aortic root surgery underwent VSRR according to the standardized technique described by Lansac *et al.* [6]. All consecutive patients were included in this study. Fourteen patients were operated in UMCG, 5 in Thorax Centrum Twente, 2 in University Hospital Brussels and 1 in University Medical Center Utrecht. Most patients ($n = 19$) were under close cardiac outpatient care in one of the Marfan or Aortic outpatient clinics. MFS was diagnosed according to the revised Ghent nosology in all patients [1]. Follow-up included regular imaging of the aortic root. Indication for aortic root surgery was according to European Society of Cardiology (ESC) Guidelines: aortic root diameter ≥ 50 or ≥ 45 mm with risk factors (family history of aortic dissection or aortic size increase >2 mm/year, severe aortic or mitral regurgitation, or desire for pregnancy) [7]. Three patients had an urgent presentation and were not under surveillance previously.

All aortic root surgery was performed by experienced aortic surgeons. Their initial training and experience were with the reimplantation technique, before adopting the technique of root remodelling with external aortic ring annuloplasty as the method of choice for VSRR in their institutes. Aortic surgery in the University Medical Center Groningen is being performed by a dedicated team of 3 aortic surgeons, one of whom also participated in the cases performed in Thorax Centrum Twente and University Medical Center Utrecht. The cases from University Hospital Brussels were performed by a single dedicated aortic surgeon with 20+ years of experience.

Operative technique

The procedure was performed through a midline sternotomy (Fig. 1). Cardiopulmonary bypass was instituted via ascending aortic arterial cannulation and 2-stage venous cannulation of the right atrium. After cardiac arrest using antegrade and/or retrograde blood cardioplegia, the aorta was transected at the sinotubular junction (STJ) level, and the aortic valve was systematically assessed. Moderate or severe calcification of cusps, poor mobility and cusp retraction (geometric height below 17 mm in tricuspid valves and below 20 mm in bicuspid valves), as well as significant fenestrations were considered a contraindication for a repair [8].

After the inner aortic annular diameter was determined using Hegar dilators, a Valsalva Dacron conduit (Gelweave Valsalva graft, Vascutek, Inchinnan, England) and an annular ring (CORONEO Inc., Montreal, Canada) were selected according to sizing recommendations by Lansac *et al.* [8].

The aortic root was dissected free from the pulmonary trunk and infundibulum beyond the subannular plane of the aortic valve. The aneurysmatic aortic root was fully resected, leaving a rim of aortic wall of ~2 mm and minimizing the coronary button size. A remodelling technique root replacement was performed. Before reimplanting the coronary buttons, the external subannular ring was lowered in place and anchored by 5 or 6 braided pledgeted sutures. Subsequently, effective height of each cusp was measured using a cusp caliper. Prolene 5.0 plicating stitches were added to the free edge of the cusps if necessary in order to obtain an effective height of at least 9 mm. The coronary reimplantation and distal anastomosis were performed in a standard fashion.

After cardiopulmonary bypass weaning, transoesophageal echocardiography was performed to assess the aortic valve. Effective height ≥ 9 mm was confirmed, and only central aortic valve regurgitation (AR) grade I or less was accepted.

Follow-up and echocardiographic assessment

All patients were followed annually in the outpatient clinic, and echocardiographic assessment of aortic valve function and ventricular function was performed according to the relevant ESC Guidelines [9, 10]. Aortic regurgitation could be absent or graded as mild (grade I), moderate (grade II) or severe (grade III). In addition, a routine computed tomography angiogram of the thoracic aorta was performed 6–12 months after surgery, to identify potential false or true aneurysm formation at the suture lines.

RESULTS

Between August 2011 and October 2018, 22 adult patients with MFS presented with aortic root dilatation or aortic valve regurgitation (Table 1). All patients underwent aortic root replacement according to the technique described by Lansac. No patients primarily received a valve replacement (aortic valve replacement or Bentall), since a repair was deemed feasible in all instances. Baseline characteristics are listed in Table 1. Three patients underwent urgent surgery, 2 after being admitted with decompensated heart failure due to grade III AR caused by gigantic aortic root aneurysms. Total follow-up was 150, 87 patient-years, with a mean follow-up of 7.5 years (range 4.4–10.7 years). Operative data are shown in Table 2.

Outcome

There was no in-hospital mortality nor mortality during follow-up. The postoperative course was uneventful in the majority of patients (17/22). One patient (#2) that underwent urgent surgery for severe aortic- and mitral regurgitation remained in cardiogenic shock postoperatively, requiring temporally support by

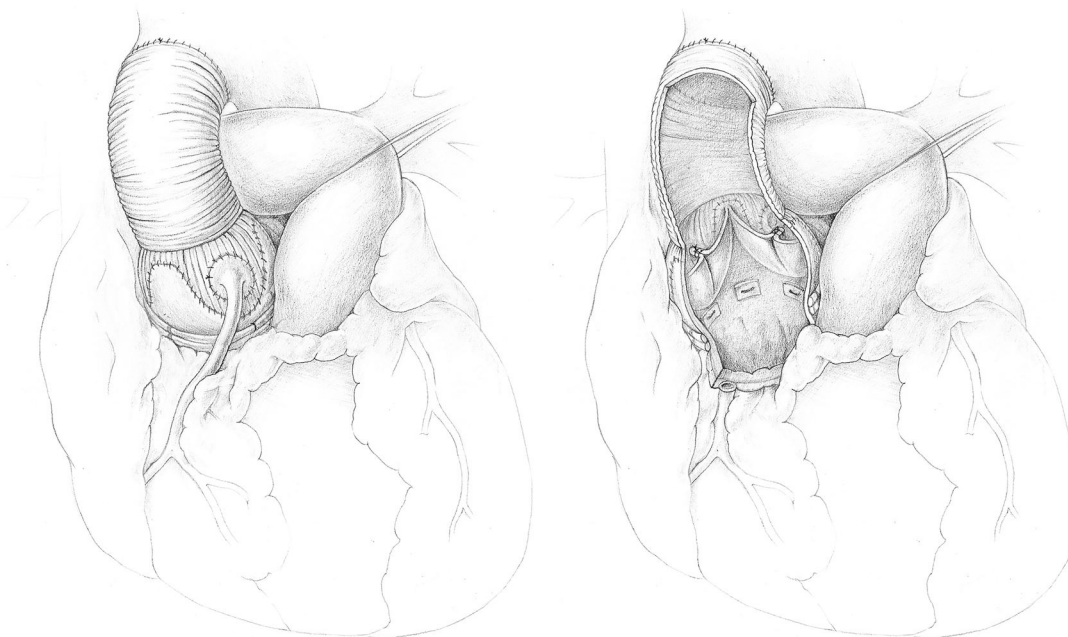


Figure 1: External and internal view of the aortic root and aortic valve after valve-sparing root replacement.

Table 1: Baseline characteristics

Characteristic	
N	22
Age (years) (mean)	36 (15–62)
Male sex	15 patients (68%)
LVEF % (mean)	53% (35–60%)
Aortic root diameter (mm) (mean, range)	54 (45–88)
Aortic root diameter \geq 45 and $<$ 50 mm	7 patients
Aortic root diameter \geq 50 and $<$ 65 mm	12 patients
Aortic root diameter \geq 65 mm and severe AR	3 patients
Aortic valve morphology (tricuspid/bicuspid)	20/2
Moderate or severe AR (grade \geq 2)	6 patients (27%)
Functional classification ^a	
Type 1a-b (ST) and/or root dilation	3 patients
Type 2 (Cusp prolapse)	3 patients
Urgent or emergent operation	2 patients (8,7%)

^aEl Khouri functional classification for aortic regurgitation [26].

AR: aortic regurgitation; LVEF: left ventricular ejection fraction; STJ: sino-tubular junction.

Table 2: Operative data

Item	
N	22
Aortic cross-clamp time (mean)	166 min
Cardiopulmonary bypass time (mean)	221 min
Concomitant procedure	
Mitral valve repair	2 patients
Coroneo ring size (mean, range)	27 mm (25–29)
Valsalve prosthesis size (mean, range)	29 mm (28–32)
Valvular cusp repair	
None	6 (27%)
Central plication	16 patients (73%)
1 cusp	7 patients
2 cusps	1 patient
3 cusps	6 patients
Fused cusp (bicuspid valve)	2 patients
Additional repair	
cusp fenestration	2 patient (9%)
commissural annuloplasty (Cabrol)	1 patient (4.5%)

extracorporeal life support. There was one patient in whom the postoperative course was complicated by pneumonia, one patient developed colitis, and 3 patients had postoperative atrial fibrillation. No patients required permanent pacemaker implantation. One patient underwent a repeat sternotomy for a late tamponade, none for bleeding, and no wound infections were noted.

The grade of AR, preoperative, postoperative and during follow-up of all patients is presented in Fig. 2. Two patients required an aortic valve reintervention during follow-up. Both patients initially presented with extremely dilated aortic roots (88 and 65 mm, respectively) and had to undergo aortic valve replacement because of recurrent grade III AR. Patient #1, who was operated on urgently, required a reoperation 1 week post-operatively due to a cusp tear at the plication site. Patient #3 had undergone a VSRR and a mitral valve annuloplasty initially. AR graded moderate at discharge, progressed to severe at 20 months of follow-up, warranting replacement of the aortic

valve. During redo-operation distinct prolapse of 1 of 3 cusps was identified in combination with some degree of annular dilatation despite the placement of a 27 mm external ring during the first operation.

In the remaining 20 patients with successful aortic valve repair, AR at a mean follow-up of 7,8 years was grade II in 2 patients and grade 0–I in 18 patients, with a mean peak gradient over the repaired aortic valves of 9 mmHg (range 5–20 mmHg). The mean left ventricular end-diastolic dimension was 52 mm (range 37–60 mm), mean left ventricular end-systolic dimension was 35 mm (range 30–49 mm), and left ventricular ejection fraction was improved or $>$ 55% in all patients.

One patient (#8) presented with acute type B dissection 8 months after the elective aortic root replacement. This was managed conservatively in the acute phase. The patient underwent successful open repair of the thoracic descending aorta with an interposition graft 2 months later. One additional patient (#13) underwent a total aortic arch replacement for the formation of an aneurysm starting at the distal anastomosis 5 years after the initial root and ascending aorta replacement. In both patients, no concomitant aortic valve or root procedure was required.

All patients were in New York Heart Association class 1 during the latest follow-up. There was no occurrence of endocarditis during the follow-up period.

DISCUSSION

We describe our multicentre experience with a contemporary technique of VSRR, described by Lansac *et al.* [6], specifically in patients with MFS. This is one of the first studies with mid-term results up to 10 years of follow-up (mean 7.5 years) in this specific population. We observed no perioperative or follow-up mortality and good durability results. We demonstrate that up to 90% of patients were free from aortic valve reintervention during follow-up.

Even though the VSRR techniques are technically more demanding, they have successfully challenged the previous standard, namely total root replacement by a composite conduit (Bentall/De Bono procedure), as the preferred procedure. The benefits of a VSRR technique are well documented. By preserving the often anatomically normal native valve, the need for life-long anticoagulation is prevented. This is especially important for the population that require root replacement at a younger age, like patients with MFS or other connective tissue diseases often do. Numerous studies showed that patients with MFS undergoing VSRR had superior freedom from bleeding/thromboembolism compared to patients with MFS undergoing a Bentall procedure [11–13]. In addition, a systematic review and meta-analysis of patients with MFS comparing the Bentall procedure with a VSRR (reimplantation technique) confirmed that freedom from valve-related reintervention, as well as mid- to long-term survival were both in favour of the VSRR group [14]. However, there is a distinction between the reimplantation technique described by David and the VSRR remodelling technique by Yacoub. While the reimplantation technique can reduce and stabilize the basal ring by fully incorporating the valve and annulus in the prosthesis, the remodelling technique allows for a more physiological reconstruction by preserving the root dynamics [6, 15]. Since annular dilatation can still progress after the remodelling procedure, most surgeons have recommended avoiding this technique in patients with connective tissue disorders [16, 17].

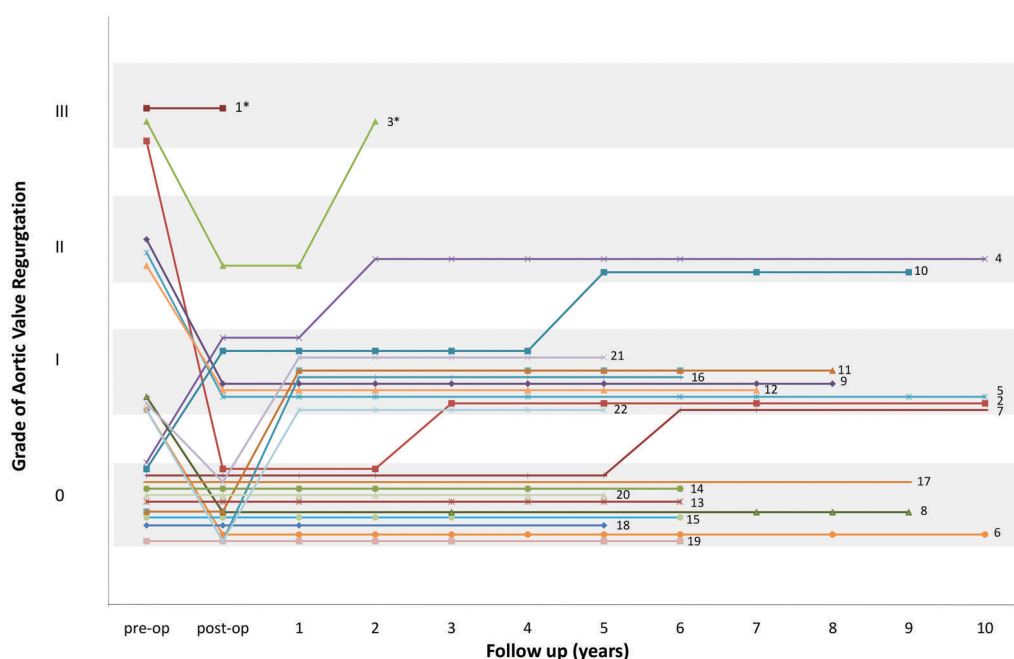


Figure 2: Grade of aortic regurgitation preoperative, postoperative and during follow-up. Two patients eventually underwent aortic valve replacement (*), respectively, 1 week and 2 years after valve-sparing root replacement due to the recurrence of grade III aortic valve regurgitation. Both had initially presented with decompensated heart failure due to grade III aortic regurgitation with extremely dilated aortic roots, 88 and 65 mm, respectively.

Indeed a meta-analysis of 1385 patients with MFS undergoing VSRR demonstrated that the reimplantation technique was associated with a reduced rate of reintervention when compared with the remodelling technique (0.7%/year vs 2.4%/year, $p=0.02$). However, it was still inferior to the Bentall procedure ($P=0.02$) [13]. As a matter of fact, VSRR was associated with a fourfold increased rate of reintervention on the aortic valve compared to the Bentall procedure (1.3% per year vs 0.3% per year; $P=0.02$). In addition, a single-centre study by De Oliveira *et al.* [18] demonstrated that grade $>II$ AR was present in up to 25% of the patients undergoing reimplantation VSRR for MFS at 8-year follow-up. Therefore, innovative VSRR techniques, which might benefit especially young patients with connective tissue disease, are being evaluated.

Long-term durability is the single most important concern of aortic root replacement technique in which the aortic valve is preserved. Understanding the mechanism of aortic root dilatation in relation to normal aortic valve function is crucial for understanding aortic valve dysfunction in the setting of MFS and failure mechanisms after VSRR. The vast majority (80%) of patients with MFS experience root dilatation in the form of annuloaortic ectasia (characterized by a pear-shaped proximal aorta) [19]. Aortic root dilatation, both STJ and aortic annulus level, contribute to valve malfunction by reduction of the coaptation zone [20]. Gradual dilatation at the level of the STJ may also cause compensatory stretching and elongation of the free edge of the cusps. Even though this may initially preserve aortic competence by preservation of the coaptation zone, progression will eventually result in AR due to severe prolapse of one or multiple cusps. In addition, abnormalities associated with MFS, like fenestrations, may contribute to aortic valve incompetence.

The VSRR technique described in the current series addresses STJ diameter, annulus diameter, as well as free edge elongation and prolapse of the individual cusps. The remodelling technique remains appealing as aortic root dynamics are better

maintained, and leaflet stress is minimized, which is thought to contribute to long-term durability [16, 21, 22].

In the first publication on the results of this technique by Lansac *et al.* [23], 18 patients with MFS were included, of which 2 required a valve replacement due to grade III AR (cusp prolapse and retraction) after 27 and 34 months, respectively. In a more recent publication on the long-term outcome of this technique, 23 MFS patients were included, of whom one required a reoperation one month postoperatively because of a false aneurysm at the level of the septum below the left and right coronary sinus commissure, caused by a tear from the pledged anchoring stitch of the aortic ring [24]. Length of follow-up in patients with MFS was not specified separately in both studies, but in the total cohort, freedom from valve-related reoperation was 90.5% at a mean follow-up of 47 ± 39.4 months [24]. Underlying MFS was not identified as a predictor of recurrence of AR (grade $\geq II$), only the presence of preoperative grade $\geq II$ AR.

A recent study by Chauvette *et al.* [25] reported results from the AVIATOR registry, focusing on patients with heritable aortic disorders (83% MFS). In a total of 237 patients undergoing 4 techniques of VSRR (root remodelling alone, remodelling with ring annuloplasty, remodelling with suture annuloplasty and reimplantation), they showed that no differences could be found between techniques in terms of post-op AR grade ≥ 2 , reintervention rate or survival rate. The incidence of reintervention on the aortic valve at 10 years was $10.9 \pm 3.1\%$ for the overall group, $16.2 \pm 6.1\%$ for root reimplantation and $6.6 \pm 3.3\%$ for remodelling with ring annuloplasty group. They did, however, observe that aortic annulus dimensions were significantly larger at 10 years of follow-up in patients undergoing root remodelling alone, compared with the reimplantation and the remodelling with annuloplasty groups. This difference became apparent after 3 years of follow-up.

Table 3 summarizes the results of the studies, including our own, on root remodelling with ring annuloplasty in patients with

Table 3: Studies reporting on VSRR using the remodelling technique with external ring annuloplasty in patients with Marfan syndrome

Study	Inclusion period	N of MFS (% of total study cohort)	Mortality	Valve/root reintervention	Follow-up (years)
Lansac <i>et al.</i> 2010 [23]	2003–2009	18 (12.5%)	0%	11.1% (2 patients underwent AVR at 27 and 34 months)	2.2 (median for overall cohort)
Lansac <i>et al.</i> 2016 [24]	2003–2015	23 (9.9%)	0%	4.3% (1 proximal false aneurysm at 1 month)	3.3 (mean for overall cohort)
Chauvette <i>et al.</i> 2022 [25]	2003–2018	59 (78%)	0%	6.6%	Up to 10 years
Current study	2011–2018	22 (100%)	0%	9.1% (2 pts underwent AVR at 1 week, 24 months)	7.5 (mean) up to 10.7 years

MFS. Longer follow-up and larger numbers of patients are required to assess the long-term durability of this relatively new technique in patients with MFS. In our series, important characteristics of patients undergoing valve-related reoperation were extensive aneurysms and poor quality of leaflets. Therefore, patient selection seems to be an important criterion for favourable results.

Limitations

Our study is limited by its retrospective design and a relatively small number of patients. It is, however, one of a very limited number of studies reporting the mid-term outcome of this technique solely in patients with MFS. Furthermore, the surgical technique was applied in a very standardized and well-documented fashion [8].

CONCLUSION

Valve-sparing aortic root replacement using aortic root remodelling, external annular stabilization and aortic valve repair is safe in patients with MFS. Moreover, in patients undergoing elective VSRR at recommended aortic root diameters, the mid-term outcome is promising. However, in patients with extremely dilated aortic roots and already grade III AR, the technique should be used cautiously as the aortic cusps are fragile and might not be suitable for a durable repair. Extended follow-up, preferably in larger multicentre studies, will help to establish the role of this technique of VSRR for patients with MFS.

FUNDING

The authors report no financial support.

Conflict of interest: none declared.

DATA AVAILABILITY

The data underlying this article will be shared on reasonable request to the corresponding author.

AUTHOR CONTRIBUTIONS

Ryan E. Accord: Investigation; Methodology; Project administration; Writing—original draft. **Gianclaudio Mecozzi:** Validation; Writing—review & editing. **Jan J.J. Aalberts:** Conceptualization; Formal analysis; Methodology; Writing—review & editing. **Jan Nijs:** Data curation; Writing—review & editing. **Mimi ter Weeme:** Data curation; Writing—review & editing. **Egidius E.H.L. van Aarnhem:** Data curation; Writing—review & editing. **Massimo A. Mariani:** Validation; Writing—review & editing. **Maarten P. van den Berg:** Conceptualization; Formal analysis; Investigation; Methodology; Project administration; Supervision; Validation; Writing—review & editing.

REVIEWER INFORMATION

Interdisciplinary CardioVascular and Thoracic Surgery thanks Ahmed, Mohammed Nabil Abd AlJawad, Thomas Martens for their contribution to the peer review process of this article.

REFERENCES

- [1] Loeys BL, Dietz HC, Braverman AC, Callewaert BL, De Backer J, Devereux RB *et al.* The revised Ghent nosology for the Marfan syndrome. *J Med Genet* 2010;47:476–85. Jul
- [2] Silverman DI, Burton KJ, Gray J, Bosner MS, Kouchoukos NT, Roman MJ *et al.* Life expectancy in the Marfan syndrome. *Am J Cardiol* 1995; 75:157–60.
- [3] Bentall H, De Bono A. A technique for complete replacement of the ascending aorta. *Thorax* 1968;23:338–9.
- [4] Sarsam MA, Yacoub M. Remodeling of the aortic valve annulus. *J Thorac Cardiovasc Surg* 1993;105:435–8.
- [5] David TE, Feindel CM. An aortic valve-sparing operation for patients with aortic incompetence and aneurysm of the ascending aorta. *J Thorac Cardiovasc Surg* 1992;103:617–21; discussion 622.
- [6] Lansac E, Di Centa I, Raoux F, Bulman-Fleming N, Ranga A, Abed A *et al.* An expansible aortic ring for a physiological approach to conservative aortic valve surgery. *J Thorac Cardiovasc Surg* 2009;138:718–24.
- [7] Baumgartner H, Bonhoeffer P, De Groot NMS, de Haan F, Deanfield JE, Galie N *et al.*; ESC Committee for Practice Guidelines (CPG). The Task Force on the Management of Grown-up Congenital Heart Disease of the European Society of Cardiology (ESC): ESC Guidelines for the management of grown-up congenital heart disease (new version 2010). *Eur Heart J* 2010;31:2915–57.
- [8] Lansac E, Di Centa I, Vojacek J, Nijs J, Hlubocky J, Mecozzi G *et al.* Valve sparing root replacement: the remodeling technique with external ring annuloplasty. *Ann Cardiothorac Surg* 2013;2:117–23.
- [9] Lancellotti P, Tribouilloy C, Hagendorff A, Popescu BA, Edvardsen T, Pierard LA *et al.*; Scientific Document Committee of the European Association of Cardiovascular Imaging. Recommendations for the echocardiographic assessment of native valvular regurgitation: an executive

- summary from the European Association of Cardiovascular Imaging. *Eur Heart J Cardiovasc Imaging* 2013;14:611–44.
- [10] Lang RM, Badano LP, Mor-Avi V, Afilalo J, Armstrong A, Ernande L *et al.* Recommendations for cardiac chamber quantification by echocardiography in adults: an update from the American Society of Echocardiography and the European Association of Cardiovascular Imaging. *Eur Heart J Cardiovasc Imaging* 2015;16:233–70.
- [11] Price J, Magruder JT, Young A, Grimm JC, Patel ND, Alejo D *et al.* Long-term outcomes of aortic root operations for Marfan syndrome: a comparison of Bentall versus aortic valve-sparing procedures. *J Thorac Cardiovasc Surg* 2016;151:330–6.
- [12] Coselli JS, Volguina IV, LeMaire SA, Sundt TM, Connolly HM, Stephens EH *et al.*; Aortic Valve Operative Outcomes in Marfan Patients Study Group. Early and 1-year outcomes of aortic root surgery in patients with Marfan syndrome: a prospective, multicenter, comparative study. *J Thorac Cardiovasc Surg* 2014;147:1758–67.e4.
- [13] Benedetto U, Melina G, Takkenberg JJ, Roscitano A, Angeloni E, Sinatra R. Surgical management of aortic root disease in Marfan syndrome: a systematic review and meta-analysis. *Heart* 2011;97:955–8.
- [14] Burgstaller JM, Held U, Mosbahi S, Stak D, Steurer J, Eckstein F *et al.* A systemic review and meta-analysis: long-term results of the Bentall versus the David procedure in patients with Marfan syndrome. *Eur J Cardiothorac Surg* 2018;54:411–9.
- [15] Kari FA, Beyersdorf F, Rylski B, Stephens EH, Russe M, Siepe M. David I reimplantation procedure for aortic root replacement in Marfan patients: medium-term outcome. *Interact CardioVasc Thorac Surg* 2014;19:743–8.
- [16] Hanke T, Charitos EI, Stierle U, Robinson D, Gorski A, Sievers H *et al.* Factors associated with the development of aortic valve regurgitation over time after two different techniques of valve-sparing aortic root surgery. *J Thorac Cardiovasc Surg* 2009;137:314–9.
- [17] Cameron DE, Alejo DE, Patel ND, Nwakanma LU, Weiss ES, Vricella LA *et al.* Aortic root replacement in 372 Marfan patients: evolution of operative repair over 30 years. *Ann Thorac Surg* 2009;87:1344–50.
- [18] De Oliveira NC, David TE, Ivanov J, Armstrong S, Eriksson MJ, Rakowski H *et al.* Results of surgery for aortic root aneurysm in patients with Marfan syndrome. *J Thorac Cardiovasc Surg* 2003;125:789–96.
- [19] Cekmecelioglu D, Coselli JS. Valve-sparing versus valve-replacing aortic root operations in patients with Marfan syndrome. *Shanghai Chest* 2020;4:23.
- [20] Matalanis G, Perera NK. Aortic valve sparing root surgery for Marfan syndrome. *Ann Cardiothorac Surg* 2017;6:682–91.
- [21] Fries R, Graeter T, Aicher D, Reul H, Schmitz C, Böhm M *et al.* *in vitro* comparison of aortic valve movement after valve-preserving aortic replacement. *J Thorac Cardiovasc Surg* 2006;132:32–7.
- [22] Soncini M, Votta E, Zinicchino S, Burrone V, Mangini A, Lemma M *et al.* Aortic root performance after valve sparing procedure: a comparative finite element analysis. *Med Eng Phys* 2009;31:234–43.
- [23] Lansac E, Di Centa I, Sleilaty G, Bouchot O, Arnaud Crozat E, Blin D *et al.* An aortic ring to standardise aortic valve repair: preliminary results of a prospective multicentric cohort of 144 patients. *Eur J Cardiothorac Surg* 2010;38:147–54.
- [24] Lansac E, Di Centa I, Sleilaty G, Lejeune S, Khelil N, Berrebi A *et al.* Long-term results of external aortic ring annuloplasty for aortic valve repair. *Eur J Cardiothorac Surg* 2016;50:350–60.
- [25] Chauvette V, Kluin J, de Kerchove L, El Khoury G, Schäfers H, Lansac E *et al.* Outcomes of valve-sparing surgery in heritable aortic disorders: results from the AVIATOR registry. *Eur J Cardiothorac Surg* 2022; 62:ezac366.
- [26] El Khoury G, Glineur D, Rubay J, Verhelst R, d'Acoz Y, Poncelet A *et al.* Functional classification of aortic root/valve abnormalities and their correlation with etiologies and surgical procedures. *Curr Opin Cardiol* 2005;20:115–21.