

University of Groningen

## The genetics and disease mechanisms of rhegmatogenous retinal detachment

Govers, Birgit M.; van Huet, Ramon A.C.; Roosing, Susanne; Keijser, Sander; Los, Leonoor I.; den Hollander, Anneke I.; Klevering, B. Jeroen

*Published in:*  
Progress in Retinal and Eye Research

*DOI:*  
[10.1016/j.preteyeres.2022.101158](https://doi.org/10.1016/j.preteyeres.2022.101158)

**IMPORTANT NOTE: You are advised to consult the publisher's version (publisher's PDF) if you wish to cite from it. Please check the document version below.**

*Document Version*  
Publisher's PDF, also known as Version of record

*Publication date:*  
2023

[Link to publication in University of Groningen/UMCG research database](#)

*Citation for published version (APA):*

Govers, B. M., van Huet, R. A. C., Roosing, S., Keijser, S., Los, L. I., den Hollander, A. I., & Klevering, B. J. (2023). The genetics and disease mechanisms of rhegmatogenous retinal detachment. *Progress in Retinal and Eye Research*, 97, Article 101158. <https://doi.org/10.1016/j.preteyeres.2022.101158>

### Copyright

Other than for strictly personal use, it is not permitted to download or to forward/distribute the text or part of it without the consent of the author(s) and/or copyright holder(s), unless the work is under an open content license (like Creative Commons).

The publication may also be distributed here under the terms of Article 25fa of the Dutch Copyright Act, indicated by the "Taverne" license. More information can be found on the University of Groningen website: <https://www.rug.nl/library/open-access/self-archiving-pure/taverne-amendment>.

### Take-down policy

If you believe that this document breaches copyright please contact us providing details, and we will remove access to the work immediately and investigate your claim.

*Downloaded from the University of Groningen/UMCG research database (Pure): <http://www.rug.nl/research/portal>. For technical reasons the number of authors shown on this cover page is limited to 10 maximum.*



## The genetics and disease mechanisms of rhegmatogenous retinal detachment

Birgit M. Govers<sup>a,c</sup>, Ramon A.C. van Huet<sup>a</sup>, Susanne Roosing<sup>b,c</sup>, Sander Keijser<sup>a</sup>, Leonoor I. Los<sup>d</sup>, Anneke I. den Hollander<sup>a,e,1</sup>, B. Jeroen Klevering<sup>a,\*</sup>

<sup>a</sup> Department of Ophthalmology, Radboud University Medical Center, Nijmegen, the Netherlands

<sup>b</sup> Department of Human Genetics, Radboud University Medical Center, Nijmegen, the Netherlands

<sup>c</sup> Donders Institute for Brain Cognition and Behaviour, Radboud University Medical Center, Nijmegen, the Netherlands

<sup>d</sup> Department of Ophthalmology, University Medical Center Groningen, Groningen, the Netherlands

<sup>e</sup> AbbVie, Genomics Research Center, Cambridge, MA, USA

### ARTICLE INFO

#### Keywords:

Rhegmatogenous retinal detachment  
Retinal detachment  
Monogenic disease  
Multifactorial disease  
Myopia  
Preventive intervention  
Gene therapy

### ABSTRACT

Rhegmatogenous retinal detachment (RRD) is a sight threatening condition that warrants immediate surgical intervention. To date, 29 genes have been associated with monogenic disorders involving RRD. In addition, RRD can occur as a multifactorial disease through a combined effect of multiple genetic variants and non-genetic risk factors. In this review, we provide a comprehensive overview of the spectrum of hereditary disorders involving RRD. We discuss genotype-phenotype correlations of these monogenic disorders, and describe genetic variants associated with RRD through multifactorial inheritance. Furthermore, we evaluate our current understanding of the molecular disease mechanisms of RRD-associated genetic variants on collagen proteins, proteoglycan versican, and the TGF- $\beta$  pathway. Finally, we review the role of genetics in patient management and prevention of RRD. We provide recommendations for genetic testing and prophylaxis of at-risk patients, and hypothesize on novel therapeutic approaches beyond surgical intervention.

### Funding

This work was supported by Stichting AF Deutman Oogheelkunde Research Fonds, Landelijke Stichting voor Blinden en Slechtzienden, Oogfonds, and Stichting Steunfonds Uitzicht.

### 1. Introduction

Rhegmatogenous retinal detachment (RRD) is a sight threatening condition that warrants immediate surgical intervention. The annual incidence in The Netherlands has been estimated at 18.2 per 100,000, with a peak incidence of 52.5 per 100,000 between 55 and 59 years of age (Van de Put et al., 2013). However, the incidence is rising: a more recent study in the same population found an increase in observed primary RRD of 44%, which could not be explained by differences in age distribution or cataract surgical rate, but a relation with myopic shift in the Dutch population could not be excluded (van Leeuwen et al., 2021).

The incidence of RRD differs between ethnic groups; the lowest annual incidence is found in the South African population with 0.5 per 100,000 (Peters, 1995), and RRD occurs more frequently in men than in women (Mitry et al., 2010a).

Several risk factors have been associated with RRD, including ageing, myopia, severe ocular trauma, previous eye surgery such as cataract removal, and ocular disorders such as lattice degeneration. In addition, there is ample evidence of a genetic predisposition for RRD both in syndromic and non-syndromic monogenic disorders, and in RRD as an idiopathic, multifactorial disease. Retinal detachment is an associated feature in various inherited disorders (Richards et al., 2002); a well-known example is Stickler syndrome. Many studies have investigated the genetic architecture of RRDs in monogenic disorders, and pathogenic variants are frequently identified in collagen genes such as *COL2A1* and *COL11A1*. In addition, genetic risk factors are likely involved in familial RRD, RRD development at a relatively young age, and giant retinal tears. Familial aggregation studies show that RRD can

\* Corresponding author. Department of Ophthalmology, Radboud University Medical Centre (Radboudumc), Geert Grooteplein Zuid 10, 6525 GA, Nijmegen, the Netherlands.

E-mail address: [Jeroen.Klevering@radboudumc.nl](mailto:Jeroen.Klevering@radboudumc.nl) (B.J. Klevering).

<sup>1</sup> Equal contributions.

<https://doi.org/10.1016/j.preteyeres.2022.101158>

Received 25 August 2022; Received in revised form 20 December 2022; Accepted 23 December 2022

Available online 6 January 2023

1350-9462/© 2023 The Authors. Published by Elsevier Ltd. This is an open access article under the CC BY license (<http://creativecommons.org/licenses/by/4.0/>).

cluster in families, and the cumulative lifetime RRD risk doubles when having a relative with RRD (Go et al., 2005; Mitry et al., 2011b). Retinal detachments occur bilaterally in approximately 10% of patients, and this percentage is higher (17%) in RRD patients up to 30 years old (Ferrara et al., 2022; Gupta and Benson, 2005; Mitry et al., 2010a). Patients with RRDs caused by a giant retinal tear (GRT) are predominantly male (90%) and have a particularly high RRD risk for the fellow eye (38%), suggesting a strong sex-related genetic risk [Govers et al., manuscript submitted]. Relatively little is known about the genetic risk factors underlying multifactorial RRD in the general population. Genome-wide association studies (GWAS) that have studied genetic risk factors underlying primary RRD, estimated to explain 23–27% of the heritability (Boutin et al., 2020; Kirin et al., 2013).

In this review, we provide a comprehensive overview of genetic risk factors associated with RRD. After providing a short overview of the relevant anatomy and mechanisms involved in RRD, we evaluate the complex spectra of inherited diseases featuring RRD. We discuss the genes linked to inherited and multifactorial forms of RRD, and describe the protein functions of the underlying genes and their mutational effects on the vitreous, vitreoretinal adhesions and on the retina. We review the spectrum of ophthalmic features associated with inherited RRD and the specific clinical characteristics to improve individual RRD risk assessment. Finally, we provide an outlook on the potential implications of the genetic findings on the treatment and prevention of rhegmatogenous retinal detachment.

## 2. Rhegmatogenous retinal detachment

### 2.1. Definition

A rhegmatogenous retinal detachment (RRD) is defined as a separation of the neurosensory retinal layer from the underlying retinal pigment epithelium (RPE) in the presence of a full-thickness retinal break.

### 2.2. Pathogenesis

The processes that lead to an RRD are complex and involve inherited and age-related changes in the vitreous architecture and vitreoretinal interface. Persistent vitreoretinal adhesions lead to traction and formation of a retinal break, allowing for the influx of fluid thus separating the neuroretina from the underlying RPE.

#### 2.2.1. The vitreous

The vitreous is a gel-like structure consisting of a highly hydrated extracellular matrix (98% water). Type II collagen accounts for 60–75% of the collagen in the vitreous. Other types of collagen include type V/XI, type IX, and small quantities of type VI collagen. Other vitreous constituents are glycosaminoglycans, mainly hyaluronan and small amounts of chondroitin sulfate and heparan sulfate (Le Goff and Bishop, 2008). Hyaluronan is able to aggregate into extended networks that bind large amounts of water. These complexes fill the spaces between the collagen fibrils (Scott et al., 1991). There are two proteoglycans containing a chondroitin sulfate side chain in the vitreous, namely: type IX collagen and versican, the latter is present in large quantities. Overall, collagen fibrils form the scaffold of the vitreous body that is inflated and supported by hyaluronan. The collagen fibrils in the central vitreous generally course in an anterior-posterior direction. The vitreous cortex is a thin layer of 100–300  $\mu\text{m}$  that surrounds the vitreous body and contains densely packed fibrils containing type II, V/XI and IX collagen (Le Goff and Bishop, 2008; Mitry et al., 2010b). Type II and V/XI collagen molecules can cluster into fibrils, and are stabilized by the formation of covalent crosslinks. Lysyl oxidase enzymes (LOX) initiate this cross-link formation by deaminating lysine and hydroxylysine residues (Bella and Hulmes, 2017). Type IX collagen is hypothesized to protect the fibrillar surface by maintaining spacing due to its chondroitin sulfate side chain

(Bishop et al., 2004). The decrease of type IX collagen on the surface of collagen fibrils, associated with ageing in the human vitreous, may allow fibril fusion.

#### 2.2.2. Vitreoretinal adhesions

The vitreoretinal interface is an extracellular matrix structure that contains the cortical vitreous, the end feet of Müller cells and the retinal inner limiting membrane (ILM). There are regional differences in the mechanism of vitreoretinal adhesion. Vitreoretinal adhesion is strongest at the vitreous base where densely packed collagen fibrils intersect radially with the pars plana and anterior retina, forming a sub-ILM network (Le Goff and Bishop, 2008). It is impossible to separate both layers at this location. With age, there is a progressive posterior extension of the vitreous base and interdigitation of collagen fibrils in the peripheral retina. This extension of the vitreous base is more pronounced in men (Wang et al., 2003). At the pre-equatorial and equatorial retina, vitreous fibrils positive for type II collagen focally penetrate the ILM and attach to the superficial retinal layer (Bu et al., 2015a). In addition, ILM-associated collagen type IV focally extends into the vitreous cortex to blend with vitreal collagen fibrils (Bu et al., 2015a). In the posterior vitreous cortex, the collagen fibrils are organized more parallel to the retina. Focal points of attachment are present at areas overlying the optic disc, the macula and the blood vessels (Le Goff and Bishop, 2008; Mitry et al., 2010b). Ponsioen and co-authors observed intraretinal dense packages of type II collagen surrounded by Müller cells in the (pre-) equatorial area, and hypothesized an interactive remodeling process of vitreous and ILM collagens (Ponsioen et al., 2005).

#### 2.2.3. Posterior vitreous detachment

During life, most commonly associated with aging, the vitreous gel-like structure degenerates, starting at the central vitreous (Sebag, 1987). This liquefaction accelerates after age 40 and at age 80, more than half of the vitreous will be liquefied (Sebag, 1987). Two age-related changes are important to this process: collagen degradation and aggregation of collagen fibrils. A decrease in collagen crosslinks, consistent with collagen breakdown, is observed from the age of 50 years and might also contribute to instability of the collagen network in the vitreous (Ponsioen et al., 2009). Additionally, enzymes such as matrix metalloproteinases, and possibly other proteolytic enzymes, are involved in active collagen degradation (van Deemter et al., 2009).

Parallel to the process of vitreous liquefaction, a vitreous dehiscence occurs that usually starts posteriorly (Foods and Wheeler, 1982; Johnson, 2010). If the proper separation of the posterior vitreous membrane from the retina fails, an anomalous posterior vitreous detachment (PVD) occurs that could result in traction on the peripheral retina and may have rhegmatogenous sequelae (Sebag, 2004). More centrally, the vitreous may pull on the macula, optic disc and/or blood vessels. Tangential traction occurs when premacular membranes develop, potentially leading to macular pucker and macular hole (Sebag, 2004; Sebag et al., 2014). It has been estimated that a spontaneous PVD is present in 10–24% of patients aged 50–59 years, climbing to 59–63% and 63–87% in patients aged 70–79 and 80+ years, respectively (Foods and Wheeler, 1982; Hikichi et al., 1995). More recently, however, the concept of vitreoschisis, where part of the cortical vitreous remains attached to the retinal surface, is better recognized on OCT and during vitreoretinal surgery. The inner wall of the vitreoschisis is easily mistaken for the posterior vitreous membrane, thus leading to an overestimation of the actual prevalence of PVD (Kuhn and Aylward, 2014). Floaters and flashes are the hallmark features of symptomatic PVD caused by collapse of the vitreous architecture and dynamic traction on the retina, respectively.

#### 2.2.4. Rhegmatogenous retinal detachment

Attachment of the retina hinges on two main factors: the RPE pumping fluid from the subretinal space to the choriocapillaris and the

adhesion through the interphotoreceptor matrix (IPM) (Cantrill and Pederson, 1984; Hageman et al., 1995; Marmor, 1990). Factors like intraocular pressure and the pressure of the vitreous contribute to a lesser extent (Marmor, 1993). In the pathogenesis of RRD, liquefied vitreous pockets lead to currents in the vitreous cavity and dynamic traction at locations with vitreoretinal adhesion. If the vitreous traction overcomes the tensile strength of the neuroretina, a retinal break will occur. However, most retinal breaks do not lead to RRD: 5–7% of postmortem human eyes showed the presence of a retinal break but no RRD (Okun, 1961). Symptomatic retinal tears following PVD lead to retinal detachment in 90% of eyes, whereas atrophic holes without traction do not cause symptoms and if a retinal detachment occurs, this often remains subclinical (Kuhn and Aylward, 2014). A notable exception are highly myopic eyes where round hole RRDs are more common (Mitry et al., 2011a). Therefore, another key element is vitreoretinal traction, necessary to overcome the RPE pump and IPM and to lift the retina adjacent to the retinal tear allowing intravitreal fluid to enter the subretinal space (Mitry et al., 2010b).

The ocular and genetic risk factors, discussed in the next paragraphs, relate to the pathogenic mechanisms involved in RRD. Therefore, vitreous degeneration, vitreoretinal adhesion, retinal strength and the forces that keep the retina attached may all increase the risk of RRD.

### 2.3. Ocular risk factors

Axial myopia is a well-recognized risk factor for RRD. A large UK Biobank study showed that for each 6 diopter (D) change towards a more myopic refractive error, the retinal detachment risk increased 7.2 fold (Han et al., 2020). High myopia (>−6 D) was present in 17% of RRD eyes in a Scottish study, which is comparable to other European series, but lower than in Asian populations (34%) (Li, 2003; Mitry et al., 2011a). Several factors contribute to the increased risk for RRD in myopic eyes: a PVD occurs on average 10 years earlier with a higher risk of retinal tears, lattice degeneration is significantly associated with high myopia, and the retina is thinner (Akiba, 1993; Ghazi and Green, 2002; Mitry et al., 2011a). In addition, mathematical models show the fluid dynamics in the larger myopic eye lead to larger shear forces (David et al., 1998). The earlier onset of PVD in myopia is explained by an increase of eye volume that exceeds the production of vitreous gel components (Mitry et al., 2010b). In RRD eyes with round, atrophic holes lattice degeneration is almost twice as prevalent (36%) than in eyes with flap tears (19%) (Mitry et al., 2011a). Atrophic round holes are also more frequently present in myopic eyes (Mitry et al., 2011a). They may indicate an intrinsic fragility of the retina, although lattice degeneration also creates focal areas of vitreoretinal traction during a PVD.

Lattice degeneration is a circumferentially and sharply demarcated area of retinal thinning with overlying pockets of liquefied vitreous and firm vitreoretinal adhesion along its border (Lewis, 2003; Mitry et al., 2010b). It is seen in almost 10% of eyes in the normal population worldwide and merely results in RRD, in about 1% (Byer, 1989; Mitry et al., 2010b). Nevertheless, lattice degeneration is significantly associated with retinal detachment and myopia (Mitry et al., 2010b), and is present in 20% of eyes with RRD (Mitry et al., 2011a), and in 9–35% of their fellow eyes (Lewis, 2003). Other retinal peripheral retinal degenerations, such as cystic and zonular traction retinal tufts or increasing white with pressure may also predispose to RRD, though are less extensively studied (Freeman, 1978; Lewis, 2003).

Pseudophakic retinal detachment forms a substantial proportion of RRD and this number is increasing.

The risk of RRD after phacoemulsification is approximately 10 times higher than in the general populations (Qureshi and Steel, 2020). The risk is further elevated (in order of decreasing effect) by vitreous loss during cataract surgery, axial myopia, younger age (especially <55), and male sex (Qureshi and Steel, 2020). The reason for the increased risk in pseudophakic patients is unclear. It has been suggested that the physical effect of replacing the large cataractous lens by a small

intraocular lens induces changes in the vitreous anatomy. In addition, cataract surgery is more likely to induce an anomalous PVD (Mahroo et al., 2012).

The contribution of ocular trauma to RRD varies in literature, but is estimated at round 5% over 6 months (Johnston, 1991). The most likely mechanism is an induced and anomalous PVD; in more severe cases direct retinal damage will cause RRD.

### 2.4. Genetic risk factors

RRD can present as a non-syndromic or syndromic monogenic disorder, where a pathogenic variant with a strong effect on a single gene leads to disease. The proportion of RRD cases related to a monogenic cause is unknown, but is likely limited. Ocular and systemic features of syndromic RRD have been reported in 0.7% of cases, supporting the idea that syndromic forms of RRD are rare (Mitry et al., 2011a). However, in most cases RRD occurs as a multifactorial disease, where the combined effect of multiple genetic variants as well as non-genetic risk factors determines the disease risk. Support for a multifactorial (or polygenic) component comes from two genome-wide associations studies, which estimated that the heritability explained by SNPs is 23–27% (Boutin et al., 2020; Kirin et al., 2013). Genetic risk factors for RRD may be intertwined with myopia, cataract development at a younger age, and lattice degeneration, which are three well-known RRD risk factors with a multifactorial etiology (Hejtmancik and Kantorow, 2004; Meguro et al., 2012; Okazaki et al., 2019; Tedja et al., 2018). The involvement of genetic risk factors in RRD pathogenesis is further substantiated by several lines of evidence: population differences, family history, and sex differences.

Population differences, likely related to ethnicity, suggest a genetic predisposition for the development of RRD. In the Singapore population, inhabitants with an Indian ethnicity showed the lowest annual incidence of 3.9 per 100,000 individuals, while those with a Chinese ancestry displayed the highest annual incidence of 11.6 per 100,000 individuals (Wong et al., 1999). Variation among ethnic backgrounds was also observed in the United Kingdom: individuals originating from India, Pakistan or Bangladesh showed a lower annual incidence of 2.0–4.6 per 100,000 persons compared to Caucasians, with an incidence of 6.3–13.0 per 100,000 persons (Mowatt et al., 2003). The South African population reported the lowest annual incidence of 0.5 per 100,000 individuals (Peters, 1995). Population differences in RRD incidence rates might not only be related to genetic factors, but may also be attributed to other RRD factors, such as the prevalence of myopia, which differs substantially among populations. RRD patients treated in London with a South Asian ethnicity (e.g. India) showed a higher myopic refractive error and more frequently presented with lattice degeneration compared to RRD patients with a European origin (Chandra et al., 2015).

Evidence for the involvement of hereditary factors also stems from family studies. A history of RRD in first-degree family members is reported in 7–8% of RRD patients (Mitry et al., 2011a, 2011b) and, when evaluating all relatives, this percentage increases to 12–13% of RRD patients (Chandra et al., 2015; Mitry et al., 2011b). While individuals without a family history of RRD have a cumulative lifetime RRD risk of 3%, this risk approximately doubles when having a relative with RRD (Go et al., 2005; Mitry et al., 2011b). The increased RRD risk in relatives of RRD patients can partially be attributed to myopia: relatives of RRD patients more often have a myopic refractive error compared to relatives of controls (Go et al., 2005). The sibling risk to develop RRD increases by 10% with each myopic diopter in the proband (Mitry et al., 2011b). Nonetheless, an increased axial length does not fully explain familial occurrence of RRD, since siblings of non-myopic RRD patients also have a two-fold increased RRD risk (Mitry et al., 2011b). Moreover, the higher RRD risk in relatives of myopic RRD patients compared to relatives of myopic probands without RRD suggests that a genetic component independent of myopia is highly plausible (Go et al., 2005).

Several studies show an increased RRD risk in men compared to

women. Approximately 60% of RRD patients are male (Mitra et al., 2010a; Van de Put et al., 2013), and a 90% male preponderance is reported in patients with RRDs caused by a giant retinal tear [Govers et al., manuscript submitted]. The higher RRD risk in men was observed among all studied ethnic backgrounds (Wong et al., 1999). The prevalence of myopia is similar among both sexes according to a meta-analysis performed by the European Eye Epidemiology Consortium (Williams et al., 2015). Yet, a longer axial length in men may contribute to an increased RRD risk (Lee et al., 2009). This is further substantiated by the observation that the increase in RRD incidence in the Netherlands, linked to an increase in myopia prevalence, is more notable in males compared to females (van Leeuwen et al., 2021). The posterior vitreous base widens with age more in men, and this may additionally augment susceptibility of retinal tear development (Wang et al., 2003). The observed sex imbalance might additionally be influenced by a difference in the probability of ocular trauma leading to retinal detachments (Wong et al., 1999). Nevertheless, the overwhelming male dominance of 90% in RRD patients with a giant retinal tear is also observed in non-traumatic cases, suggesting that sex-related genetic risk factors may be located on the X-chromosome [Govers et al., manuscript submitted]. Females with pathogenic variants on the X-chromosome may be less severely affected due to random X-inactivation, and this mosaic pattern leads to pathogenic variants expressed in only part of the cells (Migeon, 2020).

In summary, there are several lines of evidence supporting the assumption that hereditary factors contribute to the development of RRD. While a minority of RRD cases are caused by monogenic inheritance, polygenic risk factors may explain up to a quarter of RRD risk. In

Chapter 3 we discuss the spectrum of ocular phenotypes in monogenic forms of RRD.

### 3. The spectrum of hereditary disorders associated with retinal detachment

The relatively large variability in phenotypes associated with pathologic variants in a single gene and the overlap between phenotypes makes an accessible clinical classification challenging. It is important, however, to recognize phenotypes that carry a considerable risk of retinal detachment and to consider, for instance, prophylactic retinopexy in affected individuals. In this chapter, we discuss syndromic diseases and diseases where the pathology is restricted to the eye that confer an increased risk for retinal detachment. In Table 1, we provide an overview of the ophthalmic and syndromic characteristics associated with the genes that have been implicated in retinal detachment.

#### 3.1. Syndromic disorders associated with retinal detachment

##### 3.1.1. Stickler syndrome

In 1965, the pediatrician Gunnar Stickler described a hereditary arthro-ophthalmopathy that later became known as Stickler syndrome (Stickler et al., 1965). It is estimated to affect approximately 1 in 7500 to 1 in 9000 newborn babies and is currently the most common recognized cause of familial RRD (Printzlau and Andersen, 2004; Robin et al., 2021). Stickler syndrome is a hereditary connective tissue disorder that consists of a spectrum of phenotypes all associated with pathogenic variants in genes that direct the production of collagen, namely type II,

**Table 1**  
Clinical characteristics per gene associated with retinal detachment.

	ADAMTS14	ADAMTS18	BMP4	CHST14	COL2A1	COL3A1	COL9A1/2/3	COL11A1	COL18A1	FBN1	FZD4	GFZ1	KCNJ13	KIF11	LRP2	LRP5	LRPAP1	OAT	P3H1	P3H2	PIOD1	PIOD3	RS1	TINF2	TSPAN2	VCAN	XYLT2	
<b>Syndromic and/or non-syndromic</b>	NS	NS	S	S	NS, S	S	S	S	S	NS, S	NS	S	NS	NS, S	S	NS, S	NS	NS, S	S	NS	S	S	NS	S	NS	NS	S	
<b>Ocular characteristics</b>																												
<b>Refractive error</b>																												
Myopia																												
<b>Vitreous anomalies</b>																												
Membranous phenotype																												
Fibrillar or beaded phenotype																												
Optically empty phenotype																												
Other vitreous abnormalities																												
<b>Lens opacities</b>																												
Early-onset or congenital cataract																												
Quadrantic lamellar cataract																												
<b>Other lens abnormalities</b>																												
Lens subluxation or dislocation																												
Lens coloboma																												
<b>Corneal features</b>																												
Increased central corneal thickness																												
Flat cornea																												
Micro cornea																												
Reduced corneal curvature																												
Corneal guttae																												
<b>Iris abnormalities</b>																												
Iris transillumination defects																												
Iris coloboma																												
Ectopic pupil																												
<b>Abnormalities of the retinal vessels</b>																												
Avascular area peripheral retina																												
Peripheral vascular leakage																												
Straightening of retinal vessels																												
W-pattern or situs inversus																												
<b>Retinal features</b>																												
Peripheral retinal pigmentation																												
Perivascular pigmentary changes																												
Chorioretinal atrophy																												
Snowflake degeneration																												
Lattice degeneration																												
Retinoschisis																												
Cone-rod dysfunction																												
Nyctalopia																												
<b>Syndromic characteristics</b>																												
Hearing loss																												
Facial dysmorphism																												
Palatal abnormalities																												
Skeletal abnormalities																												
Early-onset arthropathy																												
Skull defects or abnormalities																												
Neurological abnormalities																												
Cardiovascular abnormalities																												
Kidney or urinary tract abnormalities																												
Skin abnormalities																												

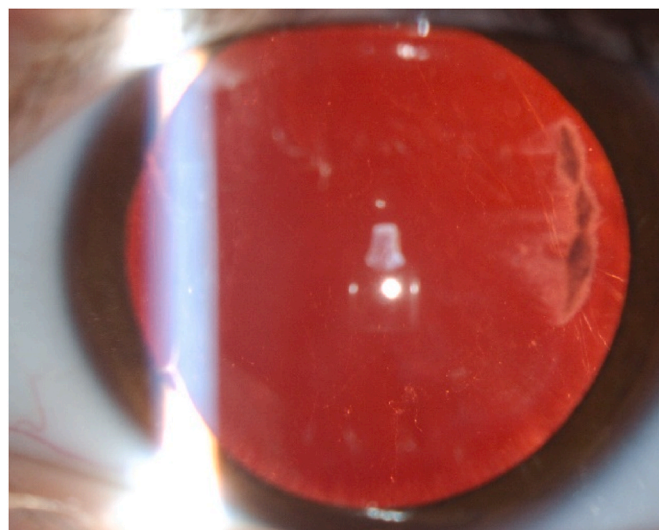
**Abbreviations:** syndromic (S), non-syndromic (NS).  
 Genes highlighted in blue font are associated with inherited disorders that may present with ophthalmic features only.  
**References:** ADAMTS14 (Chandra et al., 2012; Christensen et al., 2010; Radahl et al., 1993); ADAMTS18 (Chandra et al., 2014); BMP4 (Nixon et al., 2019b); CHST14 (Janecke et al., 2016); COL2A1 (Boothe et al., 2020; Edwards et al., 2012; Go et al., 2003; Maumenee and Traboulsi, 1985; Richards et al., 2005; Robin et al., 2005); COL3A1 (Lumi et al., 2021); COL9A1/2/3 (Baker et al., 2011; Faletta et al., 2014; Hanson-Kahn et al., 2018; Khan et al., 2021; Kjellstrom et al., 2020; Markova et al., 2021; Nash et al., 2021; Nikopoulos et al., 2011; Nixon et al., 2019a; Van Camp et al., 2006); COL11A1 (Annunen et al., 1999; Majava et al., 2007; Richards et al., 2021); COL18A1 (Hull et al., 2016); FBN1 (Esfandiari et al., 2019; Judge and Dietz, 2005; Stephenson et al., 2019); FZD4 (Chen et al., 2019; Edwards et al., 2012; Gilmore, 2015; Yuan et al., 2017); GFZ1 (Patel et al., 2017); KCNJ13 (Lee et al., 2003); KIF11 (Chen et al., 2020); LRP2 (Khan and Ghaz, 2018; Patel et al., 2007; Schrauwen et al., 2014); LRP5 (Chen et al., 2019; Gilmore, 2015; Papadopoulos et al., 2019); LRPAP1 (Khan et al., 2021; Magliyah et al., 2020); OAT (Magliyah et al., 2021); P3H1 (Scallo et al., 2018); P3H2 (Guo et al., 2014; Khan et al., 2014; Mardochai et al., 2011); PLOD1 (Yeowell and Steinmann, 2018); PLOD3 (Ewans et al., 2019); RS1 (Hahn et al., 2022); TINF2 (Supta et al., 2017); TSPAN2 (Chen et al., 2019; Gilmore, 2015; Yuan et al., 2017); VCAN (Graemiger et al., 1995; Hirose et al., 1973; Kloeckener-Gruissem and Amstutz, 2016; Ronan et al., 2009); XYLT2 (Guleray et al., 2019; Munns et al., 2015; Umair et al., 2018).

XI, and IX. Pathogenic variants affecting these collagen proteins typically cause a combination of ocular-, orofacial-, auditory- and skeletal abnormalities, although the expression is variable. The Stickler syndrome phenotypes can be categorized per causative gene: *COL2A1* encodes for all three alpha chains of type II collagen, as well as one alpha chain of type XI collagen; *COL11A1* and *COL11A2* encode two out of three alpha chains of type XI collagen; and *COL9A1*, *COL9A2*, and *COL9A3* each encode one alpha chain of type IX collagen. The complementary function of these collagens underlies the overlapping Stickler syndrome phenotypes.

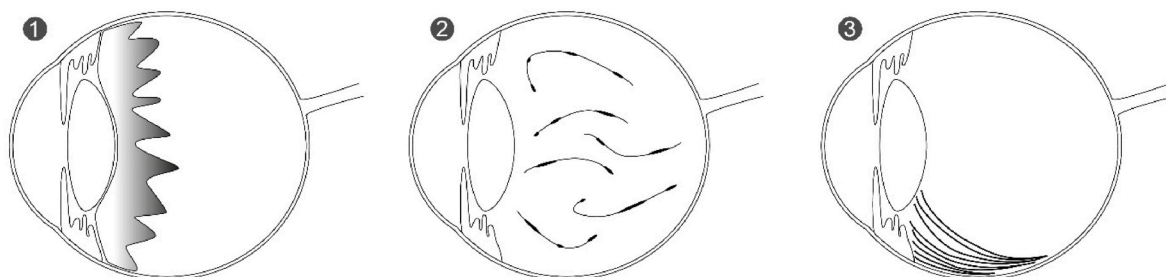
There are no agreed diagnostic criteria for Stickler syndrome, although an attempt has been made for *COL2A1*-associated forms (Rose et al., 2005). These, however, are not validated and lack discriminative power. The proposed diagnostic criteria for Stickler syndrome include orofacial, ocular, auditory and skeletal features, as well as genetic features. However, some features are not a distinguishable characteristic in all geographical areas. Flat or broad facial features, for example, are frequently encountered in the general population in Southeast Asia (Zhou et al., 2018). The typical vitreous phenotypes may be a key factor in differentiating *COL2A1*- or *COL11A1*-related Stickler syndrome (Richards et al., 2010). However, vitreous abnormalities may be absent in young patients with *COL2A1* or *COL11A1* pathogenic variants, requiring additional diagnostic clues to facilitate the diagnosis of Stickler syndrome (Zhou et al., 2018). A combination of genetic findings and distinguishing phenotypic findings, both ocular and systemic, allows for identification of Stickler syndrome variants that may confer a high risk for vision loss. Most, but not all Stickler patients develop myopia. Early-onset high myopia is the most reliable ocular feature and is, in combination with hypermobility of the elbow joint, highly suggestive for Stickler syndrome, even in the absence of vitreous abnormalities (Zhou et al., 2018). Snead et al. recently formulated the following categories where Stickler syndrome should be suspected: RRD patients with a family history of RRD; infants with congenital myopia and deafness; infants with Pierre Robin sequence (underdeveloped jaw, backward displacement of the tongue and upper airway obstruction) or cleft palate in association with myopia; and infants with joint hypermobility and/or epiphyseal dysplasia in association with myopia (Snead et al., 2021).

**3.1.1.1. *COL2A1*-related stickler syndrome.** The *COL2A1* form is by far the most commonly encountered type of Stickler syndrome in clinical practice: approximately 80–90% of cases can be attributed to pathogenic variants in this gene (Robin et al., 2021). *COL2A1*-related Stickler syndrome is inherited in an autosomal dominant fashion. Abnormalities can be confined to the eye (Stickler – ocular only) or additional multi-systemic features may be present (Stickler type 1). Approximately two-thirds (60–70%) of patients with *COL2A1*-associated Stickler will develop an RRD, and half of these patients develop bilateral retinal detachment (Boothe et al., 2020). The highest risk for retinal

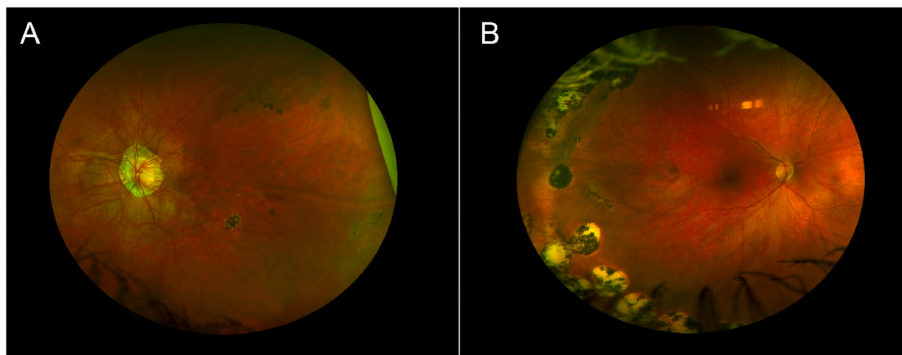
detachment lies between the ages of 10–30 years (Abeyesiri et al., 2007; Stickler et al., 2001). Patients are specifically at risk of developing giant retinal tears. Other ocular findings include (congenital) axial myopia in 80%, vitreous abnormalities in 40–100%, and cataract in 40% of patients (Hoornaert et al., 2010; Rose et al., 2005; Snead et al., 2011). The refractive error is usually non-progressive, high (–10 diopters or worse in 40%) and has a considerable astigmatic component (Boysen et al., 2020; Snead et al., 2011; Snead and Yates, 1999). Congenital vitreous abnormalities manifest as an abnormal architecture on slit lamp investigation. They usually consist of a vestigial gel in the retrolental space bounded by a convoluted membrane (Fig. 1) (Snead and Yates, 1999). Vitreous hypoplasia, defined as congenital abnormality with a less dense gel that appears optically empty or with an irregular lamellar architecture, has been described in *COL2A1*-associated Stickler syndrome as well, and may resemble the syneresis in aging and myopic eyes (Richards et al., 2010). A (congenital) quadrantic lamellar cortical cataract is a typical sign and is seen in 19% of phakic eyes (Fig. 2), however, other lens opacities such as premature nuclear sclerosis and posterior subcapsular opacification are also common, 21% (Seery et al., 1990; Snead et al., 2011). Perivascular pigmentary changes (Fig. 3), can be key to identify patients with the ocular-only variant of Stickler syndrome (Parma et al., 2002; Snead and Yates, 1999; Vu et al., 2003). Fundus autofluorescence (FAF) imaging shows hyper- and hypo-AF changes in 81% of eyes with *COL2A1*-related Stickler syndrome, that corresponded with the observed radial paravascular retinal



**Fig. 2.** Quadrantic lamellar cortical cataract in a patient with *COL2A1*-related Stickler syndrome.



**Fig. 1.** Schematic overview of three vitreous phenotypes. 1) A congenital membranous vitreous anomaly, typically seen in *COL2A1*-related Stickler syndrome, with an apparently vestigial gel in the retrolental space that is bounded by a folded membrane. 2) A 'beaded' vitreous anomaly typically seen in *COL11A1*-related Stickler syndrome with sparse, and irregular thickened fibrils throughout the vitreous cavity. 3) A vitreous phenotype typically seen in VCAN-related vitreoretinopathy with fibrillar vitreous condensations behind the lens, which turns into a faint veil or membrane that remains attached to the retina equatorially. The vitreous condensations are accompanied by extensive liquefaction in other parts.



**Fig. 3.** Imaging of 2 patients with Stickler syndrome. **Image A:** Wide field fundus imaging of the left eye from a 28-year-old female with COL2A1-related Stickler syndrome. Typical paravascular pigmentations are located in the temporal superior area, a dot-shaped pigmentation inferiorly located, and snail-track degeneration in the temporal periphery. **Image B:** Wide field fundus imaging of the right eye from a 20-year-old female with Stickler syndrome. Paravascular pigmentation is visible in the temporal periphery, located centrally from the cryocoagulation scars.

degeneration (Fujimoto et al., 2021). Therefore, FAF can be a useful tool to detect these degenerative changes more easily. In addition, circumferential lattice degeneration is a frequent finding (43%) in eyes with Stickler syndrome (Edwards, 2008; Vu et al., 2003). Foveal hypoplasia defined as persistent inner retinal layers with a reduced or absent foveal pit was identified in 82% of eyes with COL2A1-related stickler syndrome, and may vary from mild to severe (Asano et al., 2022; Matsushita et al., 2017). Congenital abnormalities of the anterior chamber drainage angle, increasing the risk for glaucoma, have been described but are uncommon (Snead et al., 2011).

Studies on RRD associated with pathogenic variants in COL2A1, leading to an ocular-only phenotype, have also been published as ‘autosomal dominant RRD’ (Go et al., 2003; Richards et al., 2005). The vitreous phenotype in these cases is inconsistent, described as an optically empty appearance with condensation equatorial, or an optically thin vitreous with a retrolental membrane, threads, and very fine beads (Edwards et al., 2012; Go et al., 2003; Richards et al., 2005).

In the ‘ocular-only’ phenotype, systemic findings are subclinical or absent (Edwards et al., 2012; Go et al., 2003; Richards et al., 2000, 2005). In Stickler type 1, the extra-ocular findings typically include midfacial hypoplasia (72–84%), hearing loss (45–76%), palatal abnormalities (53–64%), premature arthropathy (42–60%), and joint hypermobility (20–92%) (Čopíková et al., 2020; Hoornaert et al., 2010; Rose et al., 2005).

**3.1.1.2. COL11A1-related stickler syndrome.** The second most frequent cause of Stickler syndrome (10–20%) are pathogenic variants in COL11A1 (Robin et al., 2021). COL11A1-related Stickler syndrome, also termed Stickler type 2, is usually inherited in an autosomal dominant fashion (Robin et al., 2021). Recessive COL11A1 mutations lead to a usually lethal condition called fibrochondrogenesis, but due to alternative splicing recessive cases of COL11A1-related Stickler syndrome with profound hearing loss have been identified (Nixon et al., 2020; Richards et al., 2013). The risk of retinal detachment is lower compared to COL2A1-related Stickler, but RRD still develops in approximately 40% of patients (Annunen et al., 1999; Boothe et al., 2020; Poulson et al., 2004). RRD in COL11A1-related Stickler syndrome occurs on average at the age of 34 years (range: 9–55) (Poulson et al., 2004). There is significant phenotypic overlap between the COL2A1 and COL11A1-related Stickler syndromes, which may be explained by the complementary functions of proteins encoded by these genes. Yet, the distinctive vitreous phenotype can be helpful to differentiate between these types of Stickler syndrome. Pathogenic variants in COL11A1 typically result in a ‘beaded’ vitreous phenotype with sparse and irregular thickened fibrils throughout the vitreous cavity (Fig. 1) (Snead and Yates, 1999), but hypoplastic vitreous has been described in COL11A1-associated Stickler syndrome as well (Richards et al., 2010). Other typical ocular findings such as axial myopia and congenital cataract, do not differentiate between COL2A1 and COL11A1-related Stickler syndromes (Rose et al., 2005; Snead et al., 2011). However, the

degree of axial myopia is usually less severe in COL11A1 than in COL2A1-related Stickler syndrome (Boysen et al., 2020). Pigmented paravascular (lattice) degeneration is seen in 38% of patients (Poulson et al., 2004).

Hearing loss occurs in 75–80% of cases (Poulson et al., 2004; Rose et al., 2005) and is suggested to be more common and more profound compared to COL2A1-related Stickler (Boothe et al., 2020; Hoornaert et al., 2010; Majava et al., 2007). Although this is a potentially useful discriminating sign (Annunen et al., 1999), hearing loss may remain mild and asymptomatic (Poulson et al., 2004).

**3.1.1.3. COL11A2-related stickler syndrome.** COL11A2-related Stickler syndrome is also known as ‘non-ocular’ Stickler syndrome type 3 or otospondylomegaepiphyseal dysplasia. There is no ocular involvement, since COL11A2 is not expressed in the eye.

**3.1.1.4. COL9A1-, COL9A2-, and COL9A3-related stickler syndrome.** To date pathogenic variants in COL9A1, COL9A2 or COL9A3 have been identified in 41 patients with autosomal recessive Stickler syndrome, although dominant COL9A3 cases have been described (Baker et al., 2011; Faletta et al., 2014; Hanson-Kahn et al., 2018; Khan et al., 2021; Kjellstrom et al., 2020; Markova et al., 2021; Nash et al., 2021; Nikopoulou et al., 2011; Nixon et al., 2019a; Van Camp et al., 2006). These three genes each encode a type IX collagen alpha chain. The Stickler syndromes caused by pathogenic variants in these genes have been differentiated: COL9A1 (Type 4), COL9A2 (Type 5), and COL9A3 (Type 6). The risk of retinal detachment is much lower in these patients and is estimated at 8% (Baker et al., 2011; Faletta et al., 2014; Hanson-Kahn et al., 2018; Khan et al., 2021; Kjellstrom et al., 2020; Markova et al., 2021; Nikopoulou et al., 2011; Nixon et al., 2019a; Van Camp et al., 2006), although this may be an underestimation since the majority of the reported patients were still quite young (<20 years). A higher RRD risk (41%) was observed in two families with dominantly inherited pathogenic variants affecting COL9A3 (Nash et al., 2021). High myopia is present in all recessive cases, but not all dominant cases. The vitreous phenotype is variable, ranging from normal to a liquefied vitreous with membranous veils or fibrillar condensates as in age-related vitreous degeneration, to a hypoplastic vitreous. Sensorineural hearing loss is currently identified in all recessive and some dominant cases, and appears more profound and presents at a younger age compared to COL2A1 and COL11A1-related Stickler syndrome (Nixon et al., 2019a).

**3.1.1.5. Other genes associated with stickler syndrome.** Several non-collagen encoding genes are associated with phenotypes overlapping with Stickler syndrome, namely BMP4, LOXL3, LRP2 and PLOD3 (Alzahrani et al., 2015; Chan et al., 2019; Ewans et al., 2019; Nixon et al., 2019b; Schrauwen et al., 2014). These genes encode proteins involved in the posttranslational modification of collagens or the TGF- $\beta$  pathway (see section 5.1.2. and 5.3.). Although certain clinical characteristics such as high myopia, RRD, vitreous abnormalities, hearing loss,

and palatal abnormalities are also found in Stickler syndrome, other features such as renal dysplasia (Nixon et al., 2019b), proteinuria (Schrauwen et al., 2014), and vascular dissection (Ewans et al., 2019), are typically not. Snead et al. categorized the *BMP4*- and *LOXL3*-associated phenotypes as Stickler type 7 and 8, respectively (Snead et al., 2021). Whether these syndromes should truly be considered part of the Stickler spectrum, remains largely a matter of taste. It is important, however, to consider these genes when genetic analysis does not identify pathogenic variants in any of the collagen Stickler syndrome genes. We describe the genotype-phenotype correlations of these cases in section 4.1.2. and 4.1.4. The phenotype related to biallelic pathogenic variants in *LOXL3* is not further described, since this gene is not yet related to any case of retinal detachment in literature (Alzahrani et al., 2015; Chan et al., 2019).

### 3.1.2. Kniest dysplasia

The dominantly inherited Kniest dysplasia is also caused by pathogenic variants in *COL2A1*, like the most common form of Stickler syndrome type 1. Both ocular phenotypes show significant overlap and are likely to have similar ocular morbidity (Sergouniotis et al., 2015). The vitreous in Kniest dysplasia is also frequently characterized by a membranous vitreous anomaly in the retrolental space, although hypoplastic vitreous with reduced lamellae and a fibrillar cortex has also been described (Mauumenee and Traboulsi, 1985; Sergouniotis et al., 2015). There is an increased risk of retinal detachment (approximately 36%), which often develops during the first decade of life (Mauumenee and Traboulsi, 1985; Sergouniotis et al., 2015). Almost all Kniest dysplasia patients have a highly myopic refractive error and approximately half of the patients exhibit extensive lattice degeneration. In two cases subluxated lenses were noted (Mauumenee and Traboulsi, 1985; Sergouniotis et al., 2015). Palatal cleft abnormalities and severe hearing impairment are similar to *COL2A1*-related Stickler syndrome, but the skeletal abnormalities are more severe and characterized by disproportionate short stature or short-trunked dwarfism, kyphoscoliosis, and prominent large joints (Sergouniotis et al., 2015). The genetic differences between Kniest dysplasia and *COL2A1*-related Stickler syndrome are discussed in section 4.1.1.1.

### 3.1.3. Marshall syndrome

Pathogenic variants in *COL11A1* can cause Marshall syndrome, an autosomal dominantly inherited disorder. The phenotypic spectrum of Marshall and *COL11A1*-related Stickler syndrome overlap, which led to the term Marshall-Stickler syndrome (Čopíková et al., 2020; Guo et al., 2017; Janssen et al., 2021; Majava et al., 2007). There are, however, clinical and mutational differences to consider Marshall syndrome as a distinct entity (Annunen et al., 1999; Aymé and Preus, 1984; Rose et al., 2005). Ocular features are comparable, but the risk of retinal detachment in Marshall syndrome is lower than in *COL11A1*-related Stickler: 10–25% compared to 40% (Annunen et al., 1999; Majava et al., 2007). Furthermore, the Marshall syndrome cases more often have a short stature, abnormalities in cranial ossification and more profound dysmorphic facial features such as a prominent forehead and retracted maxillae resulting in a bulging eyes appearance, retracted midface with flat nasal bridge, a short nose, anteverted nostrils and a long philtrum (Annunen et al., 1999; Aymé and Preus, 1984). Ocular hypertelorism and ectodermal dysplasia have been appointed as the features differentiating Marshall from Stickler and other syndromes (Shanske et al., 1997). However, these are not consistently present, and e.g. ocular hypertelorism is also described in cases with phenotypical features of both Marshall and Stickler syndrome (Annunen et al., 1999; Čopíková et al., 2020; Majava et al., 2007). The genetic differences between Marshall syndrome and *COL11A1*-related Stickler syndrome are discussed in section 4.1.1.1.

### 3.1.4. Knobloch syndrome

Pathogenic variants in *COL18A1* can result in a recessively inherited

disorder described by Knobloch and Layer in 1971 (Knobloch and Layer, 1971). The Knobloch syndrome (type 1) is relatively rare and characterized by high myopia, vitreoretinal degeneration, and occipital skull defects (Hull et al., 2016; Khan et al., 2012; White et al., 2017). Typical vitreoretinal degenerative manifestations include diffuse RPE atrophy, macular atrophic lesions, and white fibrillar vitreous condensations (Khan et al., 2012). A variety of other ocular findings are associated with Knobloch syndrome including myopia, early-onset cataract, lens subluxation, pigment dispersion syndrome, absence of iris crypts, iris transillumination, persistent pupillary membranes, and cone-rod dysfunction (Hull et al., 2016; Khan et al., 2012; White et al., 2017). These may lead to nystagmus and severe visual impairment due to complications such as early retinal detachment and childhood-onset glaucoma (Hull et al., 2016; White et al., 2017). Of twelve patients, that were reviewed at an average age of 16 years, five already had developed retinal detachment (Hull et al., 2016). A serous retinal detachment was reported in a male patient of only seven months old (White et al., 2017). Systemic findings include occipital skull defects with or without occipital encephalocele, cutaneous occipital abnormalities such as alopecia, polymicrogyria, epilepsy, and learning difficulties (Hull et al., 2016; Khan et al., 2012; White et al., 2017).

### 3.1.5. Marfan syndrome

Pathogenic variants in *FBN1* are associated with Marfan syndrome, a connective tissue disorder manifesting in approximately 2–3 per 10,000 individuals (Judge and Dietz, 2005). It inherits typically in an autosomal dominant fashion though a family history might be absent since a quarter of patients have pathogenic *de novo* variants (Arnaud et al., 2017; Judge and Dietz, 2005). There are two key phenotypical diagnostic criteria: ectopia lentis and aortic root dilatation or dissection (Loeys et al., 2010). Ectopia lentis develops in about 60% of Marfan cases, which is diagnosed during their teens in the majority of patients (Drolsum et al., 2015; Milewicz et al., 2021). The lens subluxation generally is supero-temporal and accommodation is retained (Sadiq and Vanderveen, 2013). A myopic refractive error is present in 34–44% of patients (Esfandiari et al., 2019). In adult patients this results from an increased axial length (Drolsum et al., 2015). Common anterior segment features include a reduced corneal curvature (K-value <41.5D in 47%) (Drolsum et al., 2015), corneal and lens-related astigmatism, iris transillumination defects (20%), and ciliary muscle hypoplasia causing decreased miosis (Judge and Dietz, 2005; Salchow and Gehle, 2019). Marfan syndrome is associated with an increased risk of retinal detachment, occurring in 5–26%, and frequently both eyes are affected: in 30–42% (Esfandiari et al., 2019). The average age at which retinal detachment occurs is 26 years, and 70% of patients are 30 years or younger (Dotrelova et al., 1997; Sharma et al., 2002). The majority of Marfan cases with a retinal detachment have ectopia lentis, which exerts traction on the vitreous base (Drolsum et al., 2015; Remulla and Tolentino, 2001; Sharma et al., 2002). Other predisposing features for retinal detachment are the increased axial length and its associated complications of early vitreous liquefaction, posterior vitreous detachment, retinal thinning, and lattice degeneration; as well as aphakia (Esfandiari et al., 2019). Besides aortic pathology, Marfan syndrome is associated with various other non-ocular findings including disproportionate long bone overgrowth, scoliosis or thoracolumbar kyphosis, pneumothorax, facial features such as malar hypoplasia and retrognathia, arachnodactyly, skin striae, and mitral valve prolapse (Loeys et al., 2010).

## 3.2. Inherited ocular disorders associated with retinal detachment

### 3.2.1. *VCAN*-related vitreoretinopathy

The autosomal dominantly inherited Wagner disease and erosive vitreoretinopathy (ERVR) are allelic disorders both associated with pathogenic variants in the *VCAN* gene (Kloekener-Gruissem et al., 2006; Mukhopadhyay et al., 2006); the family described by Jansen,



sometimes referred to as Jansen syndrome, maps to the same chromosome 5q14.3 region as Wagner disease (Jansen, 1962; Perveen et al., 1999). They form a phenotypic continuum referred to as *VCAN*-related vitreoretinopathy, characterized by progressive vitreoretinal degeneration without systemic abnormalities. The phenotype typically features an ‘optically empty vitreous’ with vitreous veils (Graemiger et al., 1995). Other features include mild to moderate myopia (80%), various types of cataract (45%), an abnormal retinal vascular pattern with a typical W-pattern (Fig. 4), sometimes referred to as a *situs inversus* (54%), pseudo strabismus related to an ectopic fovea, isolated pigment clumping and perivascular pigmentation and sheathing, retinal thinning, and chorioretinal atrophy (Graemiger et al., 1995; Hirose et al., 1973; Li et al., 2020; Meredith et al., 2007; Miyamoto et al., 2005; Ronan et al., 2009). Loss of retinal pigment epithelium and choriocapillaris can be observed on fluorescein angiography, as well as a rod-cone pattern on electroretinography (ERG) (Graemiger et al., 1995). In addition to these features, ERVR also presents progressive choriocapillaris and RPE atrophy, night blindness and visual field constriction (Brown et al., 1994; Mukhopadhyay et al., 2006; Ronan et al., 2009). Severe clinical presentations of *VCAN*-related vitreoretinopathy may resemble retinitis pigmentosa or choroideraemia (Graemiger et al., 1995; Ronan et al., 2009).

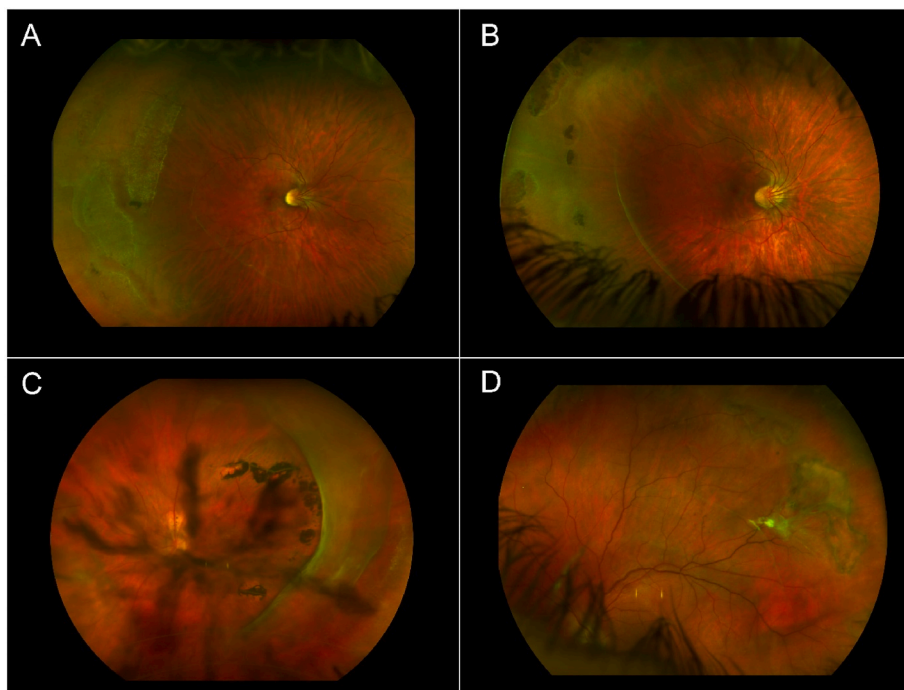
The vitreous abnormalities in *VCAN*-related vitreoretinopathies vary with age. In patients older than 30 years of age circumferentially oriented avascular vitreous strands and veils can be seen (Fig. 1). This is likely a result of the progressive vitreous degeneration that begins in childhood. In patients younger than 30 years, fibrillar vitreous condensations reflect the early degenerative changes of the vitreous (Graemiger et al., 1995). These condensations are accompanied by extensive liquefaction in other parts, eventually giving the impression of an optically empty vitreous. The condensed vitreous turns into a faint veil or membrane floating in the vitreous that remains attached to the retina equatorially. This membrane fuses with the condensed vitreous located behind the lens (Hirose et al., 1973).

There is an increased risk for tractional and rhegmatogenous RDs, developing in approximately 27–50% of patients with *VCAN*-related vitreoretinopathy, although this varies greatly among families (Brown et al., 1995; Graemiger et al., 1995; Hirose et al., 1973;

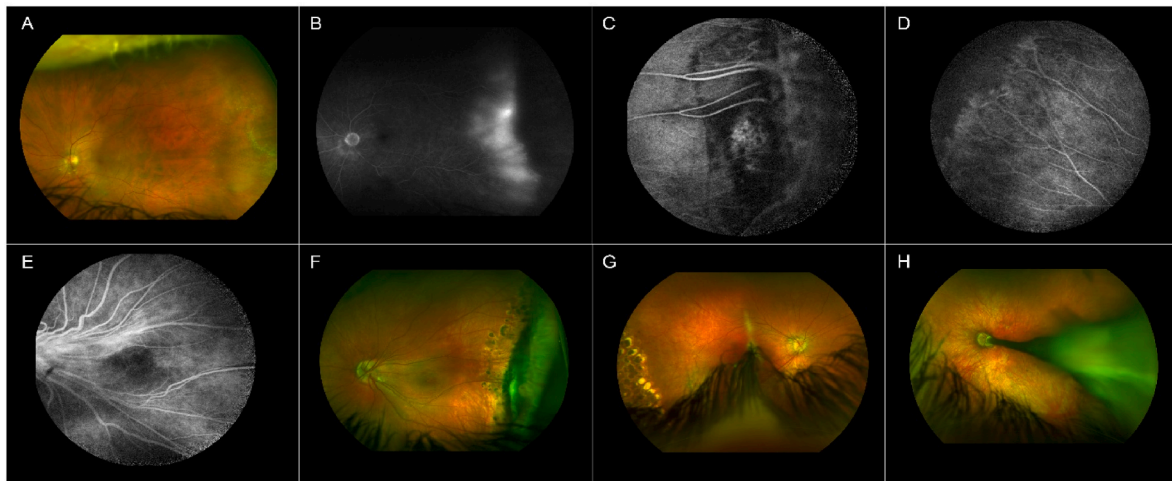
Kloekener-Gruissem and Amstutz, 2016; Miyamoto et al., 2005). In the original family reported by Graemiger and colleagues, the average age at which rhegmatogenous and tractional retinal detachment occurred was 20 and 49 years, respectively (Graemiger et al., 1995). More recent publications indicate significant younger ages at which retinal detachments occur, on average at 10 years (Burin-des-Roziers et al., 2017; Li et al., 2020; Meredith et al., 2007; Ronan et al., 2009). Tractional retinal detachments seemed to be due to organization and contraction of (mid)peripheral vitreoretinal adhesions and the peripheral retina seemed poorly vascularized. A Coats-like exudative retinopathy is seen in some of these patients (Graemiger et al., 1995). Visual acuity and chorioretinal findings can remain normal up to late adolescence, though significant loss of vision often occurs before the 5th decade of life. In a follow-up study of a pedigree originally reported by Wagner, a visual acuity of 20/40 or less was reported in 55% of all affected individuals older than 45 (Graemiger et al., 1995).

### 3.2.2. Familial exudative vitreoretinopathy

The hallmark of familial exudative vitreoretinopathy (FEVR) is a peripheral retinal avascularity in the temporal region that is variable in severity, often in a V-shaped pattern with the apex pointing posteriorly. In cases with severe retinal ischemia, secondary neovascularization may occur with subsequent fibrosis that may lead to traction on the macula, tractional retinal detachment, retinal folds and retinal dysplasia in severe cases (Fig. 5) (Benson, 1995; Gilmour, 2015; Miyakubo et al., 1984). FEVR has been associated with at least seven genes (*LRP5*, *TSPAN12*, *NDP*, *FZD4*, *KIF11*, *ZNF408*, and *RCBTB1*) (Chen et al., 2019; Qu et al., 2022; Wu et al., 2016). The inheritance pattern can be autosomal dominant, autosomal recessive, or X-linked (Chen et al., 2019; Gilmour, 2015). The expression may be asymmetric and it is estimated that 50% of patients remain asymptomatic (Benson, 1995). The diagnosis is based on the presence of an avascular peripheral retina in at least one eye in patients of any age who are born at full term, or, in case of prematurity, with disease characteristics not consistent with retinopathy of prematurity (ROP) (Gilmour, 2015). A retinal detachment may develop in 21–64% of FEVR patients, which can be tractional, exudative, or rhegmatogenous in nature (Gilmour, 2015). Tractional and exudative RDs are related to severe FEVR pathology with extensive retinal



**Fig. 4.** Wide field fundus imaging of 4 patients with *VCAN*-related vitreoretinopathy. **Image A.** The right eye of a 18-year-old female with Wagner vitreoretinopathy. The typical ‘W-pattern’ of the vascular arcade is obvious. The peripheral retina shows snail-track degeneration and infero-temporal a vitreous veil can be observed. **Image B.** The right eye of a 12-year-old female with Wagner vitreoretinopathy. The vascular arcade shows the typical W-pattern. A vitreous condensate, more profound compared to image A, is visible in the midperiphery. The peripheral retina shows pigmentations. **Image C.** The left eye of a 41-year-old female with a more severe clinical presentation on the spectrum of *VCAN*-related vitreoretinopathy, classified as ERVR. There are anterior vitreous condensations as well as a thick vitreous veil in the temporal quadrants. The retina shows chorioretinal atrophy with irregular pigment clumping. **Image D.** The left eye of a 21-year-old male with Wagner vitreoretinopathy. There are peripheral retinal degenerations visible. There is retinal traction temporal superior resulting in a retinoschisis with an inner layer defect. A thin vitreous condensate is attached to the retina just central to the degenerative area.



**Fig. 5.** Imaging of 3 patients with familial exudative vitreoretinopathy (FEVR).

**Images A and B.** Wide field fundus (A) and fluorescein angiography (B) imaging of the left eye from a 63-year-old male with FEVR. A pathogenic frame shift variant in *FZD4* and a missense variant of unknown pathogenicity in *TSPAN12* were identified. This patient had a history of giant retinal tear retinal detachment in the contralateral eye. **A:** In the temporal periphery there is a ‘U’ shaped area with retinal degeneration. **B:** There is neovascularization with vascular leakage, located at the nasal side of the temporal peripheral avascular zone.

**Image C, D, E, F.** Fluorescein angiography (C, D, E) and wide field fundus (F) imaging of the left eye from a female with FEVR, at age 7 (C, D, E) and at age 11 (F). A heterozygous pathogenic variant in *ZNF408* was identified in this patient. **C and D:** peripheral retinal nonperfusion and low angle bifurcations of the vessels in image C. **E:** straightening of the central retinal vessels towards the temporal periphery. **F:** Temporal dragging of the central retinal arcade vessels. In the temporal peripheral retina, old laser coagulates and a fibrotic membrane are visible.

**Images G and H.** Wide field fundus imaging of the right (G) and left (H) eye from a 3-year-old male patient with FEVR. The father of this patient was also diagnosed with FEVR and had a heterozygous pathogenic variant in *LRP5*. **G:** The right eye shows mild dragging of the retina with mild straightening of the central retinal arcade vessels. The peripheral retina shows old laser coagulates. **H:** The left eye shows severe dragging of the retina with a falciform membrane that runs from the optic disc, through the macula, towards the temporal periphery.

ischemia and leaky abnormal vessels, while the rhegmatogenous variants are assumed to represent a relatively mild phenotype of FEVR (Chen et al., 2019). The average age at which FEVR-RRDs develop is 22 years, and approximately 80% are under 30 years (Chen et al., 2019; Yuan et al., 2017). It is the most common hereditary cause for RRDs in the pediatric ( $\leq 18$  years) population in China (Chen et al., 2020a). Retinal defects observed in FEVR-RRD are most frequently round retinal holes (71%); horseshoe tears (22%) and giant retinal tears (7%) are observed less frequently (Yuan et al., 2017). In 90% of FEVR-RRDs, the fellow eye is asymptomatic, although 75% of these eyes show vascular leakage on the fluorescein angiogram (Yuan et al., 2017). Additionally, 54% of fellow eyes showed lattice degeneration at the border of the temporal peripheral vascular- and avascular area (Chen et al., 2019; Yuan et al., 2017). The subclinical manifestations of FEVR potentially lead to underdiagnosis in clinical practice (Chen et al., 2019, 2020a). Pathogenic variants in *LRP5* appear to be the major cause in FEVR-RRD. In a next generation sequencing study in Chinese patients, Chen and colleagues found pathogenic variants in *LRP5* (26%), in *FZD4* (7%), and *TSPAN12* (6%) (Chen et al., 2019). They could not identify a pathogenic variant in any of the currently known FEVR genes in 60% (Chen et al., 2019). Pathogenic variants in *LRP5* are also associated with osteopenia and osteoporosis, it is therefore recommended to assess bone mineral density to prevent bone fractures (Gilmour, 2015).

### 3.2.3. Snowflake vitreoretinal degeneration

Crystalline deposits in the peripheral retina are the hallmark feature of snowflake vitreoretinal degeneration (SVD). This disorder shows autosomal dominant inheritance and has phenotypical overlap with both Wagner disease and Stickler syndrome. Apart from the original family with SVD (Hirose et al., 1974; Jiao et al., 2004; Lee et al., 2003) only few families with phenotypes compatible with SVD have been described (Pollack et al., 1983; Robertson et al., 1982). Like in Wagner disease and ‘ocular-only’ *COL2A1*-related Stickler, there are no systemic abnormalities in SVD. The peripheral retinal abnormalities (present in

83% of SVD patients) consist of peripheral areas of white without pressure (WWP) and minute, brilliant yellow-white deposits that resemble snowflakes, mainly visible with scleral depression. In later stages, pigmentations and sheathing of retinal vessels occur, finally resulting in the disappearance of vessels. The absence of vitreous gel in the retrolental space with fibrillar vitreous degeneration in all patients resembles the findings in *COL11A1*-related Stickler (Lee et al., 2003). In 2008, the underlying genetic defect in SVD was located in *KCNJ13*, a gene encoding a potassium channel (Hejtmancik et al., 2008).

Patients with SVD have an increased risk of RRD: in the family described by Lee and colleagues, three patients (21%) developed RRD at an average age of 60 years (Lee et al., 2003). In the initial report, Hirose et al., mentioned horseshoe tears and punched-out retinal holes in patients with RRD (Hirose et al., 1974). Other findings in SVD include Fuchs corneal endothelial dystrophy (80%), early onset cataract (83%), optic disc abnormalities with Wagner-like ‘W-pattern’ of the retinal vessels, and elevated dark adaptation with reduced scotopic b-wave on the electroretinogram (ERG) (Lee et al., 2003). Hejtmancik and colleagues classified the phenotypic features in two subgroups of congenital abnormalities (dysmorphic optic nerve head with fibrillar vitreous degeneration) and progressive abnormalities, including corneal guttae, and peripheral retinal degeneration that may include the minute crystalline deposits (Hejtmancik et al., 2008).

### 3.2.4. X-linked retinoschisis

Pathogenic variants in *RS1* cause an inherited retinal degenerative disease called X-linked retinoschisis (XLRS) (Sauer et al., 1997). In males, it is the most common form of juvenile-onset retinal degeneration with a prevalence between 1:5000 and 1:20,000 (George et al., 1995). XLRS is characterized by schisis of the neuroretina, which can be revealed as foveal schisis and peripheral schisis. Foveal schisis is present in virtually all XLRS patients (98–100%) and can be observed on OCT imaging (Fig. 6) or as a spokewheel appearance at funduscopy in 51% (Deutman, 1971; Hahn et al., 2022). The peripheral schisis most often

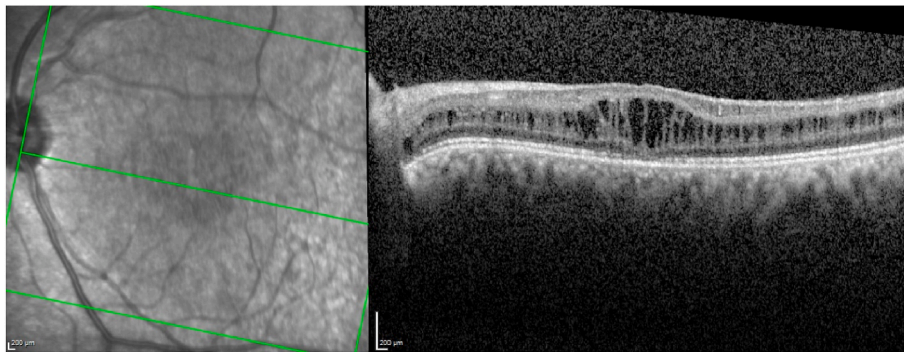


Fig. 6. OCT imaging shows foveal retinoschisis in the left eye of a 29-year old male with X-linked juvenile retinoschisis.

resides in the inferotemporal region, and can have breaks in the inner leaf varying from small holes to large tears (García-Arumí et al., 2008). Other changes include subretinal linear fibrosis, pigmentation, white retinal flecks and vascular attenuation or sheathing (George et al., 1996). Vision-threatening complications include rhegmatogenous or tractional retinal detachment, vitreous hemorrhage, hemorrhage within a large schisis cavity, neovascular glaucoma, vitreoretinal traction causing nasal macula dragging, and optic atrophy (Greven et al., 1990). Retinal detachment was reported in up to 5–20% of XLRS patients and up to a third develop vitreous hemorrhage (George et al., 1996; Kellner et al., 1990). In a recent large study of 340 XLRS patients, the prevalence of retinal detachment was 8.5% at a median age of 9 years (range 0.6–61.6) and vitreous hemorrhage in 13.2% at a median age of 9.4 years (range 0.5–62.6) (Hahn et al., 2022).

### 3.2.5. Non-syndromic ectopia lentis

Four genes have been implicated in ectopia lentis and axial high myopia in the absence of systemic abnormalities: *FBN1* (the gene also associated with Marfan), *ADAMTSL4*, *ADAMTSL8*, and *P3H2* (also known as *LEPREL1*) (Chandra et al., 2012, 2014; Christensen et al., 2010; Khan et al., 2015; Mordechai et al., 2011; Rødhahl et al., 2020; Stephenson et al., 2020). There is an increased risk of RRD in these patients that cannot solely be attributed to the cumulative risk factors of high myopia and lens surgery. All seven described individuals with *FBN1*-related autosomal dominantly inherited non-syndromic ectopia lentis developed RRD, four of which bilaterally (Stephenson et al., 2020). Four in 24 individuals (16%) with autosomal recessively inherited *ADAMTSL4*- or *ADAMTSL8*-related disease developed a retinal detachment (Chandra et al., 2012, 2014; Christensen et al., 2010). Finally, more than one-third with autosomal recessively inherited *P3H2*-related developed an RRD. In these patients a retinal dialysis was a frequent finding (Khan et al., 2015; Mordechai et al., 2011).

In summary, we discussed syndromic and non-syndromic disorders involving RRD. Recognizing these inherited disorders is important for patient counseling, molecular genetic diagnostics and possible prophylactic measures. Table 1 provides an overview of ocular and extra-ocular characteristics per gene associated with RRD, and can be used in the clinical work-up of these patients.

## 4. Genes associated with retinal detachment

As reviewed in Chapter 3, hereditary diseases involving RRD may present with a broad spectrum of disease characteristics, even among disorders caused by pathogenic variants in the same gene. The broad phenotypic spectrum may be explained by pathogenic variants exerting different effects on protein functions. Alternatively, seemingly similar variants may have different outcomes due to the modifying effect of splice regulators, and common genetic variants may further contribute to phenotypic variation (Ng et al., 2020; Richards and Snead, 2008; Snead et al., 2011). To understand the immense complexity of

overlapping phenotypes and the differences among phenotypes, we discuss genotype-phenotype correlations in monogenic disorders with an increased RRD risk in section 4.1. In section 4.2, we discuss genetic variants associated with RRD development through multifactorial inheritance.

### 4.1. Genes associated with monogenic disorders with increased risk for retinal detachment

To date, at least 29 genes have been associated with monogenic disorders in which RRD is one of the reported findings. These genes and related phenotypes are shown in Table 2. The most well studied genes associated with RRD, *COL2A1* and *COL11A1*, encode for fibrillar collagens which are present in the human vitreous, namely type II and type XI collagen. Interestingly, many other genes associated with RRD are related to collagen function due to their role in the post-translation modification of collagens; they for example play a role in extracellular crosslinking of collagen chains. In addition, we categorized a group of RRD-associated genes which are involved in the TGF- $\beta$  pathway. The pathogenic mechanisms of genetic variants in each of these pathways are discussed in Chapter 5.

#### 4.1.1. Genes related to collagen

##### 4.1.1.1. Collagen genes

**4.1.1.1.1. *COL2A1*.** Pathogenic variants in *COL2A1* are associated with a spectrum of dominant and recessive inherited disorders usually characterized by skeletal dysplasia, orofacial features, hearing impairment and ocular findings (Gregersen and Savarirayan, 2019). *COL2A1* encodes for the collagen alpha-1 (II) chain. Stickler syndrome is one of the dominantly inherited disorders caused by pathogenic variants in *COL2A1*. It is often referred to as the most common form of type II collagen disorder, although the exact prevalence of type II collagen disorders in general and Stickler syndrome is unknown. The prevalence of less severe *COL2A1* related phenotypes is, in the absence of a clinical diagnosis, likely also underestimated. Nevertheless, heterozygous pathogenic variants in *COL2A1* are the major cause of Stickler syndrome and 80–90% of cases are attributed to variants in this gene (Robin et al., 2021).

The phenotypic severity of *COL2A1* related disease varies widely, from perinatal lethality in achondrogenesis type II, to severe neonatal presentation observed in Kniest syndrome, Stickler syndrome with an intermediate phenotype, and relatively mild features presenting in adulthood in mild spondyloepiphyseal dysplasia (Gregersen and Savarirayan, 2019; Robin et al., 2021). In general, the more severe type II collagen phenotypes are caused by pathogenic variants with a dominant negative effect. These are for example missense variants that substitute the glycine in the ‘Gly-X-Y’ repeat of the alpha chain and thereby affect the triple helical structure, or variants that lead to in-frame exon skipping. The mutant product generates an abnormal collagen molecule by

**Table 2**  
Genes and related disorders associated with retinal detachment.

Gene	Cytogenetic location	Encoded protein	Related disorder	Mode of inheritance	Syndromic or non-syndromic	N. of RD cases	RD risk	Reference
<b>ADAMTSL4</b>	1q21.2	ADAMTS-like protein 4	Isolated ectopia lentis	AR	NS	<5	ND	(Chandra et al., 2012; Christensen et al., 2010)
<b>ADAMTS18</b>	16q23.1	A disintegrin and metalloproteinase with thrombospondin motifs 18	Microcornea, ectopia lentis and early cone-rod dystrophy	AR	NS	<5	ND	Chandra et al. (2014)
<b>BMP4</b>	14q22.2	Bone morphogenetic protein 4	Stickler-like syndrome with renal dysplasia	AD	S	<5	ND	Nixon et al. (2019b)
<b>CHST14</b>	15q15.1	Carbohydrate sulfotransferase 14	Ehlers-Danlos syndrome subtype	AR	S	<5	ND	Janecke et al. (2016)
<b>COL2A1</b>	12q13.11	Alpha-1 chain of type II collagen	Stickler syndrome (Type 1)	AD	S	>20	60–70%	(Boothe et al., 2020; Robin et al., 2021)
			Stickler ocular only	AD	NS	>20	~60%	(Edwards et al., 2012; Go et al., 2003; Richards et al., 2005)
			Kniest dysplasia	AD	S	>20	~36%	(Maugenee and Traboulsi, 1985; Sergouniotis et al., 2015)
<b>COL3A1</b>	2q32.2	Alpha-1 chain of type III collagen	Ehlers-Danlos syndrome subtype	AD	S	<5	ND	Lumi et al. (2021)
<b>COL9A1</b>	6q13	Alpha-1 chain of type IX collagen	Stickler syndrome (Type 4)	AR	S	<5	ND	(Khan et al., 2021; Nikopoulos et al., 2011; Nixon et al., 2019a; Van Camp et al., 2006)
<b>COL9A2</b>	1p34.2	Alpha-2 chain of type IX collagen	Stickler syndrome (Type 5)	AR	S	<5	ND	(Baker et al., 2011; Kjellstrom et al., 2020; Nixon et al., 2019a)
<b>COL9A3</b>	20q13.33	Alpha-3 chain of type IX collagen	Stickler syndrome (Type 6)	AR, AD	S	>20	8–41%	(Faletra et al., 2014; Hanson-Kahn et al., 2018; Markova et al., 2021; Nash et al., 2021; Nixon et al., 2019a)
<b>COL11A1</b>	1p21.1	Alpha-1 chain of type XI collagen	Stickler syndrome (Type 2)	AD, AR	S	>20	40%	(Richards et al., 2013; Robin et al., 2021)
			Marshall syndrome	AD	S	>20	10–25%	(Annunen et al., 1999; Majava et al., 2007)
<b>COL18A1</b>	21q22.3	Alpha-1 chain of type XVIII collagen	Knobloch syndrome	AR	S	>20	~42%	Hull et al. (2016)
<b>FBN1</b>	15q21.1	Fibrillin-1	Non-syndromic ectopia lentis	AD	NS	5–20	ND	Stephenson et al., 2020
<b>FZD4</b>	11q14.2	Frizzled class receptor 4	Marfan syndrome	AD	S	>20	5–26%	Esfandiari et al. (2019)
			Familial exudative vitreoretinopathy	AD, AR	NS	>20	21–64%	(Chen et al., 2019; Edwards et al., 2012; Gilmour, 2015)
<b>GZF1</b>	20p11.21	GDNF-inducible zinc finger protein 1	Larsen syndrome	AR	S	<5	ND	Patel et al. (2017)
<b>KCNJ13</b>	2q37.1	Inwardly rectifying potassium channel, subfamily J, member 13 (Kir7.1)	Snowflake vitreoretinal degeneration	AD	NS	5–20	~20%	(Hejtmancik et al., 2008; Lee et al., 2003)
<b>KIF11</b>	10q23.33	Kinesin-like protein KIF11	Familial exudative vitreoretinopathy	AD	NS	<5	ND	Chen et al. (2020b)
<b>LRP2</b>	2q31.1	Low density lipoprotein receptor-related protein 2	Predominant ocular Stickler-like phenotype with proteinuria and Donnai-Barrow syndrome (DBS)	AR	S	5–20	~63%	(Khan and Ghazi, 2018; Patel et al., 2007; Schrauwen et al., 2014)
<b>LRP5</b>	11q13.2	Low density lipoprotein receptor-related protein 5	Familial exudative vitreoretinopathy and Osteoporosis-pseudoglioma syndrome	AD, AR	NS, S	>20	21–64%	(Chen et al., 2019; Gilmour, 2015; Papadopoulos et al., 2019)
<b>LRPAP1</b>	4p16.3	Low-density lipoprotein receptor-related protein-associated protein 1	Non-syndromic high myopia with frequent RRD development during childhood	AR	NS	5–20	42%	(Khan et al., 2021; Magliyah et al., 2020)
<b>OAT</b>	10q26.13	Ornithine aminotransferase	Gyrate atrophy of the choroid and retina	AR	S	<5	ND	Magliyah et al. (2021)
<b>P3H1</b>	1p34.2	Prolyl 3-hydroxylase 1	Osteogenesis imperfecta	AR	S	<5	ND	Scollo et al. (2018)
<b>P3H2</b>	3q28	Prolyl 3-hydroxylase 2	Non-syndromic severe high myopia, early-onset cataract and lens subluxation	AR	NS	5–20	35%	(Guo et al., 2014; Khan et al., 2015; Mordechai et al., 2011)
<b>PLOD1</b>	1q36.22	Procollagen-lysine,2-oxoglutarate 5-dioxygenase 1 or lysyl hydroxylase 1 (LH1)	Ehlers-Danlos syndrome subtype	AR	S	<5	ND	(Bodanowitz et al., 1997; Yeowell and Steinmann, 2018)

(continued on next page)

Table 2 (continued)

Gene	Cytogenetic location	Encoded protein	Related disorder	Mode of inheritance	Syndromic or non-syndromic	N. of RD cases	RD risk	Reference
<b>PLOD3</b>	7q22.1	Procollagen-lysine,2-oxoglutarate 5-dioxygenase 3 or Lysyl hydroxylase 3 (LH3)	Stickler-like syndrome with vascular complications	AR	S	<5	ND	Ewans et al. (2019)
<b>RS1</b>	Xp22.13	Retinoschisin	X-linked retinoschisis	XL	NS	>20	9%	Hahn et al. (2022)
<b>TINF2</b>	14q12	TERF1-interacting nuclear factor 2	Revesz syndrome	AD	S	<5	ND	Gupta et al. (2017)
<b>TSPAN12</b>	7q31.31	Tetraspanin 12	Familial exudative vitreoretinopathy	AD, AR	NS	>20	21–64%	(Chen et al., 2019; Gilmour, 2015)
<b>VCAN</b>	5q14.2-q14.3	Chondroitin sulfate proteoglycan type 2 (CSPG2)	Wagner disease and erosive vitreoretinopathy	AD	NS	>20	~27–50%	(Brown et al., 1995; Graemiger et al., 1995; Hirose et al., 1973; Kloeckener-Gruissem and Amstutz, 2016; Miyamoto et al., 2005)
<b>XYLT2</b>	17q21.33	Xylosyltransferase 2	Spondyloocular syndrome	AR	S	<5	ND	(Guleray et al., 2019; Munns et al., 2015; Umair et al., 2018)

**Abbreviations:** autosomal dominant (AD), autosomal recessive (AR), X-linked (XL), not determined (ND), syndromic (S), non-syndromic (NS), retinal detachment (RD). RD risk is not determined for genes associated with retinal detachment which are described in less than five cases in literature.

assembling with wild-type produced alpha chains, thereby interfering with the wild-type product and leading to a dominant negative effect (Gregersen and Savarirayan, 2019; Richards et al., 2010; Richards and Snead, 2008). Since collagen exons usually encode complete Gly-X-Y repeats, pathogenic variants leading to exon skipping often maintain the reading frame. For example, pathogenic variants leading to exon skipping are more common in Kniest dysplasia, a phenotype on the more severe end of the type II collagen disorder spectrum (Gregersen and Savarirayan, 2019). Less severe phenotypes are generally caused by pathogenic variants leading to haploinsufficiency, usually due to reduced protein abundance caused by pathogenic nonsense or frameshift variants. Nevertheless, the genotype-phenotype correlation is complex and seemingly similar variants can result in both haploinsufficiency as well as a dominant negative effect (Richards and Snead, 2008).

Pathogenic variants in *COL2A1* that are identified in Stickler syndrome are predominantly pathogenic nonsense or frameshift variants, resulting in haploinsufficiency of the *COL2A1* gene product (Gregersen and Savarirayan, 2019; Hoornaert et al., 2010; Richards et al., 2010; Robin et al., 2021; Snead et al., 2011). Notably, missense variants located in the triple helical domain, which are expected to have a more profound mutational effect, are also found in 10% of *COL2A1*-related Stickler syndrome patients (Hoornaert et al., 2010). Pathogenic variants affecting exon 2 transcripts of *COL2A1* are associated with a predominant ocular Stickler phenotype, since this exon is spliced out in non-ocular tissue (Edwards et al., 2012; Richards et al., 2000). However, variants outside exon 2 may also result in a predominant ocular phenotype (Go et al., 2003; Richards et al., 2005). Modifying factors such as genetic variants altering exon splicing or common variants with a protective effect might explain the clinical variability, although there is currently no satisfactory explanation. It is important to consider that deep intronic variants are also potentially pathogenic, and cannot be identified by exome sequencing, a genetic approach that analyses coding exons across the genome. In a case with Stickler syndrome, a deep intronic variant in *COL2A1* was confirmed to be pathogenic using a mini-gene splice assay (Snead et al., 2021). In addition to Stickler syndrome, other type II collagen phenotypes have also been associated with an increased retinal detachment risk. Patients with other forms of type II collagen disorders develop a retinal detachment in 12% of cases. In these patients, pathogenic splice variants are associated with the highest risk for retinal detachment (Terhal et al., 2015).

**4.1.1.1.2. COL11A1.** Pathogenic variants in *COL11A1* are associated with a spectrum of disorders with increasing severity: Stickler syndrome, Marshall syndrome and fibrochondrogenesis type 1 (Robin et al., 2021). *COL11A1* encodes for the collagen alpha-1 (XI) chain,

which is one of the three alpha chains that compose type XI collagen (Ricard-Blum, 2011). Heterozygous pathogenic variants in *COL11A1* are the second most frequent cause of Stickler syndrome: almost one in five cases are associated with variants in this gene (Robin et al., 2021).

Different types of pathogenic variants in *COL11A1*, including splice site variants, missense variants, and in-frame deletions are identified in cases with Stickler syndrome (Robin et al., 2021). Pathogenic splice site variants in *COL11A1* that cause exon skipping are most frequently detected in Stickler syndrome (Richards et al., 2010, 2013). In addition, non-canonical splice site variants identified in Stickler syndrome patients have been demonstrated to induce in-frame deletions of exons, leading to a shorter collagen XI alpha chain (Micale et al., 2020). These types of pathogenic variants exert a dominant negative effect, since the mutant *COL11A1* procollagens assemble with wild-type collagen chains, thus interfering with the gene product translated from the normal allele (Richards et al., 2010, 2013). Pathogenic variants leading to haploinsufficiency of *COL11A1* potentially result in milder disease (Richards et al., 2010). A milder clinical phenotype may also occur due to mosaicism of pathogenic variants in *COL11A1* (Hufnagel et al., 2014; Lauritsen et al., 2017). Genetic variants that alter the glycine residue in the 'Gly-X-Y' repeat disrupt the triple helical domain, resulting in a spectrum of diseases with varying severity (Richards et al., 2013). The inheritance pattern of *COL11A1* related Stickler syndrome is most often autosomal dominant (Robin et al., 2021), but a number of families show a recessive form with biallelic compound heterozygous pathogenic variants (Nixon et al., 2020; Richards et al., 2013). Recessively inherited *COL11A1* related disease, caused by homozygous or compound heterozygous pathogenic variants, generally leads to fibrochondrogenesis type 1, which is the most severe disorder in the *COL11A1* spectrum. However, due to alternative splicing of e.g. exon 9 of *COL11A1*, seemingly similar pathogenic variants can result in both Stickler syndrome as well as fibrochondrogenesis type 1 (Nixon et al., 2020; Richards et al., 2013). Pathogenic variants affecting exon 9 likely lead to less pronounced skeletal features since exon 9 is not expressed in mature cartilage (Morris et al., 2000; Richards et al., 2013).

Pathogenic variants affecting splicing and leading to a deletion of one of the 54-bp exons of *COL11A1* are more often associated with Marshall syndrome, while other types of pathogenic variants in *COL11A1* may cause phenotypes with features of both Marshall and Stickler syndromes (Annunen et al., 1999; Majava et al., 2007). However, a pathogenic variant predicted to cause skipping of exon 38 of the *COL11A1* gene also resulted in a phenotype presenting with features of both Marshall and Sticker syndromes, though without the typical skull features that are usually observed in Marshall syndrome (Čopíková et al., 2020). Clinical findings associated with pathogenic variants in

*COL11A1* can vary widely (Čopíková et al., 2020; Guo et al., 2017; Hufnagel et al., 2014). For example, severe skeletal dysplasia, which shares similarities with the recessively inherited fibrochondrogenesis type 1, was associated with a heterozygous pathogenic variant in *COL11A1* in two sisters (Hufnagel et al., 2014). In addition, a case with a presumed diagnosis of osteoporosis-pseudoglioma syndrome due to low bone mass and recurrent fractures in combination with blindness, appeared to carry a pathogenic missense variant in *COL11A1* (Vogiatzi et al., 2018). Ocular involvement included retinal dysplasia and persistent hyperplastic primary vitreous after birth. Hearing impairment and dysmorphic facial features were absent.

**4.1.1.1.3. *COL9A1*, *COL9A2*, and *COL9A3*.** Pathogenic variants in *COL9A1*, *COL9A2* and *COL9A3* are associated with Stickler syndrome with, generally, an autosomal recessive inheritance pattern (Nixon et al., 2019a; Robin et al., 2021). These genes each encode one of the alpha chains of type IX collagen (Robin et al., 2021). Pathogenic variants in these genes are a rare cause of Stickler syndrome.

Biallelic variants in *COL9A1*, *COL9A2* or *COL9A3* are predicted to result in loss-of-function (Robin et al., 2021). In recessive Stickler syndrome cases, facial- and joint features are less common and, these cases have a milder presentation compared to dominantly inherited cases (Nixon et al., 2019a). Nevertheless, a more severe phenotype, which included dysmorphic facial features and early-onset arthropathy, was observed in a case with compound heterozygous variants in exons 5 and 30 of *COL9A3* (Markova et al., 2021). Autosomal dominant variants in *COL9A3* were identified in two families with profound bilateral lattice degeneration, in which seven out of seventeen individuals developed a retinal detachment at an age varying between 25 and 46 years (Nash et al., 2021). These heterozygous splice- and missense variants identified in *COL9A3*, c.1107+1G > C and c.388G > A; p.(Gly130Ser), were associated with a higher risk of retinal detachment than observed for previous homozygous pathogenic variants affecting type IX collagen (Nash et al., 2021). In contrast to recessive Stickler syndrome in which hearing loss is a consistent feature and presents at a young age, the authors observed mild to moderate sensorineural hearing loss in some cases, while four cases had normal hearing (Nash et al., 2021). Therefore, pathogenic variants in the *COL9A3* gene should be considered in all cases with bilateral lattice degeneration and a family history of retinal detachment, also in the absence of other Stickler-like features such as hearing loss. Two patients with a homozygous pathogenic variant in *COL9A2* showed a reduced rod and cone function on ERG, although it remains difficult to differentiate whether this is a direct result of the genetic variant, whether it is caused by the increased axial length, or whether it is caused by the history of retinal detachment (Kjellstrom et al., 2020).

**4.1.1.1.4. *COL18A1*.** Pathogenic variants in *COL18A1* are associated with Knobloch syndrome, a rare recessively inherited disorder. *COL18A1* encodes for the alpha-1 chain of type XVIII collagen (Hull et al., 2016). Abnormal function of type XVIII collagen affects ocular- and neurological development (Seppinen and Pihlajaniemi, 2011). The most commonly described pathogenic variants in Knobloch syndrome are nonsense variants leading to a premature termination codon, although also pathogenic deletions and splice site variants have been described (Hull et al., 2016).

**4.1.1.2. Genes related to posttranslational modification of collagens.** In addition to collagen genes, genes involved in the posttranslational modification of collagens have been associated with syndromic and non-syndromic phenotypes with an increased RRD risk.

Homozygous variants in *P3H2* (also referred to as *LEPREL1*) were associated with non-syndromic high myopia, early-onset cataract and lens subluxation in three families (Guo et al., 2014; Khan et al., 2015; Mordechai et al., 2011). *P3H2* encodes for prolyl 3-hydroxylase 2, which is one of three isoenzymes of prolyl 3-hydroxylase (P3H) that transforms proline to 3-hydroxyproline residues (Canty and Kadler, 2005; Hudson

et al., 2015; Kuo et al., 2012). Retinal tears developed in more than one-third of the 17 individuals carrying pathogenic variants in *P3H2*, with frequent retinal dialysis (Khan et al., 2015; Mordechai et al., 2011). Most patients required cataract surgery in the first or second decade of life (Guo et al., 2014; Mordechai et al., 2011). In 11 of 17 patients with a homozygous pathogenic variant in *P3H2*, spontaneous lens subluxations, or lens instability due to weak or partially missing lens zonules were found upon clinical examination or during cataract surgery (Khan et al., 2015; Mordechai et al., 2011). Interestingly, a case report of a child with a pathogenic variant in *P3H1*, which is associated with osteogenesis imperfecta, developed a bilateral giant retinal tear at the age of nine years (Scollo et al., 2018), suggesting the possible involvement of both P3H isoenzymes in the risk of retinal tear development.

Pathogenic variants in *PLOD3* can cause a connective tissue disorder, and a homozygous variant was identified in three individuals of a consanguineous family with a Stickler-like phenotype (Ewans et al., 2019). *PLOD3* encodes for lysyl hydroxylase 3 (LH3), which is one of the three LH isoenzymes that hydroxylate lysine residues in collagen. Ophthalmic features included early onset of high myopia, cataract formation, and an optical empty vitreous (Ewans et al., 2019). Additionally, systemic abnormalities with profound sensorineural hearing loss, skeletal changes such as scoliosis, and craniofacial dysmorphic features were found (Ewans et al., 2019). These clinical features are most consistent with Stickler syndrome, although the homozygous *PLOD3* variant, c.809C > T; p.(Pro270Leu), is potentially associated with an additional risk of vascular dissection and joint contractures, and thereby also shows phenotypical overlap with Ehlers-Danlos syndrome subtypes. A coronary artery dissection and aortic arch malrotation was observed in one sibling of the *PLOD3* family (Ewans et al., 2019). Vascular complications such as aortic dissection are also seen in *PLOD1*-related kyphoscoliotic Ehlers-Danlos syndrome (Yeowell and Steinmann, 2018).

#### 4.1.2. Proteoglycan *VCAN*

The disease spectrum of autosomal dominant Wagner disease and erosive vitreoretinopathy (ERVR) is associated with pathogenic variants in *VCAN*. This gene encodes for versican core protein, which is also known as chondroitin sulfate proteoglycan type 2 (*CSPG2*). The pathogenic variants in *VCAN* that were identified in more than twenty families with *VCAN*-related vitreoretinopathy all affect exon 8. These are either intron 7 splice acceptor site variants, intron 8 splice donor site variants, or copy number variations causing deletion of exon 8 (Li et al., 2020). Variants located at the splice acceptor site of intron 7 are most frequently seen in Wagner disease and ERVR, while heterozygous deletions of exon 8 are less common (Burin-des-Roziers et al., 2017; Li et al., 2020). These pathogenic variants interfere with the expression of exon 8, and thereby alter the natural isoform proportion (Kloeckener-Gruissem and Amstutz, 2016; Li et al., 2020). The *VCAN* isoform proportions related to exon 8 expression are discussed in section 5.2. Genetic factors that explain the more severe disease in ERVR have not yet been identified. Tissue specific alternative splicing may explain why alterations in the expression of exon 8 solely cause ocular abnormalities (Kloeckener-Gruissem and Amstutz, 2016). Interestingly, an asymmetric phenotype in a patient with Wagner disease was attributed to a *de novo* deletion leading to somatic mosaicism (Burin-des-Roziers et al., 2017). While the right eye showed a fibrillary optically empty vitreous and ectopic fovea with temporally dragged retinal vessels, no vitreous changes or foveal displacement were observed in the left eye (Burin-des-Roziers et al., 2017). Extensive chorioretinal atrophy sparing only the macular region is in agreement with the protein expression of *VCAN*, which is present in the vitreous, RPE-choroid complex, peripheral retina, and absent in the fovea-macular regions (Graemiger et al., 1995; Tang et al., 2019).

#### 4.1.3. Genes related to the TGF- $\beta$ pathway

Pathogenic variants in genes linked to the transforming growth factor  $\beta$  (TGF- $\beta$ ) pathway are associated with ocular and syndromic

phenotypes with an increased RRD risk.

Pathogenic variants in *FBN1* are associated with Marfan syndrome and non-syndromic ectopia lentis (Judge and Dietz, 2005; Stephenson et al., 2020). This gene encodes for fibrillin-1, a microfibril component with a structural role in the extracellular matrix, and is also involved in regulation of TGF- $\beta$  (Judge and Dietz, 2005; Neptune et al., 2003). Marfan syndrome is usually inherited in an autosomal dominant fashion, while in approximately one in 150 cases homozygous and compound heterozygous pathogenic variants are described (Arnaud et al., 2017; Judge and Dietz, 2005). Biallelic (recessive) inheritance does not seem to be associated with a more severe phenotype presentation with ocular- and cardiovascular complications at an early age (Arnaud et al., 2017). Additionally, in 25% of patients Marfan syndrome manifests due to a pathogenic *de novo* variant (Judge and Dietz, 2005). Specific genotype-phenotype correlations have not been derived, and this is further complicated since among the over 500 identified pathogenic variants, the far majority (>90%) are unique to one family or patient (Judge and Dietz, 2005). Nevertheless, a missense variant in *FBN1*, c.1916G > A; p.Cys639Tyr, was associated with non-syndromic ectopia lentis and familial RRD in one family (Stephenson et al., 2020).

Homozygous pathogenic variants in *LRPAP1* are associated with non-syndromic severe high myopia and RRD development at a young age (Khan et al., 2021; Magliyah et al., 2020). *LRPAP1* encodes for the low-density lipoprotein receptor-related protein associated protein 1, that binds to and protects the lipoprotein receptor-related proteins LRP1 and LRP2. Five of twelve children with a homozygous pathogenic variant in *LRPAP1* developed an RRD at an average age of 10 years, often with profound PVR (Magliyah et al., 2020). The disease appears to be non-syndromic and vitreous abnormalities can be absent or unnoticed, or are reported in association with increased axial length (Khan et al., 2021; Magliyah et al., 2020). In addition, a homozygous pathogenic variant in *LRP2* was associated with predominant ocular features resembling a Stickler-like phenotype with only some features of the allelic *LRP2* disorder Donnai-Barrow syndrome (Schrauwen et al., 2014). Donnai-Barrow syndrome was associated with retinal detachment in four cases (Khan and Ghazi, 2018; Patel et al., 2007).

A heterozygous pathogenic variant in *BMP4* was associated with a phenotype which partly resembled Stickler syndrome and was additionally associated with renal dysplasia (Nixon et al., 2019b). *BMP4* encodes the bone morphogenetic protein 4 which is a member of the transforming growth factor beta-1 superfamily. The heterozygous c.130G > T; p.Gly44\* variant in *BMP4* is predicted to cause a premature termination codon likely causing haploinsufficiency of the protein and leading to high myopia, a hypoplastic vitreous, variable sensorineural hearing loss, and dysmorphic facial features (Nixon et al., 2019b). Three out of five individuals from one family developed bilateral retinal detachment, with the first detachment occurring at an age between 17 and 40 years. Additionally, severe congenital renal dysplasia was observed in one of the affected individuals and was attributed to this pathogenic variant, since congenital anomalies of the kidney and urinary tract (CAKUT) are also observed in *Bmp4*<sup>tm1/+</sup> mice with loss-of-function variants (Dunn et al., 1997; Nixon et al., 2019b). The authors advised to evaluate patients for these abnormalities if a loss-of-function variant in *BMP4* is identified (Nixon et al., 2019b).

#### 4.1.4. *KCNJ13*

A heterozygous pathogenic variant (c.484C > T; p.R162W) in *KCNJ13* was associated with snowflake vitreoretinal degeneration and increased RRD risk in a family with a dominant inheritance pattern with 13 affected individuals (Hejtmancik et al., 2008). *KCNJ13* encodes for Kir7.1, a potassium channel which is localized in various layers of the human retina and RPE (Hejtmancik et al., 2008). Pathogenic variants in the gene *KCNJ13* may lead to cell depolarization, which alters cell signaling and potentially induces cell damage, though the exact mutational effect is unknown (Hejtmancik et al., 2008).

#### 4.1.5. *RS1*

Pathogenic variants in *RS1* are associated with X-linked retinoschisis. This gene encodes for retinoschisin, a protein which is expressed in bipolar and photoreceptor cells (Molday et al., 2012). Missense variants are the most common cause of X-linked retinoschisis, identified in over 60% of cases. The pathogenic missense variant, c.214G > A; p.(Glu72Lys), seems to be the most prevalent cause of X-linked retinoschisis worldwide (Hahn et al., 2022; Molday et al., 2012). No significant genotype-phenotype correlation has been identified, as all pathogenic variants likely result in a complete deficiency or a non-functional protein (Molday et al., 2012).

In conclusion, pathogenic variants in at least 29 genes cause monogenic disorders that are associated with an increased RRD risk. Although these diseases are inherited in a monogenic fashion, it should be emphasized that the genotype-phenotype correlations are complex and cannot merely be explained by differential effects of amino acid substitutions. Other mechanisms such as alternative splicing, splice site variants resulting in alternatively spliced transcripts, mosaicism, compound heterozygosity and modifying variants may further explain the broad spectrum of phenotypes associated to these genes.

#### 4.2. Genetic variants associated with retinal detachment through multifactorial inheritance

The largest proportion of RRD cases occurs as a multifactorial disease, while only a minority of RRD cases are caused by monogenic inheritance. In multifactorial inheritance the combined effect of multiple genetic variants as well as non-genetic risk factors determines the disease risk. Multifactorial diseases are generally studied using genome-wide association studies, which query the association of genetic variants across the genome with the disease of interest. To date, two genome-wide association studies (GWAS) and one Mendelian randomization study led to the identification of new RD risk loci (Boutin et al., 2020; Han et al., 2020; Kirin et al., 2013). Table 3 shows all polymorphisms associated with RD by GWAS or Mendelian randomization studies.

The six genetic variants with suggestive significance in the discovery phase of the first RD GWAS, conducted by Kirin and colleagues, were identified in or near genes involved in cell-adhesion and cytoskeletal reorganization (Kirin et al., 2013). The discovery phase included 867 Scottish RRD patients and 1953 ethnically matched controls in the first stage, and 1000 Dutch and English RRD patients and 2912 Dutch and English controls in the second stage. The replication phase was carried out with 966 cases and 3006 controls from English and Croatian descent. In a meta-analysis of the discovery and replication phase, one variant reached statistical significance: rs267738, a coding variant in *CERS2* which leads to a Glu to Ala change in the encoded protein ceramide synthase 2 (Kirin et al., 2013). Ceramides are critically involved in the induction of apoptosis in numerous biological processes, including mediating photoreceptor apoptosis in mammals (German et al., 2006; Gulbins and Li, 2006). Despite that both the direction and effect of the rs267738 variant was uniform across all populations in the first RD GWAS (Kirin et al., 2013), no significant association with *CERS2* was observed in the second GWAS (Boutin et al., 2020). The intergenic variant located between *PYCR3* and *GFUS*, rs2045084, showed a significant association under a dominant model in the replication phase. Nevertheless, possibly due to the heterogeneity between studies, it did not reach significance in the combined meta-analysis (Kirin et al., 2013).

Eleven independent loci were identified by the second GWAS, which included samples from patients with any type of retinal detachment (Boutin et al., 2020). The dataset included 3977 United Kingdom Biobank RD cases and two additional clinical cohorts consisting of 2164 ascertained RRD cases from vitreoretinal surgeries performed in the United Kingdom (Scotland and England). The X-chromosome was excluded for analyses. Six of the identified variants could be replicated, showing a significant association with RD in the 23andMe data set:

**Table 3**

Single nucleotide polymorphisms (SNPs) associated with retinal detachment in genome-wide association studies (GWAS) or Mendelian Randomization studies.

SNP	SNP location	Nearest gene	Chr. position	Effect		P value	Reference
				$\beta$	OR		
rs57574422	Intronic	<i>ARHGAP18</i>	6:129705664	-0.22		6.4 <sup>E</sup> -06	(Han et al., 2020) <sup>a</sup>
rs6054512	Intergenic	<i>BMP2</i>	20:6780865	-0.09		1.4 <sup>E</sup> -04	(Han et al., 2020) <sup>a</sup>
rs74764079*	Exonic (missense)	<i>BMP3</i>	4:81031483		0.717	1.2 <sup>E</sup> -11	(Boutin et al., 2020) <sup>d</sup>
rs74764079	Exonic (missense)	<i>BMP3</i>	4:81031483	-0.32		7.1 <sup>E</sup> -06	(Han et al., 2020) <sup>a</sup>
rs7667446	Intergenic	<i>BMP3, CFAP299</i>	4:80984870	-0.11		1.9 <sup>E</sup> -04	(Han et al., 2020) <sup>a</sup>
rs1074463	Intronic	<i>CDH12</i>	5:22635260		1.31	1.28 <sup>E</sup> -05	(Kirin et al., 2013) <sup>c</sup>
rs267738*	Exonic (missense)	<i>CERS2</i>	1:150968149		0.79	6.7 <sup>E</sup> -06	(Kirin et al., 2013) <sup>c</sup>
rs11992725*	Intronic	<i>COL22A1</i>	8:138897410		1.125	2.1 <sup>E</sup> -09	(Boutin et al., 2020) <sup>d</sup>
rs11992725	Intronic	<i>COL22A1</i>	8:138897410	-0.16		4.8 <sup>E</sup> -10	(Han et al., 2020) <sup>b</sup>
rs9651980	Intergenic	<i>COL2A1</i>	12:48010853		1.188	4.72 <sup>E</sup> -08	(Boutin et al., 2020) <sup>d</sup>
rs1248634	Exonic (synonymous)	<i>DLG5</i>	10:77819464		0.888	3.67 <sup>E</sup> -09	(Boutin et al., 2020) <sup>d</sup>
rs7940691	Intergenic	<i>EFEMP2</i>	11:65873435		1.113	3.5 <sup>E</sup> -08	(Boutin et al., 2020) <sup>d</sup>
rs60955950	Intronic	<i>FAM13A</i>	4:88835242	-0.11		4.7 <sup>E</sup> -05	(Han et al., 2020) <sup>a</sup>
rs10765567*	Intronic	<i>FAT3</i>	11:92868743		0.841	3.13 <sup>E</sup> -18	(Boutin et al., 2020) <sup>d</sup>
rs10765568	Intronic	<i>FAT3</i>	11:92874700	-0.2		1.2 <sup>E</sup> -15	(Han et al., 2020) <sup>b</sup>
rs8132771	Exonic (pseudogene)	<i>FBXW11P1</i>	21:31627110		1.43	1.96 <sup>E</sup> -05	(Kirin et al., 2013) <sup>c</sup>
rs524952	Intergenic	<i>GJD2</i>	15:34713685	-0.09		7.1 <sup>E</sup> -05	(Han et al., 2020) <sup>a</sup>
rs7744813	Intronic	<i>KCNQ5</i>	6:72933566	-0.09		1.1 <sup>E</sup> -04	(Han et al., 2020) <sup>a</sup>
rs12193446	Intronic	<i>LAMA2</i>	6:129498893	-0.18		1 <sup>E</sup> -05	(Han et al., 2020) <sup>a</sup>
rs955943	Intronic	<i>LDB2</i>	4:16512785		1.54	9.9 <sup>E</sup> -06	(Kirin et al., 2013) <sup>c</sup>
rs4243042	Intronic	<i>LOXL1</i>	15:73949283		0.889	3.33 <sup>E</sup> -08	(Boutin et al., 2020) <sup>d</sup>
rs893819	Intronic	<i>LOXL1</i>	15:73937183	-0.09		1.2 <sup>E</sup> -04	(Han et al., 2020) <sup>a</sup>
rs11187838*	Intronic	<i>PLCE1</i>	10:94278929		0.894	3.64 <sup>E</sup> -09	(Boutin et al., 2020) <sup>d</sup>
rs2045084*	Intergenic	<i>PYCR3, GFUS</i>	8:143611669		1.21	1.54 <sup>E</sup> -05	(Kirin et al., 2013) <sup>c</sup>
rs1318142	Exonic (synonymous)	<i>RDH5</i>	12:55721801	-0.12		2.2 <sup>E</sup> -05	(Han et al., 2020) <sup>a</sup>
rs12960119	Intronic	<i>SS18</i>	18:26034739		1.46	1.58 <sup>E</sup> -07	(Kirin et al., 2013) <sup>c</sup>
rs11217712	Intergenic	<i>TRIM29-OAF</i>	11:120159519		0.892	2.65 <sup>E</sup> -08	(Boutin et al., 2020) <sup>d</sup>
rs1042602*	Exonic (missense)	<i>TYR</i>	11:89178528		0.888	1.01 <sup>E</sup> -09	(Boutin et al., 2020) <sup>d</sup>
rs4373767*	Intergenic	<i>ZC3H11B</i>	1:219586340		1.128	1.3 <sup>E</sup> -09	(Boutin et al., 2020) <sup>d</sup>

Abbreviations: Single nucleotide polymorphism (SNP), genome-wide association studies (GWAS), chromosome (Chr) beta ( $\beta$ ), odds ratio (OR).

SNP base pair location based on Genome Reference Consortium Human Build 38 (GRCh38).

\*Single-nucleotide polymorphisms (SNPs) with an asterisk are significantly associated with retinal detachment in the replication phase or combined meta-analysis of GWAS.

<sup>a</sup> One of ten myopia variants that were associated with retinal detachment risk at Bonferroni-corrected level of  $P < 2.2^E-04$ .<sup>b</sup> One of two lead single-nucleotide variants in genome-wide association study for retinal detachment.<sup>c</sup> One of six most significant single-nucleotide variants with low heterogeneity across studies in the meta-analysis of three discovery studies.<sup>d</sup> One of eleven genome-wide significant association signals for retinal detachment.

rs74764079, rs11992725, rs10765567, rs11187838, rs1042602, and rs4373767, located near *BMP3*, *COL22A1*, *FAT3*, *PLCE1*, *TYR*, and *ZC3H11B*, respectively (Boutin et al., 2020). In addition, a GWAS in a restricted cohort of cases ( $n = 1380$ ) with a diagnosis of the rhegmatogenous type of retinal detachment linked in the hospital record was performed. This did not lead to any significant genome-wide associations, although *FAT3* remained one of the strongest sub-threshold signals (Boutin et al., 2020). In mice, *Fat3* deficiency results in abnormal morphology of the retinal layers, which possibly increases susceptibility of retinal break formation (Deans et al., 2011). *FAT3* and *COL22A1* variants were also significantly associated with RD in the GWAS performed in a Mendelian randomization study, though both studies derived cases from the UK Biobank cohort (Boutin et al., 2020; Han et al., 2020). *COL22A1* encodes a fibril-associated collagen with interrupted triple helices (FACIT), which is an extracellular matrix component. A study in mice shows that type XXII collagen is specifically present at tissue junctions and it may interact with fibrillin and type VI collagen in articular cartilage of mice (Koch et al., 2004). Knockdown of *col22a1* expression in zebrafish showed vulnerability of myotendinous junctions, and, although ocular tissue was not investigated in this study, these findings suggest an important role of *COL22A1* in the extracellular matrix (Charvet et al., 2013). Nevertheless, the potential role of *COL22A1* in RRD pathogenesis remains unclear.

Studying shared genetic contributions identified by GWAS provides an opportunity to gain a more profound understanding of RRD pathogenesis in relation to other multifactorial diseases that pose an increased risk for RRD. Fig. 7 shows shared genetic associations between retinal

detachment and other ocular traits. Myopia, the strongest RRD risk factor, has both environmental and polygenic drivers (Enthoven et al., 2019; Hysi et al., 2020). Variants in or near 12 genes are associated with both RD and myopia. Genes associated with both RD and myopia, including *BMP-2*, *BMP-3*, *GJD2*, *LAMA2*, *LOXL1* loci, suggest the involvement of extracellular matrix remodeling, basement membranes, biogenesis of connective tissue and retinal gap junctions in the pathogenesis of RD and myopia (Boutin et al., 2020; Han et al., 2020; Verhoeven et al., 2013). An increased axial length is likely the most contributory mechanism for the association between myopia and RRD. The *ZC3H11B* locus associated with RD is also related to ocular axial length (Boutin et al., 2020). As discussed in section 2.3, an elongated eye may lead to a weaker retina, more vulnerable to vitreoretinal tractional forces, and an earlier occurrence of vitreous degeneration induced PVD. Interestingly, another gene encoding for laminin, *LAMA5*, was associated with the occurrence of a PVD, an event that occurs significantly earlier in life in myopic individuals (Akiba, 1993; Napolitano et al., 2019). Intraocular pressure (IOP) risk alleles were associated with an increased RD risk in a Mendelian randomization analysis (Han et al., 2020). Additionally, five genes associated with RD, including *PLCE1*, showed overlap with a glaucoma GWAS gene set (Boutin et al., 2020). Although RD and glaucoma might have common underlying biological mechanisms, in the absence of an explanatory hypothesis, we assume this association is driven by a confounder: glaucoma is associated with myopia and may also develop secondary to surgical treatment of retinal detachment. Nevertheless, we cannot exclude that RD and glaucoma may share pathophysiological mechanisms.





The assembly of procollagen molecules is controlled by various steps inside the cell such as hydroxylation of prolines and lysine residues, O- and N-linked glycosylation, and transport to the Golgi complex (Bella and Hulmes, 2017). Fig. 8 shows a schematic overview of the post-translational modification of (pro)collagen intra- and extracellularly. In the endoplasmic reticulum the procollagen molecules, flanked by N' and C' propeptide domains, are modified and folded into a triple helix. The post-translational modification of proline by prolyl-3-hydroxylases (P3H) enzymes, encoded by *LEPRE* genes, appear to be essential for collagen biosynthesis and assembly (Bella and Hulmes, 2017). The lysine residues are hydroxylated by lysyl hydroxylase (LH) enzymes, encoded by *PLOD* genes (Claeys et al., 2021). Folding of the procollagen chains into a triple helix starts from the C' terminal end of the molecule. Chaperones such as HSP47, which are transcriptionally induced by transforming growth factors  $\beta 1$  (TGF $\beta 1$ ), are likely responsible for collagen triple-helix stabilization and impede premature association of procollagen chains (Bella and Hulmes, 2017; Claeys et al., 2021). The procollagens are transported into the Golgi apparatus and then secreted into the extracellular matrix. Proteolytic removal of the N- and C-propeptides, by ADAMTS and BMP enzymes, is the final modification of procollagen transformed into a mature collagen molecule (Bella and Hulmes, 2017; Claeys et al., 2021). In the extracellular matrix (ECM), the mature collagen molecules can further assemble into fibrils. These collagen fibrils are stabilized by the formation of covalent crosslinks, a process initiated by lysyl oxidase enzymes (LOX) which deaminates lysine and hydroxylysine residues (Bella and Hulmes, 2017). Although LOX acts in the ECM, it relies on the intracellular modification of LH enzymes, since these act as point of recognition (Claeys et al., 2021). Our understanding of collagen synthesis and assembly stems mostly from studies about type I collagen. Yet, these are likely similar to synthesis and assembly of other fibrillar collagens.

### 5.1.1. Collagen proteins

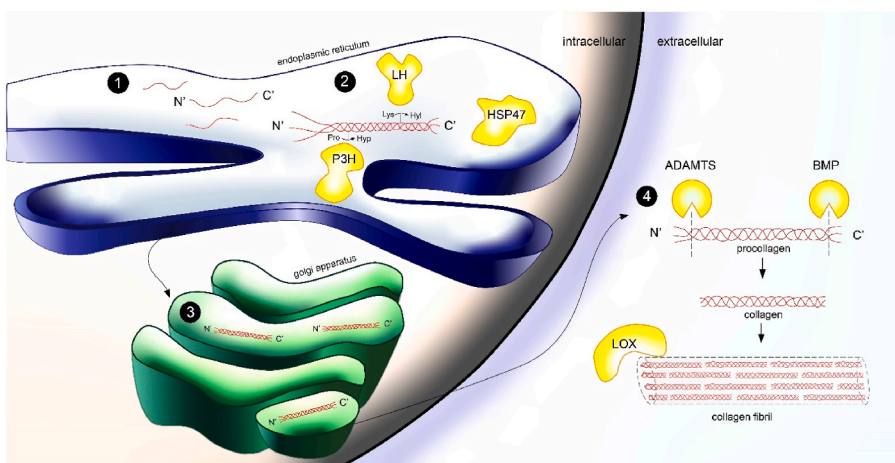
Fig. 9 shows a schematic view of collagen composition in the vitreous. These three collagens, type II, V/XI, and type IX, collaborate in the formation of collagen fibrils: type II and V/XI are fibril-forming collagens and constitute the core of collagen fibrils, type IX collagen is a fibril-associated collagen type necessary for fibril formation and fibril spacing of type II and XI (Ricard-Blum, 2011).

**5.1.1.1. Type II collagen.** Three identical alpha chains encoded by *COL2A1* may compose the homotrimer of type II collagen, a fibrillar collagen (Canty and Kadler, 2005; Ricard-Blum, 2011). Type II collagen is responsible for roughly 70% of collagen in the human vitreous, is expressed in the vitreous cortex while it is still attached to the retina, and

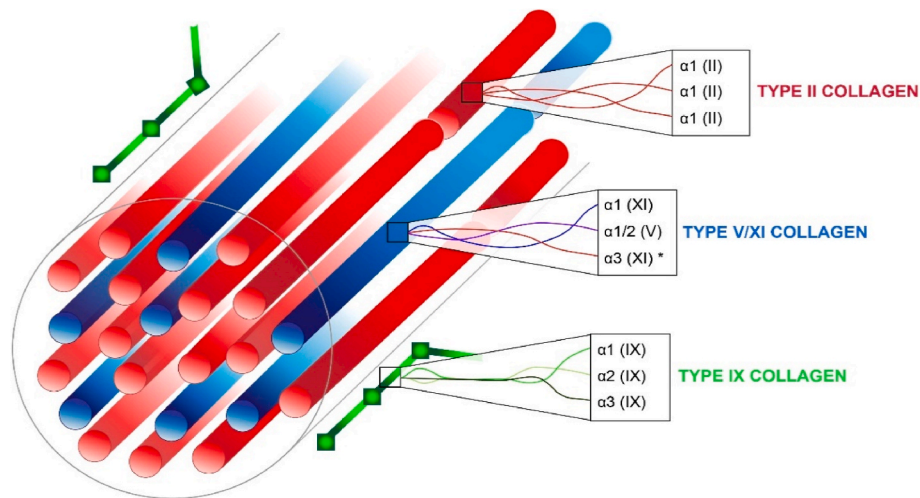
in retinal blood vessels (Bishop et al., 1994a; Bu et al., 2015a; Ponsioen et al., 2008). *COL2A1* undergoes alternative splicing and the in- or exclusion of exon 2 leads to two physiological isoforms encoded by either 54 or 53 exons: type IIA and type IIB procollagen, respectively (Bishop et al., 1994b; Ryan and Sandell, 1990). Alternative splicing is, from an evolutionary perspective, important to create diversity and increases the amount of information stored in the genome since a single gene may encode for multiple distinct transcripts (Bush et al., 2017). Including exon 2 in type IIA procollagen leads to an additional domain in the NH2-propeptide which enables binding to TGF- $\beta 1$  and BMP-2 (Zhu et al., 1999). Alternative splicing may evolve while ageing: the bovine fetal vitreous contains five times more type IIA compared to type IIB, and in the adult vitreous this ratio diminished to 1.5:1 (Bishop et al., 1994b).

Type II collagen is the most abundant collagen type in the vitreous and genetic variants altering the expression or function therefore likely affect the vitreous structure. The typical membranous vitreous phenotype in Stickler syndrome, with a folded membrane observed closely posteriorly to the lens, is assumed to be a consequence of insufficient type II collagen (Richards et al., 2002). Since collagen exons usually encode complete Gly-X-Y repeats for the triple helical domain, exon skipping may leave the mRNA in-frame, resulting into a shortened procollagen that assembles with wild-type alpha chains (Richards and Snead, 2008). In a homotrimer such as type II collagen, with three identical alpha chains, a dominant negative effect of *COL2A1* leads to 7 out of 8 collagens having at least one mutant alpha chain, and only 1 in 8 collagens that are composed of three wild-type alpha chains (Richards and Snead, 2008). Additionally, pathogenic deep intronic variants in *COL2A1* may confer a risk for RRD development by affecting the efficiency of alternative splicing of exon 2 (Spickett et al., 2016). Many intronic SNPs that have been found to affect disease susceptibility, interfere in alternative splicing (Bush et al., 2017).

**5.1.1.2. Type XI collagen.** A heterotrimer consisting of three different alpha chains is type XI collagen (Canty and Kadler, 2005; Ricard-Blum, 2011). It is a fibrillar collagen responsible for roughly 10–25% of collagen in the vitreous, and is scarcely stained in the ganglion cell layer of the retina (Ponsioen et al., 2008) [35, 22]. The presence of type XI collagen is important for lateral growth control of collagen type II fibrils and the optimal molecular ratio of type II/XI collagen, estimated up to roughly 8:1, allows uniformly formed fibrils (Blaschke et al., 2000). The first alpha chain of type XI collagen is encoded by *COL11A1*. The gene has 68 exons and produces at least four natural isoforms due to alternative splicing of exon 6, 7, and 9 (Robin et al., 2021). These isoforms vary in their binding affinity for heparan sulfate, a proteoglycan present



**Fig. 8.** Posttranslational modification of (pro) collagen intra- and extracellular. (1) Procollagen molecules flanked by N' and C' propeptide domains in the endoplasmic reticulum. (2) Modification of procollagen chains and folding into a triple helix takes place in the endoplasmic reticulum. Lysyl hydroxylase (LH) enzymes and prolyl-3-hydroxylase (P3H) enzymes hydroxylate lysine and proline residues, respectively. Folding of the procollagen chains into a triple helix starts from the C' terminal end of the molecule. The protein HSP47 contributes to stabilization of the triple helix, and transportation through the endoplasmic reticulum and into the golgi apparatus. (3) Procollagen is transported through the golgi apparatus and secreted into the extracellular matrix. (4) ADAMTS and BMP enzymes remove the N' and C' propeptides, and thereby transform procollagen into a mature collagen molecule. The mature collagen molecule can further assemble into fibrils. Lysyl oxidase (LOX) stabilizes these fibrils by initiating the formation of cross-links between collagen molecules.



**Fig. 9.** Collagen composition in the vitreous. Type II and V/XI collagen are fibril-forming collagens, and type IX collagen is a fibril-association collagen with interrupted triple-helices (FACIT). \* The  $\alpha 3$  (XI) chain has the same sequence as  $\alpha 1$  (II), though it differs in posttranslational processing.

in the vitreous (Warner et al., 2006). Type XI collagen has hybrid isoforms whereas in the vitreous the second alpha chain, usually encoded by *COL11A2*, is likely substituted by a type V collagen alpha chain (Mayne et al., 1993; Ricard-Blum, 2011). Nevertheless, in the vitreous this collagen type is therefore referred to as type V/XI collagen. The third alpha chain of type XI collagen is the same sequence as encoded by *COL2A1*, though it differs in posttranslational modification and cross-linking (Canty and Kadler, 2005; Ricard-Blum, 2011).

Type XI collagen has quantitatively a less prominent role in the vitreous compared to type II collagen, though it is significantly involved in regulating fibril diameter. Insufficient type XI collagen leads to relatively short collagen fibrils with a variable diameter (Blaschke et al., 2000). This is in agreement with the beaded vitreous phenotype related to pathogenic variants in *COL11A1*, in which the vitreous fully fills the posterior segment though shows irregular thickened fibrils. Since type XI collagen is a heterotrimer, pathogenic variants leading to haploinsufficiency might result in minor abnormalities and a possibly more difficult to recognize phenotype.

**5.1.1.3. Type IX collagen.** The ‘fibril-associated collagens with interrupted triple helices’ (FACIT) family, in which non-collagenous domains separate the collagen domains, contains type IX collagen (Canty and Kadler, 2005; Ricard-Blum, 2011). This collagen consists of three different alpha chains, encoded by *COL9A1*, *COL9A2*, and *COL9A3*. It stabilizes the fibrillar network and contributes to the initiation of type II and XI collagen fibril formation (Blaschke et al., 2000). Type IX collagen is responsible for roughly 15–25% of collagen in the vitreous and is localized on the surface of collagen fibrils where it maintains regular fibril spacing (Bishop et al., 1994a; Le Goff and Bishop, 2008; Ricard-Blum, 2011). The attachment of a chondroitin sulfate side-chain to the protein core of type IX collagen might be involved in preventing lateral fusion of collagen fibrils (Bishop et al., 2004). Type IX collagen is also variably expressed in the vitreous cortex and is observed in retinal blood vessels located pre-equatorially and equatorially (Ponsioen et al., 2008).

A deficiency of type IX collagen may lead to gradual decay of fibril structure due to reduced fibril stability (Blaschke et al., 2000). The age-related decrease of type IX collagen on the surface of collagen fibrils in the human vitreous, likely contributes to the physiological fibril aggregation and vitreous liquefaction which inevitably occurs with aging (Bishop et al., 2004). Pathogenic variants affecting type IX collagen led to only subtle vitreous changes which can easily be misidentified as age- or refraction related syneresis. Nevertheless, the third alpha chain of type IX collagen might have a critical role in vitreoretinal adhesion in

the peripheral retina and vitreous base. Pathogenic variants in *COL9A3* were associated with profound peripheral vitreoretinal lattice degeneration and increased RRD risk (Nash et al., 2021). The *COL2* and *COL3* domain in the third alpha chain of type IX collagen may be of specific interest since these domains are involved in covalently cross-linking with type II collagen (Wu et al., 1992), and can bind with Matrilin-3, an extracellular matrix protein (Fresquet et al., 2007).

**5.1.1.4. Type XVIII collagen.** A basement membrane component involved in preserving the basement membrane integrity and angiogenesis inhibition is type XVIII collagen (Seppinen and Pihlajaniemi, 2011). It is widely expressed in the human eye, including the iris, ciliary body and retinal capillaries, and is observed in all regions of the ILM, from the anterior to the posterior pole (Määttä et al., 2007; Ponsioen et al., 2008). Mice experiments showed that type XVIII collagen is involved in anchoring vitreous fibrils into the ILM (Fukai et al., 2002). The vitreoretinal adhesion established by type XVIII collagen may be attributed to its heparan sulfate side chain (Le Goff and Bishop, 2008). Opticin, an extracellular matrix protein that in humans is encoded by the *OPTC* gene, can bind to this heparan sulfate side chain of collagen type XVIII and thereby facilitate the connection between cortical vitreous collagens and the ILM (Hindson et al., 2005). Opticin may noncovalently bind collagen fibrils and regulate fibril morphology, spacing, and organization.

Early onset myopia in Knobloch syndrome, caused by pathogenic variants in *COL18A1*, was hypothesized to be caused by ILM disruption (Halfter et al., 2006). The ILM and vitreous body likely play a major role in adequate eye size regulation: in chicken embryos eye size enlargement could be induced by intravitreal collagenase treatment which disrupted ILM and vitreous body integrity (Halfter et al., 2006). Therefore, although scleral abnormalities may enable excessive axial lengths, ILM disruption potentially has a significant role in the development of congenital myopia (Halfter et al., 2006). Type XVIII collagen’s involvement in the connection between vitreous and ILM might also be involved in RRD pathogenesis. Mouse experiments showed that collagen fibrils in the peripheral vitreous seemed to penetrate the ILM in wild-type mice, while type XVIII collagen null mice showed no fibrils in the peripheral vitreous inserting the retina (Fukai et al., 2002). Additionally, persistent hyaloid vessels tightly adherent to the retina were observed in *Col18a1*<sup>-/-</sup> mice, while hyaloid capillaries disappeared postnatally in wild-type mice. A collapse of the vitreous combined with these abnormal adhesions to the retina potentially induces increased retinal detachment risk in Knobloch syndrome (Fukai et al., 2002).

### 5.1.2. Posttranslational modification of collagens

The structural role and biochemical properties of collagen chains depend on numerous posttranslational modifications such as hydroxylation of proline and lysine residues (Ricard-Blum, 2011). *P3H2* encodes for prolyl 3-hydroxylase 2 which is one of three isoenzymes of prolyl 3-hydroxylase (P3H) that transforms proline to 3-hydroxyproline residues (Canty and Kadler, 2005; Hudson et al., 2015; Kuo et al., 2012). These residues have a significant role in the supramolecular structural organization of the collagen network (Weis et al., 2010). The hydroxylation of proline is essential for triple helical stabilization of collagen, and hydroxyproline also coordinates the water network within and between collagen chains (Canty and Kadler, 2005; Kuo et al., 2012). Prolyl 3-hydroxylase (P3H) isoenzymes may differ in collagen substrate preference and the degree in 3-hydroxyproline is tissue specific (Hudson et al., 2015; Weis et al., 2010). *P3H2* can synthesize 3-hydroxyprolines at specific sites in both fibrillar collagen chains such as type II collagen, as well as type IV collagen, an important basement membrane component (Fernandes et al., 2011; Hudson et al., 2015).

Altered prolyl 3-hydroxylation due to *P3H2* deficiency may weaken triple helical domain strength of several fibrillar collagens as well as the structural organization of basement membranes such as the ILM (Fernandes et al., 2011; Halfter et al., 2006; Hudson et al., 2015; Khan et al., 2015; Mordechai et al., 2011). The excessive axial lengths in affected individuals with homozygous pathogenic variants in *P3H2* may result from both altered scleral composition by affecting type I collagen and altered ILM by affecting type IV collagen. *P3h2* knock-out mice show significantly reduced or completely absent 3-hydroxyproline in type I and IV collagen in the sclera and lens capsule, respectively (Hudson et al., 2015). Type IV collagen is also an important basement membrane component present in the entire thickness of the human ILM (Bu et al., 2015a; Ponsioen et al., 2008), and, since ILM disruption has been shown to cause excessive eye enlargement in chicken embryos (Halfter et al., 2006), pathogenic variants in *P3H2* may also cause severe axial myopia as a consequence of ILM alterations. The vitreoretinal degeneration with vitreous opacities and veils, and lattice degeneration that are observed in individuals with pathogenic variants in *P3H2*, might be secondary to the increased axial length (Guo et al., 2014; Mordechai et al., 2011). Interestingly, the degree of 3-hydroxylation at the Pro<sup>944</sup> site in type II collagen is remarkably higher in the vitreous compared to articular cartilage: more than 80% in the bovine vitreous versus less than 20% in bovine articular cartilage (Weis et al., 2010). This could be an important factor for the eye-specific pathology caused by pathogenic variants in *P3H2*. Unfortunately, the effect of *P3H2* deficiency in the vitreous remains unknown since insufficient type II collagen could be isolated from the vitreous of *P3h2* knock out mice for analysis (Hudson et al., 2015).

*PLOD3* encodes for lysyl hydroxylase 3 (LH3), which is one of the three LH isoenzymes that hydroxylates lysine residues in collagen. The formation of hydroxylysyl residues is important for strengthening the extracellular matrix since these can be further processed to form collagen crosslinks (Canty and Kadler, 2005). LH3 is also involved in glycosylation of collagen chains and a deficiency leads to reduced glucosyltransferase (GGT) activity (Ewans et al., 2019; Kuo et al., 2012). In mice, LH3 is critical for type IV collagen synthesis and basement membrane stability, either due to its role in crosslinking or glycosylation (Rautavuoma et al., 2004). Altered LH3 activity due to pathogenic variants in *PLOD3* potentially causes widespread systemic features: *PLOD3* mRNA expression was identified in the eye, cochlea, cartilage, skin and heart of human embryonic tissue (Ewans et al., 2019). Regarding ophthalmic structures: *PLOD3* is expressed in the lens and retina of embryonic human and embryonic mouse tissue, and in the adult mice eye it is mainly observed in the retinal capillaries and inner segments of photoreceptors (Ewans et al., 2019; Rautavuoma et al., 2004).

### 5.2. Proteoglycan versican

Versican is expressed in various ocular tissues including the vitreous, RPE-choroid complex, peripheral retina, and ciliary body (Tang et al., 2019). It likely contributes to the structural vitreous organization, though the exact mechanism is unknown. *VCAN* has 15 exons and alternative splicing of the two largest central exons, exon 7 and 8, leads to four isoforms assigned as V0, V1, V2, and V3 (KloECKENER-Gruissem and Amstutz, 2016). In V0, all *VCAN* exons are included, in V1 and V2 either exon 7 or exon 8 are skipped, and in V3 exon 7 and 8 are both lacking in the transcript (KloECKENER-Gruissem and Amstutz, 2016). In the vitreous, versican is one of the proteoglycans that can bind chondroitin sulfate (CS) chains (Theocharis et al., 2008). The two glycosaminoglycans (GAGs) binding domains that can attach CS side chains, GAG $\alpha$  and GAG $\beta$ , are encoded by exon 7 and 8 (KloECKENER-Gruissem and Amstutz, 2016; Tang et al., 2019). As a consequence, the four versican isoforms vary in the number of GAG side chains that can attach to the protein. Versican V0 and V1 isoforms are estimated to have 17–23 and 12–15 GAG side chains, respectively, while this is estimated 5–8 in V2, and likely no CS side chains in V3 (KloECKENER-Gruissem and Amstutz, 2016; Theocharis et al., 2008). The G1 and G3 domains located at the N-terminal and C-terminal sides of versican, respectively, enable interaction with various ECM and cell surface molecules (Tang et al., 2019). The G1 domain of versican has a hyaluronic acid binding region, and versican can interact with various other molecules through the binding sites in the G3 domain: e.g. epidermal growth factor (EGF)-like repeats and lectin-like domains (Theocharis et al., 2008).

All known pathogenic *VCAN* variants affect the exon 8 expression, thereby altering the natural isoform proportion (KloECKENER-Gruissem and Amstutz, 2016; Li et al., 2020). It is possible that the imbalanced ratios of versican isoforms, leading to a relative increase in V2 and V3 isoforms which have less GAG binding sites compared to V0 and V1, might accelerate vitreous degeneration due to early collagen fibril aggregation and thereby liquefaction of the vitreous. The pathological mutational effects that are all targeted at exon 8, might also be related to the disruption of the MMP-2 cleavage site in the GAG $\beta$  domain of versican (Tang et al., 2019). Altering this MMP proteolytic cleavage site may have a significant effect on the structure of versican and its interactions with other proteins (Tang et al., 2019).

### 5.3. TGF- $\beta$ pathway

The biological effects of proteins belonging to the TGF- $\beta$  family are context-, and dose-dependent (Morikawa et al., 2016). Interference of TGF- $\beta$  homeostasis may be a shared pathway responsible for the increased retinal detachment risk in several phenotypes, including Stickler syndrome and Marfan syndrome (Spickett et al., 2016). Pathogenic variants in *COL2A1* are the major cause of Stickler syndrome and thereby also the most common cause of inherited RRD. *COL2A1* is involved in TGF- $\beta$  regulation since the inclusion of exon 2 produces the type IIA collagen isoform which can bind to TGF- $\beta$ 1 (Zhu et al., 1999). In Marfan syndrome, pathogenic variants in fibrillin-1 are known to affect TGF- $\beta$  homeostasis (Neptune et al., 2003). Several other RRD associated genetic variants are also related to the TGF- $\beta$  pathway. *LRPAP1* encodes for a low-density lipoprotein receptor-related protein associated protein 1, that binds and protects the lipoprotein receptor-related proteins LRP1 and LRP2. Homozygous variants in *LRPAP1* can lead to a deficiency of *LRP1* and consequently upregulation of TGF- $\beta$  (Aldahmesh et al., 2013). A combination of processes may lead to increased RRD risk due to altered TGF- $\beta$  regulation, even in the absence of vitreous abnormalities. First, TGF- $\beta$  isoforms are involved in the development of myopia due to their role in control of scleral remodeling (Jobling et al., 2004). The association between pathogenic variants in *LRPAP1* and severe high myopia was therefore also related to TGF- $\beta$  signaling (Aldahmesh et al., 2013). Additionally, upregulation of TGF- $\beta$  can increase retinal stiffness and thereby create a higher susceptibility to retinal tear development

(Bu et al., 2015b). Magliyah and co-authors therefore hypothesized that pathogenic variants in *LRPAP1* confer an increased susceptibility of retinal tear formation due to a combination of scleral enlargement and reduced retinal elasticity, which are both mediated by the TGF- $\beta$  pathway (Magliyah et al., 2020). *BMP4* encodes the bone morphogenetic protein 4 which is a member of the transforming growth factor beta-1 superfamily. This protein has an inhibitory effect on TGF- $\beta$  induced processes in RPE cells and attenuates TGF- $\beta$  induced collagen gel contraction (Yao et al., 2016). Therefore, *BMP4* might also be involved in increased susceptibility to RRD development due to its role in the TGF- $\beta$  pathway.

Alternatively, decreased levels of TGF- $\beta$  might weaken adhesive properties involved in supporting retina-RPE attachment. An experimental animal study showed the essential role of TGF- $\beta$  in maintaining adhesion between the neurosensory retinal layer and the RPE (Honjo et al., 2007). Conditional knockout of TGF- $\beta$  in mice led to decreased quantities of chondroitin sulfate in the retina which appeared critical for the adhesive properties of the interphotoreceptor matrix: almost all mice showed retinal detachment at birth (Honjo et al., 2007). Decreased levels of TGF- $\beta$  may therefore reduce the degree of tractional forces that are necessary to cause a detachment of the retina.

#### 5.4. *Norrin/Frizzled4* signaling

The genes associated with FEVR, a clinically and genetically heterogeneous disorder, play a role in retinal vasculature development. Most FEVR genes (*LRP5*, *FZD4*, *TSPAN12*, and *NDP*) have a critical role in *Norrin/Frizzled4* signaling, a pathway that contributes to the development of small blood vessels in the developing retina (Gilmour, 2015). The *Lrp5* signal transduction pathway, and thereby Wnt proteins, are involved in the postnatal regression of the hyaloid artery (Kato et al., 2002), and retained hyaloid vascular remnants is associated with FEVR (Gilmour, 2015). Pathogenic variants in *LRP5* are currently the most common identified cause of RRD-FEVR (Chen et al., 2019). Other FEVR-associated genes are also related to retinal vasculature development: *ZNF408* for example, regulates the expression of genes involved in vasculature development (Karjosukarso et al., 2018). FEVR is believed to be a disorder of angiogenesis rather than vasculogenesis, which suggests a normal development of the primary vascular plexus and an absent or abnormal development of the capillaries around the fovea and in the deep and peripheral retina (Gilmour, 2015). The extent of peripheral retinal avascularity also correlates with decreased macular microvascular vessel density in patients with FEVR (Koulistis et al., 2019). Abnormality of retinal vascular development may increase the risk of retinal detachment due to fibrosis occurring at the junction of the vascular and avascular retina, which ultimately can lead to overwhelming retinal traction (Gilmour, 2015).

In summary, we discussed our current understanding of pathological mechanisms of RRD-associated pathogenic variants on protein level, and illustrated the communalities by clustering these per pathway. Understanding shared pathophysiological mechanisms is important in the application of prophylactic interventions and potential future therapeutic treatment.

### 6. The role of genetics in patient management and prevention of retinal detachment

#### 6.1. Identification of patients with genetic risk factors

The genetic contribution to retinal detachment varies among individuals. In monogenic diseases such as Stickler syndrome, which is caused by pathogenic variants in the *COL2A1* gene, the genetic contribution is strong, while the genetic contribution is intermediate in multifactorial forms of retinal detachment, and likely absent in retinal detachment caused by ocular trauma.

Genetic testing in individuals at high risk for RRD is relevant for

patient counseling and possible preventive measures. We recommend that patients with a family history (first-degree relatives with RRD), relatively young RRD patients (<30 years), especially in cases with bilateral RRD, GRT patients, and patients with characteristics of an ocular or syndromic inherited disease discussed in Chapter 3 should be offered genetic testing. Inherited disorders associated with RRD may present with subtle characteristics exclusively found in the eye. The ocular-only form of *COL2A1*-related Stickler syndrome for example, may be underdiagnosed, and variants in *COL9A3* may possibly cause a mild and underdiagnosed monogenic phenotype. Children with vitreous abnormalities, myopia, and lens opacities should be suspected of collagen abnormalities, even in the absence of systemic disease (Khan et al., 2021). In addition, RRD in the pediatric population (<18 years) is in 50% of cases associated with a congenital/developmental anomaly, most frequently FEVR and Stickler syndrome (Chen et al., 2020a). Genetic testing may also be relevant in patients with a high risk of bilateral retinal detachment. Patients with retinal detachment in one eye have an increased RRD risk of 10% to develop RRD bilaterally. In patients with a retinal detachment at relatively young age (<30 years), the risk of RRD is even higher: 17% (Ferrara et al., 2022; Gupta and Benson, 2005; Mistry et al., 2010a). GRT patients have a particularly high risk for bilateral involvement, as 38% of GRT patients develop a retinal detachment bilaterally [B.M. Manuscript submitted].

Table 1 can guide the selection of genes that should be evaluated in a genetic testing lab in patients with a suspected monogenic disease. Given the large number of genes that may require testing, the most efficient genetic test is whole exome sequencing, using a filter for the genes mentioned in Table 1. Since deep intronic variants in collagen genes can be pathogenic, sequencing of the exonic and intronic gene regions may be appropriate in cases with an expected collagen disease (Snead et al., 2021). Genetic testing in individuals suspected of *VCAN*-related vitreoretinopathy should include analyses which are able to detect copy number variations (Li et al., 2020). Genetic tests for retinal detachment may be further improved by including genetic variants identified by GWAS, that confer increased risk for RRD through multifactorial inheritance. Polygenic risk scores can be used to estimate the collective genetic risk of such variants. Genetic risk of retinal detachment is in part intertwined with genetic risk for myopia. In 20% of patients with high myopia (refractive error < -6) pathogenic variants were identified in retinal dystrophy genes, connective tissue genes (e.g. *COL2A1*, *COL18A1*), non-syndromic myopia genes (*ARR3*), and ocular development genes (Haarman et al., 2022). Therefore, genetic testing of myopia-associated genes, in addition to genotyping of myopia risk alleles and calculation of polygenic risk scores for myopia may also be considered (Ghorbani Mojarrad et al., 2020).

#### 6.2. Prophylactic options

When the risk of RRD is deemed high, and this is arbitrary, then prophylaxis becomes tempting. This forces us to consider which individual would benefit from prophylaxis and its form. We shall have to take into account the possibly negative sequelae and the question of optimal timing. Further complicating the matter is the lack of a precise individual RRD risk estimation related to its genotype.

Laser photocoagulation and cryotherapy are the least invasive interventions. These are both aimed to increase retinal adhesion by inducing chorioretinal scar tissue formation. In laser photocoagulation, this is established by light-energy that is converted to thermal energy by the pigment in the RPE. It can be applied without general or local anesthesia. In cryotherapy, this is established by intense cold gases applied transclerally or transconjunctivally, and requires local anesthesia. The rate of macular pucker formation after prophylactic laser photocoagulation or cryotherapy is similar to untreated eyes with retinal lesions: 1–2%. Other complications, such as choroidal detachment, raised intraocular pressure and vitreous hemorrhage are rare (Fraser and Steel, 2010). Placing an encircling band is a more invasive preventive

strategy and is aimed to relieve vitreous traction. In this procedure, a silicone band is placed around the equator of the eye that creates an inward indentation of the sclera and choroid.

The role of prophylactic interventions in individuals with a monogenic disorder involving RRD, is most frequently studied in patients with Stickler syndrome. All studies up to now advocate prophylaxis due to significant reduction of RRD development in patients with Stickler syndrome (Fincham et al., 2014; Khanna et al., 2022; Naravane et al., 2022; Ripandelli et al., 2022). However, this recommendation must be weighed in view of the retrospective designs of these studies. Eyes receiving prophylactic laser photocoagulation for 360° were, during the first 25-years of life, 70% less likely to develop a retinal detachment or retinal tear compared to eyes without prophylaxis (Naravane et al., 2022). The optimal timing for preventive treatment is not yet determined. Patients with COL2A1-related Stickler syndrome have the highest risk for retinal detachment during the first 3 decades of life (Abey Siri et al., 2007; Stickler et al., 2001). It is therefore highly valuable that Fincham and co-authors compared the effectiveness of cryotherapy in patients with Stickler syndrome to an aged-matched control group (Fincham et al., 2014). Bilateral cryotherapy, given at a mean age of 12 years (SD 13), significantly reduces the RRD risk from 37% to 9%. In addition, unilateral cryotherapy in the fellow eye of RD's, given at a mean age of 18 years (SD 13), significantly reduces the RD risk from 70% to 15% in patients with Stickler syndrome (Fincham et al., 2014). The median time to retinal detachment development in the fellow eye without prophylaxis is 4 years (Fincham et al., 2014). There were no significant long-term side effects reported in any of the 293 patients with Stickler syndrome, who received prophylactic cryotherapy according to the standardized Cambridge protocol (Fincham et al., 2014). Minor side-effects, such as conjunctival inflammation, nausea, accommodation insufficiency and photophobia, usually resolved within 4 weeks (Fincham et al., 2014). Unfortunately, baseline and final visual acuities were not compared between treatment and control groups. Scleral buckling combined with cryopexy can further reduce the RRD risk in patients with COL2A1-related Stickler syndrome (Ripandelli et al., 2022). In a retrospective cohort study with an average follow-up of 16 years, no retinal detachment developed in the fellow eye after prophylactic encircling scleral buckling with cryotherapy (Ripandelli et al., 2022). Yet, whether the reduction of RD risk is proportional in light of the invasiveness of these procedures remains open for debate. A better visual outcome after prophylactic intervention is only reported in patients with Stickler syndrome treated with 'extended vitreous base laser', a 360° laser treatment applied from the ora serrata to the equator (Khanna et al., 2022).

The effectiveness of prophylactic treatment in monogenic disorders other than COL2A1-related Stickler syndrome is barely studied. Unfortunately, these treatment effects cannot be extrapolated to other inherited disorders as their etiology might require different preventive strategies and the a-priori RRD risk differs. It is highly plausible that, for example encircling bands, which reduces the amount of vitreoretinal traction, are more effective compared to e.g. laser coagulation, which increases the retina-RPE adhesion, in specific inherited disease or genotypes.

Clinical features such as the presence of a GRT suffices as an argument for prophylactic treatment, even without genetic analyses. Prophylactic laser treatment does not completely prevent RD, yet, it reduces the macula-off RD risk in the fellow eye of GRT patients to nearly zero (Ripandelli et al., 2016; Verhoekx et al., 2019).

The effectiveness of preventive therapy for asymptomatic retinal defects or lattice degenerations remains not supported by evidence in the general population (Blindbaek and Grauslund, 2015; Wilkinson, 2000, 2014). There is only strong evidence available for the prophylactic treatment of symptomatic horseshoe tears (Wilkinson, 2000). Consensus recommendations established by Wilkinson and co-authors suggested to 'sometimes treat' lattice degeneration in the fellow eye of RRD patients (Wilkinson, 2000). Prophylactic treatment of lattice degeneration or

retinal defects in the fellow eye of phakic RRD patients reduces the RD risk from 5% to 2% over 7 years (Folk et al., 1989). Yet, in fellow eyes with more than 6 h of lattice degeneration or high myopia (−6 diopters or worse), prophylactic treatment of these lesions does not reduce the RRD risk (Folk et al., 1989).

Preventive measures can also be aimed at primary prevention of RRD risk factors, such as reducing progression of axial myopia. Myopia development is driven by factors with a significant gene-environment interaction (Enthoven et al., 2019). Fortunately, we are not completely determined by our genes. Klaver and co-authors created a practical lifestyle advice with the '20-20-2 rule', relevant for all youth with progressive myopia (Klaver and Polling, 2020). Pharmaceutical treatment with atropine eye drops and optical interventions such as soft dual focus contact lenses can also significantly reduce eye growth (Klaver and Polling, 2020). Furthermore, improving awareness of RRD risk and symptoms in high risk individuals is important to minimize patient delay. This ultimately improves prognostic factors, such as an attached fovea at time of surgery, associated with a better visual outcome following RRD treatment. Therefore, ophthalmologists should inform RRD patients about the increased RRD risk for their fellow eye and their family members.

The body of literature currently available does not permit one to suggest which groups of patients would benefit from a specific type of prophylaxes at what optimal age. We will need more data to offer a tailor-made approach for individuals with an inherited increased RRD risk. The outcome measures of prophylactic interventions should not only include the development of retinal detachment risk, but also visual acuity measurements. The (age-specific) RRD risk per phenotype, and more specifically per genotype, is an important factor in the decision to offer prophylactic treatment. In addition, the identification of pathogenic genetic variants in certain phenotypes, such as GRT, allows the effectiveness of prophylactic interventions to be examined per genotype. Treatment success of prophylaxes likely depends on the genotype-specific disease mechanism.

### 6.3. Surgical repair

Prophylactic measures can significantly reduce the risk on retinal detachment in patients with a monogenic disease, yet, retinal detachments are not completely prevented. Surgical repair in patients with an inherited form of RRD is often more complex due to factors such as GRTs, PVR, and an abnormal vitreous composition.

Treating retinal detachments in patients with Stickler syndrome often (81%) requires multiple surgeries (Reddy et al., 2016). On average, three vitreoretinal surgeries are necessary to achieve successful retinal re-attachment in patients with Stickler syndrome (Reddy et al., 2016). Final anatomical success can be achieved in 79–100% of eyes (Abey Siri et al., 2007; Reddy et al., 2016).

The choice of type of surgery usually depends on factors such as age, lens status and location of the break. It is highly likely that the success rate of different treatment strategies is influenced by the etiology of RRD. Various inherited vitreoretinopathies might require a different RRD treatment approach. Still, there is no consensus whether different surgical strategies achieve similar success rates in the most common inherited vitreoretinopathy: Stickler syndrome. Primary vitrectomy was associated with higher anatomical success rates compared to scleral buckling (84% vs 67%) in one retrospective cohort study, while no difference in treatment success was identified in a more recent study (Abey Siri et al., 2007; Reddy et al., 2016). The retrospective nature of these studies introduces several biases, as the type of surgery depends patient characteristics and the surgeon's preference. This ultimately leads to a problematic interpretation in the comparison of different types of surgical treatment success in inherited forms of RRD.

Visual function achieved after RRD treatment is significantly associated with duration of symptoms at presentation, foveal involvement, PVR, and primary surgical success (Williamson et al., 2013). In general,

a 6/6 Snellen visual acuity or better is achieved in a quarter (27%) of primary RRD patients, and this is 6/15 or worse in one-third (34%) (Williamson et al., 2013). In patients with Stickler syndrome, the visual outcome after surgery is widely variable. The average final VA is 20/796 (Snellen equivalent), and in one-third of eyes VA improves after surgery, and in one-third it remains stable (Reddy et al., 2016). The presenting VA has significant predictive value in final visual outcome achieved after treatment in general RRD patients as well as patients with Stickler syndrome (Reddy et al., 2016; Williamson et al., 2013).

#### 6.4. Therapeutic options

In recent decades, new perspectives have emerged for the treatment of inherited, potentially blinding, eye diseases. In section 6.4 we discuss possible therapeutic strategies for future treatments of inherited disorders involving RRD, namely: gene therapy and pharmacological agents.

##### 6.4.1. Gene therapy

One of the most promising tools in the treatment for inherited retinal disease, such as retinitis pigmentosa and Leber congenital amaurosis, has become gene therapy. Gene therapy aims to cure disease by correcting the pathogenic effects of genetic variants and its strategy therefore relies on the molecular pathogenesis of disease. Two main gene therapy strategies can be distinguished: gene augmentation (augmenting the defective gene) and genome editing therapy (correcting the genetic defect in the patient's DNA). Loss-of-function variants, usually underlying autosomal recessive or X-linked disease, require treatment that is aimed to restore the synthesis of protein (gene augmentation). The genome editing approach can also be used to correct recurrent loss-of-function mutations (Ledford, 2020). On the other hand, gain-of-function variants or variants with a dominant negative effect, usually identified in autosomal dominant disease, require treatment that is aimed to prevent the expression of an aberrant protein (by gene silencing or genome editing) (Amato et al., 2021). Viral vectors, such as the adeno-associated virus, have been used to introduce genetic material into target cells of the retina. Drug delivery by subretinal injection is most frequently used in inherited retinal diseases and treats a local area. The genome editing tool CRISPR/Cas9 system has been successfully used for transcript degradation in dominantly inherited retinitis pigmentosa caused by rhodopsin mutations, and correction of an intronic splice mutation in autosomal recessive Leber congenital amaurosis caused by *CEP290* mutations (Amato et al., 2021; Ledford, 2020). Treatment of RRD-related disease using gene therapy has not yet been explored, except for gene therapy in retinoschisis (Pennesi et al., 2022). It is unclear whether gene therapy should aim to restore the properties of the vitreous body, weakening the vitreoretinal interface or strengthening the retina to prevent RRD. In addition, it is important to consider which clinical end-points are appropriate to evaluate the effect of gene therapy in this disease. Drug delivery through intravitreal injection, which has a potential widespread effect, may be most appropriate in inherited disease involving RRD. However, vectors injected intravitreally face several challenges, as they must overcome a larger distance to the target cell, and are exposed to the host's immune response in the vitreous body (Ross and Ofri, 2021). Intravitreal injections bear a small risk for RD, therefore their use must be kept to a minimum lest they negate their potential utility. Intravitreal injection of a recombinant adeno-associated virus vector expressing retinoschisin in patients with X-linked retinoschisis, frequently resulted in varying degrees of intraocular inflammation, and retinal detachment in two (7%) patients (Pennesi et al., 2022).

Mice carrying a heterozygous inactivation of *Col2a1* showed a reduced amount of type II in the vitreous body and retina (Kaarniranta et al., 2006). This mouse model could potentially be used to examine whether gene therapy is able to restore vitreous body properties postnatally or prevent retinal degeneration, and whether it can reverse pathological changes seen in Stickler syndrome such as vitreous and

lattice degeneration.

##### 6.4.2. Pharmacological treatment

Another interesting therapeutic approach is pharmacological treatment. Potential strategies include targeting the pathological effect of protein misfolding through the use of chaperones, or separation of vitreoretinal adhesions by using proteases.

Endoplasmic reticulum stress is a significant factor in the pathophysiology of extracellular matrix disease, and is caused by misfolding of proteins (Lamandé and Bateman, 2020). Chaperones are able to prevent misfolding of proteins as they attach to and stabilize unfolded proteins in the endoplasmic reticulum. Disease caused pathogenic variants with a dominant negative effect due to protein misfolding can therefore potentially be treated by chaperone therapy. The use of chaperones is currently explored in fibroblast cell lines of men with Alport syndrome, an inherited disorder caused by pathogenic variants affecting type IV collagen (Chavez et al., 2022). In addition, unfolded proteins induce a stress response that also contribute to pathology in extracellular matrix disorders. Reducing the accumulation of a mutant protein pharmacologically, by stimulating proteasome or ubiquitination, downregulates these stress markers. This approach is pre-clinically explored in a type X collagen disorder, and is considered promising for application in other extracellular matrix misfolding disease (Lamandé and Bateman, 2020).

Enzymatic separation of vitreoretinal adhesions may prevent excess vitreous traction onto the retina. Ocriplasmin, a recombinant truncated form of human plasmin, cleaves proteins present in the vitreoretinal interface such as laminin, fibronectin, and collagen. Its usage for treatment of vitreomacular traction syndrome is associated with several complications, including retinal detachment (Madi et al., 2016). The increased RRD risk might be a consequence of the inhomogeneous vitreolytic effect, which could either be explained by local differences in vitreoretinal adhesion, or a lack of drug exposure in the anterior vitreous. A complete separation of the vitreous cortex and retina, without local vitreoretinal adhesions, is important for the potential use of proteases in RRD treatment or prevention. Another challenge in the use of enzymes which cleave vitreoretinal interface components, is that they should not affect the integrity of the retina. Ocriplasmin has a wide range of substrates and its use is associated with retinal dysfunction and dyschromatopsia. To reduce the retinal toxicity of enzymatic reagents and to limit its activity to the vitreous cavity, a fusion protein of collagenase fused to a hyaluronic acid-binding peptide was constructed: iHA-VMA (Santra et al., 2021). This *Vibrio mimicus* derived collagenase was able to induce a complete PVD without significant changes in the retinal histomorphology in rabbits.

Vitreous replacement therapy: numerous efforts have been made to replace the vitreous body by permanent vitreous substitutes, so far without sufficient effectiveness to be incorporated in clinical practice (Lin et al., 2021). Important characteristics of vitreous substitutes would include transparency, correct refractive index, and biocompatibility. Alginate- and hyaluronic acid-based hydrogels have in vitro been shown to have good optical, viscoelastic, and biocompatible properties required for their use as vitreous substitute (Schulz et al., 2020). A challenging aspect that is generally insufficiently addressed is whether the inhomogeneous structure of the human vitreous due to an inhomogeneous distribution of collagens and hyaluronan should be mimicked (Los, 2008; Sebag and Sebag, 1989). This aspect might be essential for the transport of fluid and macromolecules through the vitreous and maintaining an optimal micro-environment for the lens and retina. Alternatively, vitreous preservation attempts have been considered to reduce the effects of age-related liquefaction (Zhang et al., 2014) and vitreous regeneration may be induced by some hydrogels (Cai and Chen, 2019).

Therapeutic strategies such as gene editing or chaperone treatment may seem a distant approach for inherited disorders involving RRD. Nevertheless, these research fields are evolving rapidly, and the

potential applications are worth exploring for their use in RRD-associated hereditary disease.

## 7. Conclusions

In this review, we provided an extensive overview of the clinical characteristics in monogenic diseases involving RRD, as well as genotype-phenotype correlations of these disorders. Recognizing these inherited disorders is important for patient counseling, genetic testing, and possible prophylactic measures. We provide an overview of genes that may be evaluated by genetic testing in patients suspected of a monogenic disorder with RRD. In the future, the collective genetic risk of variants associated with multifactorial retinal detachment may be estimated by polygenic risk scores. We discussed the influence of pathogenic variants on collagen proteins, posttranslational modification of collagens, proteoglycans, and the TGF- $\beta$  pathway, thereby illustrating the shared pathophysiological mechanisms within the spectrum of RRD-associated disease. A profound understanding of the genotype-phenotype correlations and the molecular disease mechanisms will enable exploration of a more personalized approach for prophylactic interventions and the potential application of new therapeutic strategies in the future.

## Author statement

**Birgit M. Govers:** Conceptualization, writing original draft, writing review and editing, visualization **Ramon A.C. van Huet:** Writing original draft, writing review and editing, supervision **Susanne Roosing:** Writing original draft, writing review and editing **Sander Keijser:** Writing original draft, writing review and editing, supervision **Leonoor I. Los:** Writing original draft, writing review and editing **Anneke I. den Hollander:** Conceptualization, writing original draft, writing review and editing, supervision, funding acquisition, **B. Jeroen Klevering:** Conceptualization, writing original draft, writing review and editing, supervision, funding acquisition.

## Data availability

No data was used for the research described in the article.

## References

- Abeysiri, P., Bunce, C., da Cruz, L., 2007. Outcomes of surgery for retinal detachment in patients with Stickler syndrome: a comparison of two sequential 20-year cohorts. Graefes archive for clinical and experimental ophthalmology = Albrecht von Graefes Archiv für klinische und experimentelle Ophthalmologie 245, 1633–1638.
- Akiba, J., 1993. Prevalence of posterior vitreous detachment in high myopia. *Ophthalmology* 100, 1384–1388.
- Aldahmesh, M.A., Khan, A.O., Alkuraya, H., Adly, N., Anazi, S., Al-Saleh, A.A., Mohamed, J.Y., Hijazi, H., Prabakaran, S., Tacke, M., Al-Khrashi, A., Hashem, M., Reinheckel, T., Assiri, A., Alkuraya, F.S., 2013. Mutations in LRPAP1 are associated with severe myopia in humans. *Am. J. Hum. Genet.* 93, 313–320.
- Alzahran, F., Al Hazzaa, S.A., Tayeb, H., Alkuraya, F.S., 2015. LOXL3, encoding lysyl oxidase-like 3, is mutated in a family with autosomal recessive Stickler syndrome. *Hum. Genet.* 134, 451–453.
- Amato, A., Arrigo, A., Aragona, E., Manitto, M.P., Saladino, A., Bandello, F., Battaglia Parodi, M., 2021. Gene therapy in inherited retinal diseases: an update on current state of the art. *Front. Med.* 8, 750586.
- Annunen, S., Körkkö, J., Czarny, M., Warman, M.L., Brunner, H.G., Kääriäinen, H., Mulliken, J.B., Tranebjærg, L., Brooks, D.G., Cox, G.F., Cruysberg, J.R., Curtis, M.A., Davenport, S.L., Friedrich, C.A., Kaitila, I., Krawczynski, M.R., Latos-Bielenska, A., Mukai, S., Olsen, B.R., Shinno, N., Somer, M., Viikula, M., Zlotogora, J., Prockop, D. J., Ala-Kokko, L., 1999. Splicing mutations of 54-bp exons in the COL11A1 gene cause Marshall syndrome, but other mutations cause overlapping Marshall/Stickler phenotypes. *Am. J. Hum. Genet.* 65, 974–983.
- Arnaud, P., Hanna, N., Aubart, M., Leheup, B., Dupuis-Girod, S., Naudion, S., Lacombe, D., Milleron, O., Odent, S., Faivre, L., Bal, L., Edouard, T., Collod-Beroud, G., Langeois, M., Spentchian, M., Gouya, L., Jondeau, G., Boileau, C., 2017. Homozygous and compound heterozygous mutations in the FBN1 gene: unexpected findings in molecular diagnosis of Marfan syndrome. *J. Med. Genet.* 54, 100–103.
- Asano, M., Yokoyama, K., Oku, K., Matsushita, I., Kimoto, K., Kubota, T., Kondo, H., 2022. Severe foveal hypoplasia and macular degeneration in Stickler syndrome caused by missense mutation in COL2A1 gene. *Ophthalmic Genet.* 1–5.
- Aymé, S., Preus, M., 1984. The Marshall and Stickler syndromes: objective rejection of lumping. *J. Med. Genet.* 21, 34–38.
- Baker, S., Booth, C., Fillman, C., Shapiro, M., Blair, M.P., Hyland, J.C., Ala-Kokko, L., 2011. A loss of function mutation in the COL9A2 gene causes autosomal recessive Stickler syndrome. *Am. J. Med. Genet.* 155a, 1668–1672.
- Bella, J., Hulmes, D.J., 2017. Fibrillar collagens. *Subcell. Biochem.* 82, 457–490.
- Benson, W.E., 1995. Familial exudative vitreoretinopathy. *Trans. Am. Ophthalmol. Soc.* 93, 473–521.
- Bishop, P.N., Crossman, M.V., McLeod, D., Ayad, S., 1994a. Extraction and characterization of the tissue forms of collagen types II and IX from bovine vitreous. *Biochem. J.* 299 (Pt 2), 497–505.
- Bishop, P.N., Holmes, D.F., Kadler, K.E., McLeod, D., Bos, K.J., 2004. Age-related changes on the surface of vitreous collagen fibrils. *Invest. Ophthalmol. Vis. Sci.* 45, 1041–1046.
- Bishop, P.N., Reardon, A.J., McLeod, D., Ayad, S., 1994b. Identification of alternatively spliced variants of type II procollagen in vitreous. *Biochem. Biophys. Res. Commun.* 203, 289–295.
- Blaschke, U.K., Eikenberry, E.F., Hulmes, D.J., Galla, H.J., Bruckner, P., 2000. Collagen XI nucleates self-assembly and limits lateral growth of cartilage fibrils. *J. Biol. Chem.* 275, 10370–10378.
- Blindbaek, S., Grauslund, J., 2015. Prophylactic treatment of retinal breaks—a systematic review. *Acta Ophthalmol.* 93, 3–8.
- Bodanowitz, S., Hesse, L., Pöstgens, H., Kroll, P., 1997. [Retinal detachment in Ehlers-Danlos syndrome. Treatment by pars plana vitrectomy]. *Ophthalmologie* 94, 634–637.
- Boothe, M., Morris, R., Robin, N., 2020. Stickler syndrome: a review of clinical manifestations and the genetics evaluation. *J. Personalized Med.* 10.
- Boutin, T.S., Charteris, D.G., Chandra, A., Campbell, S., Hayward, C., Campbell, A., Nandakumar, P., Hinds, D., Mitry, D., Vitart, V., 2020. Insights into the genetic basis of retinal detachment. *Hum. Mol. Genet.* 29, 689–702.
- Boysen, K.B., La Cour, M., Kessel, L., 2020. Ocular complications and prophylactic strategies in Stickler syndrome: a systematic literature review. *Ophthalmic Genet.* 41, 223–234.
- Brown, D.M., Graemiger, R.A., Hergersberg, M., Schinzel, A., Messmer, E.P., Niemeyer, G., Schneeberger, S.A., Streb, L.M., Taylor, C.M., Kimura, A.E., et al., 1995. Genetic linkage of Wagner disease and erosive vitreoretinopathy to chromosome 5q13-14. *Arch. Ophthalmol.* 113, 671–675. *Chicago, Ill.* : 1960.
- Brown, D.M., Kimura, A.E., Weingeist, T.A., Stone, E.M., 1994. Erosive vitreoretinopathy. A new clinical entity. *Ophthalmology* 101, 694–704.
- Bu, S.C., Kuijter, R., van der Worp, R.J., Li, X.R., Hooymans, J.M., Los, L.I., 2015a. The ultrastructural localization of type II, IV, and VI collagens at the vitreoretinal interface. *PLoS One* 10, e0134325.
- Bu, S.C., Kuijter, R., van der Worp, R.J., van Putten, S.M., Wouters, O., Li, X.R., Hooymans, J.M., Los, L.I., 2015b. Substrate elastic modulus regulates the morphology, focal adhesions, and  $\alpha$ -smooth muscle actin expression of retinal müller cells. *Invest. Ophthalmol. Vis. Sci.* 56, 5974–5982.
- Burin-des-Roziers, C., Rothschild, P.R., Layet, V., Chen, J.M., Ghiotti, T., Leroux, C., Cremers, F.P., Brézin, A.P., Valleix, S., 2017. Deletions overlapping VCAN exon 8 are new molecular defects for wagner disease. *Hum. Mutat.* 38, 43–47.
- Bush, S.J., Chen, L., Tovar-Corona, J.M., Urrutia, A.O., 2017. Alternative splicing and the evolution of phenotypic novelty. *Philos. Trans. R. Soc. Lond. B Biol. Sci.* 372.
- Byer, N.E., 1989. Long-term natural history of lattice degeneration of the retina. *Ophthalmology* 96, 1396–1401 discussion 1401-1392.
- Cai, P., Chen, X., 2019. Hydrogels for artificial vitreous: from prolonged substitution to elicited regeneration. *ACS Mater. Lett.* 1, 285–289.
- Cantrill, H.L., Pederson, J.E., 1984. Experimental retinal detachment. VI. The permeability of the blood-retinal barrier. *Arch. Ophthalmol.* 102, 747–751. *Chicago, Ill.* : 1960.
- Canty, E.G., Kadler, K.E., 2005. Procollagen trafficking, processing and fibrillogenesis. *J. Cell Sci.* 118, 1341–1353.
- Chan, T.K., Alkaabi, M.K., ElBarky, A.M., El-Hattab, A.W., 2019. LOXL3 novel mutation causing a rare form of autosomal recessive Stickler syndrome. *Clin. Genet.* 95, 325–328.
- Chandra, A., Aragon-Martin, J.A., Hughes, K., Gati, S., Reddy, M.A., Deshpande, C., Cormack, G., Child, A.H., Charteris, D.G., Arno, G., 2012. A genotype-phenotype comparison of ADAMTSL4 and FBN1 in isolated ectopia lentis. *Invest. Ophthalmol. Vis. Sci.* 53, 4889–4896.
- Chandra, A., Arno, G., Williamson, K., Sergouniotis, P.I., Preising, M.N., Charteris, D.G., Thompson, D.A., Holder, G.E., Borman, A.D., Davagnanam, I., Webster, A.R., Lorenz, B., FitzPatrick, D.R., Moore, A.T., 2014. Expansion of ocular phenotypic features associated with mutations in ADAMTSL8. *JAMA Ophthalmol* 132, 996–1001.
- Chandra, A., Banerjee, P., Davis, D., Charteris, D., 2015. Ethnic variation in rhegmatogenous retinal detachments. *Eye* 29, 803–807.
- Charvet, B., Guiraud, A., Malbouyres, M., Zwolaneck, D., Guillon, E., Bretaud, S., Monnot, C., Schulze, J., Bader, H.L., Allard, B., Koch, M., Ruggiero, F., 2013. Knockdown of col22a1 gene in zebrafish induces a muscular dystrophy by disruption of the myotendinous junction. *Development* 140, 4602–4613.
- Chavez, E., Rodriguez, J., Drexler, Y., Fornoni, A., 2022. Novel therapies for alport syndrome. *Front. Med.* 9.
- Chen, C., Huang, S., Sun, L., Li, S., Huang, L., Wang, Z., Luo, X., Ding, X., 2020a. Analysis of etiologic factors in pediatric rhegmatogenous retinal detachment with genetic testing. *Am. J. Ophthalmol.* 218, 330–336.
- Chen, C., Sun, L., Li, S., Huang, L., Zhang, T., Wang, Z., Yu, B., Luo, X., Ding, X., 2020b. Novel variants in familial exudative vitreoretinopathy patients with KIF11 mutations and the Genotype-Phenotype correlation. *Exp. Eye Res.* 199, 108165.



- Chen, C., Wang, Z., Sun, L., Huang, S., Li, S., Zhang, A., Luo, X., Huang, L., Ding, X., 2019. Next-generation sequencing in the familial exudative vitreoretinopathy-associated rhegmatogenous retinal detachment. *Invest. Ophthalmol. Vis. Sci.* 60, 2659–2666.
- Christensen, A.E., Fiskerstrand, T., Knappskog, P.M., Boman, H., Rødahl, E., 2010. A novel ADAMTSL4 mutation in autosomal recessive ectopia lentis et pupillae. *Invest. Ophthalmol. Vis. Sci.* 51, 6369–6373.
- Claeys, L., Storoní, S., Eekhoff, M., Elting, M., Wisse, L., Pals, G., Bravenboer, N., Maugeri, A., Micha, D., 2021. Collagen transport and related pathways in Osteogenesis Imperfecta. *Hum. Genet.* 140, 1121–1141.
- Čopíková, J., Paďerová, J., Románková, V., Havlovicová, M., Balasčáková, M., Zelinová, M., Vejvalková, Š., Simandlová, M., Štěpánková, J., Horňová, V., Kantorová, E., Krečková, G., Pospíšilová, J., Boday, A., Meszarosová, A.U., Turnovec, M., Votýpka, P., Lišková, P., Kremlíková Pourouová, R., 2020. Expanding the phenotype spectrum associated with pathogenic variants in the COL2A1 and COL11A1 genes. *Ann. Hum. Genet.* 84, 380–392.
- David, T., Smye, S., Dabbs, T., James, T., 1998. A model for the fluid motion of vitreous humour of the human eye during saccadic movement. *Phys. Med. Biol.* 43, 1385–1399.
- Deans, M.R., Krol, A., Abiraira, V.E., Copley, C.O., Tucker, A.F., Goodrich, L.V., 2011. Control of neuronal morphology by the atypical cadherin Fat3. *Neuron* 71, 820–832.
- Deutman, A.F., 1971. Sex-linked Juvenile Retinoschisis. Deutman AF, Ed. *The Hereditary Dystrophies of the Posterior Pole of the Eye*. Van Gorcum, Assen, the Netherlands, pp. 48–89.
- Dotrelova, D., Karel, I., Clupkova, E., 1997. Retinal detachment in Marfan's syndrome. Characteristics and surgical results. *Retina* 17, 390–396.
- Drolsum, L., Rand-Hendriksen, S., Paus, B., Geiran, O.R., Semb, S.O., 2015. Ocular findings in 87 adults with Ghent-1 verified Marfan syndrome. *Acta Ophthalmol.* 93, 46–53.
- Dunn, N.R., Winnier, G.E., Hargett, L.K., Schrick, J.J., Fogo, A.B., Hogan, B.L., 1997. Haploinsufficient phenotypes in Bmp4 heterozygous null mice and modification by mutations in Gli3 and Alx4. *Dev. Biol.* 188, 235–247.
- Edwards, A.O., 2008. Clinical features of the congenital vitreoretinopathies. *Eye* 22, 1233–1242.
- Edwards, T.L., Burt, B.O., Black, G.C., Perveen, R., Kearns, L.S., Staffieri, S.E., Toomes, C., Buttery, R.G., Mackey, D.A., 2012. Familial retinal detachment associated with COL2A1 exon 2 and FZD4 mutations. *Clin. Exp. Ophthalmol.* 40, 476–483.
- Enthoven, C.A., Tideman, J.W.L., Polling, J.R., Tedja, M.S., Raat, H., Iglesias, A.I., Verhoeven, V.J.M., Klaver, C.C.W., 2019. Interaction between lifestyle and genetic susceptibility in myopia: the Generation R study. *Eur. J. Epidemiol.* 34, 777–784.
- Esfandiari, H., Ansari, S., Mohammad-Rabei, H., Mets, M.B., 2019. Management strategies of ocular abnormalities in patients with marfan syndrome: current perspective. *J. Ophthalmic Vis. Res.* 14, 71–77.
- Ewans, L.J., Colley, A., Gaston-Massuet, C., Gualtieri, A., Cowley, M.J., McCabe, M.J., Anand, D., Lachke, S.A., Scietti, L., Forneris, F., Zhu, Y., Ying, K., Walsh, C., Kirk, E. P., Miller, D., Giunta, C., Sillence, D., Dinger, M., Buckley, M., Roscioli, T., 2019. Pathogenic variants in PLOD3 result in a Stickler syndrome-like connective tissue disorder with vascular complications. *J. Med. Genet.* 56, 629–638.
- Faletta, F., D'Adamo, A.P., Bruno, I., Athanasakis, E., Biskup, S., Esposito, L., Gasparini, P., 2014. Autosomal recessive Stickler syndrome due to a loss of function mutation in the COL9A3 gene. *Am. J. Med. Genet.* 164a, 42–47.
- Fernandes, R.J., Farnand, A.W., Traeger, G.R., Weis, M.A., Eyre, D.R., 2011. A role for prolyl 3-hydroxylase 2 in post-translational modification of fibril-forming collagens. *J. Biol. Chem.* 286, 30662–30669.
- Ferrara, M., Al-Zubaidy, M., Song, A., Avery, P., Laidlaw, D.A., Williamson, T.H., Yorston, D., Steel, D.H.W., 2022. The effect of age on phenotype of primary rhegmatogenous retinal detachment. *Eye*. <https://doi.org/10.1038/s41433-022-02061-y>. Online ahead of print.
- Fincham, G.S., James, S., Spickett, C., Hollingshead, M., Thrasivoulou, C., Poulson, A.V., McNinch, A., Richards, A., Snead, D., Limb, G.A., Snead, M.P., 2018. Posterior vitreous detachment and the posterior hyaloid membrane. *Ophthalmology* 125, 227–236.
- Fincham, G.S., Pasea, L., Carroll, C., McNinch, A.M., Poulson, A.V., Richards, A.J., Scott, J.D., Snead, M.P., 2014. Prevention of retinal detachment in Stickler syndrome: the Cambridge prophylactic cryotherapy protocol. *Ophthalmology* 121, 1588–1597.
- Folk, J.C., Arrindell, E.L., Klugman, M.R., 1989. The fellow eye of patients with phakic lattice retinal detachment. *Ophthalmology* 96, 72–79.
- Foos, R.Y., Wheeler, N.C., 1982. Vitreoretinal junction. Synchysis senilis and posterior vitreous detachment. *Ophthalmology* 89, 1502–1512.
- Fraser, S., Steel, D., 2010. Retinal detachment. *Clin. Evid.* 2010 (11), 710.
- Freeman, H.M., 1978. Fellow eyes of giant retinal breaks. *Trans. Am. Ophthalmol. Soc.* 76, 343–382.
- Fresquet, M., Jowitt, T.A., Ylöstalo, J., Coffey, P., Meadows, R.S., Ala-Kokko, L., Thornton, D.J., Briggs, M.D., 2007. Structural and functional characterization of recombinant matrilin-3 A-domain and implications for human genetic bone diseases. *J. Biol. Chem.* 282, 34634–34643.
- Fujimoto, K., Nagata, T., Matsushita, I., Oku, K., Imagawa, M., Kuniyoshi, K., Hayashi, T., Kimoto, K., Ohji, M., Kusaka, S., Kondo, H., 2021. ULTRA-WIDE field fundus autofluorescence imaging of eyes with stickler syndrome. *Retina* 41, 638–645.
- Fukai, N., Eklund, L., Marneros, A.G., Oh, S.P., Keene, D.R., Tamarkin, L., Niemelä, M., Ilves, M., Li, E., Pihlajaniemi, T., Olsen, B.R., 2002. Lack of collagen XVIII/endostatin results in eye abnormalities. *EMBO J.* 21, 1535–1544.
- García-Arumí, J., Corcóstegui, I.A., Navarro, R., Zapata, M.A., Berrocal, M.H., 2008. Vitreoretinal surgery without schisis cavity excision for the management of juvenile X linked retinoschisis. *Br. J. Ophthalmol.* 92, 1558–1560.
- George, N.D., Yates, J.R., Moore, A.T., 1995. X linked retinoschisis. *Br. J. Ophthalmol.* 79, 697–702.
- George, N.D., Yates, J.R., Moore, A.T., 1996. Clinical features in affected males with X-linked retinoschisis. *Arch. Ophthalmol.* 114, 274–280. Chicago, Ill. : 1960.
- German, O.L., Miranda, G.E., Abraham, C.E., Rotstein, N.P., 2006. Ceramide is a mediator of apoptosis in retina photoreceptors. *Invest. Ophthalmol. Vis. Sci.* 47, 1658–1668.
- Ghazi, N.G., Green, W.R., 2002. Pathology and pathogenesis of retinal detachment. *Eye* 16, 411–421.
- Ghorbani Mojarad, N., Plotnikov, D., Williams, C., Guggenheim, J.A., 2020. Association between polygenic risk score and risk of myopia. *JAMA Ophthalmol* 138, 7–13.
- Gilmour, D.F., 2015. Familial exudative vitreoretinopathy and related retinopathies. *Eye* 29, 1–14.
- Go, S.L., Hoyng, C.B., Klaver, C.C., 2005. Genetic risk of rhegmatogenous retinal detachment: a familial aggregation study. *Arch. Ophthalmol.* 123, 1237–1241. Chicago, Ill. : 1960.
- Go, S.L., Maugeri, A., Mulder, J.J., van Driel, M.A., Cremers, F.P., Hoyng, C.B., 2003. Autosomal dominant rhegmatogenous retinal detachment associated with an Arg453Ter mutation in the COL2A1 gene. *Invest. Ophthalmol. Vis. Sci.* 44, 4035–4043.
- Graemiger, R.A., Niemeier, G., Schneeberger, S.A., Messmer, E.P., 1995. Wagner vitreoretinal degeneration. Follow-up of the original pedigree. *Ophthalmology* 102, 1830–1839.
- Gregersen, P.A., Savarirayan, R., 2019. In: Adam, M.P., Ardinger, H.H., Pagon, R.A., Wallace, S.E., Bean, L.J.H., Mirzaa, G., Amemiya, A. (Eds.), *Type II Collagen Disorders Overview*. GeneReviews®. University of Washington, Seattle, Seattle (WA).
- Greven, C.M., Moreno, R.J., Tasman, W., 1990. Unusual manifestations of X-linked retinoschisis. *Trans. Am. Ophthalmol. Soc.* 88, 211–225. ; discussion 226–218.
- Gulbins, E., Li, P.L., 2006. Physiological and pathophysiological aspects of ceramide. *Am. J. Physiol. Regul. Integr. Comp. Physiol.* 290, R11–R26.
- Guleray, N., Simsek Kiper, P.O., Utine, G.E., Boduroglu, K., Alikasifoglu, M., 2019. Intrafamilial variability of XYLT2-related spondyloocular syndrome. *Eur. J. Med. Genet.* 62, 103585.
- Guo, H., Tong, P., Peng, Y., Wang, T., Liu, Y., Chen, J., Li, Y., Tian, Q., Hu, Y., Zheng, Y., Xiao, L., Xiong, W., Pan, Q., Hu, Z., Xia, K., 2014. Homozygous loss-of-function mutation of the LEPREL1 gene causes severe non-syndromic high myopia with early-onset cataract. *Clin. Genet.* 86, 575–579.
- Guo, L., Elcioglu, N.H., Wang, Z., Demirkol, Y.K., Isguven, P., Matsumoto, N., Nishimura, G., Miyake, N., Ikegawa, S., 2017. Novel and recurrent COL11A1 and COL2A1 mutations in the Marshall-Stickler syndrome spectrum. *Hum Genome Var* 4, 17040.
- Gupta, M.P., Talcott, K.E., Kim, D.Y., Agarwal, S., Mukai, S., 2017. Retinal findings and a novel TINF2 mutation in Revesz syndrome: clinical and molecular correlations with pediatric retinal vasculopathies. *Ophthalmic Genet.* 38, 51–60.
- Gupta, O.P., Benson, W.E., 2005. The risk of fellow eyes in patients with rhegmatogenous retinal detachment. *Curr. Opin. Ophthalmol.* 16, 175–178.
- Haarman, A.E.G., Thiadens, A., van Tienhoven, M., Loudon, S.E., de Klein, J., Brosens, E., Polling, J.R., van der Schoot, V., Bouman, A., Kievit, A.J.A., Hoefloot, L.H., Klaver, C.C.W., Verhoeven, V.J.M., 2022. Whole exome sequencing of known eye genes reveals genetic causes for high myopia. *Hum. Mol. Genet.* 31, 3290–3298.
- Hageman, G.S., Marmor, M.F., Yao, X.Y., Johnson, L.V., 1995. The interphotoreceptor matrix mediates primate retinal adhesion. *Arch. Ophthalmol.* 113, 655–660. Chicago, Ill. : 1960.
- Hahn, L.C., van Schooneveld, M.J., Wesseling, N.L., Florijn, R.J., Ten Brink, J.B., Lissenberg-Witte, B.I., Strubbe, I., Meester-Smoor, M.A., Thiadens, A.A., Diederens, R. M., van Cauwenbergh, C., de Zaeytijd, J., Walraedt, S., de Baere, E., Klaver, C.C.W., Ossewaarde-van Norel, J., van den Born, L.I., Hoyng, C.B., van Genderen, M.M., Sieving, P.A., Leroy, B.P., Bergen, A.A., Boon, C.J.F., 2022. X-linked retinoschisis: novel clinical observations and genetic spectrum in 340 patients. *Ophthalmology* 129, 191–202.
- Halfter, W., Winzen, U., Bishop, P.N., Eller, A., 2006. Regulation of eye size by the retinal basement membrane and vitreous body. *Invest. Ophthalmol. Vis. Sci.* 47, 3586–3594.
- Han, X., Ong, J.S., An, J., Craig, J.E., Gharahkhani, P., Hewitt, A.W., MacGregor, S., 2020. Association of myopia and intraocular pressure with retinal detachment in European descent participants of the UK Biobank cohort: a mendelian randomization study. *JAMA Ophthalmol* 138, 671–678.
- Hanson-Kahn, A., Li, B., Cohn, D.H., Nickerson, D.A., Bamshad, M.J., Hudgins, L., 2018. Autosomal recessive Stickler syndrome resulting from a COL9A3 mutation. *Am. J. Med. Genet.* 176, 2887–2891.
- Hejtmancik, J.F., Jiao, X., Li, A., Sergeev, Y.V., Ding, X., Sharma, A.K., Chan, C.C., Medina, I., Edwards, A.O., 2008. Mutations in KCNJ13 cause autosomal-dominant snowflake vitreoretinal degeneration. *Am. J. Hum. Genet.* 82, 174–180.
- Hejtmancik, J.F., Kantorow, M., 2004. Molecular genetics of age-related cataract. *Exp. Eye Res.* 79, 3–9.
- Hikichi, T., Hirokawa, H., Kado, M., Akiba, J., Kakehashi, A., Yoshida, A., Trempe, C.L., 1995. Comparison of the prevalence of posterior vitreous detachment in whites and Japanese. *Ophthalmic Surg.* 26, 39–43.
- Hindson, V.J., Gallagher, J.T., Halfter, W., Bishop, P.N., 2005. Opticin binds to heparan and chondroitin sulfate proteoglycans. *Invest. Ophthalmol. Vis. Sci.* 46, 4417–4423.
- Hirose, T., Lee, K.Y., Schepens, C.L., 1973. Wagner's hereditary vitreoretinal degeneration and retinal detachment. *Arch. Ophthalmol.* 89, 176–185. Chicago, Ill. : 1960.

- Hirose, T., Lee, K.Y., Schepens, C.L., 1974. Snowflake degeneration in hereditary vitreoretinal degeneration. *Am. J. Ophthalmol.* 77, 143–153.
- Honjo, Y., Nagineni, C.N., Larsson, J., Nandula, S.R., Hooks, J.J., Chan, C.C., Karlsson, S., Kulkarni, A.B., 2007. Neuron-specific TGF-beta signaling deficiency results in retinal detachment and cataracts in mice. *Biochem. Biophys. Res. Commun.* 352, 418–422.
- Hoornaert, K.P., Vereecke, I., Dewinter, C., Rosenberg, T., Beemer, F.A., Leroy, J.G., Bendix, L., Björck, E., Bonduelle, M., Boutte, O., Cormier-Daire, V., De Die-Smulders, C., Dieux-Coeslier, A., Dollfus, H., Elting, M., Green, A., Guerci, V.I., Hennekam, R.C., Hihorts-Hofstee, Y., Holder, M., Hoyng, C., Jones, K.J., Josifova, D., Kaitila, I., Kjaergaard, S., Kroes, Y.H., Lagerstedt, K., Lees, M., Lemerrer, M., Magnani, C., Marcellis, C., Martorell, L., Mathieu, M., McEntagart, M., Mendicino, A., Morton, J., Orazio, G., Paquis, V., Reish, O., Simola, K.O., Smithson, S.F., Temple, K.L., Van Aken, E., Van Bever, Y., van den Ende, J., Van Hagen, J.M., Zelante, L., Zordania, R., De Paepe, A., Leroy, B.P., De Buyzere, M., Coucke, P.J., Mortier, G.R., 2010. Stickler syndrome caused by COL2A1 mutations: genotype-phenotype correlation in a series of 100 patients. *Eur. J. Hum. Genet.* 18, 872–880.
- Hudson, D.M., Joeng, K.S., Werther, R., Rajagopal, A., Weis, M., Lee, B.H., Eyre, D.R., 2015. Post-translationally abnormal collagens of prolyl 3-hydroxylase-2 null mice offer a pathobiological mechanism for the high myopia linked to human LEPREL1 mutations. *J. Biol. Chem.* 290, 8613–8622.
- Hufnagel, S.B., Weaver, K.N., Hufnagel, R.B., Bader, P.I., Schorry, E.K., Hopkin, R.J., 2014. A novel dominant COL11A1 mutation resulting in a severe skeletal dysplasia. *Am. J. Med. Genet.* 164a, 2607–2612.
- Hull, S., Arno, G., Ku, C.A., Ge, Z., Waseem, N., Chandra, A., Webster, A.R., Robson, A.G., Michaelides, M., Weleber, R.G., Davagnanam, I., Chen, R., Holder, G.E., Pennesi, M. E., Moore, A.T., 2016. Molecular and clinical findings in patients with Knobloch syndrome. *JAMA Ophthalmol* 134, 753–762.
- Hysi, P.G., Choquet, H., Khawaja, A.P., Wojciechowski, R., Tedja, M.S., Yin, J., Simcoe, M.J., Patasova, K., Mahroo, O.A., Thai, K.K., Cumberland, P.M., Melles, R.B., Verhoeven, V.J.M., Vitart, V., Segre, A., Stone, R.A., Wareham, N., Hewitt, A.W., Mackey, D.A., Klaver, C.C.W., MacGregor, S., Khaw, P.T., Foster, P.J., Guggenheim, J.A., Rahi, J.S., Jorgenson, E., Hammond, C.J., 2020. Meta-analysis of 542,934 subjects of European ancestry identifies new genes and mechanisms predisposing to refractive error and myopia. *Nat. Genet.* 52, 401–407.
- Janecke, A.R., Li, B., Boehm, M., Krabichler, B., Rohrbach, M., Müller, T., Fuchs, I., Golas, G., Katagiri, Y., Ziegler, S.G., Gahl, W.A., Wilnai, Y., Zoppi, N., Geller, H.M., Giunta, C., Slavotinek, A., Steinmann, B., 2016. The phenotype of the musculocontractural type of Ehlers-Danlos syndrome due to CHST14 mutations. *Am. J. Med. Genet.* 170a, 103–115.
- Jansen, L.M., 1962. Degeneratio hyaloideo-retinalis hereditaria. *Ophthalmologica* 144, 458–464.
- Janssen, E.J.M., Stegmann, A.P.A., Stumpel, C., 2021. Distinguishing Marshall from Stickler syndrome: a clinical and genetic challenge. *Clin. Dysmorphol.* 30, 58–61.
- Jiao, X., Ritter 3rd, R., Hejtmancik, J.F., Edwards, A.O., 2004. Genetic linkage of snowflake vitreoretinal degeneration to chromosome 2q36. *Invest. Ophthalmol. Vis. Sci.* 45, 4498–4503.
- Jobling, A.I., Nguyen, M., Gentile, A., McBrien, N.A., 2004. Isoform-specific changes in scleral transforming growth factor-beta expression and the regulation of collagen synthesis during myopia progression. *J. Biol. Chem.* 279, 18121–18126.
- Johnson, M.W., 2010. Posterior vitreous detachment: evolution and complications of its early stages. *Am. J. Ophthalmol.* 149, 371–382 e371.
- Johnston, P.B., 1991. Traumatic retinal detachment. *Br. J. Ophthalmol.* 75, 18–21.
- Judge, D.P., Dietz, H.C., 2005. Marfan's syndrome. *Lancet* 366, 1965–1976.
- Kaarniranta, K., Ihanamäki, T., Sahlman, J., Pulkkinen, H., Uusitalo, H., Arita, M., Tammi, R., Lammi, M.J., Helminen, H.J., 2006. A mouse model for Stickler's syndrome: ocular phenotype of mice carrying a targeted heterozygous inactivation of type II (pro)collagen gene (Col2a1). *Exp. Eye Res.* 83, 297–303.
- Karczewski, K.J., Solomonson, M., Chao, K.R., Goodrich, J.K., Tiao, G., Lu, W., Riley-Gillis, B.M., Tsai, E.A., Kim, H.I., Zheng, X., Rahimov, F., Esmaeili, S., Grundstad, A. J., Reppell, M., Waring, J., Jacob, H., Sexton, D., Bronson, P.G., Chen, X., Hu, X., Goldstein, J.L., King, D., Vitall, C., Peterba, T., Palmer, D.S., Churchhouse, C., Howrigan, D.P., Zhou, W., Watts, N.A., Nguyen, K., Nguyen, H., Mason, C., Farnham, C., Tolonen, C., Gauthier, L.D., Gupta, N., MacArthur, D.G., Rehm, H.L., Seed, C., Philippakis, A.A., Daly, M.J., Davis, J.W., Runz, H., Miller, M.R., Neale, B. M., 2021. Systematic Single-Variant and Gene-Based Association Testing of 3,700 Phenotypes in 281,850 UK Biobank Exomes. medRxiv, 21259117, 2021.2006.2019.
- Karjosukar, D.W., van Gestel, S.H.C., Qu, J., Kouwenhoven, E.N., Duijkers, L., Garanto, A., Zhou, H., Collin, R.W.J., 2018. An FEVR-associated mutation in ZNF408 alters the expression of genes involved in the development of vasculature. *Hum. Mol. Genet.* 27, 3519–3527.
- Kato, M., Patel, M.S., Levasseur, R., Lobov, I., Chang, B.H., Glass 2nd, D.A., Hartmann, C., Li, L., Hwang, T.H., Brayton, C.F., Lang, R.A., Karsenty, G., Chan, L., 2002. Cbfa1-independent decrease in osteoblast proliferation, osteopenia, and persistent embryonic eye vascularization in mice deficient in Lrp5, a Wnt coreceptor. *J. Cell Biol.* 157, 303–314.
- Kellner, U., Brümmer, S., Foerster, M.H., Wessing, A., 1990. X-linked congenital retinoschisis. Graefe's archive for clinical and experimental ophthalmology = Albrecht von Graefes Archiv für klinische und experimentelle Ophthalmologie 228, 432–437.
- Khan, A.O., AlAbdi, L., Patel, N., Helaby, R., Hashem, M., Abdulwahab, F., AlBadr, F.B., Alkuraya, F.S., 2021. Genetic testing results of children suspected to have Stickler syndrome type collagenopathy after ocular examination. *Mol. Genet. Genomic Med.* 9, e1628.
- Khan, A.O., Aldahmesh, M.A., Alsharif, H., Alkuraya, F.S., 2015. Recessive mutations in LEPREL1 underlie a recognizable lens subluxation phenotype. *Ophthalmic Genet.* 36, 58–63.
- Khan, A.O., Aldahmesh, M.A., Mohamed, J.Y., Al-Mesfer, S., Alkuraya, F.S., 2012. The distinct ophthalmic phenotype of Knobloch syndrome in children. *Br. J. Ophthalmol.* 96, 890–895.
- Khan, A.O., Ghazi, N.G., 2018. The distinct optic disk and peripapillary appearance in Donnai-Barrow syndrome. *Ophthalmic Genet.* 39, 321–324.
- Khanna, S., Rodriguez, S.H., Blair, M.A., Wroblewski, K., Shapiro, M.J., Blair, M.P., 2022. Laser prophylaxis in patients with stickler syndrome. *Ophthalmol. Retina* 6, 263–267.
- Kirin, M., Chandra, A., Charteris, D.G., Hayward, C., Campbell, S., Celap, I., Bencic, G., Vatauvuk, Z., Kirac, I., Richards, A.J., Tenesa, A., Snead, M.P., Fleck, B.W., Singh, J., Harsum, S., Maclaren, R.E., den Hollander, A.I., Dunlop, M.G., Hoyng, C.B., Wright, A.F., Campbell, H., Vitart, V., Mitry, D., 2013. Genome-wide association study identifies genetic risk underlying primary rhegmatogenous retinal detachment. *Hum. Mol. Genet.* 22, 3174–3185.
- Kjellstrom, U., Martell, S., Brobeck, C., Andreasson, S., 2020. Autosomal recessive Stickler syndrome associated with homozygous mutations in the COL9A2 gene. *Ophthalmic Genet.* 1–9.
- Klaver, C., Polling, J.R., 2020. Myopia management in The Netherlands. *Ophthalmic Physiol. Opt.* 40, 230–240.
- Kloekener-Gruissem, B., Amstutz, C., 2016. VCAN-related vitreoretinopathy. In: Adam, M.P., Ardinger, H.H., Pagon, R.A., Wallace, S.E., Bean, L.J.H., Mirzaa, G., Amemiya, A. (Eds.), *GeneReviews*(®). University of Washington, Seattle, Seattle (WA), 1993–2021.
- Kloekener-Gruissem, B., Bartholdi, D., Abdou, M.T., Zimmermann, D.R., Berger, W., 2006. Identification of a genetic defect in the original Wagner syndrome family. *Mol. Vis.* 12, 350–355.
- Knobloch, W.H., Layer, I.M., 1971. Retinal detachment and encephalocele. *J. Pediatr. Ophthalmol.* 8, 181–118.
- Koch, M., Schulze, J., Hansen, U., Ashwodt, T., Keene, D.R., Brunken, W.J., Burgeson, R. E., Bruckner, P., Bruckner-Tuderman, L., 2004. A novel marker of tissue junctions, collagen XXII. *J. Biol. Chem.* 279, 22514–22521.
- Koullis, N., Moysidis, S.N., Yonekawa, Y., Dai, Y.L., Burkemper, B., Wood, E.H., Lertjirachai, I., Todorich, B., Khundkar, T.Z., Chu, Z., Wang, R.K., Williams, G.A., Dresner, K.A., Capone Jr., A., Trese, M.T., Nudleman, E., 2019. Correlating changes in the macular microvasculature and capillary network to peripheral vascular pathologic features in familial exudative vitreoretinopathy. *Ophthalmol. Retina* 3, 597–606.
- Kuhn, F., Aylward, B., 2014. Rhegmatogenous retinal detachment: a reappraisal of its pathophysiology and treatment. *Ophthalmic Res.* 51, 15–31.
- Kuo, D.S., Labelle-Dumais, C., Gould, D.B., 2012. COL4A1 and COL4A2 mutations and disease: insights into pathogenic mechanisms and potential therapeutic targets. *Hum. Mol. Genet.* 21, R97–R110.
- Lamandé, S.R., Bateman, J.F., 2020. Genetic disorders of the extracellular matrix. *Anat. Rec.* 303, 1527–1542.
- Lauritsen, K.F., Lildballe, D.L., Coucke, P.J., Monrad, R., Larsen, D.A., Gregersen, P.A., 2017. A mild form of Stickler syndrome type II caused by mosaicism of COL11A1. *Eur. J. Med. Genet.* 60, 275–278.
- Le Goff, M.M., Bishop, P.N., 2008. Adult vitreous structure and postnatal changes. *Eye* 22, 1214–1222.
- Ledford, H., 2020. CRISPR treatment inserted directly into the body for first time. *Nature* 579, 185.
- Lee, K.E., Klein, B.E., Klein, R., Quandt, Z., Wong, T.Y., 2009. Association of age, stature, and education with ocular dimensions in an older white population. *Arch. Ophthalmol.* 127, 88–93. Chicago, Ill. : 1960.
- Lee, M.M., Ritter, R., Hirose, T., Vu, C.D., Edwards, A.O., 2003. Snowflake vitreoretinal degeneration. *Ophthalmology* 110, 2418–2426.
- Lewis, H., 2003. Peripheral retinal degenerations and the risk of retinal detachment. *Am. J. Ophthalmol.* 136, 155–160.
- Li, S., Li, M., Sun, L., Zhao, X., Zhang, T., Huang, L., Huang, S., Chen, C., Wang, Z., Ding, X., 2020. Identification of novel copy number variations of VCAN gene in three Chinese families with wagner disease. *Genes* 11.
- Li, X., 2003. Incidence and epidemiological characteristics of rhegmatogenous retinal detachment in Beijing, China. *Ophthalmology* 110, 2413–2417.
- Lin, K.T., Wang, A., Nguyen, A.B., Iyer, J., Tran, S.D., 2021. Recent advances in hydrogels: ophthalmic applications in cell delivery, vitreous substitutes, and ocular adhesives. *Biomedicines* 9.
- Loeys, B.L., Dietz, H.C., Braverman, A.C., Callewaert, B.L., De Backer, J., Devreux, R.B., Hihorts-Hofstee, Y., Jondeau, G., Faivre, L., Milewicz, D.M., Pyeritz, R.E., Sponseller, P.D., Wordsworth, P., De Paepe, A.M., 2010. The revised Ghent nosology for the Marfan syndrome. *J. Med. Genet.* 47, 476–485.
- Los, L.L., 2008. The rabbit as an animal model for post-natal vitreous matrix differentiation and degeneration. *Eye* 22, 1223–1232.
- Lumi, X., Bergant, G., Lumi, A., Mahnic, M., 2021. Outcomes of vitrectomy for retinal detachment in a patient with Ehlers-Danlos syndrome type IV: a case report. *J. Med. Case Rep.* 15, 249.
- Lumi, X., Jelen, M.M., Zupan, A., Boštjančić, E., Ravnik-Glavčič, M., Hawlina, M., Glavčič, D., 2020. Single nucleotide polymorphisms in retinal detachment patients with and without proliferative vitreoretinopathy. *Retina* 40, 811–818.
- Määttä, M., Heljasvaara, R., Pihlajaniemi, T., Uusitalo, M., 2007. Collagen XVIII/endostatin shows a ubiquitous distribution in human ocular tissues and endostatin-containing fragments accumulate in ocular fluid samples. Graefe's archive for clinical and experimental ophthalmology = Albrecht von Graefes Archiv für klinische und experimentelle Ophthalmologie 245, 74–81.

- Madi, H.A., Haynes, R.J., Depla, D., de la Cour, M.D., Lesnik-Oberstein, S., Muqit, M.M., Patton, N., Price, N., Steel, D.H., 2016. Rhegmatogenous retinal detachment following intravitreal ocriplamin. Graefes's archive for clinical and experimental ophthalmology = Albrecht von Graefes Archiv fur klinische und experimentelle Ophthalmologie 254, 2333–2338.
- Magliyah, M., Alsalamah, A.K., AlOtaibi, M., Nowilaty, S.R., 2021. A novel c.980C>G variant in OAT results in identifiable gyrate atrophy phenotype associated with retinal detachment in a young female. *Ophthalmic Genet.* 42, 204–208.
- Magliyah, M.S., Alsulaiman, S.M., Nowilaty, S.R., Alkuraya, F.S., Schatz, P., 2020. Rhegmatogenous retinal detachment in nonsyndromic high myopia associated with recessive mutations in LRPAP1. *Ophthalmol. Retina* 4, 77–83.
- Mahroo, O.A.R., Dybowski, R., Wong, R., Williamson, T.H., 2012. Characteristics of rhegmatogenous retinal detachment in pseudophakic and phakic eyes. *Eye* 26, 1114–1121.
- Majava, M., Hoornaert, K.P., Bartholdi, D., Bouma, M.C., Bouman, K., Carrera, M., Devriendt, K., Hurst, J., Kitsos, G., Niedrist, D., Petersen, M.B., Shears, D., Stolte-Dijkstra, L., Van Hagen, J.M., Ala-Kokko, L., Männikkö, M., Mortier, G.R., 2007. A report on 10 new patients with heterozygous mutations in the COL11A1 gene and a review of genotype-phenotype correlations in type XI collagenopathies. *Am. J. Med. Genet.* 143a, 258–264.
- Markova, T., Sparber, P., Borovikov, A., Nagornova, T., Dadali, E., 2021. Clinical and genetic characterization of autosomal recessive stickler syndrome caused by novel compound heterozygous mutations in the COL9A3 gene. *Mol. Genet. Genomic Med.* 9, e1620.
- Marmor, M.F., 1990. Control of subretinal fluid: experimental and clinical studies. *Eye* 4 (Pt 2), 340–344.
- Marmor, M.F., 1993. Chapter 8 Mechanisms of retinal adhesion. *Prog. Retin. Res. um* 12.
- Matsushita, I., Nagata, T., Hayashi, T., Kimoto, K., Kubota, T., Ohji, M., Kusaka, S., Kondo, H., 2017. Foveal hypoplasia in patients with stickler syndrome. *Ophthalmology* 124, 896–902.
- Maumenee, I.H., Traboulsi, E.I., 1985. The ocular findings in Kniest dysplasia. *Am. J. Ophthalmol.* 100, 155–160.
- Mayne, R., Brewton, R.G., Mayne, P.M., Baker, J.R., 1993. Isolation and characterization of the chains of type V/type XI collagen present in bovine vitreous. *J. Biol. Chem.* 268, 9381–9386.
- Meester, J.A.N., Verstraeten, A., Schepers, D., Alaerts, M., Van Laer, L., Loeys, B.L., 2017. Differences in manifestations of Marfan syndrome, Ehlers-Danlos syndrome, and Loeys-Dietz syndrome. *Ann. Cardiothorac. Surg.* 6, 582–594.
- Meguro, A., Ideta, H., Ota, M., Ito, N., Ideta, R., Yonemoto, J., Takeuchi, M., Uemoto, R., Nishide, T., Iijima, Y., Kawagoe, T., Okada, E., Shiota, T., Hagihara, Y., Oka, A., Inoko, H., Mizuki, N., 2012. Common variants in the COL4A4 gene confer susceptibility to lattice degeneration of the retina. *PLoS One* 7, e39300.
- Meredit, S.P., Richards, A.J., Flanagan, D.W., Scott, J.D., Poulson, A.V., Snead, M.P., 2007. Clinical characterisation and molecular analysis of Wagner syndrome. *Br. J. Ophthalmol.* 91, 655–659.
- Micale, L., Morlino, S., Schirizzi, A., Agolini, E., Nardella, G., Fusco, C., Castellana, S., Guameri, V., Villa, R., Bedeschi, M.F., Grammatico, P., Novelli, A., Castori, M., 2020. Exon-trapping assay improves clinical interpretation of COL11A1 and COL11A2 intronic variants in stickler syndrome type 2 and otospondylomegaepiphyseal dysplasia. *Genes* 11.
- Migeon, B.R., 2020. X-linked diseases: susceptible females. *Genet. Med.* 22, 1156–1174.
- Milewicz, D.M., Braverman, A.C., De Backer, J., Morris, S.A., Boileau, C., Maumenee, I. H., Jondeau, G., Evangelista, A., Peyeritz, R.E., 2021. Marfan syndrome. *Nat. Rev. Dis. Prim.* 7, 64.
- Mitry, D., Charteris, D.G., Fleck, B.W., Campbell, H., Singh, J., 2010a. The epidemiology of rhegmatogenous retinal detachment: geographical variation and clinical associations. *Br. J. Ophthalmol.* 94, 678–684.
- Mitry, D., Fleck, B.W., Wright, A.F., Campbell, H., Charteris, D.G., 2010b. Pathogenesis of rhegmatogenous retinal detachment: predisposing anatomy and cell biology. *Retina* 30, 1561–1572.
- Mitry, D., Singh, J., Yorston, D., Siddiqui, M.A., Wright, A., Fleck, B.W., Campbell, H., Charteris, D.G., 2011a. The predisposing pathology and clinical characteristics in the Scottish retinal detachment study. *Ophthalmology* 118, 1429–1434.
- Mitry, D., Williams, L., Charteris, D.G., Fleck, B.W., Wright, A.F., Campbell, H., 2011b. Population-based estimate of the sibling recurrence risk ratio for rhegmatogenous retinal detachment. *Invest. Ophthalmol. Vis. Sci.* 52, 2551–2555.
- Miyakubo, H., Hashimoto, K., Miyakubo, S., 1984. Retinal vascular pattern in familial exudative vitreoretinopathy. *Ophthalmology* 91, 1524–1530.
- Miyamoto, T., Inoue, H., Sakamoto, Y., Kudo, E., Naito, T., Mikawa, T., Mikawa, Y., Isashiki, Y., Osabe, D., Shinohara, S., Shiota, H., Itakura, M., 2005. Identification of a novel splice site mutation of the CSPG2 gene in a Japanese family with Wagner syndrome. *Invest. Ophthalmol. Vis. Sci.* 46, 2726–2735.
- Molday, R.S., Kellner, U., Weber, B.H., 2012. X-linked juvenile retinoschisis: clinical diagnosis, genetic analysis, and molecular mechanisms. *Prog. Retin. Eye Res.* 31, 195–212.
- Mordechai, S., Gradstein, L., Pasanen, A., Ofir, R., El Amour, K., Levy, J., Belfair, N., Lifshitz, T., Joshua, S., Narkis, G., Elbedour, K., Mullyharju, J., Birk, O.S., 2011. High myopia caused by a mutation in LEPREL1, encoding prolyl 3-hydroxylase 2. *Am. J. Hum. Genet.* 89, 438–445.
- Morikawa, M., Derynck, R., Miyazono, K., 2016. TGF- $\beta$  and the TGF- $\beta$  family: context-dependent roles in cell and tissue physiology. *Cold Spring Harbor Perspect. Biol.* 8.
- Morris, N.P., Oxford, J.T., Davies, G.B., Smoody, B.F., Keene, D.R., 2000. Developmentally regulated alternative splicing of the alpha1(XI) collagen chain: spatial and temporal segregation of isoforms in the cartilage of fetal rat long bones. *J. Histochem. Cytochem.* 48, 725–741.
- Mowatt, L., Shun-Shin, G., Price, N., 2003. Ethnic differences in the demand incidence of retinal detachments in two districts in the West Midlands. *Eye* 17, 63–70.
- Mukhopadhyay, A., Nikopoulos, K., Maugeri, A., de Brouwer, A.P., van Nouhuys, C.E., Boon, C.J., Perveen, R., Zegers, H.A., Wittebol-Post, D., van den Biesen, P.R., van der Velde-Visser, S.D., Brunner, H.G., Black, G.C., Hoyng, C.B., Cremers, F.P., 2006. Erosive vitreoretinopathy and wagner disease are caused by intronic mutations in CSPG2/Versican that result in an imbalance of splice variants. *Invest. Ophthalmol. Vis. Sci.* 47, 3565–3572.
- Munns, C.F., Fahiminiya, S., Poudel, N., Munteanu, M.C., Majewski, J., Silience, D.O., Metcalf, J.P., Biggin, A., Glorieux, F., Fassier, F., Rauch, F., Hinsdale, M.E., 2015. Homozygosity for frameshift mutations in XYL2 result in a spondylo-ocular syndrome with bone fragility, cataracts, and hearing defects. *Am. J. Hum. Genet.* 96, 971–978.
- Napolitano, F., Di Iorio, V., Di Iorio, G., Melone, M.A.B., Gianfrancesco, F., Simonelli, F., Esposito, T., Testa, F., Sampaolo, S., 2019. Early posterior vitreous detachment is associated with LAMA5 dominant mutation. *Ophthalmic Genet.* 40, 39–42.
- Naravane, A.V., Belin, P.J., Pierce, B., Quiram, P.A., 2022. Risk and prevention of retinal detachments in patients with stickler syndrome. *Ophthalmic Surg Lasers Imaging Retina* 53, 7–11.
- Nash, B.M., Watson, C.J.G., Hughes, E., Hou, A.L., Loi, T.H., Bennetts, B., Jelovic, D., Polkinghorne, P.J., Gorbato, M., Grigg, J.R., Vincent, A.L., Jamieson, R.V., 2021. Heterozygous COL9A3 variants cause severe peripheral vitreoretinal degeneration and retinal detachment. *Eur. J. Hum. Genet.* 29, 881–886.
- Neptune, E.R., Frischmeyer, P.A., Arking, D.E., Myers, L., Bunton, T.E., Gayraud, B., Ramirez, F., Sakai, L.Y., Dietz, H.C., 2003. Dysregulation of TGF-beta activation contributes to pathogenesis in Marfan syndrome. *Nat. Genet.* 33, 407–411.
- Ng, T.K., Chen, W., Chen, Q., Zheng, Y., Xu, Y., Chen, W., Zhang, G., Chen, J., Pang, C.P., Chen, H., 2020. COL2A1 protective variant reduces sporadic rhegmatogenous retinal detachment severity. *Exp. Eye Res.* 191, 107907.
- Nikopoulos, K., Schrauwen, I., Simon, M., Collin, R.W., Veckeneer, M., Keymolen, K., Van Camp, G., Cremers, F.P., van den Born, L.L., 2011. Autosomal recessive Stickler syndrome in two families is caused by mutations in the COL9A1 gene. *Invest. Ophthalmol. Vis. Sci.* 52, 4774–4779.
- Nixon, T., Richards, A.J., Lomas, A., Abbs, S., Vasudevan, P., McNinch, A., Alexander, P., Snead, M.P., 2020. Inherited and de novo biallelic pathogenic variants in COL11A1 result in type 2 Stickler syndrome with severe hearing loss. *Mol. Genet. Genomic Med.* 8, e1354.
- Nixon, T.R.W., Alexander, P., Richards, A., McNinch, A., Bearcroft, P.W.P., Cobben, J., Snead, M.P., 2019a. Homozygous type IX collagen variants (COL9A1, COL9A2, and COL9A3) causing recessive Stickler syndrome-Expanding the phenotype. *Am. J. Med. Genet.* 179, 1498–1506.
- Nixon, T.R.W., Richards, A., Towns, L.K., Fuller, G., Abbs, S., Alexander, P., McNinch, A., Sandford, R.N., Snead, M.P., 2019b. Bone morphogenetic protein 4 (BMP4) loss-of-function variant associated with autosomal dominant Stickler syndrome and renal dysplasia. *Eur. J. Hum. Genet.* 27, 369–377.
- Okazaki, S., Meguro, A., Ideta, R., Takeuchi, M., Yonemoto, J., Teshigawara, T., Yamane, T., Okada, E., Ideta, H., Mizuki, N., 2019. Common variants in the COL2A1 gene are associated with lattice degeneration of the retina in a Japanese population. *Mol. Vis.* 25, 843–850.
- Okun, E., 1961. Gross and microscopic pathology in autopsy eyes. III. Retinal breaks without detachment. *Am. J. Ophthalmol.* 51, 369–391.
- Papadopoulos, I., Bountouvi, E., Attilakos, A., Gole, E., Dinopoulos, A., Peppas, M., Nikolaidou, P., Papadopoulou, A., 2019. Osteoporosis-pseudoglioma syndrome: clinical, genetic, and treatment-response study of 10 new cases in Greece. *Eur. J. Pediatr.* 178, 323–329.
- Parma, E.S., Körkök, J., Hagler, W.S., Ala-Kokko, L., 2002. Radial perivasculature retinal degeneration: a key to the clinical diagnosis of an ocular variant of Stickler syndrome with minimal or no systemic manifestations. *Am. J. Ophthalmol.* 134, 728–734.
- Patel, N., Hejkal, T., Katz, A., Margalit, E., 2007. Ocular manifestations of Donnai-Barrow syndrome. *J. Child Neurol.* 22, 462–464.
- Patel, N., Shamseldin, H.E., Sakati, N., Khan, A.O., Softa, A., Al-Fadhli, F.M., Hashem, M., Abdulwahab, F.M., Alshidi, T., Alomar, R., Alobeid, E., Wakil, S.M., Colak, D., Alkuraya, F.S., 2017. GZF1 mutations expand the genetic heterogeneity of larsen syndrome. *Am. J. Hum. Genet.* 100, 831–836.
- Pennesi, M.E., Yang, P., Birch, D.G., Weng, C.Y., Moore, A.T., Iannaccone, A., Comander, J.L., Jayasundera, T., Chulay, J., 2022. Intravitreal Delivery of rAAV2(YF-CB-hRS1) Vector for Gene Augmentation Therapy in X-Linked Retinoschisis - 1 Year Clinical Results. *Ophthalmol. Retina*.
- Perveen, R., Hart-Holden, N., Dixon, M.J., Wiszniewski, W., Fryer, A.E., Brunner, H.G., Pinkners, A.J., van Beersum, S.E., Black, G.C., 1999. Refined genetic and physical localization of the Wagner disease (WGN1) locus and the genes CRTLL1 and CSPG2 to a 2- to 2.5-cM region of chromosome 5q14.3. *Genomics* 57, 219–226.
- Peters, A.L., 1995. Retinal detachment in black South Africans. *S. Afr. Med. J.* 85, 158–159.
- Pollack, A., Uchenik, D., Chemke, J., Oliver, M., 1983. Prophylactic laser photocoagulation in hereditary snowflake vitreoretinal degeneration. A family report. *Arch. Ophthalmol.* 101, 1536–1539. Chicago, Ill. : 1960.
- Ponsioen, T.L., Deemter, M., Bank, R.A., Snel, J.M., Zijlstra, G.S., van der Worp, R.J., Hooymans, J.M., Los, L.I., 2009. Mature enzymatic collagen cross-links, hydroxyllysylpyridinoline and lysyllysylpyridinoline, in the aging human vitreous. *Invest. Ophthalmol. Vis. Sci.* 50, 1041–1046.
- Ponsioen, T.L., van der Worp, R.J., van Luyn, M.J., Hooymans, J.M., Los, L.I., 2005. Packages of vitreous collagen (type II) in the human retina: an indication of postnatal collagen turnover? *Exp. Eye Res.* 80, 643–650.

- Ponsioen, T.L., van Luyn, M.J., van der Worp, R.J., van Meurs, J.C., Hooymans, J.M., Los, L.I., 2008. Collagen distribution in the human vitreoretinal interface. *Invest. Ophthalmol. Vis. Sci.* 49, 4089–4095.
- Poulsen, A.V., Hooymans, J.M., Richards, A.J., Bearcroft, P., Murthy, R., Baguley, D.M., Scott, J.D., Snead, M.P., 2004. Clinical features of type 2 Stickler syndrome. *J. Med. Genet.* 41, e107.
- Printzlau, A., Andersen, M., 2004. Pierre Robin sequence in Denmark: a retrospective population-based epidemiological study. *Cleft Palate Craniofac J* 41, 47–52.
- Qu, N., Li, W., Han, D.M., Gao, J.Y., Yang, Z.T., Jiang, L., Liu, T.B., Chen, Y.X., Jiang, X.S., Zhou, L., Wu, J.H., Huang, X., 2022. Mutation spectrum in a cohort with familial exudative vitreoretinopathy. *Mol. Genet. Genomic Med.* 10, e2021.
- Qureshi, M.H., Steel, D.H.W., 2020. Retinal detachment following cataract phacoemulsification—a review of the literature. *Eye* 34, 616–631.
- Rautavuoma, K., Takaluoma, K., Sormunen, R., Myllyharju, J., Kivirikko, K.I., Soininen, R., 2004. Premature aggregation of type IV collagen and early lethality in lysyl hydroxylase 3 null mice. *Proc. Natl. Acad. Sci. U. S. A.* 101, 14120–14125.
- Reddy, D.N., Yonekawa, Y., Thomas, B.J., Nudleman, E.D., Williams, G.A., 2016. Long-term surgical outcomes of retinal detachment in patients with Stickler syndrome. *Clin. Ophthalmol.* 10, 1531–1534.
- Remulla, J.F., Tolentino, F.I., 2001. Retinal detachment in Marfan's syndrome. *Int. Ophthalmol. Clin.* 41, 235–240.
- Ricard-Blum, S., 2011. The collagen family. *Cold Spring Harbor Perspect. Biol.* 3, a004978.
- Richards, A.J., Fincham, G.S., McNinch, A., Hill, D., Poulsen, A.V., Castle, B., Lees, M.M., Moore, A.T., Scott, J.D., Snead, M.P., 2013. Alternative splicing modifies the effect of mutations in COL11A1 and results in recessive type 2 Stickler syndrome with profound hearing loss. *J. Med. Genet.* 50, 765–771.
- Richards, A.J., Martin, S., Yates, J.R., Scott, J.D., Baguley, D.M., Pope, F.M., Snead, M.P., 2000. COL2A1 exon 2 mutations: relevance to the Stickler and Wagner syndromes. *Br. J. Ophthalmol.* 84, 364–371.
- Richards, A.J., McNinch, A., Martin, H., Oakhill, K., Rai, H., Waller, S., Treacy, B., Whittaker, J., Meredith, S., Poulson, A., Snead, M.P., 2010. Stickler syndrome and the vitreous phenotype: mutations in COL2A1 and COL11A1. *Hum. Mutat.* 31, E1461–E1471.
- Richards, A.J., Meredith, S., Poulson, A., Bearcroft, P., Crossland, G., Baguley, D.M., Scott, J.D., Snead, M.P., 2005. A novel mutation of COL2A1 resulting in dominantly inherited rhegmatogenous retinal detachment. *Invest. Ophthalmol. Vis. Sci.* 46, 663–668.
- Richards, A.J., Scott, J.D., Snead, M.P., 2002. Molecular genetics of rhegmatogenous retinal detachment. *Eye* 16, 388–392.
- Richards, A.J., Snead, M.P., 2008. The influence of pre-mRNA splicing on phenotypic modification in Stickler's syndrome and other type II collagenopathies. *Eye* 22, 1243–1250.
- Ripandelli, G., Rossi, T., Cacciamani, A., Scarinci, F., Piaggi, P., Stirpe, M., 2016. Laser prophylactic treatment of the fellow eye in giant retinal tears: long-term follow-up. *Retina* 36, 962–966.
- Ripandelli, G., Rossi, T., Pesci, F.R., Cecere, M., Stirpe, M., 2022. The prophylaxis of fellow-eye retinal detachment in stickler syndrome: a retrospective series. *Retina* 42, 250–255.
- Robertson, D.M., Link, T.P., Rostvold, J.A., 1982. Snowflake degeneration of the retina. *Ophthalmology* 89, 1513–1517.
- Robin, N.H., Moran, R.T., Ala-Kokko, L., 2021. Stickler syndrome. In: Adam, M.P., Ardinger, H.H., Pagon, R.A., Wallace, S.E., Bean, L.J.H., Mirzaa, G., Amemiya, A. (Eds.), *GeneReviews*(®). University of Washington, Seattle, Seattle (WA), 1993–2021.
- Rodahl, E., Mellgren, A.E.C., Boonstra, N.E., Knappskog, P.M., 2020. ADAMTSL4-Related eye disorders. In: Adam, M.P., Ardinger, H.H., Pagon, R.A., Wallace, S.E., Bean, L.J.H., Gripp, K.W., Mirzaa, G.M., Amemiya, A. (Eds.), *GeneReviews*(®). University of Washington, Seattle, Seattle (WA), 1993–2022.
- Ronan, S.M., Tran-Viet, K.N., Burner, E.L., Metlapally, R., Toth, C.A., Young, T.L., 2009. Mutational hot spot potential of a novel base pair mutation of the CSPG2 gene in a family with Wagner syndrome. *Arch. Ophthalmol.* 127, 1511–1519. Chicago, Ill. : 1960.
- Rose, P.S., Levy, H.P., Liberfarb, R.M., Davis, J., Szymko-Bennett, Y., Rubin, B.I., Tsilou, E., Griffith, A.J., Francomano, C.A., 2005. Stickler syndrome: clinical characteristics and diagnostic criteria. *Am. J. Med. Genet.* 138A, 199–207.
- Ross, M., Ofri, R., 2021. The future of retinal gene therapy: evolving from subretinal to intravitreal vector delivery. *Nat. Regen. Res.* 16, 1751–1759.
- Ryan, M.C., Sandell, L.J., 1990. Differential expression of a cysteine-rich domain in the amino-terminal propeptide of type II (cartilage) procollagen by alternative splicing of mRNA. *J. Biol. Chem.* 265, 10334–10339.
- Sadiq, M.A., Vanderveen, D., 2013. Genetics of ectopia lentis. *Semin. Ophthalmol.* 28, 313–320.
- Salchow, D.J., Gehler, P., 2019. Ocular manifestations of Marfan syndrome in children and adolescents. *Eur. J. Ophthalmol.* 29, 38–43.
- Sanabria Ruiz-Colmenares, M.R., Pastor Jimeno, J.C., Garrote Adrados, J.A., Telleria Orriols, J.J., Yugueros Fernández, M.I., 2006. Cytokine gene polymorphisms in retinal detachment patients with and without proliferative vitreoretinopathy: a preliminary study. *Acta Ophthalmol. Scand.* 84, 309–313.
- Santra, M., Sharma, M., Katoch, D., Jain, S., Saikia, U.N., Dogra, M.R., Luthra-Guptasarma, M., 2021. Enzymatic vitreolysis using reengineered *Vibrio mimicus*-derived collagenase. *Mol. Vis.* 27, 125–141.
- Sauer, C.G., Gehrig, A., Warneke-Wittstock, R., Marquardt, A., Ewing, C.C., Gibson, A., Lorenz, B., Jurklics, B., Weber, B.H., 1997. Positional cloning of the gene associated with X-linked juvenile retinoschisis. *Nat. Genet.* 17, 164–170.
- Savage, J., Sheth, S., Leys, A., Nicholson, A., Mack, H.G., Colville, D., 2015. Ocular features in Alport syndrome: pathogenesis and clinical significance. *Clin. J. Am. Soc. Nephrol.* 10, 703–709.
- Schrauwen, I., Sommen, M., Claes, C., Pinner, J., Flaherty, M., Collins, F., Van Camp, G., 2014. Broadening the phenotype of LRP2 mutations: a new mutation in LRP2 causes a predominantly ocular phenotype suggestive of Stickler syndrome. *Clin. Genet.* 86, 282–286.
- Schulz, A., Rickmann, A., Wahl, S., Germann, A., Stanzel, B.V., Januschowski, K., Szurman, P., 2020. Alginate- and hyaluronid acid-based hydrogels as vitreous substitutes: an in vitro evaluation. *Transl. Vis. Sci. Technol.* 9, 34–34.
- Scollo, P., Snead, M.P., Richards, A.J., Pollitt, R., DeVile, C., 2018. Bilateral giant retinal tears in Osteogenesis Imperfecta. *BMC Med. Genet.* 19, 8.
- Scott, J.E., Cummings, C., Brass, A., Chen, Y., 1991. Secondary and tertiary structures of hyaluronan in aqueous solution, investigated by rotary shadowing-electron microscopy and computer simulation. Hyaluronan is a very efficient network-forming polymer. *Biochem. J.* 274 (Pt 3), 699–705.
- Sebag, J., 1987. Ageing of the vitreous. *Eye* 1 (Pt 2), 254–262.
- Sebag, J., 2004. Anomalous posterior vitreous detachment: a unifying concept in vitreoretinal disease. Graefes' archive for clinical and experimental ophthalmology = Albrecht von Graefes Archiv für klinische und experimentelle Ophthalmologie 242, 690–698.
- Sebag, J., Niemyer, M., Koss, M.J., 2014. III.B. Anomalous posterior vitreous detachment and vitreoschisis. In: Sebag, J. (Ed.), *Vitreous: in Health and Disease*. Springer New York, New York, NY, pp. 241–263.
- Sebag, J., Sebag, J., 1989. Biochemistry of the vitreous. In: Sebag, J. (Ed.), *The Vitreous: Structure, Function, and Pathobiology*. Springer New York, New York, NY, pp. 17–33.
- Seery, C.M., Pruett, R.C., Liberfarb, R.M., Cohen, B.Z., 1990. Distinctive cataract in the Stickler syndrome. *Am. J. Ophthalmol.* 110, 143–148.
- Seppinen, L., Pihlajaniemi, T., 2011. The multiple functions of collagen XVIII in development and disease. *Matrix Biol.* 30, 83–92.
- Sergouniotis, P.I., Fincham, G.S., McNinch, A.M., Spickett, C., Poulson, A.V., Richards, A.J., Snead, M.P., 2015. Ophthalmic and molecular genetic findings in Knies dysplasia. *Eye* 29, 475–482.
- Shaikh, S., Garretson, B., Williams, G.A., 2003. Vitreoretinal degeneration complicated by retinal detachment in alport syndrome. *Retina* 23, 119–120.
- Shanske, A.L., Bogdanow, A., Shprintzen, R.J., Marion, R.W., 1997. The Marshall syndrome: report of a new family and review of the literature. *Am. J. Med. Genet.* 70, 52–57.
- Sharma, T., Gopal, L., Shanmugam, M.P., Bhende, P.S., Agrawal, R., Shetty, N.S., Gopalakrishna, M., Rao, M.K., Balusamy, S., 2002. Retinal detachment in Marfan syndrome: clinical characteristics and surgical outcome. *Retina* 22, 423–428.
- Snead, M.P., McNinch, A.M., Poulson, A.V., Bearcroft, P., Silverman, B., Gomersall, P., Parfekt, V., Richards, A.J., 2011. Stickler syndrome, ocular-only variants and a key diagnostic role for the ophthalmologist. *Eye* 25, 1389–1400.
- Snead, M.P., Richards, A.J., McNinch, A.M., Alexander, P., Martin, H., Nixon, T.R.W., Bale, P., Shenker, N., Brown, S., Blackwell, A.M., Poulson, A.V., 2021. Stickler syndrome - lessons from a national cohort. *Eye* 1–7.
- Snead, M.P., Snead, D.R., Mahmood, A.S., Scott, J.D., 1994. Vitreous detachment and the posterior hyaloid membrane: a clinicopathological study. *Eye* 8 (Pt 2), 204–209.
- Snead, M.P., Yates, J.R., 1999. Clinical and molecular genetics of stickler syndrome. *J. Med. Genet.* 36, 353–359.
- Spickett, C., Hysi, P., Hammond, C.J., Prescott, A., Fincham, G.S., Poulson, A.V., McNinch, A.M., Richards, A.J., Snead, M.P., 2016. Deep intronic sequence variants in COL2A1 affect the alternative splicing efficiency of exon 2, and may confer a risk for rhegmatogenous retinal detachment. *Hum. Mutat.* 37, 1085–1096.
- Stephenson, K.A.J., Dockery, A., O'Keefe, M., Green, A., Farrar, G.J., Keegan, D.J., 2020. A FBN1 variant manifesting as non-syndromic ectopia lentis with retinal detachment: clinical and genetic characteristics. *Eye* 34, 690–694.
- Stickler, G.B., Belau, P.G., Farrell, F.J., Jones, J.D., Pugh, D.G., Steinberg, A.G., Ward, L.E., 1965. Hereditary progressive arthro-ophthalmopathy. *Mayo Clin. Proc.* 40, 433–455.
- Stickler, G.B., Hughes, W., Houchin, P., 2001. Clinical features of hereditary progressive arthro-ophthalmopathy (Stickler syndrome): a survey. *Genet. Med.* 3, 192–196.
- Tang, P.H., Velez, G., Tsang, S.H., Bassuk, A.G., Mahajan, V.B., 2019. VCAN canonical splice site mutation is associated with vitreoretinal degeneration and disrupts an MMP proteolytic site. *Invest. Ophthalmol. Vis. Sci.* 60, 282–293.
- Tedja, M.S., Haarman, A.E.G., Meester-Smoor, M.A., Kaprio, J., Mackey, D.A., Guggenheim, J.A., Hammond, C.J., Verhoeven, V.J.M., Klaver, C.C.W., 2019. Imi - myopia genetics report. *Invest. Ophthalmol. Vis. Sci.* 60, M89–m105.
- Tedja, M.S., Wojciechowski, R., Hysi, P.G., Eriksson, N., Furlotte, N.A., Verhoeven, V.J.M., Iglesias, A.L., Meester-Smoor, M.A., Tompson, S.W., Fan, Q., Khawaja, A.P., Cheng, C.Y., Höhn, R., Yamashiro, K., Wenocur, A., Grazal, C., Haller, T., Metspalu, A., Wedenoja, J., Jonas, J.B., Wang, Y.X., Xie, J., Mitchell, P., Foster, P.J., Klein, B.E.K., Klein, R., Paterson, A.D., Hoesseini, S.M., Shah, R.L., Williams, C., Teo, Y.Y., Tham, Y.C., Gupta, P., Zhao, W., Shi, Y., Saw, W.Y., Tai, E.S., Sim, X.L., Huffman, J.E., Polasek, O., Hayward, C., Bencic, G., Rudan, I., Wilson, J.F., Joshi, P.K., Tsujikawa, A., Matsuda, F., Whisenhunt, K.N., Zeller, T., van der Spek, P.J., Haak, R., Meijers-Heijboer, H., van Leeuwen, E.M., Iyengar, S.K., Lass, J.H., Hofman, A., Rivadeneira, F., Uitterlinden, A.G., Vingerling, J.R., Lehtimäki, T., Raitakari, O.T., Biino, G., Concas, M.P., Schwantes-An, T.H., Igo Jr., R.P., Cuellar-Partida, G., Martin, N.G., Craig, J.E., Gharahkhani, P., Williams, K.M., Nag, A., Rahi, J.S., Cumberland, P.M., Delcourt, C., Bellenguez, C., Ried, J.S., Bergen, A.A., Meitinger, T., Gieger, C., Wong, T.Y., Hewitt, A.W., Mackey, D.A., Simpson, C.L., Pfeiffer, N., Pärssinen, O., Baird, P.N., Vitart, V., Amin, N., van Duijn, C.M., Bailey-Wilson, J.E., Young, T.L., Saw, S.M., Stambolian, D., MacGregor, S., Guggenheim, J.

- A., Tung, J.Y., Hammond, C.J., Klaver, C.C.W., 2018. Genome-wide association meta-analysis highlights light-induced signaling as a driver for refractive error. *Nat. Genet.* 50, 834–848.
- Terhal, P.A., Niveststein, R.J., Verver, E.J., Topsakal, V., van Dommelen, P., Hoornaert, K., Le Merrer, M., Zankl, A., Simon, M.E., Smithson, S.F., Marcellis, C., Kerr, B., Clayton-Smith, J., Kinning, E., Mansour, S., Elmslie, F., Goodwin, L., van der Hout, A.H., Veenstra-Knol, H.E., Herkert, J.C., Lund, A.M., Hennekam, R.C., Mégarbané, A., Lees, M.M., Wilson, L.C., Male, A., Hurst, J., Alanay, Y., Annerén, G., Betz, R.C., Bongers, E.M., Cormier-Daire, V., Dieux, A., David, A., Elting, M.W., van den Ende, J., Green, A., van Hagen, J.M., Hertel, N.T., Holder-Espinasse, M., den Hollander, N., Homfray, T., Hove, H.D., Price, S., Raas-Rothschild, A., Rohrbach, M., Schroeter, B., Suri, M., Thompson, E.M., Tobias, E.S., Toutain, A., Vreeburg, M., Wakeling, E., Knoers, N.V., Coucke, P., Mortier, G.R., 2015. A study of the clinical and radiological features in a cohort of 93 patients with a COL2A1 mutation causing spondyloepiphyseal dysplasia congenita or a related phenotype. *Am. J. Med. Genet.* 167a, 461–475.
- Theocharis, D.A., Skandalis, S.S., Noulas, A.V., Papageorgakopoulou, N., Theocharis, A. D., Karamanos, N.K., 2008. Hyaluronan and chondroitin sulfate proteoglycans in the supramolecular organization of the mammalian vitreous body. *Connect. Tissue Res.* 49, 124–128.
- Umair, M., Eckstein, G., Rudolph, G., Strom, T., Graf, E., Hendig, D., Hoover, J., Alanay, J., Meitinger, T., Schmidt, H., Ahmad, W., 2018. Homozygous XYLT2 variants as a cause of spondyloocular syndrome. *Clin. Genet.* 93, 913–918.
- Van Camp, G., Snoeckx, R.L., Hilgert, N., van den Ende, J., Fukuoka, H., Wagatsuma, M., Suzuki, H., Smets, R.M., Vanhoenacker, F., Declau, F., Van de Heyning, P., Usami, S., 2006. A new autosomal recessive form of Stickler syndrome is caused by a mutation in the COL9A1 gene. *Am. J. Hum. Genet.* 79, 449–457.
- Van de Put, M.A.J., Hooymans, J.M.M., Los, L.I., 2013. The incidence of rhegmatogenous retinal detachment in The Netherlands. *Ophthalmology* 120, 616–622.
- van Deemter, M., Pas, H.H., Kuijter, R., van der Worp, R.J., Hooymans, J.M., Los, L.I., 2009. Enzymatic breakdown of type II collagen in the human vitreous. *Invest. Ophthalmol. Vis. Sci.* 50, 4552–4560.
- van Leeuwen, R., Haarman, A.E.G., van de Put, M.A.J., Klaver, C.C.W., Los, L.I., 2021. Association of rhegmatogenous retinal detachment incidence with myopia prevalence in The Netherlands. *JAMA Ophthalmol* 139, 85–92.
- Verhoeck, J.S.N., van Etten, P.G., Wubbels, R.J., van Meurs, J.C., van Overdam, K.A., 2019. PROPHYLACTIC LASER TREATMENT TO DECREASE THE INCIDENCE OF RETINAL DETACHMENT IN FELLOW EYES OF IDIOPATHIC GIANT RETINAL TEARS (Retina).
- Verhoeven, V.J., Hysi, P.G., Wojciechowski, R., Fan, Q., Guggenheim, J.A., Höhn, R., MacGregor, S., Hewitt, A.W., Nag, A., Cheng, C.Y., Yonova-Doing, E., Zhou, X., Ikram, M.K., Buitendijk, G.H., McMahon, G., Kemp, J.P., Pourcain, B.S., Simpson, C. L., Mäkelä, K.M., Lehtimäki, T., Kähönen, M., Paterson, A.D., Hosseini, S.M., Wong, H.S., Xu, L., Jonas, J.B., Pärssinen, O., Wedenoja, J., Yip, S.P., Ho, D.W., Pang, C.P., Chen, L.J., Burdon, K.P., Craig, J.E., Klein, B.E., Klein, R., Haller, T., Metspalu, A., Khor, C.C., Tai, E.S., Aung, T., Vithana, E., Tay, W.T., Barathi, V.A., Chen, P., Li, R., Liao, J., Zheng, Y., Ong, R.T., Döring, A., Evans, D.M., Timpson, N.J., Verkerk, A.J., Meitinger, T., Raitakari, O., Hawthorne, F., Spector, T.D., Karssen, L. C., Pirastu, M., Murgia, F., Ang, W., Mishra, A., Montgomery, G.W., Pennell, C.E., Cumberland, P.M., Cotlarciuc, I., Mitchell, P., Wang, J.J., Schache, M., Janmahasatian, S., Igo Jr., R.P., Lass, J.H., Chew, E., Iyengar, S.K., Gorgels, T.G., Rudan, I., Hayward, C., Wright, A.F., Polasek, O., Vataavuk, Z., Wilson, J.F., Fleck, B., Zeller, T., Mirshahi, A., Müller, C., Uitterlinden, A.G., Rivadeneira, F., Vingerling, J. R., Hofman, A., Oostra, A.M., Amin, N., Bergen, A.A., Teo, Y.Y., Rahi, J.S., Vitart, V., Williams, C., Baird, P.N., Wong, T.Y., Oexle, K., Pfeiffer, N., Mackey, D.A., Young, T. L., van Duijn, C.M., Saw, S.M., Bailey-Wilson, J.E., Stambolian, D., Klaver, C.C., Hammond, C.J., 2013. Genome-wide meta-analyses of multi-ancestry cohorts identify multiple new susceptibility loci for refractive error and myopia. *Nat. Genet.* 45, 314–318.
- Vogiatzi, M.G., Li, D., Tian, L., Garifallou, J.P., Kim, C.E., Hakonarson, H., Levine, M.A., 2018. A novel dominant COL11A1 mutation in a child with Stickler syndrome type II is associated with recurrent fractures. *Osteoporos. Int.* 29, 247–251.
- Vu, C.D., Brown Jr., J., Körkkö, J., Ritter 3rd, R., Edwards, A.O., 2003. Posterior chorioretinal atrophy and vitreous phenotype in a family with Stickler syndrome from a mutation in the COL2A1 gene. *Ophthalmology* 110, 70–77.
- Wang, J., McLeod, D., Henson, D.B., Bishop, P.N., 2003. Age-dependent changes in the basal retinovitreous adhesion. *Invest. Ophthalmol. Vis. Sci.* 44, 1793–1800.
- Warner, L.R., Brown, R.J., Yingst, S.M., Oxford, J.T., 2006. Isoform-specific heparan sulfate binding within the amino-terminal noncollagenous domain of collagen alpha1(XI). *J. Biol. Chem.* 281, 39507–39516.
- Weis, M.A., Hudson, D.M., Kim, L., Scott, M., Wu, J.J., Eyre, D.R., 2010. Location of 3-hydroxyproline residues in collagen types I, II, III, and V/XI implies a role in fibril supramolecular assembly. *J. Biol. Chem.* 285, 2580–2590.
- White, R.J., Wang, Y., Tang, P., Montezuma, S.R., 2017. Knobloch syndrome associated with Polymicrogyria and early onset of retinal detachment: two case reports. *BMC Ophthalmol.* 17, 214.
- Wilkinson, C.P., 2000. Evidence-based analysis of prophylactic treatment of asymptomatic retinal breaks and lattice degeneration. *Ophthalmology* 107, 12–15 ; discussion 15–18.
- Wilkinson, C.P., 2014. Interventions for asymptomatic retinal breaks and lattice degeneration for preventing retinal detachment. *Cochrane Database Syst. Rev.*, Cd003170, 2014.
- Williams, K.M., Verhoeven, V.J., Cumberland, P., Bertelsen, G., Wolfram, C., Buitendijk, G.H., Hofman, A., van Duijn, C.M., Vingerling, J.R., Kuijpers, R.W., Höhn, R., Mirshahi, A., Khawaja, A.P., Luben, R.N., Erke, M.G., von Hanno, T., Mahroo, O., Hogg, R., Gieger, C., Coughard-Grégoire, A., Anastasopoulos, E., Bron, A., Dartigues, J.F., Korobelnik, J.F., Creuzot-Garcher, C., Topouzis, F., Delcourt, C., Rahi, J., Meitinger, T., Fletcher, A., Foster, P.J., Pfeiffer, N., Klaver, C. C., Hammond, C.J., 2015. Prevalence of refractive error in Europe: the European eye epidemiology (E(3)) Consortium. *Eur. J. Epidemiol.* 30, 305–315.
- Williamson, T.H., Shunmugam, M., Rodrigues, I., Dogramaci, M., Lee, E., 2013. Characteristics of rhegmatogenous retinal detachment and their relationship to visual outcome. *Eye* 27, 1063–1069.
- Wong, T.Y., Tielsch, J.M., Schein, O.D., 1999. Racial difference in the incidence of retinal detachment in Singapore. *Arch. Ophthalmol.* 117, 379–383. Chicago, Ill. : 1960.
- Wu, J.H., Liu, J.H., Ko, Y.C., Wang, C.T., Chung, Y.C., Chu, K.C., Liu, T.T., Chao, H.M., Jiang, Y.J., Chen, S.J., Chung, M.Y., 2016. Haploinsufficiency of RCBTB1 is associated with Coats disease and familial exudative vitreoretinopathy. *Hum. Mol. Genet.* 25, 1637–1647.
- Wu, J.J., Woods, P.E., Eyre, D.R., 1992. Identification of cross-linking sites in bovine cartilage type IX collagen reveals an antiparallel type II-type IX molecular relationship and type IX to type IX bonding. *J. Biol. Chem.* 267, 23007–23014.
- Yao, H., Li, H., Yang, S., Li, M., Zhao, C., Zhang, J., Xu, G., Wang, F., 2016. Inhibitory effect of bone morphogenetic protein 4 in retinal pigment epithelial-mesenchymal transition. *Sci. Rep.* 6, 32182.
- Yeowell, H.N., Steinmann, B., 2018. In: Adam, M.P., Ardinger, H.H., Pagon, R.A., Wallace, S.E., Bean, L.J.H., Mirzaa, G., Amemiya, A. (Eds.), PLOD1-Related Kyphoscoliotic Ehlers-Danlos Syndrome, GeneReviews(®). University of Washington, Seattle, Seattle (WA).
- Yuan, M., Ding, X., Yang, Y., Liu, F., Li, J., Liang, X., Zhang, X., Hu, A., Li, Z., Zhan, Z., Lu, L., 2017. Clinical features of affected and undetached fellow eyes in patients with fevr-associated rhegmatogenous retinal detachment. *Retina* 37, 585–591.
- Zhang, Q., Filas, B.A., Roth, R., Heuser, J., Ma, N., Sharma, S., Panitch, A., Beebe, D.C., Shui, Y.B., 2014. Preservation of the structure of enzymatically-degraded bovine vitreous using synthetic proteoglycan mimics. *Invest. Ophthalmol. Vis. Sci.* 55, 8153–8162.
- Zhou, L., Xiao, X., Li, S., Jia, X., Wang, P., Sun, W., Zhang, F., Li, J., Li, T., Zhang, Q., 2018. Phenotypic characterization of patients with early-onset high myopia due to mutations in COL2A1 or COL11A1: why not Stickler syndrome? *Mol. Vis.* 24, 560–573.
- Zhu, Y., Oganessian, A., Keene, D.R., Sandell, L.J., 1999. Type IIA procollagen containing the cysteine-rich amino propeptide is deposited in the extracellular matrix of prechondrogenic tissue and binds to TGF-beta1 and BMP-2. *J. Cell Biol.* 144, 1069–1080.