

University of Groningen

Lumbar Percutaneous Facet Denervation

Stolker, Robert Jan; van Suijlekom, Hans; van Zundert, André; Groen, Gerbrand

Published in:
Regional Nerve Blocks in Anesthesia and Pain Therapy

DOI:
[10.1007/978-3-030-88727-8_47](https://doi.org/10.1007/978-3-030-88727-8_47)

IMPORTANT NOTE: You are advised to consult the publisher's version (publisher's PDF) if you wish to cite from it. Please check the document version below.

Document Version
Publisher's PDF, also known as Version of record

Publication date:
2022

[Link to publication in University of Groningen/UMCG research database](#)

Citation for published version (APA):

Stolker, R. J., van Suijlekom, H., van Zundert, A., & Groen, G. (2022). Lumbar Percutaneous Facet Denervation. In *Regional Nerve Blocks in Anesthesia and Pain Therapy: Imaging-Guided and Traditional Techniques* (pp. 661-666). Springer International Publishing AG. https://doi.org/10.1007/978-3-030-88727-8_47

Copyright

Other than for strictly personal use, it is not permitted to download or to forward/distribute the text or part of it without the consent of the author(s) and/or copyright holder(s), unless the work is under an open content license (like Creative Commons).

The publication may also be distributed here under the terms of Article 25fa of the Dutch Copyright Act, indicated by the "Taverne" license. More information can be found on the University of Groningen website: <https://www.rug.nl/library/open-access/self-archiving-pure/taverne-amendment>.

Take-down policy

If you believe that this document breaches copyright please contact us providing details, and we will remove access to the work immediately and investigate your claim.

Downloaded from the University of Groningen/UMCG research database (Pure): <http://www.rug.nl/research/portal>. For technical reasons the number of authors shown on this cover page is limited to 10 maximum.



Lumbar Percutaneous Facet Denervation

47

Robert Jan Stolker, Hans van Suijlekom,
André van Zundert, and Gerbrand Groen

Contents

General Consideration	661
Indications	661
Anatomy	662
Technique	663
Instructions to Patients	664
Complications and Side Effects	664
Literature Review	664
Outcome	664
Technical Issues	664
Conclusion	666
Suggested Reading	666

General Consideration

The technique of lumbar facet denervation was first described by Shealy in 1974. Later several authors modified this technique. Anatomical studies revealed more exactly the place where the block had to be performed. In this chapter the most common technique will be described using fluoroscopy and bony landmarks. The procedure can be performed in an outpatient setting with the patient awake. Most patients are sufficiently cooperative. Administration of a sedative is rarely

required. As the innervation of the joint and other structures in the dorsal compartment is regarded as two-leveled, the procedure should be performed at two levels. Consequently, considering that one vertebra has two facet joints, one with the superior and one with the inferior articular process, when both facet joints are involved, three subsequent medial branches should be targeted. The procedure can be performed uni- or bilaterally.

R. J. Stolker (✉)

Department of Anesthesiology, Erasmus University Medical Center, Rotterdam, The Netherlands
e-mail: r.stolker@erasmusmc.nl

H. van Suijlekom

Department of Anesthesiology, ICU & Pain Therapy, Catharina-ziekenhuis, Eindhoven, The Netherlands

A. van Zundert

Department of Anaesthesia & Perioperative Medicine, Royal Brisbane & Women's Hospital, Brisbane, QLD, Australia

G. Groen

Pain Center, University Medical Center Groningen, University of Groningen, Haren, The Netherlands

Indications

In the literature there is doubt about the existence of a specific facet syndrome but in Table 47.1 some signs and symptoms are listed, suggesting pain originating from facet joints.

Uni- or bilateral pain lasting longer than 3–6 months not reacting on physical therapy and other conservative management could be an indication for percutaneous facet denervation (PFD). In the absence of a specific facet syndrome, most authors advocate to perform a diagnostic block prior to a PFD. The diagnostic block can be in the form of a medial branch block or an intra-articular block with local anesthetic. The volume of local anesthetic should be limited to 0.5 mL

Table 47.1 Possible signs and symptoms of facet pain in the lumbar region

• Back pain with or without irradiation to the groin, buttock, leg, and sometimes abdomen
• Pain aggravated by rest in any posture (standing, sitting, lying in bed)
• Pain relieved by movement
• Radiculopathy is absent (no neurological deficit)
• Pain should not radiate below the knee
• Morning stiffness
• Awakening by turning in bed
• Pain on anteflexion and/or rotation of the spine
• Paravertebral tenderness

Table 47.2 Contraindications

• Sensory loss
• Lack of cooperativeness
• Bleeding disorders or use of anticoagulants
• Signs of local infection
• Signs of local malignancy
• Presence of osteosynthesis material
• Allergy to local anesthetics

per level in order to achieve a block as selective as possible. The risk of low volume blocks is a lower sensitivity. In the literature a medial branch block is considered to have more predictive value than an intra-articular joint block. Some authors advocate the use of double blocks with local anesthetic with a different duration of action or control blocks with saline in order to rule out placebo response. This is applied in some trials but not common in daily practice. Some patients benefit for a long time after injection of local anesthetic.

Some authors adjust steroids in order to achieve a longer lasting effect of the test procedure, since adding steroids would reduce any coexisting inflammation. Furthermore, the steroids prolong the action of local anesthetic by several hours. Radiological findings per se, such as facet arthritis, are no indication for a PFD. Contraindications are shown in (Table 47.2).

Anatomy

The goal of a lumbar percutaneous facet denervation procedure is to block the medial branch of the dorsal ramus of the spinal nerve (Fig. 47.1). When the dorsal and ventral roots come together, the spinal nerve is formed, which splits up into a ventral and a dorsal ramus. This dorsal ramus divides into a medial and a lateral ramus (=branch). The dorsal or posterior ramus supplies the so-called dorsal compartment of the back, which consists of structures of the back situated behind the intervertebral foramen. This dorsal compartment contains muscles, ligaments,

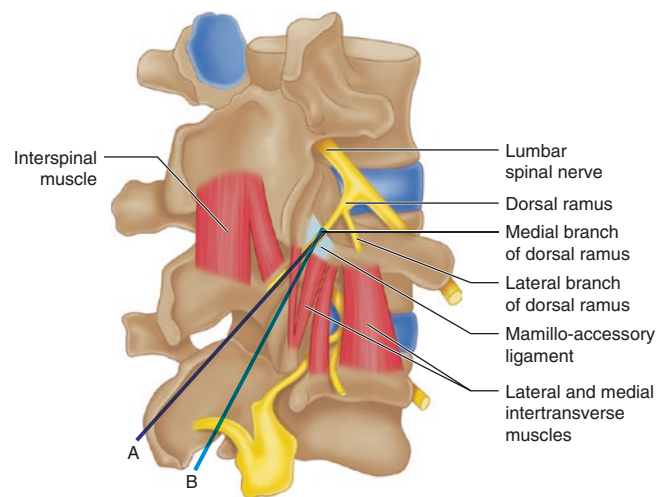


Fig. 47.1 Schematic drawing of dorsal lumbar branches and adjacent spinal muscles. (1) lumbar spinal nerve; (2) dorsal ramus; (3¹) medial branch of dorsal ramus; (3²) lateral branch of dorsal ramus; (4) mamillo-accessory ligament; (5, 6) lateral and medial intertransverse muscles; (7) interspinous muscle. The blue lines depict a parallel (A) and near-parallel (B) insertion of the electrodes. (Cohen et al. 2020. *Redrawn after Paturet* (Paturet G. *Traité d'Anatomie Humaine*, Tome IV, *Système Nerveux*. Masson et Cie, Paris 1964)

blood vessels, and the facet joints. The facet or zygapophyseal joints are joints between the inferior articular process of a vertebra and the superior articular process of the vertebra below. Lumbar facet joints are small joints located in pairs on the back of the spine, providing stability and guiding motion in the lower back. These joints at the dorsal side of the spine form together with the intervertebral disk at the ventral side, the three moving parts of a motion segment.

The facet joints are innervated by medial branches of the dorsal ramus from the corresponding level and the superior adjacent level. As such, the facet joint L5–S1 is innervated by the dorsal rami L4 and L5. Furthermore, the medial branches innervate the skin, ligaments, and lumbar muscles as well, whereas at level L5 the medial branch mostly consists of sensory fibers. The lateral branches innervate muscles. The advocated manner to block the medial branches is in the groove between the superior articular process and the transverse process (Fig. 47.1). The anatomy of the back and the innervation of the posterior compartment are described elsewhere more extensively (see reference 1 in the reference section).

If the joints become painful, they may cause pain in the low back, abdomen, buttocks, groins, or legs. The lumbar zygapophyseal joints are a potential source of low back pain and referred leg pain. However, there are doubts about the existence of a specific facet syndrome. This pain also may originate from other structures (muscles and ligaments) situated in the dorsal compartment.

Table 47.3 Equipment for the procedure

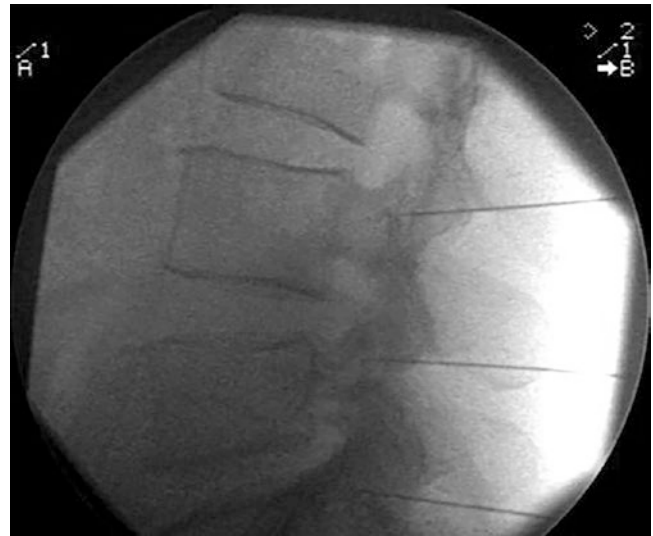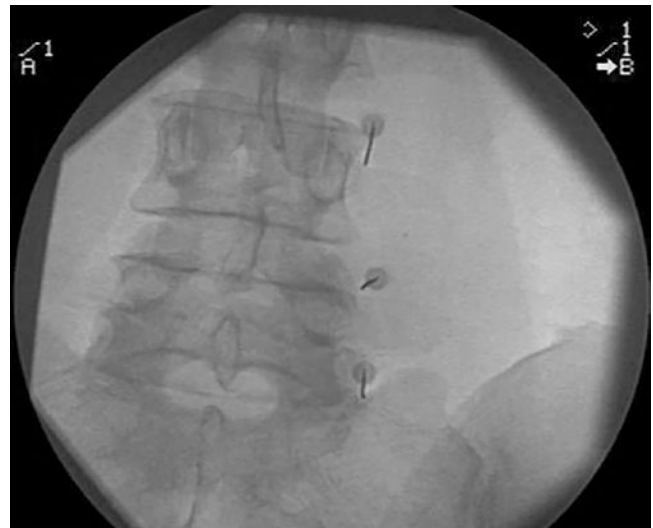
• 2–4 10 cm 22 G radiofrequency (RF) needles with 5 mm blank tip
• Local infiltration (e.g., lidocaine 1–2%)
• Thermocouple 10 cm
• Radiofrequency lesion generator
• Ground plate
• Connecting wires

Technique

This procedure should be performed by an experienced anesthesiologist specialized in invasive pain medicine or under his/her supervision. The equipment is summarized in Table 47.3. The patient is positioned in the prone position on a special table allowing the use of fluoroscopy.

The fluoroscope is directed in anteroposterior view. Sometimes a 5–10° oblique view is needed to obtain more reliable pictures. There is some debate about the angle between the needle and the medial branch. There is debate about the angle of insertion. In the ideal situation the target position of the needle is assumed to be parallel to the medial branch. However, the target position is not always visible in anteroposterior view. As a more lateral approach leads to a less parallel position, the angle of insertion should be as minimal as possible. The insertion place is marked at the skin by using a plastic calliper with a radiopaque ring, which should be placed at the site of the projection of the junction of the transverse and superior articular process. After disinfection of the skin, the needle is inserted following the local infiltration of the skin with 1 mL lidocaine 1–2%, and its position is controlled by fluoroscopic viewing. The direction of the needle is, if necessary, corrected and the needle is advanced until bone contact is made. After correcting the needle position slightly, the tip of the needle is advanced just a little more, keeping bone contact. The depth of the needle is controlled by a fluoroscopic lateral view. The projection of the needle may not be ventral to the dorsal rim of the intervertebral foramen (Figs. 47.2, 47.3, and 47.4).

After obtaining the correct anatomical position, the stylet of the needle is removed, and a thermocouple electrode inserted. The electrode has to be connected to the lesion generator. The ground plate is connected. Stimulation with a 50 Hz current is performed, and the patient is asked to warn if a tingling feeling laterocaudal to the insertion site of the needle and/or at the buttock will be felt. Stimulation threshold must be less than 1 V. The lower the threshold the better the outcome, as the value of the threshold reflects the distance to the nerve. A tingling feeling in the leg refers to a too anterior position of the needle (too close to the spinal nerve), which has to be withdrawn. The same stimulation procedure can be done with a 2 Hz current. As the medial

**Fig. 47.2** Lumbar facet denervation (X-ray lateral view)**Fig. 47.3** Lumbar facet denervation (X-ray anteroposterior view)

branch is a mixed nerve (possible exception L5), a response at the same threshold (or 0.1 V higher) is expected. Local contractions will occur. Contractions of the leg are a sign of a too anterior position, close to the spinal nerve. A threshold for motor response of the leg at 2 V or less, must never be accepted.

If these thresholds are met, 0.5 mL lidocaine 1% (some recommend ≤ 0.5 mL) must be injected after careful aspiration in each needle in order to anesthetize the site of the thermolesion.

After a waiting period of 1–2 min, the radiofrequency lesion at 80 °C for 60 s can be made. In the thoracic spine a similar technique can be used. The position of the needle is somewhat more lateral compared to the lumbar procedure.

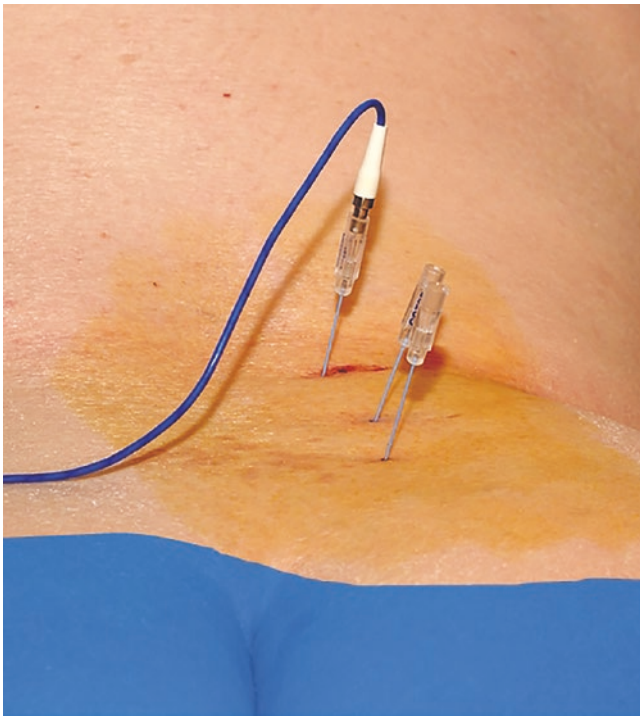


Fig. 47.4 Lumbar facet denervation: positioning needles L4–L5–S1

Instructions to Patients

Patients have to give their (written) informed consent. If patients are using acetylsalicylic acid or other thrombocyte aggregation inhibitors, they are informed to stop 5 days before the procedure. In case of the use of coumarin derivatives, the intake of these drugs should be interrupted and the INR controlled before the procedure. An INR of 1.8 or less is appropriate.

Patients are advised to take a light meal before the procedure. Diabetic patients should not change their habits. Intake of food is free after the procedure. Because of possible temporary leg numbness and/or weakness, it is recommended the patients stay in the hospital at least 1 h following the procedure. Sometimes discharge must be postponed if the patient is unable to walk properly. In all cases the patient has to be driven home accompanied by a competent adult and they are not allowed to participate in the traffic (e.g., drive a car) or take important decisions during the day of operation for legal and liability reasons.

Complications and Side Effects

The main complication is postoperative pain. Not only pain of the needle lasting for a few days but also serious burning pain may occur in 20% of the patients. Patients should be informed that they can experience pain 7–9 days after the

procedure, which can last for a couple of weeks. This pain will subside within 4–6 weeks. Bruising and hematomas at the back occur in a low percentage and are rarely serious. Neurological damage is very rare if the positioning and stimulation have been performed carefully but local numbness may infrequently occur despite a correct technique. The procedure has three preventive moments avoiding neurological deficits: (1) the lateral view (although not completely reliable), (2) electrostimulation, and (3) the injection of 0.5 mL or less lidocaine 1% is too small to anesthetize a spinal nerve when the electrode is accidentally placed too close. Sometimes a leg is numb and/or weak after the procedure due to overflow of the local anesthetic. This will subside spontaneously within a few hours.

Literature Review

Outcome

A recent meta-analysis (including eight studies with 303 patients) shows positive results on short term but limited results on longer term. According to the authors, most studies were of low quality, mainly due to heterogeneity. Inclusion criteria and the use of medial branch or intra-articular blocks with local anesthetics as selection for the procedure are still subject of discussion. Some authors use single test blocks; others double blocks whereas others perform no blocks at all as selection for the PFD. Their patient selection is fully based on clinical signs and symptoms.

Furthermore, technical differences, such as the exact positioning, angle of insertion of the needles, size of the electrodes (larger needles may cause a higher success rate and longer duration but also increase the risk of side effects) making one or more lesions, applied temperature and exposure time, use of electrical stimulation (sensory), are still subject of debate and may be the cause of variable and differing outcomes. Finally, in the studies up to now, also criteria for success (VAS-score, use of medication, inability scales, global perceived effect, or combinations of these) are not equivalent, which hampers a reliable comparison of results.

Technical Issues

At present the main parameters that are considered to increase the efficacy rate of radiofrequency lumbar facet denervation are patient selection and procedural factors. Which patients are to benefit from the procedure? In this regard, it is important to emphasize that pain derived from the locomotor apparatus is relayed on a manner similar to visceral pain, i.e., as pain referred to areas corresponding to the spinal cord segments where the nociceptive input is

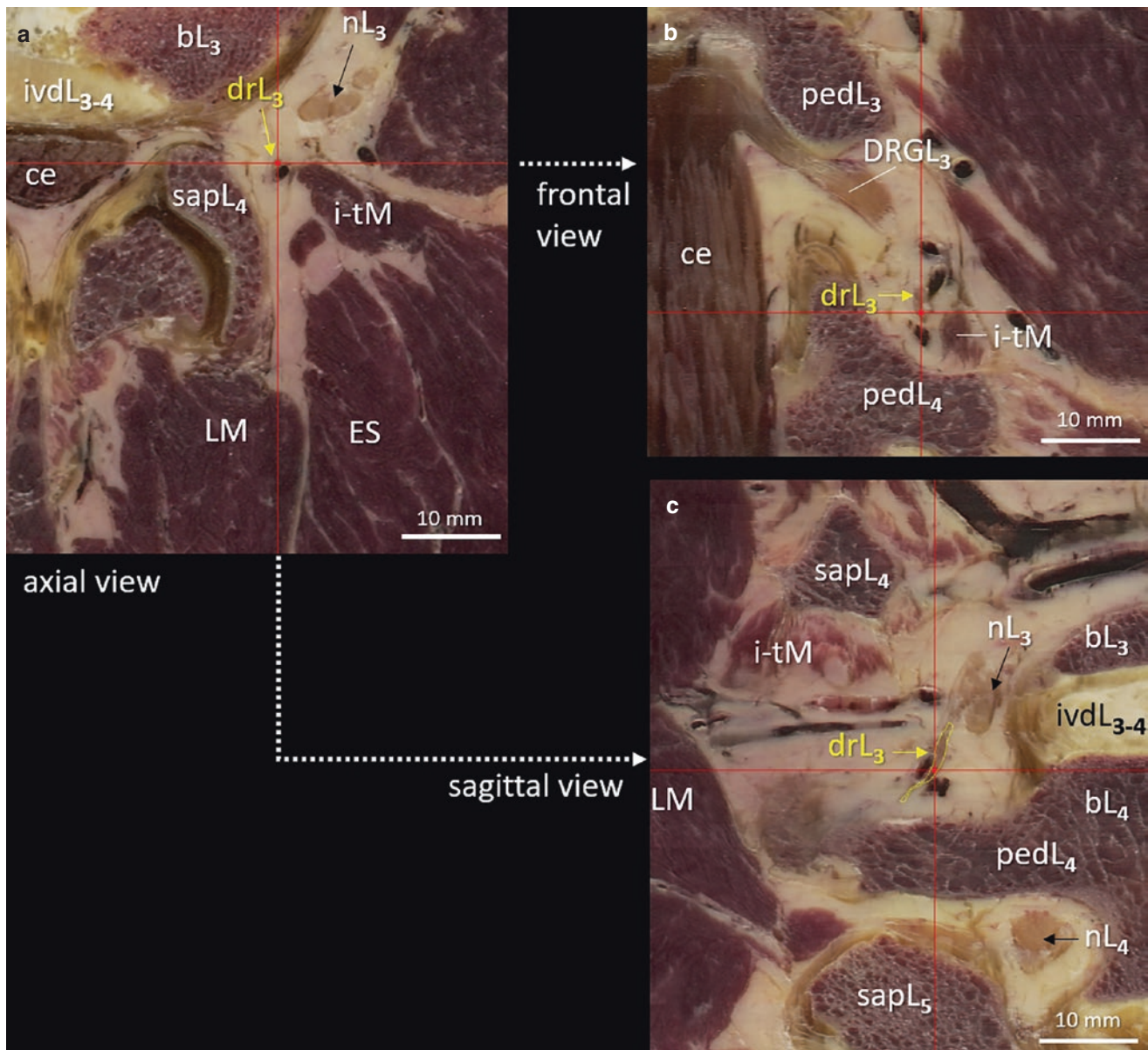


Fig. 47.5 Detailed views of digitized anatomical cross-sections of the spine in the three orthogonal planes *within the same* specimen, i.e., (a) axial, original; (b) frontal, reconstructed; and (c) sagittal, reconstructed. The small red lines depict the level of each cross-section, and the dorsal ramus of L3 (drL3) is highlighted in yellow. Section A is at the lowest

part of the intervertebral foramen L3–L4 and shows the third lumbar spinal nerve (nL3) distal to the dorsal root ganglion (DRGL3). *bL3*, *bL4* body L3, L4, *ce* cauda equina, *ES* erector spinae, *i-tM* intertransverse muscles, *ivd* intervertebral disc, *LM* lumbar multifidus muscle, *ped* pedicle, *sap* superior articular process. Bar represents 10 mm

received. Because of the multisegmental nerve supply of structures of the spine, the overlap in referral pain areas hinders a precision diagnosis of the pain source. Thus, facetogenic pain may not be easily discriminated from pain of other adjacent locomotor sources.

With regard to the technical procedures, low volume diagnostic blocks with local anesthetics are advocated, single vs. double. However, in a recent paper it is put forward that the credibility of randomized, placebo-controlled blocks is higher than that of randomized, comparative local anesthetic blocks (95% vs. 75%). Furthermore, it is generally assumed

that the medial branch of the dorsal ramus of the spinal nerve has a more or less constant trajectory, in which the L1–L4 branches bypass the subjacent transverse process, under the mamillo-accessory ligament (MAL) at the junction of the superior articular process and the root of the transverse process, in a medio-dorsal course. This is also shown in Figs. 47.5 and 47.6 from a digitized series of an anatomically obtained spine of a 43-year-old male, which demonstrate not only the extremely small sizes of the dorsal ramus and its medial branch but also their distance to the adjacent bony structures, which may amount up to 5 mm.

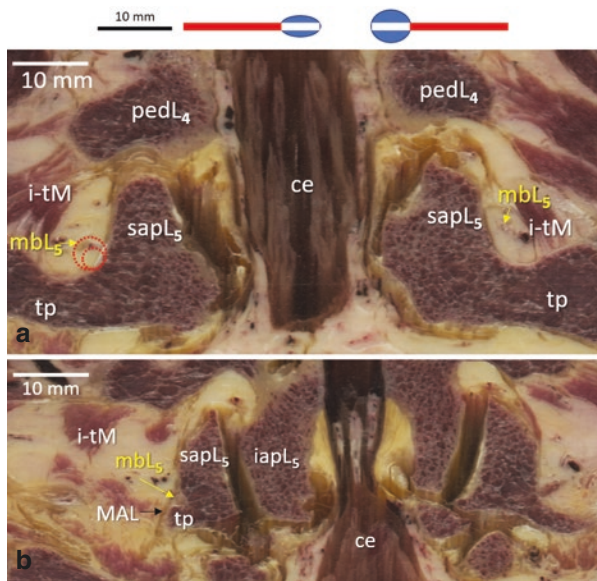


Fig. 47.6 Consecutive frontal views of a digitized spine at the level of L4–L5 showing the more distal trajectory of the medial branch of the dorsal ramus (mbl5) in the groove between superior articular process L5 (sapL5) and the transverse process. It runs between the intertransverse muscles (i-tM) and the bony structures and is accompanied by blood vessels (a); more distal it crosses beneath the mamillo-accessory ligament (MAL) (b). The figure above depicts the relative size of a RF lesion with a 22 G RF needle with 5 mm tip at 80 °C during 60 s. in egg white (2.9 mm max) and meat (4.5 mm max) according to Buijs et al. 2004; Bogduk et al. 1987; Lau et al. 2004. In (a) both lesions are depicted near the medial branch (red dashed lines). *Ce* cauda equina, *iap* inferior articular process. Bar represents 10 mm

In addition, it can be seen that the branches run adjacent to accompanying small blood vessels and lie close to small intrinsic spinal (intertransverse) muscles.

These factors partly may explain the variance in technical denervation of the medial branch when using small diameter RF needle (22 G) and the increase in chance of success with larger lesions as has been reported (some advocate even needle sizes of at least 18 G, enough to hit the target nerve).

Regarding the size of lesion, a RF lesion with a 10 cm RF needle, 5 mm tip, 22 G, and 80 °C for 60 s, the maximum effective radius in vitro (transverse diameter outside needle tip) has been measured as 1.1 ± 0.25 mm in egg white and 1.9 ± 0.30 mm in meat. In case of a 0.7 mm diameter needle, this would mean a cross-sectional diameter of the in vitro lesion 2.9 mm and 4.5 mm max, respectively, as shown above in Fig. 47.6, and at the left in Fig. 47.6a at its highest transverse cross-section near the medial branch.

The same accounts for duration of the lesioning. It was observed that after 60 s, about 87% of the maximal lesion is reached and that a longer duration and a higher temperature

will increase the lesion size as well, sometimes even significantly.

Moreover, from the figures it can be deduced that a larger lesion, although advocated for a longer lasting clinical effect, also would include adjacent nonneural tissues, thus potentially increasing adverse effects and leading to unwanted local tissue destruction with unknown long-term side effects.

Conclusion

A selected group of patients with disabling low back pain, not relieved by conservative measures, attributed to the facet joints, can be successfully treated by lumbar facet joint denervation. Adequate patient selection and the use of an accurate lesioning technique under fluoroscopy are essential elements to get good long-term results following radiofrequency denervation. This minimally invasive technique, however, is appealing given the rather easy accessibility of the medial branch of the dorsal ramus and the reassurance of virtually nonexistent complications.

Suggested Reading

- Bogduk N, Macintosh J, Marsland A. Technical limitations to the efficacy of radiofrequency neurotomy for spinal pain. *Neurosurgery*. 1987;20:529–35.
- Buijs EJ, van Wijk RMAW, Geurts JWM, Weeseman RR, Stolker RJ, Groen GJ. Radiofrequency lumbar facet denervation: a comparative study to the reproducibility of lesion size following two current radiofrequency techniques. *Reg Anesth Pain Med*. 2004;29:400–7.
- Chappell ME, Lakshman R, Trotter P, Abrahams M, Lee M. Radiofrequency denervation for chronic back pain: a systematic review and meta-analysis. *BMJ Open*. 2020;10:e035540. <https://doi.org/10.1136/bmjopen-2019-035540>.
- Cohen SP, Huang JHY, Brummett C. Facet joint pain—advances in patient selection and treatment. *Nat Rev Rheumatol*. 2013;9:101–16.
- Cohen SP, Bhaskar A, Bhatia A, et al. Consensus practice guidelines on interventions for lumbar facet joint pain from a multispecialty, international working group. *Reg Anesth Pain Med*. 2020;45:424–67.
- Cosman ER, Dolensky JR, Hoffman RA. Factors that affect radiofrequency heat lesion size. *Pain Med*. 2014;15:2020–36.
- Engel AJ, Bogduk N. Mathematical validation and credibility of diagnostic blocks for spinal pain. *Pain Med*. 2016;17:1821–8.
- Juch JNS, Maas ET, Ostelo RWJG, et al. Effect of radiofrequency denervation in pain intensity among patients with chronic low back pain. The Mint randomized trials. *JAMA*. 2017;318:68–81.
- Lau P, Mercer S, Bogduk N. The surgical anatomy of lumbar medial branch neurotomy (facet denervation). *Pain Med*. 2005;5:289–98.
- Provenzano DA, Watson TW, Somers DL. The interaction between the composition of preinjected fluids and duration of radiofrequency on lesion size. *Reg Anesth Pain Med*. 2015;40:112–24.
- Stolker RJ, Vervest ACM, Groen GJ. Percutaneous facet denervation in chronic thoracic spinal pain. *Acta Neurochir*. 1993;122:82–90.