

University of Groningen

Animal models for pah and increased pulmonary blood flow

Dickinson, Michael G.; Bartelds, Beatrijs; Berger, Rolf M.F.

Published in:

Pediatric and Congenital Cardiology, Cardiac Surgery and Intensive Care

DOI:

[10.1007/978-1-4471-4619-3_203](https://doi.org/10.1007/978-1-4471-4619-3_203)

IMPORTANT NOTE: You are advised to consult the publisher's version (publisher's PDF) if you wish to cite from it. Please check the document version below.

Document Version

Publisher's PDF, also known as Version of record

Publication date:

2014

[Link to publication in University of Groningen/UMCG research database](#)

Citation for published version (APA):

Dickinson, M. G., Bartelds, B., & Berger, R. M. F. (2014). Animal models for pah and increased pulmonary blood flow. In E. M. Da Cruz, D. Ivy, & J. Jagers (Eds.), *Pediatric and Congenital Cardiology, Cardiac Surgery and Intensive Care* (pp. 2103-2121). Springer-Verlag London Ltd. https://doi.org/10.1007/978-1-4471-4619-3_203

Copyright

Other than for strictly personal use, it is not permitted to download or to forward/distribute the text or part of it without the consent of the author(s) and/or copyright holder(s), unless the work is under an open content license (like Creative Commons).

The publication may also be distributed here under the terms of Article 25fa of the Dutch Copyright Act, indicated by the "Taverne" license. More information can be found on the University of Groningen website: <https://www.rug.nl/library/open-access/self-archiving-pure/taverne-amendment>.

Take-down policy

If you believe that this document breaches copyright please contact us providing details, and we will remove access to the work immediately and investigate your claim.

Downloaded from the University of Groningen/UMCG research database (Pure): <http://www.rug.nl/research/portal>. For technical reasons the number of authors shown on this cover page is limited to 10 maximum.

Michael G. Dickinson, Beatrijs Bartelds, and Rolf M. F. Berger

Abstract

Pulmonary arterial hypertension (PAH), a progressive pulmonary vasoproliferative disorder, is characterized by the development of unique neointimal lesions including concentric laminar intimal fibrosis and plexiform lesions.

In PAH associated with congenital heart disease, increased pulmonary blood flow (i.e., systemic-to-pulmonary shunt) is an essential trigger for the occurrence of neointimal lesions and disease development. Although neointimal development is well described histopathologically, the pathogenesis of flow-induced PAH and its typical vascular lesions is largely unknown.

Animal models play a crucial part in giving insight in new pathobiological processes in PAH and possible new therapeutic targets. However, as for any preclinical model, the pathophysiological mechanism and clinical course have to be comparable to the human disease that it is supposed to mimic. This means that animal models mimicking human PAH ideally are characterized by (1) a hit resembling the human disease, (2) specific vascular remodeling that resembles neointimal development in human PAH, and (3) progressive disease development that leads to right ventricular (RV) dysfunction and eventually death.

Therefore, this chapter will discuss currently used animal models for pulmonary hypertension that are of interest for PAH in the pediatric population, specifically PAH associated with congenital heart disease.

M.G. Dickinson (✉) • B. Bartelds
Center for Congenital Heart Diseases, division Pediatric
Cardiology, Beatrix Children's Hospital, University
Medical Center Groningen, Groningen, The Netherlands
e-mail: m.g.dickinson@umcg.nl; b.bartelds@umcg.nl

R.M.F. Berger
Center for Congenital Heart Diseases, Department of
Pediatric Cardiology, Beatrix Children's Hospital,
University Medical Center Groningen, University of
Groningen, Groningen, The Netherlands
e-mail: r.m.f.berger@umcg.nl

Since increased pulmonary blood flow is known to be a trigger for PAH development in this population, particular emphasis will be put on models with increased pulmonary blood flow.

Keywords

Animal models • Endothelial cells • Histology • Lamb • Mouse • Neointimal lesions • Occlusion • Pulmonary artery • Pulmonary blood flow • Pulmonary hypertension • Rat • Shunt • Vascular remodeling

Introduction

Pulmonary hypertension (PH) has been divided into five groups based on clinical parameters, histopathology, and therapeutic response according to the most recent Dana Point clinical classification update [1]. In this classification, group 1 comprises pulmonary arterial hypertension (PAH), a progressive and life-threatening pulmonary vasoproliferative disorder, which can occur idiopathically (iPAH) or can be associated with specific underlying conditions such as congenital heart defects (CHD) with a systemic-to-pulmonary shunt [1].

Regardless of the underlying cause, PAH is characterized by a characteristic form of pulmonary vascular remodeling, i.e., plexogenic arteriopathy (Fig. 118.1) [2]. While thickening of the media and adventitia layer of the pulmonary arterioles is seen in many forms of PH (e.g., PH associated with hypoxemia), PAH is characterized by the formation of complex cellular and fibrotic lesions with at the end of the spectrum the formation of concentric laminar intimal fibrosis and plexiform lesions (Fig. 118.1) [3, 4]. These neointimal lesions cause intraluminal obstruction characterized by apoptotic dysregulation and proliferation of endothelial cells, smooth muscle cells, fibrosis, and inflammation [3, 5].

Although neointimal lesions in PAH are well described histopathologically, the pathogenesis of neointimal development remains largely unknown. Clinical experience has shown that in patients with CHD who develop PAH, characteristic vascular lesions occur almost exclusively in defects associated with increased pulmonary blood flow, qualifying this increased flow as a trigger for the


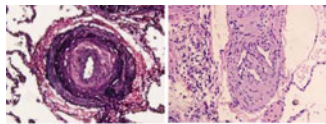

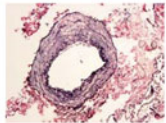

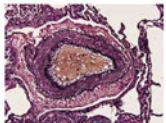

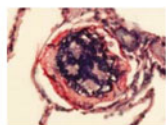

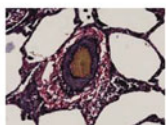
induction of neointimal development. In patients with increased pulmonary blood flow, additional increased pulmonary arterial pressure, as a second trigger, seems to accelerate this development of pulmonary vascular remodeling in PAH [6]. These observations indicate that besides flow certain additional triggers (e.g., increased pressure) are able to accelerate disease development.

PAH is considered irreversible when these neointimal lesions have formed, which results in increased pulmonary vascular resistance, increased right ventricular (RV) workload, and eventual death due to RV failure. Therefore, the complex pathogenesis of PAH needs to be further explored in order to identify potential therapeutic targets and improve future treatment possibilities.

During the past five decades, animal models have played a crucial part in this process and will continue to give investigators new insight for PH research in the future. This chapter will discuss currently used PAH animal models that are of interest for PAH, specifically PAH associated with congenital heart disease. Since increased pulmonary blood flow (i.e., systemic-to-pulmonary shunt) is regarded as a trigger for PAH development in this population, particular emphasis will be put on models with increased pulmonary blood flow.

Animal Models of PAH: General Concept

Animal models remain to play a crucial role in studying both new biomolecular pathways as well as investigating new treatment effects in PAH.

Clinical Classification Group	Characteristics of arteriopathy		Histological examples
1. Pulmonary arterial hypertension, Pulmonary veno-occlusive disease or pulmonary capillary hemangiomas	<ul style="list-style-type: none"> • Medial hypertrophy • Muscularization of arterioles • Cellular proliferation of intima layer • Concentric laminar intimal fibrosis • Plexiform lesions • Fibrinoid necrosis 		
2. PH due to left heart disease	<ul style="list-style-type: none"> • Medial hypertrophy • Muscularization of arterioles and veins • non-obstructive intimal fibrosis • moderate intima fibrosis veins 		
3. PH due to lung disease or hypoxia	<ul style="list-style-type: none"> • Large arteries mostly normal • Medial hypertrophy • Muscularization of arterioles • similar changes to lesser extent in small pulmonary veins 		
4. Chronic Thromboembolic PH (CTEPH)	<ul style="list-style-type: none"> • Mild medial hypertrophy • Eccentric intimal fibrosis • Recanalization of lumen • recent thrombi rare 		
5. PH with unclear multifactorial mechanisms	<ul style="list-style-type: none"> • Muscularization of arterioles and veins (fibrotic lung disease, tumors) • non-obstructive intimal fibrosis (fibrotic lung disease, tumors) • vascular granulomas (sarcoidosis, tuberculosis) • enlargement of bronchial arteries (bronchiectasis) 		

Adapted from Wagenvoort and Mooi

Fig. 118.1 Correlate of the Dana Point 2008 clinical classification with the characteristics of the pulmonary vascular arteriopathy. Group 1, PAH, is characterized by formation of plexiform lesions and concentric laminar

intimal fibrosis. Typical examples of these lesions are presented in the right-sided column (Figure adapted from Mooi and Wagenvoort [2])

However, as for any preclinical model, the pathophysiological mechanisms and clinical course have to be comparable to the human disease that it is supposed to mimic. For PAH this means that an ideal model would include the following:

1. An initiation or trigger of pulmonary vascular remodeling that mimics the human situation (e.g., increased pulmonary blood flow)
2. Pulmonary vascular remodeling that represents plexogenic arteriopathy and includes the development of complex obliterative lesions of the small intra-acinar arteries and media hypertrophy of the smaller preacinar arterioles
3. A progressive disease development that leads to RV dysfunction and eventually death

In addition, the model has to be viable in an experimental setting regarding both functional (hemodynamic and histological assessments)

and biomolecular analyses as well as having a workable period to disease progression.

To date no such ideal model for PAH exists. However, some recent animal models may resemble more closely both pathophysiological mechanisms and clinical course of human PAH compared to more historical animal models of PH.

Development of Pulmonary Vasculature: How Do Animals Compare to Humans?

In choosing a proper animal model for PH research, consideration first has to be given to possible anatomical and developmental differences between specific animals and humans. In humans the pulmonary parenchyma undergoes several

developmental stages of which only alveolar development and vascular maturation remain after birth. Comparable with humans, rats and mice have little alveolar development at birth, whereas, for instance, lambs have already well-developed alveoli at birth, making these species less suitable for studying perinatal changes in pulmonary blood flow and vascular remodeling [7].

Rat lungs on the other hand show quite similar alveolar and capillary surface developments after birth compared to humans [8]. Mice have less pulmonary blood vessel walls and more alveolar space compared to rats [8] which could possibly explain the mild forms of vascular remodeling in most murine PH models, as described below.

The pulmonary vasculature is lined by endothelial cells, which are the first structures to perceive changes in hemodynamic forces as increased blood flow or shear stress. The endothelium is the barrier between blood and the interstitium connected with surrounding vascular cell layers (e.g., smooth muscle cells, fibroblasts) and has an important function in controlling vasomotor tone, regulating permeability, maintenance of hemostatic balance, and immunity. There is increasing evidence that pulmonary vascular endothelial cells change in characteristics with size and location in the pulmonary vascular tree [9]. As the pulmonary vascular tree branches and the size of the pulmonary arteries decreases, the endothelial cell phenotype progresses from pulmonary artery endothelial cells towards pulmonary microvascular endothelial cells, which differ in their permeability and mechanistic properties [9]. These differences may reflect in the location specificity of the pulmonary vascular histomorphological changes observed in PAH. In the larger preacinar arterioles (100–500 μm), only increased medial wall thickness and intimal proliferation are observed, whereas complex neointimal lesions (e.g., laminar concentric intimal fibrosis, plexiform lesions) progressively develop in the normally nonmuscular arterioles (<100 μm), the so-called intra-acinar arteries (Fig. 118.2) [2]. It is debatable whether the most severe lesions, i.e., laminar concentric intimal fibrosis and plexiform lesions, are formed at distal dichotomous branching points [10] or at the branching points of supernumerary

arteries [11]. For murine models, for instance, this is important to realize since there is still debate on whether or not mice even develop supernumerary arteries [7]. This may explain why to date it is so difficult to induce severe PAH in a mouse model, as discussed later [48].

Historical PH Models

Historically, the most widely used animal models of PH have been chronic hypoxia and the monocrotaline-induced PH rodent models. Although these models have added enormously to the understanding of the mechanisms of pulmonary vascular remodeling in PH, they are limited by the lack of typical complex vascular neointimal lesions and severe disease phenotype seen in PAH [12]. Still, these models form a basis for other newer animal models where multiple hits (triggers) result in characteristic pulmonary vascular lesions closely resembling human disease, e.g., the monocrotaline/increased flow model [13, 14] or the hypoxia/Sugen model [15]. Therefore, these historical PH models are briefly discussed below.

Chronic Hypoxia PH Model

The chronic hypoxia model is a widely used example for the investigation of PH in both large and small mammals, particularly rodents. As previously reviewed in greater detail by Stenmark et al. [12], rats, and to lesser extent mice, subjected to either chronic normo- or hypobaric hypoxia demonstrate muscularization of the precapillary arterioles, increase in mean pulmonary artery pressure, and RV hypertrophy. With the exception of fawn-hooded rats which develop severe PH after hypoxia exposure, most rodents only develop a moderate form of vessel muscularization after hypoxia exposure. Furthermore, this muscularization and the disease phenotype are reversible when normal oxygen levels are restored. Moreover, pulmonary neointimal lesions, typical for PAH, as well as apparent RV failure are not seen in the hypoxia-induced PH models [12].

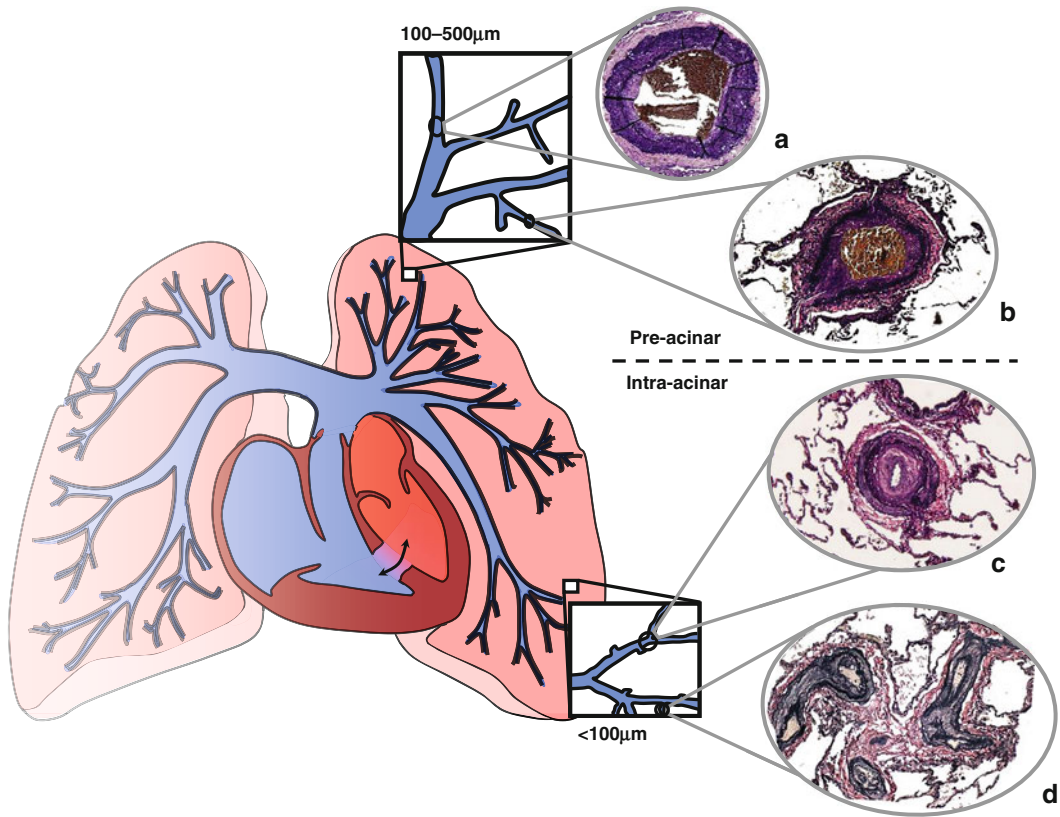


Fig. 118.2 Distribution of the specific lesions seen in pulmonary hypertension throughout the pulmonary vascular tree. The preacinar pulmonary arteries mainly display a phenotype of media hypertrophy (a) and neointimal

formation (b), whereas the intra-acinar arteries have typical occlusive lesions such as concentric intimal fibrosis (c) and plexiform lesions (d)

Monocrotaline PH Rat Model

The effects of monocrotaline on the pulmonary vasculature have been extensively referenced [12, 16, 17]. In short, monocrotaline is a pyrrolizidine alkaloid that can be found in the plant *Crotalaria spectabilis*. Once activated to the toxic monocrotaline pyrrole by cytochrome p450, monocrotaline can induce pulmonary vascular injury characterized by vessel muscularization and arteritis in a dose-dependent manner, as first shown by Lalich et al. [18]. The rat is the most widely used animal for monocrotaline-induced PH due to its reproducibility and ease of manipulation. In mice, monocrotaline is less effective, as mice show little to no pulmonary vascular remodeling even

after a tenfold dose. In rats, muscularization of the small intra-acinar vessels takes place 1–2 weeks after monocrotaline injection followed by RV hypertrophy in 3–4 weeks, depending on the dose used. However, the exact mechanism of monocrotaline-induced vascular remodeling is not known. It has been suggested that perivascular accumulation of inflammatory cells such as macrophages play a role in smooth muscle cell hypertrophy after monocrotaline injection. This concept is supported by the fact that therapy targeting monocyte chemoattractant protein-1 (MCP-1), a proinflammatory cytokine, attenuates muscularization of the small arterioles in monocrotaline-induced PH.

In addition to inflammation, it has been reported that early endothelial damage may

form the basis of monocrotaline-induced vascular remodeling since endothelial cell injury has been observed in early stages of vessel remodeling. However, the endothelial cell injury seen after monocrotaline injection is not followed by the typical endothelial cell proliferation as seen in neointimal lesions in human PAH. The lack of obstructive vascular remodeling with MCT-induced PH might explain the observation that almost every therapeutic intervention used in the monocrotaline model is able to either prevent or reduce pulmonary vascular remodeling and disease development [12, 16].

Increased Pulmonary Blood Flow and Vascular Remodeling

As stated above, in congenital heart disease (CHD) patients, increased pulmonary blood flow is a trigger for PAH-specific vascular remodeling. In patients with CHD associated with a pretricuspid shunt, where the vascular bed is solely subjected to increased pulmonary blood flow, but not to systemic pressure, 10–20 % of patients will develop progressive PAH and this usually requires 30–40 years to develop [19]. In contrast, in patients with unrestrictive posttricuspid shunts, in which the pulmonary vascular bed is subjected to both increased blood flow and systemic pressure, PAH develops, if left untreated, in virtually all patients and mostly within the first years of life. In other words, in patients with CHD, increased pulmonary blood flow is a trigger for PAH-specific neointimal development in a seemingly “susceptible” subset of patients, while second hits, such as increased pulmonary arterial pressure, can accelerate the development of pulmonary vascular remodeling in PAH.

Models of Increased Pulmonary Blood Flow

The role of increased pulmonary blood flow on vascular remodeling has been previously studied in experimental setting both in larger

animals [20–23] and in rodents [24]. Various pathways that are known to play a role in human PAH have been studied in models of increased pulmonary blood flow. First, several studies have reported that systemic-to-pulmonary shunting in young lambs and piglets results in alterations of the endothelin pathway [21, 22, 25]. In these models, endothelin-1 and endothelin A receptor expression is first upregulated followed by increased endothelin B receptor expression after chronic (>8 weeks) shunting which were found on the smooth muscle cells of the pulmonary vessels [21]. Chronically increased flow has also been shown to increase endothelial nitric oxide synthesis (eNOS), but not inducible nitric oxide synthesis (iNOS), activity in lung tissue and pulmonary arteries subjected to increased flow [21, 22]. Interestingly, NO availability itself was reported to decrease after increased flow exposure, which has been suggested to be the result of peroxynitrite production that leads to scavenging of NO and decreased production of NO by eNOS. In addition to biomolecular investigation, several treatment effects have been reported in these models, including beneficial effects on pulmonary vascular resistance and vascular wall thickness after preventive treatment with PAH-specific drugs, i.e., endothelin receptor antagonists (ERAs) [26, 27], phosphodiesterase-5 inhibitors [26], prostacyclin, and inhaled NO [28].

In all models described above, increased pulmonary blood flow results in development of media hypertrophy of the pulmonary vessels (Fig. 118.3). Obliterative lesions of the intracinar vessels or advanced plexiform lesions have not been found. Hence, although the hit is clinically relevant, i.e., (i) increased pulmonary blood flow, the pulmonary vascular remodeling is not representative for group I PAH (ii), which makes it difficult to extrapolate the therapeutic effects to human PAH where irreversible neointimal lesions form the basis of therapeutic targeting. A possible explanation for the moderate form of vascular remodeling is that in these larger rodent models the duration of shunting was not sufficient to produce complex lesions – weeks instead of months or years. Indeed, chronic (>a year) systemic-to-pulmonary shunting in both

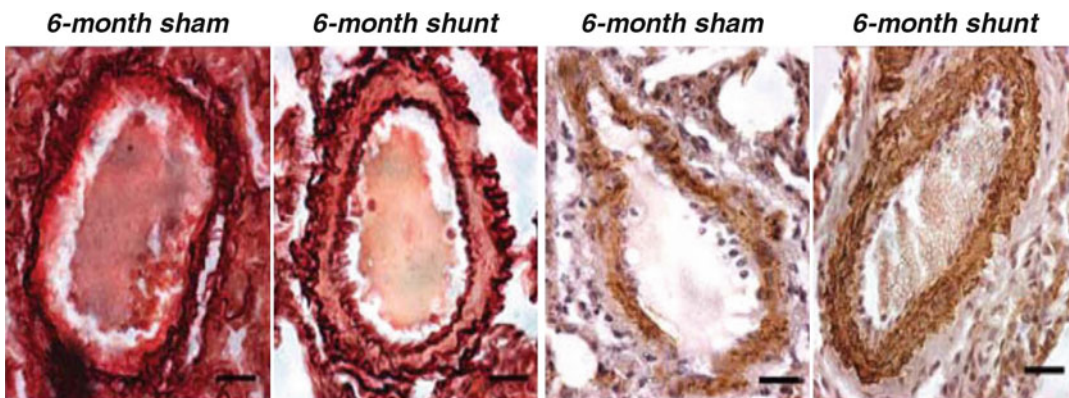


Fig. 118.3 Effects of increased pulmonary blood flow on the pulmonary vasculature in large animals. Pulmonary vascular histology in these models was dominated by

medial wall thickness only; no advanced lesions were observed after 3 months of aortopulmonary shunting in piglets (Adapted from Rondelet et al. [21])

sheep and dogs has shown to result in plexiform-like lesions similar to human disease (Fig. 118.4) [29, 30]. A second possible explanation for the moderate form of vascular remodeling in many larger rodent models is that the shunt used in these models is a restrictive shunt [21, 25–28]. As mentioned above, only a limited proportion of patients with restrictive shunts develop advanced arteriopathy and only after several decades.

Several studies have shown that when either one lung (i.e., left pulmonary artery) [20, 31] or a single lobe [23, 32] is directly connected to the aorta, resulting in both high pulmonary blood flow in combination with (or) and high pressure, neointimal lesions comparable with human disease are seen to develop (Fig. 118.4). This confirms the clinical observation in CHD patients that increased pressure, as an additional hit, accelerates pulmonary vascular remodeling. Unfortunately, since extensive morphometric analysis was not conducted in these studies, it is difficult to interpret the exact magnitude of this remodeling.

Increased Pulmonary Blood Flow Combined with an Additional Trigger

A Second Hit Needed?

Okada and colleagues were the first to show that combining vascular injury (via monocrotaline administration) with increased pulmonary blood

flow (via an anastomosis of the left subclavian artery to the distal left pulmonary artery) results in an extended neointimal pattern of pulmonary vascular remodeling in the lung subjected to high flow after 5 weeks [13, 33]. In addition, increased pulmonary artery pressure and RV hypertrophy were reported. In this study either monocrotaline or anastomosis alone did not result in severe neointimal vascular remodeling. In a different model van Albada et al. have shown that when combined with monocrotaline administration, increased pulmonary flow via an aortacaval (av-) shunt results in (1) neointimal obliteration of the intra-acinar vessels staining positive for eNOS and smooth muscle actin, (2) increased systolic pulmonary artery pressure and RV hypertrophy, and (3) increased mortality after 5 weeks (Fig. 118.5) [34].

This data suggests that increased pulmonary blood flow, as a second hit in addition to MCT, is a prerequisite for the development of pulmonary neointimal lesions. Interestingly, in an experimental study Nishimura and colleagues showed that when monocrotaline was administered after av-shunt creation, pulmonary vascular remodeling was less pronounced, and the authors suggested a salvage effect of increased flow [35]. However, this is more likely to be explained by the fact that due to the increased blood flow through av- shunt, the concentration of monocrotaline pyrrole in the lungs was 2–3 times lower compared to nonshunted rats.

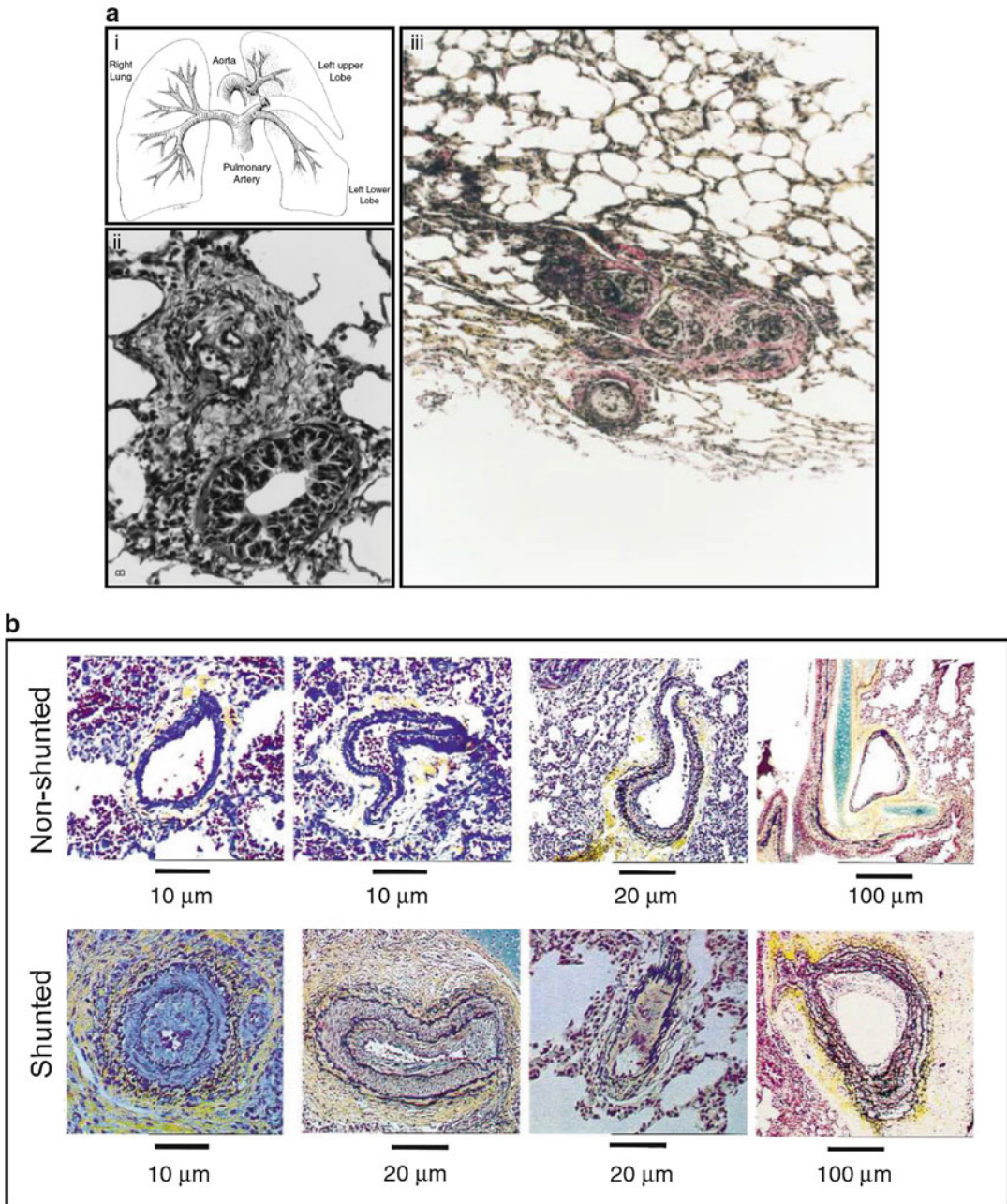


Fig. 118.4 Prolonged increased pulmonary blood flow in large animals mimics pulmonary vascular lesions in children with congenital heart defects: **(a)** A sheep model of increased pulmonary blood flow in the *left upper lobe* **(i)**, induced intimal proliferation after 2 months **(ii)**, but developed into more advanced lesions after 1.5 years

(iii) (Adapted from Schnader et al. [30]). **(b)** Beginning of neointimal lesions and medial wall thickness observed in small intra-acinar vessels after 8 weeks due to an anastomosis of the *left lower lobe* directly to the aorta in pigs (Adapted from Bousamra et al. [32])

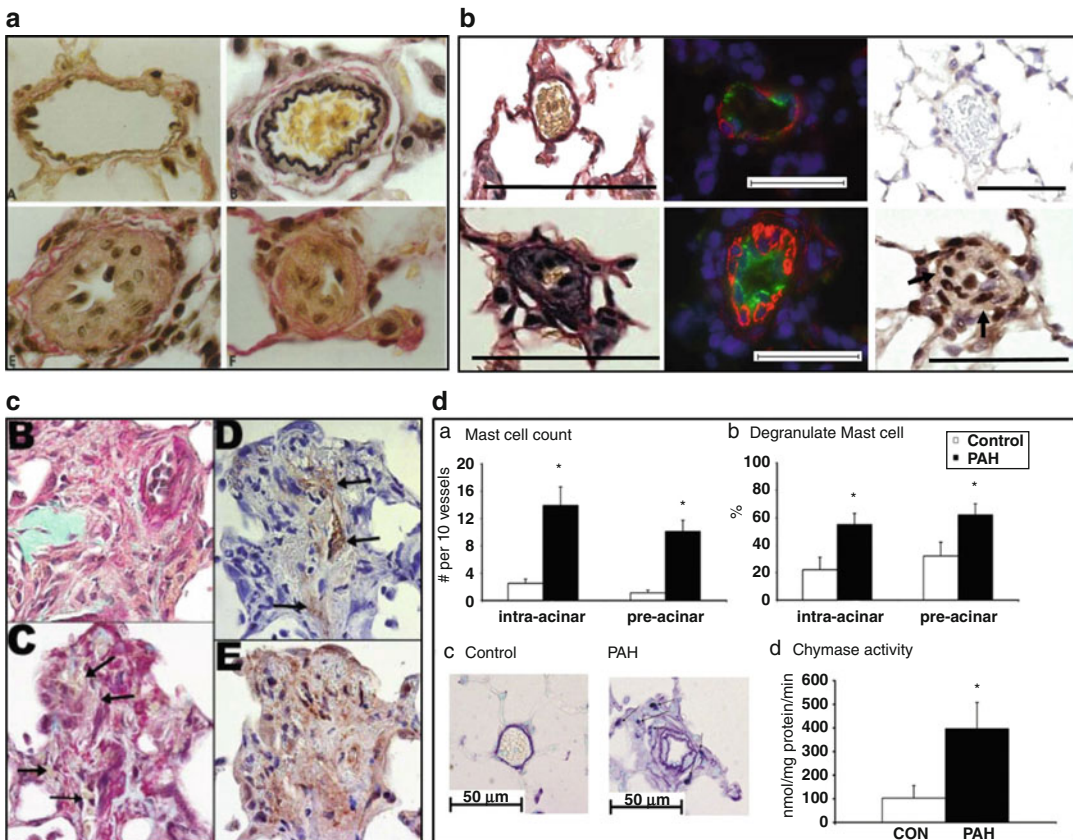


Fig. 118.5 Examples of extensive lesions resembling human PAH group 1 in “double-hit” models: (a) Extensive neointimal proliferation in the pulmonary vessels of rats subjected to a pneumonectomy combined with monocrotaline (Adapted from Okada et al. [13]). (b) Neointimal proliferation in intra-acinar vessels of rats with an aortocaval shunt combined with monocrotaline (left). Immunofluorescence staining shows proliferation of endothelial cells (green, vWF) and smooth muscle cells (red, α -SMA). Immunostaining shows increased

expression of Egr-1 a putative inducer of advanced lesions (Adapted from Dickinson et al. [14]). (c) Typical examples of plexiform-like lesions in young rats subjected to a pneumonectomy and monocrotaline. These lesions stain positive for vWF (top right) and VEGFR-2 (bottom right) (Adapted from White et al. [38]). (d) Increased presence of mast cells around pulmonary vessels of rats with an aortocaval shunt combined with monocrotaline as well as increased chymase activity, one of the mast cell proteases (Adapted from Bartelds et al. [46])

Alternatively, the induction of the shunt may also activate genetic pathways that oppose previously activated pathways induced by monocrotaline [36].

Neointimal Lesions in Models with Increased Pulmonary Blood Flow

Are the vascular lesions seen in the “double-hit” models comparable with those in human disease?

In human PAH irreversible neointimal lesions are comprised of both ECs and SMCs with

a reduction in apoptotic markers and increase in inflammatory cells [37].

In flow models, these obliterative lesions are comprised of cells that stain positive for the endothelial cell markers VEGF-R2 [38], eNOS [34], von Willebrand factor [14, 38], and CD31+ [39] and for SMCs staining positive for α -smooth muscle actin (Fig. 118.5) [14, 34, 38, 39]. Longitudinal studies using both the av-shunt and pneumonectomy/monocrotaline models have shown that these neointimal lesions start to form 1–2 weeks after increased pulmonary blood flow (Fig. 118.5) [13, 14, 38]. In these experimental

models the exact role of apoptotic or proproliferative state of these vessels during vascular remodeling is fairly unknown. In addition, questions still remain whether in the smaller pulmonary vasculature these occlusive lesions are most prominent (i.e., at branching points of larger arteries or at more distal locations).

Interestingly, White and colleagues have reported in their model that when monocrotaline administration is combined with unilateral pneumonectomy in younger rats, more complex plexiform-like lesions are formed (Fig. 118.5) [38]. The authors suggested that younger rats were more prone to vascular proliferation after injury. These plexiform-like lesions stained positive for vWF, VEGFR-2, and α -SMA and, as shown by microangiography, to be part of the pulmonary vasculature. However, with regard to this monocrotaline/pneumonectomy model, unlike the monocrotaline/av-shunt model, the possible effects of proliferation of lung parenchyma itself (up to 35 % due to pneumonectomy) have to be taken into consideration with this model, as previously shown [40].

Increased Pulmonary Blood Flow and Inflammation

Inflammation has been suggested to play a role in experimental PAH as well as in the development of flow-induced neointimal formation in PAH patients with systemic-to-pulmonary shunts [36, 41, 42, 46].

Proinflammatory cytokines and other inflammatory cells including mast cells [43, 46], macrophages, lymphocytes [41], and dendritic cells [44] have all been linked to either flow or nonflow PAH.

Accumulation of inflammatory cells in experimental PAH has also been linked to increased oxidative stress [44], which is also seen in pulmonary vessels of PAH patients [45].

In animal models of increased pulmonary blood flow, inflammation has also been suggested to play a role in neointimal development [36, 44, 46]. Clearly, the effect of monocrotaline administration in vascular inflammation has to be taken into account in these experimental models [16, 17], and questions remain whether

inflammation can be seen as the additional trigger for neointimal development in the increased pulmonary blood flow/monocrotaline models.

Still, reducing inflammation such as recently shown by mast cell stabilization or inhibition of chymase can attenuate the development of pulmonary vascular remodeling [46, 47]. These results justify future exploration of the possible role of anti-inflammatory therapy for PAH.

In summary, in flow models that combine a trigger such as vascular injury (monocrotaline) with either pneumonectomy or an av shunt, increased pulmonary blood flow specifically induces severe pulmonary vascular remodeling including neointimal development, perivascular inflammation, and plexiform-like lesions that show remarkable similarities with human plexogenic arteriopathy (2) (Fig. 118.6). In addition, increased flow leads to more pronounced increases in pulmonary artery pressure, RV hypertrophy, and mortality (3).

Other Neointimal Models

Besides flow-associated PAH animals, other models (mostly rat and murine) have also been reported to develop specific obliterative lesions, some with great resemblance to neointimal lesions in human PAH.

Murine models are of interest since they allow researchers to investigate the relevance of single genes using genetic manipulation. The main disadvantage of murine models, however, is the mild degree of PH and RV dysfunction that usually are achieved in mice compared to other animal models [48]. In addition, possible differences in the vascular bed of mice and humans have to be taken into consideration when comparing these data, as described above.

Sugen/Hypoxia Rat Model

Vascular endothelial growth factor (VEGF) is a prosurvival growth factor and is known to play a critical role in normal lung development [49]. In both iPAH as well as PAH associated with

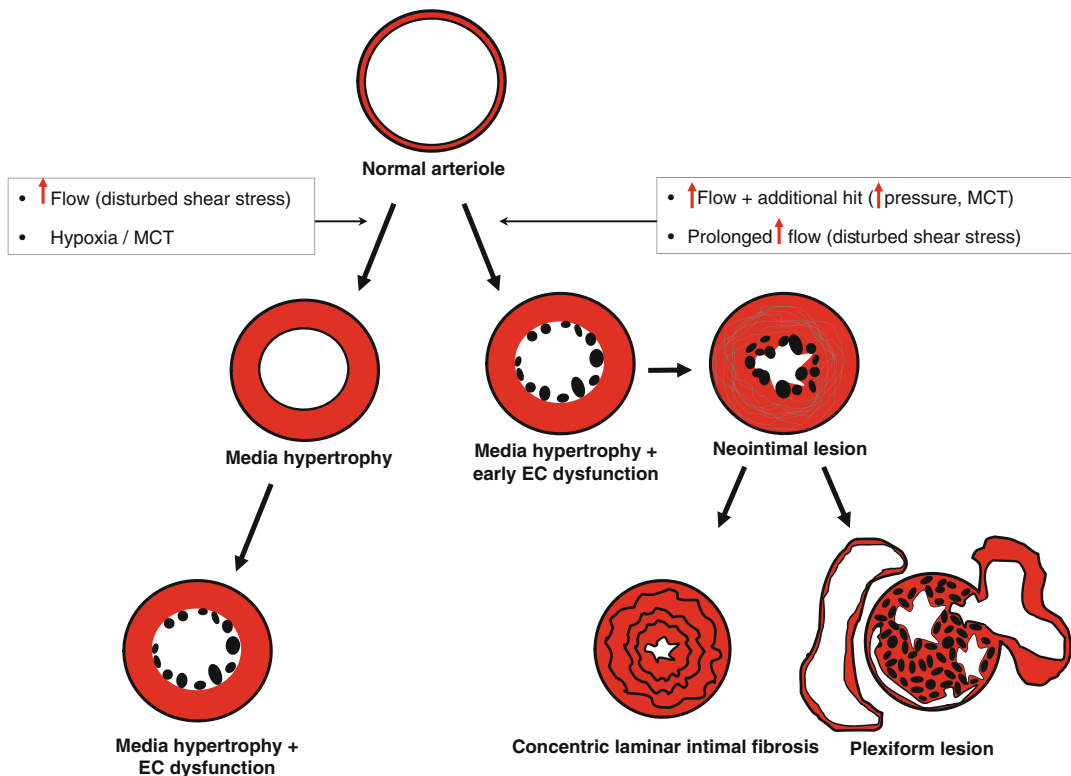


Fig. 118.6 Schematic representation of effects of increased flow on the development of pulmonary vascular lesions in PAH models. *Left side:* Triggers such as increased flow, monocrotaline, or hypoxia induce media hypertrophy and can induce endothelial cell changes. However, in most animal models, these hits alone do not trigger neointimal

development within the time frame studied. *Right side:* Double-hit models progress from early endothelial cell activation via an initial hit, either increased pulmonary blood flow or monocrotaline, followed by a second hit, increased pressure, (prolonged) increased blood flow that combined triggers neointimal development in these animal models

congenital systemic-to-pulmonary shunts, VEGF is strongly expressed in plexiform lesions in end-stage disease [49]. However, the role of VEGF in pulmonary vascular remodeling in PAH remains unclear.

Taraseviciene-Stewart et al. have shown that by combining VEGF receptor 2 (VEGFR2) inhibition, using the compound Sugen 5416, with chronic hypoxia, results in PAH with characteristic obstructive neointimal lesions in the arterioles, increased mPAP, and right ventricular hypertrophy (Fig. 118.7) [15, 50]. Pulmonary vascular remodeling in this model is characterized by SMC proliferation, an initial endothelial cell apoptosis followed by endothelial cell proliferation that continues even after reexposure to normoxia (Fig. 118.7) [15]. In addition, when these rats are subjected to normoxia for a longer period of time (up to 14 weeks), more complex

neointimal lesions are formed, showing similarities with human plexiform lesions (Fig. 118.7) [51]. However, unlike in irreversible human PAH, the survival rate of Sugen 5416/hypoxia rats has been shown to be close to 100 % even during long follow-up [51]. Apparently the degree and magnitude of arteriopathy in these rats is unable to induce RV failure, which raises the question whether the extent of arteriopathy is representative for the human setting.

Endothelial cell apoptosis could also play a major role in vessel occlusion in this model. Sakao et al. have shown that human pulmonary microvascular ECs (hPMVEC), when subjected to Sugen 5416, go into apoptosis and stimulate vascular SMC proliferation [5].

Despite these observations, it remains unclear how this characteristic arteriopathy develops in

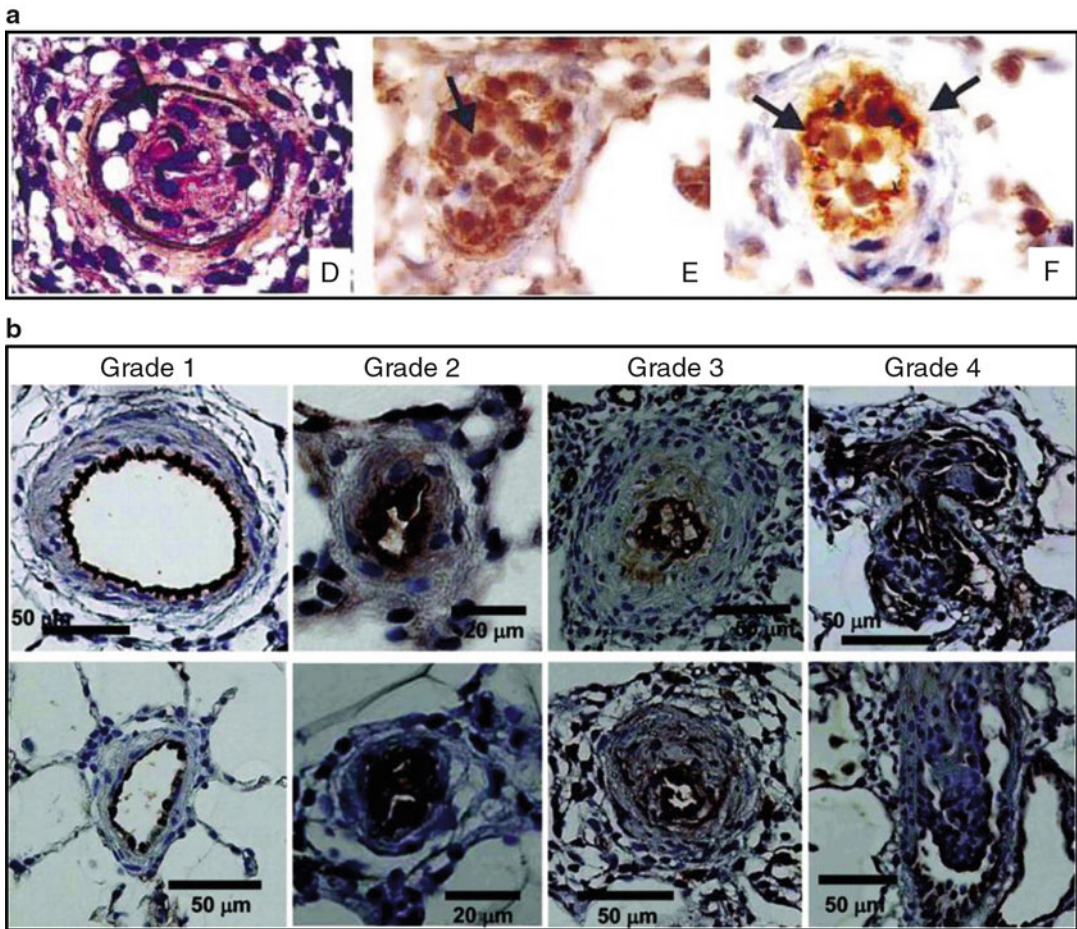


Fig. 118.7 Examples of advanced lesions observed in a model of inhibited angiogenesis combined with hypoxia (Sugen/hypoxia): (a) Rats treated a synthetic VEGF receptor antagonist and subjected to 3 weeks of hypoxia show lumen obliteration that stains positive for factor VIII and VEGFR-2 (Adapted from Taraseviciene-Stewart et al. [15]).

(b) The severity of lesions increases in rats subjected to Su5416, 3 weeks of hypoxia, and subsequent normoxia. After 5, 8, and 13 weeks of normoxia, lesions progressed to plexiform-like lesions with both intraluminal cell proliferations as well as aneurysm like lesions (Adapted from Abe et al. [51])

the Sugén 5416/hypoxia rats. Sugén 5416 injection or hypoxia alone both do not result in obliterative lesions of the intra-acinar vessels indicating that also in this model additional triggers are needed to develop complex vascular lesions [15]. Unfortunately, little is known about the exact role of Sugén 5416 in this process of SMC and EC proliferation and vascular occlusion. For instance, besides VEGF-R2 inhibition, Sugén 5416 is also known for its inhibitory effect on other tyrosine kinases, making it possible that not only VEGF-R2 inhibition is the

leading effect on vascular remodeling [52, 53]. It is therefore possible that other kinases also can play a role in the development of vascular remodeling in the 5416/hypoxia model. This raises the question whether the Sugén/hypoxia (normoxia) model of PAH is really ideal for bio-molecular analysis of PAH. Indeed, Moreno-Vinasco et al have shown that when comparing gene expression of Sugén/hypoxia rat lungs with human PAH lung tissue, only one similar hit comes up (Fyn: a protein-tyrosine kinase oncogene) [54].

Endothelin-B Receptor-Deficient Rats

Ivy et al. have reported in rats that endothelin B (ETB) receptor deficiency combined with monocrotaline results in the development of neointimal lesions, increased RV hypertrophy and reduced cardiac output compared to monocrotaline alone [55]. The vascular lesions in this model are comprised of cells staining positive for both EC and SMC markers and show similarities with human PAH lesions as well as those in other PAH models. Also similar to other models is that this model also needs a double hit for neointimal lesions to develop. Still, when ETB receptor-deficient rats are subjected to hypoxia instead of monocrotaline [56], these neointimal lesions are not seen even though PH does occur, indicating that not all additional trigger induce the same magnitude of pulmonary vascular remodeling.

Although treatment effects have yet to be reported in this model, the current data suggests that the ETB receptor exhibits angioproliferative properties, when combined with the proper additional hit.

Bone Morphogenetic Protein Receptor 2 (BMPR-2) Gene Mutations

Germline mutations in the bone morphogenetic protein receptor 2 (BMPR-2) gene are known to play a role in the development of PAH [57].

In PAH patients BMPR-2 loss-of-function mutations have only been found in the heterozygous state. The heterozygous BMPR-2 knockout, however, showed only mild increased pulmonary artery pressure and pulmonary vessel muscularization at best [58].

A more recent work has focused on cell-specific BMPR-2 loss of function. SMC-specific loss of BMPR-2 shows a more profound vascular remodeling and increased RV systolic pressure, although neointimal lesions were not found [59, 60]. In contrast, endothelial-specific loss of BMPR-2 expression in mice resulted in pulmonary vascular remodeling consisting of proliferating α -SMA positive cells, in situ thrombosis,

and perivascular macrophage and leukocyte infiltration leading to increased RV systolic pressure and RV hypertrophy [61]. Although the degree of vascular remodeling is not completely comparable with human PAH, these BMPR-2 models may provide a better understanding of the possible synergistic effects of genetic predisposition and environmental triggers that cause PAH.

Other models of potential interest are the II-6 transgenic mice [62] and mice overexpressing a calcium-binding protein S100A4Mts [63]. Nevertheless, in both models disease penetrance is incomplete and a second hit is needed to develop pulmonary, non-neointimal vascular lesions.

Treatment Effects in Neointimal Animal Models

Currently PAH patients are treated, in addition to supportive medication, with either (1) calcium channel blockers or (2) one or a combination of the following agents: prostacyclin analogues, endothelin receptor antagonists, and phosphodiesterase-5 inhibitors. Despite improvements with these treatments, PAH still remains a fatal disease. The general thought is that this is related to the severity of pulmonary vascular remodeling, which is considered irreversible once neointimal lesions have formed. Therefore, future treatments should focus targeting on reversal of these so-called irreversible neointimal lesions, something that has not been accomplished so far.

In general – although some positive effects have been described (predominantly in prevention studies) – to date, no cure for animals with established advanced lesions has been found. Nevertheless, several interesting “proof of principle” studies may direct future research for development of novel therapies.

In monocrotaline/av-shunt rats, inhibition of the vasoconstrictor thromboxane, a key player of vascular remodeling in PAH, using the prostacyclin analogue treprostinil, resulted in a reduction in pulmonary artery pressure, although neointimal development was not reduced [64].

Similar resistance to vascular remodeling improvement was seen when using aspirin or iloprost [65], suggesting a vasodilatory effect rather than an antiproliferative effect of the drug.

Other studies have shown that ACE inhibition, using quinapril, attenuated neointimal formation of the intra-acinar vessels [47]. Also, when triptolide (a Chinese herb with anti-inflammatory and antiproliferative effects [66]) was administered to monocrotaline/pneumonectomy rats, neointimal formation, pulmonary artery pressure, as well as RV hypertrophy could be both attenuated and reversed [66]. However, the authors also described a mortality rate of roughly 30 % in the triptolide-treated group.

In the future, novel treatments in PAH may shift more towards targeting angiogenesis and inflammation. Indeed, in monocrotaline/flow models, simvastatin (also known for its anti-inflammatory properties) [39], mast cell stabilization (via cromolyn) [46], dehydroepiandrosterone (known to have antioxidant and anti-inflammatory effects) [67], rapamycin (an antiangiogenic agent) [68], and EPO (erythropoietin, known for endothelial repair by endothelial progenitor cell mobilization) [69] have shown to attenuate, or in part reverse [39, 68], neointimal formation and/or increased pulmonary artery pressure. However, caution is ought to be taken when directly extrapolating these data to the human setting as illustrated a recent randomized controlled trial in PAH patients, in which simvastatin as add-on therapy did not show a positive effect on 6 min walking distance [70].

Therapies in Models of Sugen + Hypoxia

Similar to the human setting, vascular remodeling seen in the Sugen 5416/hypoxia model has shown to be resistant to many drugs (Ca^{2+} channel receptor blockers, prostacyclin analogues, dual endothelin A/B ($\text{ET}_{A/B}$) receptor antagonists) currently used for the treatment of human PAH [50, 71].

Several other therapeutic treatments have been evaluated in this model. For instance, the caspase inhibitor Z-Asp- CH_2 -DCB [15], the anti-neoplastic agent sorafenib [54], the bradykinin receptor 2 agonist B9972 [72], and simvastatin [50] all have shown to prevent the development of neointimal formation and severe pulmonary hypertension. However, similar to results from flow-PAH models, caution has to be taken when extrapolating these data to the human setting [70]. In addition, several other drugs including angiotensin-2 receptor blockers and angiotensin-converting enzyme inhibitors have shown to have no effect on prevention of pulmonary vascular remodeling [50, 73]. Also, to date no drugs have shown reversal of pulmonary vascular remodeling in this model, which as an intervention is more clinically relevant since most PAH patients present when vascular remodeling has already developed.

Other Interesting Pathways in Animal Models

Possible Novel Pathophysiological Pathways in PAH

The pathogenesis of the complex pulmonary vascular lesions is likely a multifactorial process, necessitating system biology approaches to identify novel targets [74]. Using a microarray analysis, van Albada et al. showed that increased pulmonary blood flow specifically induced the expression WNT-signaling genes and several other transcription factors including activating transcription factor-3 and early growth response factor-1 (Egr-1) [14, 36]. Also, in the last years many new putative pathways have been discovered in non-neointimal models that could potentially affect PAH development. Examples are the PPAR gamma pathway in PAEC in mice [75], tyrosine kinase inhibitors in hypoxic PH or monocrotaline-induced PH [76], soluble GCs [77] and the possible role of microRNAs in PH [78]. Although promising pathways, their roles have yet to be established in more clinically relevant neointimal models of PAH.

Concluding Remarks

Pulmonary arterial hypertension is still a progressive disease with typical lesions characterized by neointimal formation, obliteration, and plexiform lesions. The pathogenetic mechanism underlying the formation of these progressive pulmonary vascular lesions is still poorly understood but might be the key to curative treatment. Animal models mimicking the human disease ideally are characterized by (1) a hit resembling the human disease (e.g., increased pulmonary blood flow), (2) the progression towards the characteristic pulmonary vascular remodeling that represents plexogenic arteriopathy and includes the development of complex obliterative lesions

of the small intra-acinar arteries and muscularization of larger preacinar arteries, and (3) progressive disease development that leads to RV dysfunction and eventually death. Although no model to date is ideal, models showing the closest resemblance with human disease are those that use multiple triggers for disease development and result in neointimal lesions (Fig. 118.8). Since increased pulmonary blood flow is a known trigger for neointimal development and PAH associated with congenital heart diseases, flow-associated animal models that result in neointimal lesions are of particular interest for this patient population.

Using these more clinically relevant neointimal models, future studies should consider focusing their attention on the following: (1) the





Experimental model	Characteristics of arteriopathy	
<p><i>Increased flow models:</i></p> <ul style="list-style-type: none"> • short term or small systemic-to-pulmonary shunt in rats, pigs, sheep 	<ul style="list-style-type: none"> • media hypertrophy and muscularization of arterioles 	
<p><i>Other models</i></p> <ul style="list-style-type: none"> • hypoxic model rat /mouse • MCT model in rats 	<ul style="list-style-type: none"> • media hypertrophy and muscularization of arterioles 	Media hypertrophy
<p><i>Increased flow models:</i></p> <ul style="list-style-type: none"> • MCT + aortocaval shunt in rats • MCT + pneumonectomy • Chronic systemic-to-pulmonary shunt in rats, pigs, sheep, dogs 	<ul style="list-style-type: none"> • muscularization + obliterative lesions (SMCs/ECs), perivascular inflammation. • neointimal proliferation of arteries; muscularization + obliterative lesions arterioles 	
<p><i>Other models:</i></p> <ul style="list-style-type: none"> • Sugen 5416 + chronic hypoxia • S100A4/Mts1 overexpression in mice • S100A4/Mts1 overexpression + YHSV-68in mice • IL6 overexpression + with hypoxia in mice 	<ul style="list-style-type: none"> • muscularization + obliterative lesions (ECs) • muscularization + obliterative lesions (SMCs) + perivascular inflammation • obliterative lesions (ECs) + perivascular inflammation 	Obliterative lesion (neointima)
<p><i>increased flow models:</i></p> <ul style="list-style-type: none"> • systemic-to-pulmonary shunt (prolonged increased flow + pressure) in dogs, sheep • MCT + pneumonectomy in young rats 	<ul style="list-style-type: none"> • plexiform lesions with cellular vessel obstruction, dilatation and recanalization • perivascular proliferation with lesions containing ECs 	
<p><i>Other models:</i></p> <ul style="list-style-type: none"> • Sugen 5416 / hypoxia + prolonged normoxia 	<ul style="list-style-type: none"> • plexiform like lesions containing obliterative lesions (SMCs/ ECs and aneurysm like lesions 	Plexiform lesion

Fig. 118.8 Summary of the main histopathological changes found in several experimental models used to study pathophysiological mechanism of PAH: (a) Models with only increased blood flow typically show only increased medial wall thickness in the time frame studied. (b) Double-hit models with histology resembling human

pathology (e.g., increased flow + additional hit) typically progress into advanced neointimal lesions with obliteration of the vascular lumen within the time frame studied. (c) Severe prolongation of increase pulmonary blood flow can induce plexiform lesions, as is also observed in other double-hit models using experimental stimuli

exact localization of neointimal development in the vascular bed, (2) pathobiological pathways triggered by clinically relevant hits (i.e., increased pulmonary blood flow), and (3) novel therapeutic treatments that can reverse rather than prevent neointimal development. Using these methods, new pathways are deemed to emerge which may lead to new therapeutic targets for patients with PAH in the future.

References

- Simonneau G, Robbins IM, Beghetti M, Channick RN, Delcroix M, Denton CP et al (2009) Updated clinical classification of pulmonary hypertension. *J Am Coll Cardiol* 54:S43–S54
- Mooi WJ, Wagenvoort CA (1989) Biopsy pathology of the pulmonary vasculature, 1st edn. Chapman and Hall Medical, London
- Humbert M, Morrell NW, Archer SL, Stenmark KR, MacLean MR, Lang IM et al (2004) Cellular and molecular pathobiology of pulmonary arterial hypertension. *J Am Coll Cardiol* 43:13S–24S
- Sakao S, Tatsumi K, Voelkel NF (2010) Reversible or irreversible remodeling in pulmonary arterial hypertension. *Am J Respir Cell Mol Biol* 43:629–634
- Sakao S, Taraseviciene-Stewart L, Lee JD, Wood K, Cool CD, Voelkel NF (2005) Initial apoptosis is followed by increased proliferation of apoptosis-resistant endothelial cells. *FASEB J* 19:1178–1180
- Roofthoof MTR, Van Loon RLE, Berger RMF (2009) Pulmonary arterial hypertension in children with congenital heart disease. *PVRI Rev* 1:203–207
- Zoetis T, Hurtt ME (2003) Species comparison of lung development. *Birth Defects Res B Dev Reprod Toxicol* 68:121–124
- Faffe DS, Rocco PR, Negri EM, Zin WA (2002) Comparison of rat and mouse pulmonary tissue mechanical properties and histology. *J Appl Physiol* 92:230–234
- Stevens T (2011) Functional and molecular heterogeneity of pulmonary endothelial cells. *Proc Am Thorac Soc* 8:453–457
- Cool CD, Stewart JS, Werahera P, Miller GJ, Williams RL, Voelkel NF et al (1999) Three-dimensional reconstruction of pulmonary arteries in plexiform pulmonary hypertension using cell-specific markers. Evidence for a dynamic and heterogeneous process of pulmonary endothelial cell growth. *Am J Pathol* 155:411–419
- Yaginuma G, Mohri H, Takahashi T (1990) Distribution of arterial lesions and collateral pathways in the pulmonary hypertension of congenital heart disease: a computer aided reconstruction study. *Thorax* 45:586–590
- Stenmark KR, Meyrick B, Galie N, Mooi WJ, McMurtry IF (2009) Animal models of pulmonary arterial hypertension: the hope for etiological discovery and pharmacological cure. *Am J Physiol Lung Cell Mol Physiol* 297:L1013–L1032
- Okada K, Tanaka Y, Bernstein M, Zhang W, Patterson GA, Botney MD (1997) Pulmonary hemodynamics modify the rat pulmonary artery response to injury. A neointimal model of pulmonary hypertension. *Am J Pathol* 151:1019–1025
- Dickinson MG, Bartelds B, Molema G, Borgdorff MA, Boersma B, Takens J et al (2011) Egr-1 expression during neointimal development in flow-associated pulmonary hypertension. *Am J Pathol* 179:2199–2209
- Taraseviciene-Stewart L, Kasahara Y, Alger L, Hirth P, Mc Mahon G, Waltenberger J et al (2001) Inhibition of the VEGF receptor 2 combined with chronic hypoxia causes cell death-dependent pulmonary endothelial cell proliferation and severe pulmonary hypertension. *FASEB J* 15:427–438
- Gomez-Arroyo JG, Farkas L, Alhussaini AA, Farkas D, Kraskauskas D, Voelkel NF et al (2011) The monocrotaline model of pulmonary hypertension in perspective. *Am J Physiol Lung Cell Mol Physiol* 302(4):L363–L369
- Rosenberg HC, Rabinovitch M (1988) Endothelial injury and vascular reactivity in monocrotaline pulmonary hypertension. *Am J Physiol* 255: H1484–H1491
- Lalich JJ, Ehrhart LA (1962) Monocrotaline-induced pulmonary arteritis in rats. *J Atheroscler Res* 2:482–492
- van Loon RL, Roofthoof MT, Hillege HL, ten Harkel AD, van Osch-Gevers M, Delhaas T et al (2011) Pediatric pulmonary hypertension in the Netherlands: epidemiology and characterization during the period 1991 to 2005. *Circulation* 124:1755–1764
- Fasules JW, Tryka F, Chipman CW, Van Devanter SH (1994) Pulmonary hypertension and arterial changes in calves with a systemic-to-left pulmonary artery connection. *J Appl Physiol* 77:867–875
- Rondelet B, Dewachter C, Kerbaul F, Kang X, Fesler P, Brimiouille S et al (2011) Prolonged overcirculation-induced pulmonary arterial hypertension as a cause of right ventricular failure. *Eur Heart J* 33(8):1017–1026
- Aggarwal S, Gross C, Fineman JR, Black SM (2010) Oxidative stress and the development of endothelial dysfunction in congenital heart disease with increased pulmonary blood flow: lessons from the neonatal lamb. *Trends Cardiovasc Med* 20:238–246
- Rendas A, Lennox S, Reid L (1979) Aorta-pulmonary shunts in growing pigs. Functional and structural assessment of the changes in the pulmonary circulation. *J Thorac Cardiovasc Surg* 77:109–118
- Garcia R, Diebold S (1990) Simple, rapid, and effective method of producing aorticaval shunts in the rat. *Cardiovasc Res* 24:430–432

25. Rondelet B, Kerbaul F, Van Beneden R, Motte S, Fesler P, Hubloue I et al (2004) Signaling molecules in overcirculation-induced pulmonary hypertension in piglets: effects of sildenafil therapy. *Circulation* 110:2220–2225
26. Rondelet B, Dewachter L, Kerbaul F, Dewachter C, Hubloue I, Fesler P et al (2010) Sildenafil added to sitaxsentan in overcirculation-induced pulmonary arterial hypertension. *Am J Physiol Heart Circ Physiol* 299:H1118–H1123
27. Rondelet B, Kerbaul F, Motte S, van Beneden R, Rimmelink M, Brimiouille S et al (2003) Bosentan for the prevention of overcirculation-induced experimental pulmonary arterial hypertension. *Circulation* 107:1329–1335
28. Wauthy P, Abdel Kafi S, Mooi WJ, Naeije R, Brimiouille S (2003) Inhaled nitric oxide versus prostacyclin in chronic shunt-induced pulmonary hypertension. *J Thorac Cardiovasc Surg* 126:1434–1441
29. Heath D, Donald DE, Edwards JE (1959) Pulmonary vascular changes in a dog after aortopulmonary anastomosis for four years. *Br Heart J* 21:187–196
30. Schnader J, Schloo BL, Anderson W, Stephenson LW, Fishman AP (1996) Chronic pulmonary hypertension in sheep: temporal progression of lesions. *J Surg Res* 62:243–250
31. Corno AF, Tozzi P, Genton CY, von Segesser LK (2003) Surgically induced unilateral pulmonary hypertension: time-related analysis of a new experimental model. *Eur J Cardiothorac Surg* 23:513–517
32. Bousamra M 2nd, Rossi R, Jacobs E, Parviz M, Busch C, Nelin LD et al (2000) Systemic lobar shunting induces advanced pulmonary vasculopathy. *J Thorac Cardiovasc Surg* 120:88–98
33. Tanaka Y, Schuster DP, Davis EC, Patterson GA, Botney MD (1996) The role of vascular injury and hemodynamics in rat pulmonary artery remodeling. *J Clin Invest* 98:434–442
34. van Albada ME, Schoemaker RG, Kemna MS, Cromme-Dijkhuis AH, van Veghel R, Berger RM (2005) The role of increased pulmonary blood flow in pulmonary arterial hypertension. *Eur Respir J* 26:487–493
35. Nishimura T, Faul JL, Berry GJ, Kao PN, Pearl RG (2003) Effect of a surgical aortocaval fistula on monocrotaline-induced pulmonary hypertension. *Crit Care Med* 31:1213–1218
36. van Albada ME, Bartelds B, Wijnberg H, Mohaupt S, Dickinson MG, Schoemaker RG et al (2010) Gene expression profile in flow-associated pulmonary arterial hypertension with neointimal lesions. *Am J Physiol Lung Cell Mol Physiol* 298:L483–L491
37. Levy M, Maurey C, Celermajer DS, Vouhe PR, Danel C, Bonnet D et al (2007) Impaired apoptosis of pulmonary endothelial cells is associated with intimal proliferation and irreversibility of pulmonary hypertension in congenital heart disease. *J Am Coll Cardiol* 49:803–810
38. White RJ, Meoli DF, Swarouth RF, Kallop DY II, Galaria JLH et al (2007) Plexiform-like lesions and increased tissue factor expression in a rat model of severe pulmonary arterial hypertension. *Am J Physiol Lung Cell Mol Physiol* 293:L583–L590
39. Nishimura T, Faul JL, Berry GJ, Vaszar LT, Qiu D, Pearl RG et al (2002) Simvastatin attenuates smooth muscle neointimal proliferation and pulmonary hypertension in rats. *Am J Respir Crit Care Med* 166:1403–1408
40. Buhain WJ, Brody JS (1973) Compensatory growth of the lung following pneumonectomy. *J Appl Physiol* 35:898–902
41. Hassoun PM, Mouthon L, Barbera JA, Eddahibi S, Flores SC, Grimminger F et al (2009) Inflammation, growth factors, and pulmonary vascular remodeling. *J Am Coll Cardiol* 54:S10–S19
42. Vaszar LT, Nishimura T, Storey JD, Zhao G, Qiu D, Faul JL et al (2004) Longitudinal transcriptional analysis of developing neointimal vascular occlusion and pulmonary hypertension in rats. *Physiol Genomics* 17:150–156
43. Hamada H, Terai M, Kimura H, Hirano K, Oana S, Niimi H (1999) Increased expression of mast cell chymase in the lungs of patients with congenital heart disease associated with early pulmonary vascular disease. *Am J Respir Crit Care Med* 160:1303–1308
44. Dorfmueller P, Chaumais MC, Giannakouli M, Durand-Gasselini I, Raymond N, Fadel E et al (2011) Increased oxidative stress and severe arterial remodeling induced by permanent high-flow challenge in experimental pulmonary hypertension. *Respir Res* 12:119
45. Bowers R, Cool C, Murphy RC, Tuder RM, Hopken MW, Flores SC et al (2004) Oxidative stress in severe pulmonary hypertension. *Am J Respir Crit Care Med* 169:764–769
46. Bartelds B, van Loon RL, Mohaupt S, Wijnberg H, Dickinson M, Boersma B et al (2011) Mast cell inhibition improves pulmonary vascular remodeling in pulmonary hypertension. *Chest* 141(3):651–660
47. Okada K, Bernstein ML, Zhang W, Schuster DP, Botney MD (1998) Angiotensin-converting enzyme inhibition delays pulmonary vascular neointimal formation. *Am J Respir Crit Care Med* 158:939–950
48. Gomez-Arroyo JG, Saleem SJ, Mizuno S, Syded AA, Bogaard HJ, Abbate A et al (2012) A brief overview of mouse models of pulmonary arterial hypertension: problems and prospects. *Am J Physiol Lung Cell Mol Physiol* 302(10):L977–L991
49. Voelkel NF, Vandivier RW, Tuder RM (2006) Vascular endothelial growth factor in the lung. *Am J Physiol Lung Cell Mol Physiol* 290:L209–L221
50. Taraseviciene-Stewart L, Scerbavicius R, Choe KH, Cool C, Wood K, Tuder RM et al (2006) Simvastatin causes endothelial cell apoptosis and attenuates severe pulmonary hypertension. *Am J Physiol Lung Cell Mol Physiol* 291:L668–L676
51. Abe K, Toba M, Alzoubi A, Ito M, Fagan KA, Cool CD et al (2010) Formation of plexiform lesions in

- experimental severe pulmonary arterial hypertension. *Circulation* 121:2747–2754
52. Sakao S, Tatsumi K (2011) The effects of antiangiogenic compound SU5416 in a rat model of pulmonary arterial hypertension. *Respiration* 81:253–261
 53. Yee KW, O'Farrell AM, Smolich BD, Cherrington JM, McMahon G, Wait CL et al (2002) SU5416 and SU5614 inhibit kinase activity of wild-type and mutant FLT3 receptor tyrosine kinase. *Blood* 100:2941–2949
 54. Moreno-Vinasco L, Gomberg-Maitland M, Maitland ML, Desai AA, Singleton PA, Sammani S et al (2008) Genomic assessment of a multikinase inhibitor, sorafenib, in a rodent model of pulmonary hypertension. *Physiol Genomics* 33:278–291
 55. Ivy DD, McMurtry IF, Colvin K, Imamura M, Oka M, Lee DS et al (2005) Development of occlusive neointimal lesions in distal pulmonary arteries of endothelin B receptor-deficient rats: a new model of severe pulmonary arterial hypertension. *Circulation* 111:2988–2996
 56. Ivy DD, Yanagisawa M, Garipey CE, Gebb SA, Colvin KL, McMurtry IF (2002) Exaggerated hypoxic pulmonary hypertension in endothelin B receptor-deficient rats. *Am J Physiol Lung Cell Mol Physiol* 282:L703–L712
 57. Aldred MA, Vijaykrishnan J, James V, Soubrier F, Gomez-Sanchez MA, Martensson G et al (2006) BMPR2 gene rearrangements account for a significant proportion of mutations in familial and idiopathic pulmonary arterial hypertension. *Hum Mutat* 27:212–213
 58. Beppu H, Ichinose F, Kawai N, Jones RC, Yu PB, Zapol WM et al (2004) BMPR-II heterozygous mice have mild pulmonary hypertension and an impaired pulmonary vascular remodeling response to prolonged hypoxia. *Am J Physiol Lung Cell Mol Physiol* 287:L1241–L1247
 59. West J, Harral J, Lane K, Deng Y, Ickes B, Crona D et al (2008) Mice expressing BMPR2R899X transgene in smooth muscle develop pulmonary vascular lesions. *Am J Physiol Lung Cell Mol Physiol* 295:L744–L755
 60. Yasuda T, Tada Y, Tanabe N, Tatsumi K, West J (2011) Rho-kinase inhibition alleviates pulmonary hypertension in transgenic mice expressing a dominant-negative type II bone morphogenetic protein receptor gene. *Am J Physiol Lung Cell Mol Physiol* 301:L667–L674
 61. Hong KH, Lee YJ, Lee E, Park SO, Han C, Beppu H et al (2008) Genetic ablation of the BMPR2 gene in pulmonary endothelium is sufficient to predispose to pulmonary arterial hypertension. *Circulation* 118:722–730
 62. Steiner MK, Syrkin OL, Kolliputi N, Mark EJ, Hales CA, Waxman AB (2009) Interleukin-6 overexpression induces pulmonary hypertension. *Circ Res* 104:236–244, 28p following 244
 63. Greenway S, van Suylen RJ, Du Marchie Sarvaas G, Kwan E, Ambartsumian N, Lukanidin E et al (2004) S100A4/Mts1 produces murine pulmonary artery changes resembling plexogenic arteriopathy and is increased in human plexogenic arteriopathy. *Am J Pathol* 164:253–262
 64. van Albada ME, van Veghel R, Cromme-Dijkhuis AH, Schoemaker RG, Berger RM (2006) Treprostinil in advanced experimental pulmonary hypertension: beneficial outcome without reversed pulmonary vascular remodeling. *J Cardiovasc Pharmacol* 48:249–254
 65. van Albada ME, Berger RM, Niggebrugge M, van Veghel R, Cromme-Dijkhuis AH, Schoemaker RG (2006) Prostacyclin therapy increases right ventricular capillarisation in a model for flow-associated pulmonary hypertension. *Eur J Pharmacol* 549:107–116
 66. Faul JL, Nishimura T, Berry GJ, Benson GV, Pearl RG, Kao PN (2000) Triptolide attenuates pulmonary arterial hypertension and neointimal formation in rats. *Am J Respir Crit Care Med* 162:2252–2258
 67. Homma N, Nagaoka T, Karoor V, Imamura M, Taraseviciene-Stewart L, Walker LA et al (2008) Involvement of RhoA/Rho kinase signaling in protection against monocrotaline-induced pulmonary hypertension in pneumonectomized rats by dehydroepiandrosterone. *Am J Physiol Lung Cell Mol Physiol* 295:L71–L78
 68. Nishimura T, Faul JL, Berry GJ, Veve I, Pearl RG, Kao PN (2001) 40-O-(2-hydroxyethyl)-rapamycin attenuates pulmonary arterial hypertension and neointimal formation in rats. *Am J Respir Crit Care Med* 163:498–502
 69. van Albada ME, du Marchie Sarvaas GJ, Koster J, Houwertjes MC, Berger RM, Schoemaker RG (2008) Effects of erythropoietin on advanced pulmonary vascular remodeling. *Eur Respir J* 31:126–134
 70. Kawut SM, Bagiella E, Lederer DJ, Shimbo D, Horn EM, Roberts KE et al (2011) Randomized clinical trial of aspirin and simvastatin for pulmonary arterial hypertension: ASA-STAT. *Circulation* 123:2985–2993
 71. Oka M, Homma N, Taraseviciene-Stewart L, Morris KG, Kraskauskas D, Burns N et al (2007) Rho kinase-mediated vasoconstriction is important in severe occlusive pulmonary arterial hypertension in rats. *Circ Res* 100:923–929
 72. Taraseviciene-Stewart L, Scerbavicius R, Stewart JM, Gera L, Demura Y, Cool C et al (2005) Treatment of severe pulmonary hypertension: a bradykinin receptor 2 agonist B9972 causes reduction of pulmonary artery pressure and right ventricular hypertrophy. *Peptides* 26:1292–1300
 73. Casserly B, Mazer JM, Vang A, Harrington EO, Klinger JR, Rounds S et al (2011) C-type natriuretic peptide does not attenuate the development of pulmonary hypertension caused by hypoxia and VEGF receptor blockade. *Life Sci* 89:460–466
 74. Ahmad F, Champion HC, Kaminski N (2012) Toward systems biology of pulmonary hypertension. *Circulation* 125:1477–1479

75. Alastalo TP, Li M, Perez Vde J, Pham D, Sawada H, Wang JK et al (2011) Disruption of PPARgamma/beta-catenin-mediated regulation of apelin impairs BMP-induced mouse and human pulmonary arterial EC survival. *J Clin Invest* 121:3735–3746
76. Schermuly RT, Dony E, Ghofrani HA, Pullamsetti S, Savai R, Roth M et al (2005) Reversal of experimental pulmonary hypertension by PDGF inhibition. *J Clin Invest* 115:2811–2821
77. Dumitrascu R, Weissmann N, Ghofrani HA, Dony E, Beuerlein K, Schmidt H et al (2006) Activation of soluble guanylate cyclase reverses experimental pulmonary hypertension and vascular remodeling. *Circulation* 113:286–295
78. Parikh VN, Jin RC, Rabello S, Gulbahce N, White K, Hale A et al (2012) MicroRNA-21 integrates pathogenic signaling to control pulmonary hypertension: results of a network bioinformatics approach. *Circulation* 125:1520–1532