

University of Groningen

## EASL-ERN position paper on liver involvement in patients with Fontan-type circulation

Télléz, Luis; Payancé, Audrey; Tjwa, Eric; del Cerro, María Jesús; Idorn, Lars; Ovroutski, Stanislav; De Bruyne, Ruth; Verkade, Henkjan J.; De Rita, Fabrizio; de Lange, Charlotte

*Published in:*  
Journal of Hepatology

*DOI:*  
[10.1016/j.jhep.2023.07.013](https://doi.org/10.1016/j.jhep.2023.07.013)

**IMPORTANT NOTE:** You are advised to consult the publisher's version (publisher's PDF) if you wish to cite from it. Please check the document version below.

*Document Version*  
Publisher's PDF, also known as Version of record

*Publication date:*  
2023

[Link to publication in University of Groningen/UMCG research database](#)

### *Citation for published version (APA):*

Télléz, L., Payancé, A., Tjwa, E., del Cerro, M. J., Idorn, L., Ovroutski, S., De Bruyne, R., Verkade, H. J., De Rita, F., de Lange, C., Angelini, A., Paradis, V., Rautou, P. E., & García-Pagán, J. C. (2023). EASL-ERN position paper on liver involvement in patients with Fontan-type circulation. *Journal of Hepatology*, 79(5), 1270-1301. <https://doi.org/10.1016/j.jhep.2023.07.013>

### **Copyright**

Other than for strictly personal use, it is not permitted to download or to forward/distribute the text or part of it without the consent of the author(s) and/or copyright holder(s), unless the work is under an open content license (like Creative Commons).

The publication may also be distributed here under the terms of Article 25fa of the Dutch Copyright Act, indicated by the "Taverne" license. More information can be found on the University of Groningen website: <https://www.rug.nl/library/open-access/self-archiving-pure/taverne-amendment>.

### **Take-down policy**

If you believe that this document breaches copyright please contact us providing details, and we will remove access to the work immediately and investigate your claim.

*Downloaded from the University of Groningen/UMCG research database (Pure): <http://www.rug.nl/research/portal>. For technical reasons the number of authors shown on this cover page is limited to 10 maximum.*

# EASL-ERN position paper on liver involvement in patients with Fontan-type circulation

Luis Téllez<sup>1,2</sup>, Audrey Payancé<sup>3,4</sup>, Eric Tjwa<sup>5</sup>, María Jesús del Cerro<sup>6,7</sup>, Lars Idorn<sup>8</sup>, Stanislav Ovroutski<sup>9</sup>, Ruth De Bruyne<sup>10,†</sup>, Henkjan J. Verkade<sup>11,†</sup>, Fabrizio De Rita<sup>12</sup>, Charlotte de Lange<sup>13</sup>, Annalisa Angelini<sup>14</sup>, Valérie Paradis<sup>15,16</sup>, Pierre Emmanuel Rautou<sup>17,18,†</sup>, Juan Carlos García-Pagán<sup>19,20,\*</sup>

## Summary

Fontan-type surgery is the final step in the sequential palliative surgical treatment of infants born with a univentricular heart. The resulting long-term haemodynamic changes promote liver damage, leading to Fontan-associated liver disease (FALD), in virtually all patients with Fontan circulation. Owing to the lack of a uniform definition of FALD and the competitive risk of other complications developed by Fontan patients, the impact of FALD on the prognosis of these patients is currently debatable. However, based on the increasing number of adult Fontan patients and recent research interest, the European Association for The Study of the Liver and the European Reference Network on Rare Liver Diseases thought a position paper timely. The aims of the current paper are: (1) to provide a clear definition and description of FALD, including clinical, analytical, radiological, haemodynamic, and histological features; (2) to facilitate guidance for staging the liver disease; and (3) to provide evidence- and experience-based recommendations for the management of different clinical scenarios.

© 2023 European Association for the Study of the Liver. Published by Elsevier B.V. All rights reserved.



## Background

Approximately 1 in 10,000 infants are born with a univentricular heart and are unlikely to survive without cardiac surgery.<sup>1–4</sup> Fontan-type surgery is the final step in the sequential palliative surgical treatment for these cases, and it is usually performed in infants between the ages of 2 and 4 years.<sup>5–7</sup> The procedure aims to restore serial circulation and avoid cyanosis at the expense of chronic high central venous pressure (CVP) and low cardiac output.<sup>4,8–10</sup> Those long-term maintained haemodynamic changes promote liver damage in virtually all patients. Although similarities exist in the pathophysiology of other congestive hepatopathies in adults with right-sided heart failure, Fontan-associated liver disease (FALD) is more complex and severe.

The number of persons living with Fontan-type surgery in 2020 has been estimated to be 66 per million, expected to rise to 79 per million by 2030. In 2020, this population comprised 55% adults, 17% adolescents, and 28% children, proportions which are expected to shift to 64%, 13%, and 23%, respectively, by 2030.<sup>11–13</sup> This increasing number of adult Fontan patients and the recent publication of several cases of hepatocellular carcinoma (HCC) in this young population have focused interest on FALD.<sup>14,15</sup> Due to the lack of a uniform definition of FALD and the competitive risk of other

complications developed by Fontan patients, the impact of FALD on the prognosis of these patients is currently debatable. However, there is evidence suggesting that the identification of advanced FALD could identify a group of patients with a worse prognosis. Given these concerns and the increasing number of recent publications on FALD, the European Association for The Study of the Liver (EASL) and the European Reference Network on Rare Liver Diseases (ERN RARE-LIVER) decided to launch the present position document. The aims of the current paper are: (1) to provide a clear definition and description of FALD, including clinical, analytical, radiological, haemodynamic, and histological features; (2) to facilitate guidance for staging the liver disease; and (3) to provide evidence- and experience-based recommendations for the management of different clinical scenarios.

## Methods

### Review of evidence

This position document is based on a systematic literature search according to a PICO format (**P** Patient, Population or Problem; **I** Intervention, Prognostic Factor, or Exposure; **C** Comparison or Intervention [if appropriate]; **O** Outcome of interest), using clinical scenarios. A comprehensive literature re-

Keywords: Fontan surgery; Fontan-associated liver disease; congenital heart disease; liver fibrosis; hepatocellular carcinoma; liver nodules; portal hypertension; esophageal varices; ascites; liver transplantation; heart transplantation.

Received 6 July 2023; accepted 6 July 2023;

\* Corresponding author. Address: Barcelona Hepatic Hemodynamic Laboratory, Liver Unit, Hospital Clínic, Institut de Investigacions Biomèdiques August Pi i Sunyer (IDIBAPS), University of Barcelona, Barcelona, Spain.

E-mail address: JCGARCIA@clinic.cat (J.C. García Pagán)

† ERN RARE-LIVER

<https://doi.org/10.1016/j.jhep.2023.07.013>



ELSEVIER

view identified articles in English relevant to FALD care for each topic area, employing keywords proposed for each clinical scenario and topic. MEDLINE and Cochrane Library have been used. Possible exceptions (*i.e.*, data not published or analyzed explicitly for the current document) in topics with little or no direct evidence were also accepted.

### Level of evidence

The guidance in this position document could not be conventionally evidence-based. As is typical for a rare disease, few large-scale prospective or randomized controlled studies have been completed for FALD. Therefore, guidance has been addressed using a method that queries a group of experts on the appropriateness and necessity of specific definitions, assessments, and interventions. This method was intended to objectify expert opinion and to make the guidance a true reflection of the views and practices of an expert panel based on their interpretation and application of the existing scientific literature.<sup>16</sup> Following the definitions used by the GRADE (Grading of Recommendations Assessment and Evaluation) Working Group, we adapted the level of evidence (LoE) into four categories (high: further research is very unlikely to change our confidence in the estimate of effect; moderate: further research is likely to have an important impact on our confidence in the estimate of effect and may change the estimate; low: further research is very likely to have an important impact on our confidence in the estimate of effect and may change the estimate; and very low: any estimate of effect is very uncertain).<sup>17</sup>

### Strength of recommendation

As a specific rare disease, few high-quality studies are available. Consequently, the strength of the recommendation has been adapted to this scenario and divided into two categories: strong and weak. The strength of recommendation was based on the quality of the evidence, consistency of studies, expert opinion, clinical relevance, cost-effectiveness, legal consequences, availability of care, and safety. Definitions and statements were not graded.

### Consensus

A list of 14 Steering Committee experts contributed to this position document development. These experts covered six specialties: hepatologists, cardiologists, paediatricians, cardiac surgeons, radiologists, and pathologists. Expert selection criteria included: relevant publication experience, authors H-index, and perception as experts by their peers (authors called upon by the medical community to present their knowledge on FALD in international meetings). The Steering Committee was led by one ERN RARE-LIVER selected chair (JCGP) and one EASL representative (PER), who advised and drove the consensus. Each selected expert took responsibility and made proposals for definitions, statements, and recommendations for a specific section of the position document based on their expertise and shared the text summarizing the evidence with the working group. The consensus process for final statements and recommendations was based on unstructured methodologies (four teleconferences). All panelists discussed and approved all definitions, statements, and recommendations.

### Proposed clinical scenarios and PICO questions

The panel initially established the most relevant topics to address, considering the published evidence and clinical relevance. The ten main topics that the panel included were.

- a) Definition and description of the population
- b) Definition of FALD
- c) Clinical evaluation and staging of FALD
- d) Portal hypertension considerations in FALD
- e) Liver nodules and risk of HCC in FALD
- f) Management of HCC in FALD
- g) Heart and combined (heart-liver) transplantation in FALD
- h) Other liver-related issues
  - i) Role of FALD surveillance programs and specialized multidisciplinary units in FALD
- j) Unmet needs and future directions

### Description of the population

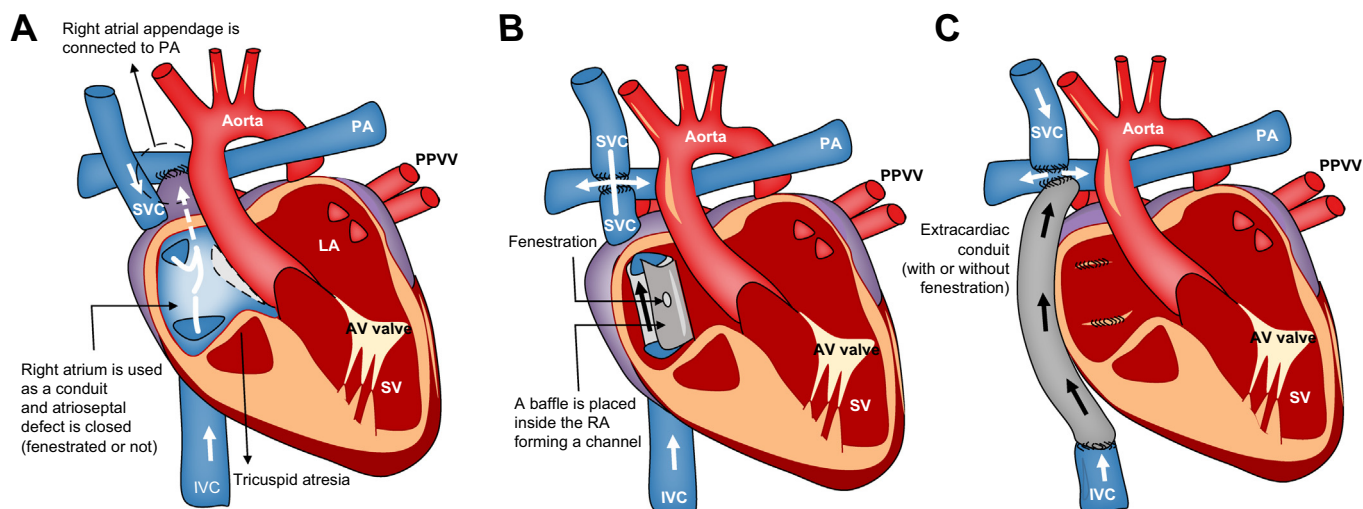
#### Statements

- Fontan circulation is the result of connecting the systemic veins directly to pulmonary arteries. Thus, the pulmonary and systemic circulations are connected in series but without a sub-pulmonary ventricle, resulting in a central venous pressure higher than normal (**High LoE**).
- Fontan circulation can fail due to systolic or diastolic ventricular dysfunction, atrioventricular valve disease, elevated pulmonary vascular resistance, recurrent arrhythmia, lymphatic insufficiency, or end-organ complications. Accordingly, symptoms may be related to heart failure and hypoxemia or end-organ complications, resulting in different clinical and haemodynamic Fontan failure phenotypes (**Moderate LoE**).
- Fontan circulatory failure should be considered in patients with at least one of the following criteria: New York Heart Association (NYHA) functional class IV, NYHA functional class III for  $\geq 12$  months without sustained improvement,  $>2$  unscheduled hospital admissions within 12 months for heart failure symptoms, and active protein losing enteropathy (PLE) or plastic bronchitis (PB) without remission for  $\geq 6$  months (**Low LoE**).

### What is Fontan-type surgery?

The Fontan procedure was first described in 1971 as a palliative procedure for patients with tricuspid atresia and since then has been used for a variety of univentricular heart defects. It is mainly used in patients with congenital univentricular heart disease when a biventricular repair is not feasible.<sup>4</sup> In simple terms, the Fontan-type techniques create a new circulatory system (Fontan circulation) connecting the systemic venous return from both the inferior and superior vena cava and the pulmonary arteries, avoiding the right ventricle, which will passively transmit the blood through the lungs to the single ventricular chamber.

The original approach (the atriopulmonary connection or classic Fontan) was described for patients with tricuspid atresia and consisted of closing the atrial septal defect and connecting



**Fig. 1. The different Fontan-type procedures.** (A) The atriopulmonary appendage connects the RA directly to the right PA. (B) The intracardiac total cavopulmonary connection or lateral tunnel procedure connects the SVC to the right PA. A baffle is placed inside the RA, forming a channel to direct blood from the IVC to the PA. (C) The extracardiac cavopulmonary connection consists of a direct anastomosis of the SVC to the PA and in the interposition of an extracardiac prosthesis between the IVC and the PA. AV, atrioventricular; IVC, inferior vena cava; LA, left atrium; PA, pulmonary artery; PPVV, pulmonary veins; RA, right atrium; SV, single ventricle; SVC, superior vena cava.

the right atrium directly to the right pulmonary artery. Several modifications were introduced later (Fig. 1A).<sup>4,7,18,19</sup> Shortly, Kreutzer *et al.* described their modified atriopulmonary connection, and Björk *et al.* reported a right atrial-right ventricular connection.<sup>20,21</sup> More recently, the total intracardiac cavopulmonary connection or lateral tunnel was established by De Leval in 1988.<sup>8</sup> This procedure connects the superior vena cava to the right pulmonary artery (classical Glenn shunt) and the inferior vena cava to the pulmonary arteries through a patch-created intracardiac tunnel in the right atrium (Fig. 1B). Finally, the most recent approach, the extracardiac cavopulmonary connection, consists of a direct anastomosis of the superior vena cava to the right pulmonary artery and the interposition of an extracardiac vascular prosthesis between the inferior vena cava and the right pulmonary artery (Fig. 1C).<sup>22</sup> The advantage of the latter surgical technique is that it can be performed without myocardial ischaemia, and there are fewer suture lines and no foreign material in the right atrium.

### What haemodynamic changes are associated with Fontan circulation?

The pulmonary and systemic circulations are connected in series in the normal heart, and a ventricle supports each circulation. The right ventricle acts as a pump and drives the systemic venous blood into the pulmonary circulation. The tricuspid valve guards the right atrium and the systemic veins from the pressure generated in the right ventricle. Therefore, CVP remains low (<10 mmHg) while the systolic pulmonary artery pressure is higher (>15 mmHg).<sup>23</sup>

In the Fontan circulation, the pulmonary and systemic circulations are connected in series, like in the normal heart, but without a sub-pulmonary ventricle. The systemic venous blood is directly channeled into the pulmonary arteries from the systemic veins, and the active force of the right ventricle propelling the blood is lost. In this situation, pulmonary pressure is a result of pulmonary artery resistance and pulmonary blood flow, which is passive and dependent on central CVP. Compared to

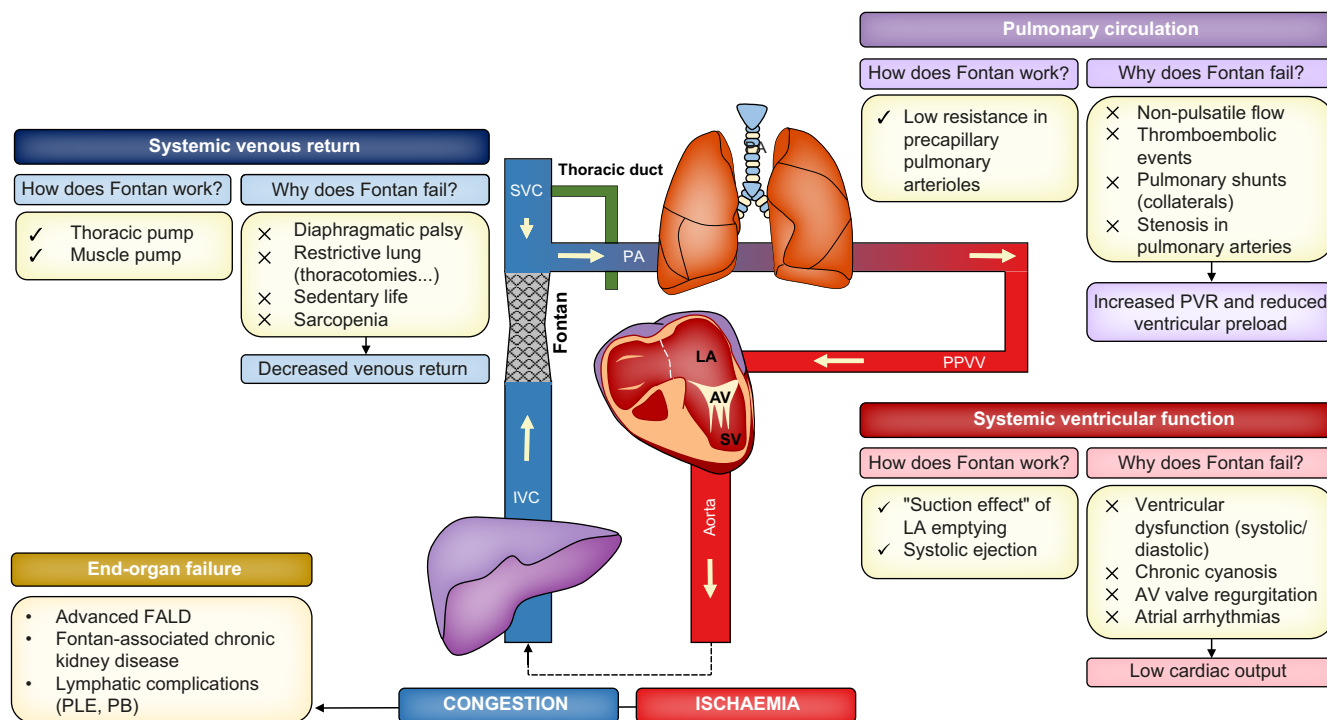
healthy individuals, the cavopulmonary connection results in an obligate higher CVP than normal (>10 mmHg) (Fig. 2).<sup>24</sup>

In this situation, three driving forces make possible the passage of blood flow from the systemic venous system to the left (systemic) atrium: 1) the "suction effect" of the left atrium emptying, resulting from the combination of good systolic and diastolic function of the single ventricle, atrioventricular synchrony, and the normal function of the systemic atrioventricular valve; 2) the "lung and muscle pump" resulting from the negative intrathoracic pressure created by inspiration, increased inferior vena cava return (secondary to diaphragmatic contraction and promoted by exercise), and increased recruitment of lung vessels;<sup>25</sup> and 3) the low resistance in the pulmonary circuit (precapillary arterioles) in the absence of mechanical stenosis in the Fontan conduit, main pulmonary arteries, and pulmonary veins.

Despite central venous hypertension, patients are in a ventricular preload deficient state after Fontan completion. Systemic venous return must traverse the pulmonary circuit (in case of no fenestration and collaterals) before filling the single (systemic) ventricle, resulting in low end-diastolic volume and decreased stroke volume.<sup>26</sup> At rest, the cardiac output of a Fontan patient is at least reduced to 80% of normal. During exercise, the increase in cardiac output is even more impaired due mainly to decreased preload (augmentation of pulmonary blood flow is limited due to the lack of a sub-pulmonary ventricle) and concurrent factors like chronotropic insufficiency, decreased oxygen saturation, and reduced muscle mass (Fig. 2).<sup>27,28</sup>

### What are the main end-organ complications of Fontan circulation?

Chronic systemic venous congestion and relatively low cardiac output form the basis for potential deleterious end-organ consequences. Several systems and organs might be affected:<sup>29</sup>



**Fig. 2. How the Fontan circulation works in the absence of a sub-pulmonary pump and why the Fontan circulation fails: the three key elements.** FALD, Fontan-associated liver disease; LA, left atrium; PA, pulmonary artery; PB, plastic bronchitis; PLE, protein-losing enteropathy; PPVV, pulmonary veins; PVR, pulmonary vascular resistance; SV, single ventricle.

- Heart: arrhythmias, valvulopathies, and single ventricle dysfunction.<sup>30,31</sup>
- Liver: FALD and HCC.<sup>32–34</sup>
- Kidney: Fontan-associated chronic kidney disease.<sup>35</sup>
- Gut: PLE.<sup>36,37</sup>
- Bone: bone mineral deficiency.<sup>38</sup>
- Lungs: pleural effusion and hypoxia due to intrapulmonary shunts.<sup>39</sup>
- Brain: neurocognitive disorders and behavioural deficits.<sup>40</sup>
- Lymphatic system: chylothorax, chyloous ascites, PLE, and PB (characterized by the leakage of proteinaceous material into the airways).<sup>34,41,42</sup>
- Vascular system: thromboembolism, peripheral oedema, and lower extremity venous insufficiency.<sup>43–46</sup>

The reported prevalence of end-organ complications is 16–34% for arrhythmia,<sup>47–49</sup> 13–86% for FALD,<sup>50–52</sup> 10–50% for nephropathy,<sup>53–56</sup> 1–5% for PLE,<sup>57</sup> 50–60% for venous insufficiency,<sup>46,58</sup> and 1–4% for PB.<sup>59</sup> However, the actual prevalence of some of these disorders could be higher due to subclinical disease presentation and the lack of universal definitions.<sup>60</sup>

### What is the Fontan circulatory failure?

A recent consensus statement proposed a standardized definition for Fontan circulatory failure as a non-specific term to describe a deteriorated clinical status affecting the patient's ability to carry out daily activities.<sup>34</sup> This complex syndrome can result from multiple potential aetiologies such as ventricular dysfunction, atrioventricular valve failure, increased pulmonary vascular resistance, recurrent arrhythmia, Fontan pathway

obstruction, lymphatic insufficiency (PLE, PB, or chyloous ascites), or other end-organ dysfunction.<sup>61–63</sup> Accordingly, symptoms may be related to heart failure and hypoxemia or end-organ complications (mainly PLE, PB, or advanced FALD), resulting in different clinical and haemodynamic Fontan failure phenotypes (patients with systolic ventricular dysfunction [reduced ejection fraction]; with diastolic ventricular dysfunction [preserved ejection fraction]; with systemic congestion but preserved ventricular function; and with abnormal lymphatics).<sup>64</sup> This clinical picture is the most frequent cause of death in this population and should be suspected in all patients meeting at least one of the following criteria: NYHA functional class IV; NYHA functional class III for  $\geq 12$  months without sustained improvement;  $> 2$  unscheduled hospital admissions within 12 months for heart failure symptoms; and active PLE or PB without remission for  $\geq 6$  months.<sup>56,65–68</sup> In a cohort including 683 Fontan patients aged  $> 16$  years, the probability of remaining free from Fontan circulatory failure was 93%, 77%, 62%, and 30% at ages 20, 30, 40, and 50 years, respectively.<sup>69</sup>

### What is the prognosis of patients with Fontan circulation?

The success of Fontan-type surgery has increased in parallel with advances in surgical procedures and perioperative management.<sup>5,70–72</sup> While in the 1980s, only 73% of Fontan patients reached adolescence, today, this is achieved by more than 95%.<sup>15,73,74</sup> Nonetheless, observational studies have shown that although Fontan-type surgery is an excellent medium-term solution, it is suboptimal in the long term, and the resulting circulation cannot be maintained indefinitely.<sup>75</sup> Distinctively, adults with Fontan circulation have the highest

mortality ratio of any congenital heart disease, with a more than 20-fold increased risk of death compared to an age-matched population.<sup>76</sup> As a clarifying example, a 20-year-old Fontan patient has approximately the same 5-year risk of death as a 64-year-old individual in the general population.<sup>75</sup>

## Definition of Fontan-associated liver disease

### Statements

- FALD encompasses a broad spectrum of structural, functional, and clinical liver alterations secondary to Fontan haemodynamic changes (**Moderate LoE**).
- Some degree of FALD is universally present after Fontan-type surgery. Liver damage can start even before the Fontan procedure and is present in patients without Fontan circulatory failure (**Moderate LoE**).
- There is not a homogeneous definition of advanced FALD. A proposal is to consider advanced FALD in patients with clinical signs highly suggestive of portal hypertension (oesophageal varices, portosystemic shunts, ascites, or splenomegaly) due to liver fibrosis (**Low LoE**).
- The time elapsed from Fontan-type surgery is the main risk factor for developing advanced FALD (**High LoE**).
- Fontan patients can exhibit additional risk factors for liver damage, such as an increased prevalence of HCV or HBV infection or the use of hepatotoxic drugs (*i.e.*, amiodarone) (**High LoE**).

### How is FALD defined?

In 1983, Lemmer *et al.* described, for the first time, the development of severe liver fibrosis in a patient 5 years after Fontan surgery.<sup>77</sup> Since then, many clinical series have employed the term FALD to name this particular liver damage, providing incidence rates ranging from 36% to 86%, depending on the diagnostic method used (signs and symptoms, imaging, liver biopsy, serological tests, or combined evaluations).<sup>77–84</sup> However, the true incidence of FALD is unknown and likely under-recognized, as we lack a uniformly accepted definition of the disease. Findings from elective liver biopsy indicate that all patients with Fontan circulation have some degree of liver fibrosis. Indeed, liver damage may begin even before the Fontan completion due to the numerous haemodynamic insults cumulatively developed from birth, as suggested in autopsy studies performed in patients who died very soon after the Fontan procedure.<sup>32,85–87</sup>

FALD encompasses a broad spectrum of structural, functional, and clinical liver alterations secondary to Fontan haemodynamic changes. These changes are secondary to the pathological haemodynamic state that exists in any kind of Fontan circulation since the first day of the surgical procedure, which means that FALD can also occur in patients without Fontan circulatory failure. This definition agrees with the recent expert consensus launched by several societies and initiatives involved in Fontan patient care.<sup>34,88</sup>

### What is the pathophysiology of FALD?

Different mechanisms related to the vascular supply and drainage of the liver have been linked to the development of hepatic damage in Fontan patients.

- **Liver congestion:** The hepatic veins transmit systemic venous hypertension to the sinusoid, leading to sinusoidal dilatation, hyperfiltration, and perisinusoidal oedema.<sup>32,89</sup> In turn, sinusoidal shear stress promotes sinusoidal endothelial cell capillarization, decreases intrahepatic nitric oxide concentration, and facilitates the mechanical activation of mechanosensitive cell signaling pathways in hepatic stellate cells, resulting in liver fibrosis.<sup>90–92</sup> These changes also hamper the diffusion of oxygen and nutrients and promote centrilobular hepatocellular dropout and atrophy.<sup>93</sup> The severity of liver congestion is heterogeneous due to the technique-dependent flow characteristics of the Fontan connection in each patient, which partly explain the interindividual variability seen in liver damage.<sup>94</sup>
- **Hypoxia and hepatic ischaemia:** Elevated CVP may reduce the effectiveness of the hepatic arterial buffering response.<sup>95–97</sup> These changes put the liver at risk for hypoxemic injury during an acute event (cardiac surgeries or cardiopulmonary collapse). Moreover, in the long term, chronic reduced cardiac output and the development of aberrant intrapulmonary shunts would perpetuate liver hypoxia.<sup>98,99</sup>
- **Prothrombotic state:** Hepatic sinusoidal thrombosis, as evidenced by fibrin deposition, has been demonstrated both in animal models of FALD and in humans with Fontan circulation.<sup>90,91</sup> The anatomical and functional characteristics of the Fontan circulation and the acquired thrombophilic state (low serum levels of antithrombin III, thrombomodulin, alpha-2-antiplasmin, and C and S proteins and high levels of thrombin-antithrombin complex) could facilitate intrahepatic microthromboses.<sup>100–105</sup>
- **Lymphatic congestion:** Increased hepatic lymphangiogenesis and lymphatic stasis contribute to significant dilatation of hepatic sinusoids, the space of Disse, and channels passing through the limiting plate, which may contribute to collagen fiber deposition.<sup>106,107</sup>
- **Systemic inflammation:** It has been speculated that a state of latent microinflammation may promote end-organ fibrogenesis (*i.e.*, kidneys, liver, and myocardium).<sup>108</sup> Increased intestinal permeability secondary to venous and lymphatic congestion and chronic ischaemia may play a central role in the inflammatory state.<sup>109</sup>
- Other risk factors include an increased prevalence of hepatitis C (~ 4% of chronic infection) and B virus infection and risk of hepatotoxic injury due to medications (*i.e.*, amiodarone).<sup>110–112</sup>

### What is the definition of, and what are the risk factors for, advanced FALD?

There is no uniform definition of advanced FALD, and several studies have proposed arbitrary definitions based on serological biomarkers and radiological, histological, or clinical evaluations.<sup>83,113–115</sup> Combined clinical serological and radiological scores, such as the VAST score (VAST score >1, 1 point each for the presence of oesophageal varices, ascites, splenomegaly, or thrombocytopenia), have been proposed to diagnose advanced FALD. However, we need more data to establish these scores as a gold standard.<sup>83</sup> A proposal is to consider advanced FALD in those patients with clinical, endoscopic, or

radiological signs of portal hypertension (varices, portosystemic collaterals, ascites, or splenomegaly) secondary to liver fibrosis. Extrapolating the current concept from other advanced chronic liver diseases, advanced FALD can be sub-classified as compensated or decompensated. FALD would be defined as decompensated when patients have developed liver-related complications, including encephalopathy (any grade), liver-related ascites (grade >1), and (or) variceal bleeding.

Although risk factors for severe liver damage are not well-established, there is a clear relationship between the severity of liver damage and the time elapsed from Fontan-type surgery.<sup>116,117</sup> The risk of advanced FALD and severe fibrosis is low within the first 5 years after surgery but increases significantly after 15 years.<sup>78,85,118–121</sup> In a retrospective study using non-invasive tests, the authors reported 10-, 20- and 30-year freedom from cirrhosis rates of 99%, 94%, and 57%, respectively.<sup>122</sup> Older age at the time of Fontan-type surgery has also been related to augmented fibrosis, suggesting that prolonged univentricular circulation promotes fibrogenesis.<sup>86,123</sup> The atriopulmonary surgery variant has also been associated with a higher degree of liver fibrosis. However, this surgery was employed decades ago and has been replaced by total cavopulmonary techniques, so this observation is susceptible to time-dependent bias. Females have significantly higher median total fibrosis scores than males for a similar average age and Fontan circulation duration.<sup>124</sup> Other authors have suggested that those with an extracardiac connection may develop hepatic fibrosis faster than those with a lateral tunnel connection due to the different compliance.<sup>125,126</sup> Hypoplastic left ventricular syndrome, as the underlying cardiac defect, is also related to more severe liver disease in one small case series.<sup>122</sup> Intrapulmonary shunts and secondary chronic hypoxemia may increase the risk of advanced liver fibrosis.<sup>127</sup> Finally, several studies have linked the degree of liver damage (estimated by non-invasive methods) with some adverse cardiovascular events presented during follow-up: decreased ventricular function, increased pulmonary resistance, tachyarrhythmia, sinus node dysfunction, atrioventricular valve insufficiency, and Fontan conduit thrombosis or stenosis.<sup>50,79,115,128–131</sup>

### What are the main histological characteristics that define FALD?

Histologically, FALD is typified by gross architectural distortion, massive sinusoidal dilation, and perisinusoidal fibrosis in the absence of significant parenchymal inflammation.<sup>30,89</sup> The most notable feature is sinusoidal dilatation, which extends from the centrilobular region (zone 3) to the portal tract (zone 1).<sup>89</sup>

As in other congestive liver diseases, histological changes predominantly affect the centrilobular zone instead of the portal area.<sup>129–135</sup> Fibrosis starts with a fine neomatrix deposited within the space of Disse and progresses, matures, and enlarges over time. The extreme long-standing congestion extends fibrosis even to the portal area, which may differentiate FALD from other congestive hepatopathies.<sup>86,89,119,121,136–138</sup> In FALD, cirrhosis is histologically defined by regenerative liver nodules and scar areas of bridging fibrosis, linking the central vein initially to the central vein and then the central vein to the portal tract or portal to portal tract.<sup>121,139</sup>

Perisinusoidal and centrilobular fibrosis is typically accompanied by centrilobular vascular alterations such as arterialization, microvessel formation, sinusoidal capillarization, and centrilobular

ductular metaplasia, overall leading to loss of typical liver zonation. Centrilobular microvessel formation and sinusoidal capillarization are closely interrelated and are found in the early and late stages. The ingrowth of centrilobular arterioles could result from vascular remodelling during fibrosis progression.<sup>140</sup> In addition, most FALD biopsies show some degree of ductular reaction.<sup>89</sup>

Hepatocellular necrosis can be described in the setting of shock or respiratory failure.<sup>132</sup> On the other hand, portal inflammation, steatosis, ballooned hepatocytes, apoptotic bodies, ceroid-laden macrophages, and iron deposition are not hallmarks of FALD but can be observed in patients with risk factors for comorbidity.<sup>86,138</sup> No differences in terms of morphological substrates between paediatric and adult populations have been identified. The only key issue is the amount of collagen deposition, which correlates with the length of follow-up.<sup>87</sup>

## Clinical evaluation and staging of Fontan-associated liver disease

### Statements

- FALD is typified by gross architectural distortion, massive sinusoidal dilation, and perisinusoidal fibrosis in the absence of significant parenchymal inflammation (**High LoE**).
- In patients with FALD, liver fibrosis is nearly universal and distinctively involves both centrilobular and portal areas (**High LoE**).
- The patchy distribution of fibrosis in FALD may lead to underestimation of its stage (**Moderate LoE**).

### When is a liver biopsy indicated in Fontan patients?

### Recommendations

- Liver biopsy should be considered the gold standard for assessing liver fibrosis in FALD (**Moderate LoE; strong recommendation**).
- Liver biopsy is recommended in patients with Fontan circulatory failure who are candidates for heart transplantation or if another aetiology of liver disease is present or suspected (**Low LoE; strong recommendation**).

Although quantification of liver fibrosis has been proposed as one of the primary predictive tools in patients with FALD, cross-sectional and retrospective studies have demonstrated poor correlation with clinical outcomes without differences in heart transplant-free survival according to the stage of liver fibrosis.<sup>137,141</sup> To date, no study has prospectively compared biopsy findings with the risk of relevant clinical events. Biopsy has several limitations: high costs compared to non-invasive methods, the potential need for anaesthesia, the risk of bleeding and the risk of sampling error due to the extremely patchy nature of FALD.<sup>138,142–144</sup> Indeed, fibrosis grade was underestimated in 40% of liver biopsies obtained during the pretransplant evaluation of Fontan patients who underwent heart-liver transplantation.<sup>145</sup>

Despite these inherent limitations, most authors agree that biopsy remains the gold standard for disease staging. The need for well-designed longitudinal and prospective studies evaluating these strategies prevents us from supporting the routine performance of liver biopsy in all patients with Fontan circulation. There are two clear indications for liver biopsy: 1) in patients with Fontan circulatory failure who are candidates for cardiac transplantation, to help to decide whether combined heart-liver transplantation would be required to treat dual organ failure,<sup>146,147</sup> and, 2) if another aetiology of liver disease is present or suspected. Finally, some authors have suggested that biopsies systematically performed 10-15 years after completion of the Fontan procedure or when cardiac catheterization is indicated, may help to identify patients who should be referred early for medical or interventional optimization of Fontan circulation to prevent or reduce liver disease progression.<sup>14,129,148-151</sup>

### **What is the best scoring system for grading fibrosis in FALD?**

#### **Recommendations**

- Simplified scoring systems integrating central zone and portal fibrosis are preferred in FALD. A combined 4-scale scoring system, such as the congestive hepatic fibrosis score, is accurate and clinically relevant and therefore suggested (**Low LoE, weak recommendation**).

Traditional staging systems of portal fibrosis, using Metavir, Ishak, and Scheuer, are helpful in identifying cirrhosis in FALD, but the intermediate stages of these scores may underestimate the severity of liver fibrosis.<sup>14,85,120</sup> To overcome this limitation, Kendall *et al.* used a hybrid fibrosis staging system based on gross architectural distortion (ranging from 0 to 4, modified from the Metavir system) and sinusoidal fibrosis (ranging from 0 to 3, according to the area involved).<sup>89</sup> Similarly, Wu *et al.* evaluated liver fibrosis in a series of 68 Fontan patients using dedicated semiquantitative scoring systems for portal fibrosis (Metavir system) and central fibrosis based on the extent of pericellular fibrosis (ranging from 0 to 4).<sup>137</sup> In contrast, other authors proposed using simplified scoring systems integrating centrilobular and portal fibrosis, such as the congestive hepatic fibrosis score (ranging from 0 to 4) or the modified Ishak congestive hepatic fibrosis histologic score (ranging from 0 to 6) (Table 1).<sup>132,136</sup> As these scores may overestimate fibrosis, Louie *et al.* adapted a 3-scale scoring system from liver explants and biopsies, with stage 3 defined as bridging fibrosis with regenerative nodules.<sup>142</sup> We propose considering a combined 4-scale scoring system (*i.e.*, congestive hepatic fibrosis score) as more accurate and clinically relevant, as it may reflect liver changes in FALD better (centrilobular and portal damage) and may be easier to implement for pathologists and clinicians who are familiar with 4-scale scores in other chronic liver diseases.<sup>14,120,129,141,151</sup> Importantly, whereas interobserver agreement has been evaluated in very few studies in the context of FALD, it is much better on portal fibrosis (>0.7) than on sinusoidal fibrosis and significantly improved after a training session.<sup>132,141</sup>

In parallel to semiquantitative fibrosis scoring systems, quantitative measurement of collagen deposition area through specific staining (*i.e.*, picrosirius red) using dedicated software may provide an objective global assessment of portal and centrilobular fibrosis.<sup>85,120,141</sup> As previously reported in chronic HCV infection, quantitative measurement of fibrosis correlated with semiquantitative staging systems.<sup>120,141</sup>

### **What are the minimum criteria for quality histological specimens for accurate fibrosis staging in FALD?**

#### **Recommendations**

- Liver biopsy should be performed and evaluated in referral centres in FALD (**Low LoE; strong recommendation**).
- Routine staining for assessment of liver fibrosis may include Masson trichrome and picrosirius red. Orcein staining may provide further information on the maturity of fibrosis and the potential for reversibility (**Moderate LoE, weak recommendation**).

No studies have specifically addressed the representability of liver biopsy in FALD.<sup>152</sup> However, a non-fragmented specimen with a length of at least 15 mm is usually considered adequate in FALD.<sup>120,132</sup> Munsterman *et al.* defined adequate biopsy samples as having a length >2 cm and the presence of at least 11 portal tracts.<sup>141</sup> In addition to length, the width of liver biopsy, which is usually not reported, should be considered given the potential underestimation of fibrosis staging in narrow samples. Given the risk of sampling bias, we suggest performing at least two different passes.

Different staining methods, such as Masson trichrome and picrosirius red, are routinely performed to assess liver fibrosis.<sup>85,132</sup> Evaluation of the quality and texture of fibrosis is also essential as it reflects the chronicity of liver injury and its potential reversibility. Accordingly, orcein staining provides further information on the maturity of fibrosis and its potential for regression after Fontan circulatory failure improvement or heart transplantation.<sup>89</sup>

Beyond these minimum quality criteria of a liver biopsy, it is necessary to highlight that the pathologist's expertise is crucial. We recommend that dedicated pathologists interpret FALD biopsies in referral centres.

### **Is there any preference regarding the route of liver biopsy (transjugular or percutaneous) in Fontan patients?**

#### **Recommendations**

- The diagnostic quality of liver tissue samples obtained by transjugular and percutaneous approaches is similar. Given the risk of sampling bias, performing at least two different passes is suggested (**Very low LoE; weak recommendation**).
- The transjugular approach may be preferred over the percutaneous, based on safety considerations and the possibility of performing cardiac and hepatic vein catheterization during the same procedure (**Low LoE; weak recommendation**).



**Table 1. Histological grading systems integrating centrilobular and portal fibrosis employed to evaluate hepatic specimen of patients with FALD.**

<b>Congestive hepatic fibrosis score (CHFS)<sup>134</sup></b>	
0	No fibrosis
1	Central zone fibrosis
2a	Central zone and mild portal fibrosis, with accentuation at central zone
2b	At least moderate portal fibrosis and central zone fibrosis, with accentuation at portal zone
3	Bridging fibrosis
4	Cirrhosis
<b>Modified Ishak congestive hepatic fibrosis score<sup>131</sup></b>	
0	No fibrosis (similar to CHFS 0)
1	Central zone fibrosis (similar to CHFS 1)
2a	Central zone and portal fibrosis, with accentuation of fibrosis in the central zone (similar to CHFS 2a)
2b	Portal and central zone fibrosis, with accentuation of fibrosis in the portal zone (similar to CHFS 2b)
3	Fibrous expansion of most portal areas with occasional portal to portal or portal to central bridging (similar to Ishak score 3)
4	Fibrous expansion of most portal areas with marked portal to portal or portal to central bridging (similar to Ishak score 4)
5	Marked bridging with occasional nodules or incomplete cirrhosis (similar to Ishak score 5)
6	Cirrhosis (similar to CHFS 4 or Ishak score 6)
<b>Modified Metavir system<sup>91</sup></b>	
0	No definite fibrosis
1	Minimal fibrosis (no septa or rare thin septum)
2	Mild fibrosis (occasional thin septa)
3	Moderate fibrosis (moderate thin septa; up to incomplete cirrhosis)
4	Cirrhosis definite or probable
<b>3-scale scoring system for changes related to chronic congestion<sup>144</sup></b>	
0	No fibrosis
1	Pericellular fibrosis
2	Bridging fibrosis
3	Bridging fibrosis and regenerative nodules

Transjugular and percutaneous routes can be equally effective. Nevertheless, as morphological features are preferentially observed in subcapsular areas, the percutaneous route is expected to be the most informative, especially when performed with ultrasound guidance, allowing for the selection of the most abnormal regions.<sup>142,153,154</sup> While there have been suggestions that transjugular biopsy may introduce a sampling bias as it preferentially samples the perivascular region, which may theoretically be more affected by venous congestion, this was not confirmed by Vaikunth *et al.*, who showed that transjugular biopsy somewhat underestimated fibrosis.<sup>145</sup> This could be partly explained by the narrower and more prone fragment samples obtained by the transjugular route. Despite these limitations, the transjugular approach has some advantages, it provides additional liver haemodynamic data, can be performed during cardiac catheterization, and is safer. A recent cohort of percutaneous liver biopsies confirmed this population's high risk of bleeding, with a 7.1% post-procedural haemorrhage rate (minor in 5.9% and major in 1.5%, despite using tract embolization with gelatin sponge in 76%), compared to 3.2% reported with the transjugular route.<sup>151,153</sup>

#### **Is hepatic venous pressure gradient a valuable measurement for staging and grading portal hypertension in FALD?**

The HVPG facilitates the differential diagnosis of portal hypertension: high hepatic vein pressures (free and wedged) with a

#### **Statements**

- The hepatic haemodynamic profile of FALD is characterized by high hepatic vein pressures (free and wedged) with a normal hepatic venous pressure gradient (HVPG), *i.e.* post-sinusoidal portal hypertension (**High LoE**).
- HVPG has no value in assessing the presence of advanced fibrosis or the severity of portal hypertension and does not have prognostic significance in Fontan patients (**Moderate LoE**).

normal HVPG suggest a post-hepatic origin, the most frequent finding in advanced FALD.<sup>155</sup> In FALD, five studies assessed HVPG in 248 patients. In those studies, the median HVPG never exceeded 2 mmHg. In a recent large study including 56 Fontan patients, HVPG was not associated with the severity of liver dysfunction or the presence of signs of portal hypertension, nor with heart transplant-free survival.<sup>156</sup> As expected, HVPG did not correlate with liver stiffness or fibrosis severity.<sup>136,156,157</sup> Three studies evaluated the correlation between HVPG and cardiac haemodynamic features, concluding that HVPG was only poorly associated with a higher Fontan conduit, end-diastolic, and pulmonary arterial pressures.<sup>118,156,158</sup> Moreover, the increased prevalence of intra-hepatic veno-venous collaterals and intense hepatic vein dilatation may compromise the accuracy of HVPG measurement.<sup>15,88</sup> Consequently, HVPG measurement has limited, if any, usefulness for staging the severity of FALD and does not have prognostic significance. The significance of absolute values of free and wedged pressures should be studied in the future.

#### **What are the typical symptoms and signs of FALD?**

FALD is often clinically silent and diagnosed through invasive and non-invasive liver tests. Due to the distension of the Glisson capsule, some patients report discomfort in the upper right quadrant of the abdomen. The liver edge is easily palpable, hard, smooth, and tender in these cases. Hepatojugular reflux could also be easily identified after applying compression over the liver. In adolescent Fontan patients, hepatomegaly is associated with poor cardiovascular outcomes.<sup>159</sup> Mild jaundice is common, yet deeper jaundice is rare, though it may occur at the end of an episode of hypoxic hepatitis. Finally, signs of portal hypertension may appear in the later stages of FALD.

#### **What are the typical laboratory abnormalities of FALD? Are serum biomarkers useful for the diagnosis and staging of FALD?**

#### **Statements**

- A mild increase in serum gamma-glutamyltransferase is the most common and early laboratory liver abnormality in Fontan patients. Slight elevations of serum bilirubin may also be present (**High LoE**).
- Most scores (*i.e.*, model for end-stage liver disease [MELD], MELD-Na, and Child-Pugh classification) may not be accurate to stage liver disease severity in this population (**Moderate LoE**).

## Recommendations

- Serological and combined serum-clinical tests used in other liver aetiologies (aspartate aminotransferase-to-platelet ratio index [APRI], ELF, FIB-4, Forns index, and FibroTest®) have a modest discriminatory power in identifying patients with severe fibrosis and cannot be routinely recommended for staging the liver disease (**Low LoE, strong recommendation**).

A mild increase in serum gamma-glutamyltransferase is the most common and early laboratory liver abnormality, present in >85% of adult Fontan patients.<sup>79,119,160</sup> However, markers of cholestasis are not clearly associated with worse cardiac function, more severe liver fibrosis or impairment of other liver function parameters.<sup>141,161–163</sup> Mild unconjugated hyperbilirubinemia is also frequently observed in FALD. Hyperbilirubinemia can be multifactorial and results from a combination of liver impairment and passive congestion or, less frequently, due to ischaemic biliary damage, haemolysis, or medications.<sup>154,164</sup> In the non-cirrhotic phase of FALD, passive congestion is associated with elevated prothrombin time and prolonged international normalized ratio (INR). Still, only one case series of 74 patients with FALD showed a relationship between elevated INR and the severity of fibrosis.<sup>120</sup> Aminotransferases are rarely elevated in stable Fontan patients, but they can increase in acute cardiac events (*i.e.*, after cardiac surgeries or a cardiovascular collapse), reflecting hypoxic injury and hepatocellular necrosis.<sup>154</sup> Low serum albumin levels may be secondary to PLE, nephropathy, malnutrition, or chronic wasting.<sup>57,109,165,166</sup> However, in advanced FALD, the liver's synthetic protein function may also fail and albumin levels decrease.

Addressing liver function is challenging since most commonly employed scores (*i.e.*, MELD and Child-Pugh classification) are based on creatinine, INR, albumin, and bilirubin, which may reflect liver function poorly in this population.<sup>35,167</sup> MELD score excluding the international normalized ratio (MELD-XI) can be employed to overcome the increased INR due to warfarin therapy.<sup>118</sup> MELD-XI has demonstrated a significant correlation with histologically proven liver fibrosis, though a specific MELD-XI cut-off value for severe liver fibrosis has not been identified. Other reports did not observe this correlation.<sup>141</sup> Retrospective studies suggest that the MELD-XI score correlates with systolic ventricular dysfunction and decreased oxygen saturation.<sup>168</sup> In a single-centre experience, MELD-Na was highly elevated in patients with bridging fibrosis who died.<sup>161</sup> Progressive thrombocytopenia is frequently found in FALD and may be associated with more advanced fibrosis, reflecting hypersplenism due to portal hypertension.<sup>83,150,161</sup>

Most serological tests used to estimate liver fibrosis in other chronic liver diseases (ELF score, APRI, FIB-4, FibroTest®, and Forns index) have been evaluated in FALD in several studies. However, these studies generally lacked histology as the gold standard and demonstrated a modest discriminatory power in identifying patients with severe fibrosis in FALD.<sup>78,81,129,169–174</sup> A single-centre study comparing patients with histologically proven mild and severe liver fibrosis did not find differences in ELF score, APRI, and FIB-4 values between the two groups.<sup>141</sup> Although APRI and FIB-4 were significantly higher in patients

with severe fibrosis in a larger cohort; these tests had a modest discriminatory power in identifying patients with advanced FALD.<sup>161</sup> Novel approaches should be clinically evaluated in the future.<sup>175</sup>

## What are the typical radiological abnormalities of FALD? Are radiological findings useful for diagnosing and staging FALD?

### Recommendations

- In abdominal imaging, typical findings of FALD are bulging liver contours, hepatomegaly, dilated hepatic veins, atrophy of the right lobe, hypertrophy of the caudate and left lobes, patchy and heterogenous parenchyma patterns, and multiple peripheral small nodules. These changes are more apparent with increased Fontan circulation duration and can be secondary to liver congestion, fibrosis, or both. Thus, abdominal imaging alone cannot be recommended for staging liver disease severity (**Low LoE, strong recommendation**).

In abdominal imaging, typical findings of FALD are bulging liver contours, hepatomegaly, atrophy of the right lobe, and hypertrophy of the caudate and left lobes, which become more apparent as the duration of the Fontan circulation increases.<sup>176,177</sup> Notably, the vascular origin of liver damage results in a patchy and heterogeneous distribution of fibrosis, which is also represented by multiple peripheral nodules of different sizes and peripheral irregular regions of poor enhancement after contrast administration. In advanced fibrosis and cirrhosis, the liver becomes less compliant, and dilated hepatic veins within the liver may not be observed.<sup>88</sup>

**Abdominal Doppler ultrasound:** The most frequent ultrasound findings are heterogeneous echogenicity (16–92%), a nodular liver surface, and small-sized hyperechoic nodules.<sup>30,50,178–182</sup> Heterogeneous echogenicity is not specific to congestion and can also be related to fibrosis, cirrhosis, or steatosis. Veno-venous shunts between hepatic veins can be seen in states of severe congestion.<sup>88</sup> Doppler changes in Fontan patients may show the same patterns as in patients with chronic liver disease, but the lack of three-phase blood flow of hepatic veins may be secondary to the loss of the atrial beat.<sup>181–183</sup>

**CT and MRI:** Hepatic MRI is preferable but not always possible due to contraindications such as incompatible cardiac devices, in which CT of the liver is recommended. The most common finding in CT and MRI is a heterogeneous parenchymal enhancement (68–98%) with mosaic or reticular liver patterns.<sup>80,82,119,182,184</sup> On MRI, the T2-weighted images frequently exhibit diffusely increased liver signal intensity that might reflect the degree of congestion.<sup>180,185</sup> This is contrary to hepatic fibrosis in non-congestive chronic liver disease, revealing typical changes such as peripheral reticular increased T2-weighted and decreased T1-weighted signal intensity.<sup>186</sup> The vascular contrast enhancement pattern on CT and MRI of the liver in a patient with Fontan circulation demonstrates a distinct peripheral, reticular, and patchy enhancement pattern during the late arterial and portal venous phases, which equilibrates during the delayed phase.<sup>187</sup> This configuration is probably due to delayed wash-in of contrast material into the

congested liver. Using hepatocyte-specific contrast agents, the heterogeneous enhancement of the liver parenchyma is most prominent during the portal venous phase and may equilibrate in the equilibrium or delayed phase.<sup>186</sup> A heterogeneous hypoenhancement in the hepatobiliary phase MRI using a hepatocyte-specific contrast agent may reflect decreased hepatic function.<sup>188</sup> Liver extracellular volume fraction, derived from MRI T1 relaxometry, is increased in Fontan patients, which suggests fibrotic remodelling and/or congestion in the liver, but its prognostic significance remains to be determined.<sup>189–191</sup>

In summary, most patients with Fontan circulation show radiological changes in the liver parenchyma, which may be related to congestion, fibrosis, or both. Only a few studies have compared the significance of these alterations to liver biopsy. They agree that conventional radiological changes highly suggestive of severe fibrosis in non-congestive aetiologies (*i.e.*, nodular liver contours, heterogeneous parenchyma, and segmental atrophy) are frequently present in Fontan patients even with absent, mild, or moderate fibrosis.<sup>141,161</sup> Consequently, the prognostic significance of radiological changes remains to be determined. One of the primary uses of CT and MRI in FALD stems from their accurate diagnosis and characterization of liver nodules.<sup>145,179</sup>

### Is liver stiffness helpful for staging liver fibrosis in FALD?

Different elastography techniques have studied the role of liver stiffness measurement (LSM) in Fontan patients: point shear-wave elastography, also called point radiation force impulse; two-dimensional shear-wave elastography imaging; transient elastography (TE) (Fibroscan®); and MR elastography (MRE). Their use in Fontan patients is challenging, as systemic venous congestion can increase LSM.<sup>192,193</sup> Compared to healthy controls, children and adults with Fontan-type surgery universally show increased values of LSM, mostly reaching values corresponding to advanced disease stages for non-congestive aetiologies.<sup>194–200</sup>

Studies using elastography have reported difficulties in staging fibrosis in children and adults with Fontan circulation. Only one study found a correlation between LSM estimated by ultrasound elastography and fibrosis grade on biopsy, and another work observed an association between LSM, ventricular pressure, and veno-venous collaterals.<sup>195,201</sup> However, other series displayed different results.<sup>202</sup> A few studies using TE have compared LSM to histology, but no strong correlation to fibrosis grade was found.<sup>141,157,203–205</sup> Other studies found a relationship between some parameters of liver impairment (MELD-XI, serum albumin, and platelets) and LSM estimated by TE, suggesting that in the later stages, fibrosis may contribute to LSM.<sup>118,170,182</sup> There is still little evidence of MRE's role in staging fibrosis. However, two small cohorts of adult Fontan patients revealed a strong correlation of LSM with histology and duration of Fontan circulation.<sup>129,199,206</sup> Elastography deserves prospective studies that might determine appropriate "normal" LSM values for Fontan patients and to evaluate if different cut-offs of LSM for ruling in and ruling out severe liver fibrosis could be established.

### Is LSM valuable for predicting clinical outcomes?

The relationship between LSM and strong liver-related outcomes has been scarcely studied.<sup>118,170,182,200,206–209</sup> Some

studies have demonstrated that patients with clinical signs of portal hypertension showed higher LSM than patients without portal hypertension, but no cut-offs have been established.<sup>162,182,203,204,210,211</sup> One small single-centre study showed that LSM was significantly higher in patients with liver nodules, but these results have not been replicated.<sup>179,212</sup> Unfortunately, no study has specifically evaluated the usefulness of elastography for risk stratification of HCC in this population. In one retrospective and longitudinal study including 22 patients, progression of LSM estimated by MRE correlated with clinical deterioration as measured by worsening liver disease severity scores (MELD and MELD-XI) and the occurrence of adverse events (death, heart-liver transplant listing, palliative care, hospitalization, and need for paracentesis).<sup>213</sup> Longitudinal and prospective studies are required to determine the specific role of elastography in predicting strong clinical outcomes.

The correlation between LSM and the risk of Fontan circulatory failure is debatable. In a study with MRE, haemodynamic signs of Fontan failure showed a weak correlation to LSM in adults, which was not reproduced in a paediatric cohort.<sup>211,214</sup> Other studies found moderate associations between LSM and decreased systolic and diastolic function.<sup>113,195,215</sup> Simultaneously, a correlation between LSM and CVP has been found in several studies.<sup>129,157,195,196</sup> In a large cohort of 129 Fontan patients evaluated by a non-invasive comprehensive hepatic assessment, the authors created the FALD score based on laboratory, hepatic ultrasound, and TE results.<sup>50</sup> The resulting score significantly correlated with impaired Fontan haemodynamics (increased end-diastolic ventricular, arterial pulmonary, and CVP) and showed high diagnostic accuracy in detecting Fontan circulatory failure. Finally, in a case-control study, patients with PLE had increased values of LSM by TE compared to Fontan patients without bowel impairment.<sup>109</sup> These results suggest a possible role of elastography and other non-invasive parameters as valuable biomarkers for predicting non-liver-related clinical outcomes.<sup>50</sup>

### Is spleen stiffness measurement valuable for staging FALD?

A few small studies have been published correlating spleen stiffness measurement (SSM) with liver fibrosis, but no firm conclusions can be made.<sup>206,216–220</sup> One prospective study reported that SSM was higher in children with Fontan circulation than in healthy controls.<sup>221</sup> In a cohort of 50 patients (biopsy was available in 10), MRE-SSM correlated with the histologic degree of liver fibrosis and was related to spleen volume and the presence of oesophageal varices.<sup>206</sup> On the other hand, a retrospective study found SWE-SSM comparable to healthy controls.<sup>222</sup> No studies using the spleen-specific probe of TE are available.

### Should LSM be recommended for FALD surveillance?

#### Recommendations

- Longitudinal assessment of LSM during follow-up could help monitor patients and predict clinical outcomes. Thus, in surveillance programmes for FALD, LSM can be considered and easily performed when available as an adjunct to a liver ultrasound or MR examination (**Very low LoE, weak recommendation**).

The variable results of elastography studies are explained by the complex interplay between LSM, degree of liver fibrosis, Fontan pathway pressure, and risk of Fontan circulatory failure. However, it is essential to highlight that increased LSM measured with elastography in the individual patient may signal the need to further evaluate the Fontan circulation and advanced FALD. Conversely, a reduction in LSM could indicate an improvement in the Fontan circulation in the short term and liver fibrosis in the long term.<sup>88</sup> Consequently, different surveillance strategies have been proposed in children and adults where elastography has been added as a part of liver disease screening or follow-up.<sup>30,143,154,223</sup> MRE is still not widely available but it is recommended if available and when performing MRI during follow-up from adolescence onwards.

## Portal hypertension considerations and management of complications

### What is the risk of oesophageal varices and variceal bleeding in FALD?

The risk of oesophageal or gastric varices in the Fontan population has been poorly evaluated and predominantly assessed at imaging.<sup>83,119,224</sup> Accordingly, the prevalence of varices in adult Fontan patients ranges from 19% to 43%, while it is lower in children (~9%), which suggests that its development is a late complication.<sup>118</sup>

The presence of oesophageal varices at endoscopy deserves special consideration, as they can appear in FALD even in the absence of severe liver fibrosis or cirrhosis. In the context of elevated superior vena cava and pulmonary pressures, venovenous communications and diffuse dilatation of the upper venous plexus can be present. These venous communications can lead to oesophageal varices more likely to be located in the upper oesophagus (also known as “downhill varices”) rather than lower varices reflecting true portal hypertension. Consequently, if upper gastrointestinal endoscopy is performed, a detailed description of varices (size, presence of red wale marks, and location) should be reported.

The incidence of haemorrhage related to portal hypertension following the Fontan operation appears to be lower than in non-cardiac cirrhosis and is a rare cause of death.<sup>60,130,225,226</sup> In a retrospective study, oesophageal varices were documented in 43% and portal hypertensive gastropathy in 39% of adults with Fontan-type surgery, but gastrointestinal bleeding was only observed in 6% of them.<sup>52</sup>

### Is primary and secondary prophylaxis of variceal bleeding indicated in FALD?

#### Recommendations

- Gastro-oesophageal varices in FALD are usually small, and the risk of bleeding is very low. Primary prophylaxis cannot be systematically suggested (**Very low LoE, weak recommendation**).
- Treatment of acute variceal bleeding and secondary prophylaxis can follow the current recommendations for patients with cirrhosis (**Very low LoE, weak recommendation**).

The impact of non-selective beta-blockers (NSBBs) on portal pressure has yet to be addressed in Fontan patients. However, from a pathophysiological point of view, NSBBs could be less effective or ineffective in the FALD model of portal hypertension, characterized by hypodynamic circulation. Alternatively, sedated endoscopic variceal band ligation can be employed as primary or secondary prophylaxis, but the risk of deep sedation should be considered. Thus, considering the low incidence and risk of bleeding in this population, a discussion regarding primary prophylaxis should be had with a cardiologist, considering the risk and benefits of NSBBs and interventional endoscopy, and primary prophylaxis cannot be systematically recommended. Without evidence on FALD, secondary prophylaxis can follow current recommendations for patients with cirrhosis (NSBBs plus variceal band ligation). Still, this treatment should be individualized, as NSBB use or sedation is contraindicated in some Fontan patients.

### Is variceal screening recommended in patients with FALD?

#### Recommendations

- “Downhill oesophageal varices” secondary to diffuse dilatation of the upper venous plexus or systemic-to-pulmonary venous communications and real portal hypertension-derived gastro-oesophageal varices can coexist in FALD. Thus, a detailed description of varices (size, presence of red wale marks, and location) should always be reported (**Low LoE, strong recommendation**).
- The presence of gastro-oesophageal varices is related to worse outcomes in FALD, and screening for gastro-oesophageal varices is suggested for staging purposes (**Low LoE, weak recommendation**).

In the VAST study, comprising a retrospective cohort of 73 Fontan patients, the presence of oesophageal varices, along with other manifestations of portal hypertension, was associated with an increased risk of death, heart transplantation, and HCC.<sup>83,118</sup> Consequently, screening for oesophageal varices may be advisable for staging purposes. Because of the poor association between the severity of FALD and LSM, the Baveno VII recommendation to avoid endoscopy cannot be applied in this population.<sup>155,227</sup> Although varices may be incidentally noted on cross-sectional imaging; endoscopy is the only modality recommended for screening. Some groups propose that upper gastrointestinal endoscopy may be systematically performed after 10 years of Fontan-type surgery and then every 2 years during follow-up and prior to listing in all candidates for heart transplantation.<sup>15</sup> However, based on current evidence, a strong recommendation about the optimal timing of upper endoscopy cannot be made.

### How should variceal haemorrhage be managed in FALD?

#### Recommendations

- TIPS is not indicated in FALD, but it may be considered in highly selected cases of severe uncontrolled variceal bleeding (**Very low LoE, weak recommendation**).

Without specific studies on FALD, acute episodes of variceal haemorrhage should be managed with vasoactive drugs, endoscopic band ligation, and prophylactic antibiotics.<sup>155</sup> The preemptive transjugular intrahepatic portosystemic shunt (TIPS) strategy cannot be recommended in these patients, and there is not enough evidence to suggest TIPS in all cases of recurrent bleeding. The sudden decompression of the splanchnic circulation induces a blood volume shift into the systemic vascular bed, resulting in increased pulmonary preload, which may precipitate cardiac failure in case of poor ventricular function. Hence, TIPS use should be restricted to highly selected cases of severe uncontrolled bleeding when ventricular and valvular functions are estimated to be sufficient to serve increased cardiac output demands.<sup>150,228</sup>

**What is the minimum diagnostic workup indicated in patients with Fontan circulation who develop ascites?**

### Recommendations

- The minimum workup recommended in patients developing ascites shall include performing heart catheterization, addressing stenosis or thrombosis across the Fontan pathway, and excluding PLE (**Low LoE, strong recommendation**).

Ascites is present in 4% to 58% of Fontan patients and may have a multifactorial origin.<sup>80,120,141,170,207,224,229</sup> Diagnostic paracentesis can be recommended in patients with new-onset grade 2 or 3 ascites. To determine the hepatic or cardiac origin, the serum albumin ascites gradient (SAAG) and heart catheterization may be helpful.<sup>154,230</sup> A SAAG >1.1 g/dl indicates that portal hypertension is involved in ascites formation but a SAAG >1.1 g/dl can also be present in heart failure.<sup>231,232</sup> A high ascitic fluid protein concentration (>2.5 g/dl) supports a cardiac origin.<sup>233,234</sup> An ascitic concentration of triglycerides >200 mg/dl suggests chylous ascites. Although serum brain natriuretic peptide >364 pg/ml has a sensitivity of 98% and specificity of 99% in diagnosing cardiac ascites, this cut-off has yet to be specifically evaluated in patients with Fontan circulation who have both cardiac and hepatic impairment.<sup>235</sup> Measuring HVPG has also been proposed for the differential diagnosis. However, the HVPG value is typically within the normal range in FALD and cannot differentiate between ascites of hepatic or cardiac origin. Notably, evaluating new-onset or worsening ascites should address residual stenosis or thrombosis across the Fontan pathway. Finally, ascites can directly result from decreased oncotic pressure due to hypoalbuminemia secondary to PLE.

Thus, in patients with ascites and low serum proteins, PLE should be ruled out, and a determination of alpha-1 anti-trypsin clearance is recommended, even in the absence of diarrhoea.<sup>37</sup>

**How should ascites be managed in patients with Fontan circulation?**

### Recommendations

- The initial treatment of ascites should include optimizing cardiac function, loop diuretics, and anti-aldosterone drugs. In some cases, heart transplantation and other therapies directed towards the aetiologies of ascites may be needed (**Moderate LoE, strong recommendation**).
- TIPS is not indicated in patients with recurrent or refractory ascites, and repeated paracentesis is recommended (**Very low LoE, strong recommendation**).

Given the multifactorial origin of ascites (PLE, lymphatic abnormalities, sinusoidal portal hypertension, Fontan pathway obstructions or Fontan circulatory failure), holistic management is desirable. Generally, ascites is usually manageable by optimizing cardiac function and nutrition, loop diuretics, and anti-aldosterone drugs.<sup>154,236–238</sup> In patients with ascites and Fontan circuit obstruction, a transcatheter treatment (stenting or dilatation) should be performed, even in patients without a measurable pressure gradient.<sup>239</sup> Those cases with Fontan circulatory failure and no pathway obstruction should be evaluated for heart transplantation. In patients with ascites and PLE, some options may be considered: angiotensin-converting enzyme (ACE) inhibitors, pulmonary vasodilators, oral glucocorticoids, heparin therapy, albumin, fresh frozen plasma, and immunoglobulin infusions; transcatheter direct embolization of liver lymphatic channels into the duodenum and interventional thoracic duct decompression; or heart transplantation as a last resort.<sup>240–242</sup>

Although infrequently needed, large-volume paracentesis is the rescue treatment in patients with tense ascites and may even improve systemic haemodynamics.<sup>243</sup> Repeated paracentesis is useful in patients with recurrent ascites. Alfapump ensured a significant reduction of the number of paracentesis procedures required in non-FALD patients with cirrhosis and refractory ascites, but at the expense of a high risk of infection. Anecdotally, intraperitoneal corticosteroid injection has shown some efficacy in patients with recurrent ascites and low SAAG.<sup>244</sup> Given the high risk of heart failure, TIPS is not a good option in Fontan patients with refractory ascites, and no case reports have been published.

### Is hepatic encephalopathy a frequent complication of FALD?

Hepatic encephalopathy is a rare complication of FALD, which can be explained by preserved liver function, even in patients with severe fibrosis. Only a few cases have been described in the literature.<sup>122,148,245</sup> However, the actual incidence and prevalence might be underestimated by the retrospective nature of most series and the frequent presence of other neurological complications in the Fontan population (*i.e.*, anoxic encephalopathy, cardioembolic stroke, and cognitive impairment).<sup>15,246,247</sup> In a retrospective review of 10 patients who received vasoconstrictor therapy for Fontan failure, Miike *et al.* reported hyperammonemia in nine patients and overt hepatic encephalopathy (with severe symptoms of drowsiness and seizures) in five patients. In this study, hepatic encephalopathy strongly predicted mortality.<sup>248</sup>

### Is portal vein thrombosis a frequent complication of FALD?

Despite the high inherent risk of thrombosis and thromboembolism in almost all variants of Fontan circulation, portal vein thrombosis has not obviously been described in the context of FALD, and only one case has been documented.<sup>249–251</sup> Based on the currently available data, there is no evidence to support specific screening or preventive measures for portal vein thrombosis in FALD.

## Liver nodule characterization and hepatocellular carcinoma surveillance and diagnosis in Fontan patients

### Statement

- Nodular hepatocellular lesions of different sizes are common in FALD and are mostly benign (**Low LoE**).

### Recommendations

- Compared with the age-matched population, the incidence of HCC in Fontan patients is increased, and a surveillance programme is recommended (**Low LoE, strong recommendation**).
- HCC surveillance should be initiated 10 years after Fontan-type surgery and strongly considered earlier in case of Fontan circulatory failure (**Low LoE, strong recommendation**).
- Surveillance should be performed by experienced personnel using abdominal ultrasound examination every 6 months. This should be complemented by cross-sectional contrast-enhanced imaging every 1–2 years (**Very low LoE, strong recommendation**).
- Patients developing liver nodules should be referred to centres experienced in managing FALD (**Very low LoE, strong recommendation**).

- Contrast-enhanced cross-sectional imaging (CT and MRI) is preferred over ultrasound examination to characterize liver nodules. The use of hepatobiliary MR contrast agents, if available, may facilitate better characterization (**Low LoE, strong recommendation**).
- The semi-annual determination of alpha-fetoprotein (AFP) can be used for HCC surveillance. Elevated AFP levels ( $\geq 10$  ng/ml) might be considered suspicious of malignancy (**Very low LoE, weak recommendation**).
- A biopsy of all radiologically suspicious nodules  $>1$  cm (see Table 2) is always required for a more definitive diagnosis of a malign or benign lesion. The optimal management of nodules  $<1$  cm showing typical HCC patterns should be discussed in multidisciplinary teams (**Moderate LoE, strong recommendation**).
- Diagnosis of HCC in FALD should be confirmed by pathology (**Low evidence, strong recommendation**).
- Repeated sampling is recommended in cases of inconclusive histological or discordant findings or cases of growth or change in enhancement pattern during follow-up (**Low evidence, strong recommendation**).

### Are liver nodules frequent in Fontan patients?

Liver nodules are frequent in children and adult Fontan patients, and the prevalence varies across studies, ranging from 20–35% in retrospective series to 48% in a large prospective and multicentric cohort.<sup>119,176,178–180,206,252–255</sup> These differences may be due to the diagnostic method employed.<sup>179</sup> Liver nodules may correspond to benign regenerative lesions and malignant neoplasms (*i.e.*, HCC).<sup>139,179,186</sup> The main risk factors for nodule development are elevated systemic pressure and longer duration of Fontan circulation.<sup>179,254,256</sup>

### What are the histological features of liver nodules in FALD?

The most common focal lesions in FALD are benign nodules, and the histological diagnosis relies on the classic morphological features initially described in patients without FALD.<sup>121,257,258</sup> In FALD, typical benign nodules may show overlapping features between large regenerative nodules and focal nodular hyperplasia (FNH) and have been called FNH-like nodules. FNH-like nodules are characterized by the proliferation of normal hepatocytes without a prominent central scar, lobulated by thin fibrous septa with a more or less apparent ductular reaction. These lesions have been linked to a hyperplastic response to impaired hepatic venous outflow, which leads to atrophy and hypoxia-induced damage, followed by a compensatory arterialization of liver parenchyma and regenerative changes.<sup>176,254</sup>

Hepatocellular adenomas are less frequent, and all subtypes may be described theoretically.<sup>121,139,258–260</sup> However, they

**Table 2. Radiological features of liver nodules in FALD.**

Benign nodules	Nodules suspicious of malignancy
<ul style="list-style-type: none"> <li>• Small (&lt;1 cm), well-defined, multiple, and peripheral</li> <li>• CT/MR Hyperenhancing in arterial phase that turn isodense/isointense in the portal venous phase compared to surrounding parenchyma</li> <li>• Homogeneous in attenuation on all MR sequences</li> <li>• Mild MR T1 and T2 iso-/hypo-/hyperintensity</li> <li>• MR iso- to hyperintense compared to the surrounding parenchyma in the late hepatocyte phase</li> <li>• Stable in size during follow-up</li> </ul>	<ul style="list-style-type: none"> <li>• Large (&gt;1 cm) and irregular</li> <li>• CT/MR Hyperenhancing in arterial phase with portal venous or delayed phase washout of contrast</li> <li>• MR High T1 weighted signal intensity with signal drop on T1 opposed phase and hypointense or heterogeneous signal on T2 weighted images</li> <li>• MR hypointensity compared to the surrounding parenchyma in the hepatobiliary phase (using a hepatobiliary MR contrast agent)</li> <li>• Presence of threshold growth during follow-up (50% in less than six months or 100% in more than six months)</li> </ul>

could be underdiagnosed as their radiological and histological appearance may overlap with regenerative nodules. Finally, patients with FALD are prone to develop dysplastic nodules and HCC.<sup>261</sup> Differentiating regenerative, dysplastic, and neoplastic nodules is challenging, and it should be based on a panel of cytological and architectural criteria and additional immunomarkers associated with malignancy.<sup>262</sup>

### What are the radiological features of “typical benign” and “suspicious of malignancy” liver nodules in FALD?

#### “Typical” imaging features of a “benign nodule” in FALD

On ultrasound, benign lesions are usually detected as small (<5 mm), multiple, rounded, and hyper- or isoechogenic nodules located in peripheral areas of the liver.<sup>139,179,180</sup> These characteristics make them difficult to visualize within heterogeneous coarse parenchyma, which explains the low sensitivity of ultrasound for detecting liver nodules compared to cross-sectional imaging.<sup>179,253,263</sup>

On CT and MRI, benign nodules are typically identified in the arterial contrast phase as small, hyperenhancing, and rounded lesions that turn isodense/isointense to the surrounding parenchyma in the portal venous phase.<sup>139,179,252,254</sup> Notably, the finding of washout in the delayed phase can also be seen in benign FNH-like nodules. On MRI, FNH-like nodules are commonly homogeneous in attenuation on all series, with mild T2 iso- to hyperintensity, isointensity to slightly isointensity in the T1 signal, and mild or no restricted diffusion.<sup>186,254</sup> After injection of a hepatocyte-specific contrast agent (*i.e.*, gadoxetic acid), FNH-like nodules are typically iso- to hyperintense compared to the surrounding parenchyma in the late hepatocyte phase.<sup>176,180,186,199,253,255</sup> They generally remain stable in size during follow-up and rarely disappear.<sup>264</sup>

#### “Suspicious of malignancy” imaging features of liver nodules in FALD

Liver nodules above 10 mm diameter, irregular contours, or rapid growth (50% in less than 6 months or 100% in more than 6 months) detected on ultrasound examination should be evaluated with CT or, preferably, with MRI with a hepatocyte-specific contrast agent for better characterization.<sup>154,179,199</sup> The “worrisome features” of a liver nodule on contrast-enhanced CT and MRI are: i) portal venous and delayed phase washout of contrast; ii) capsule appearance (smooth, uniform, sharp, enhancing or non-enhancing border around liver nodule that can represent a true pathological capsule or a pseudocapsule); iii) restricted diffusion; iv) high T1-weighted signal intensity with signal dropout on opposed phase

imaging (suggesting lipid content) and decreased or heterogeneous signal on T2-weighted images; and v) hypointensity compared to the liver parenchyma in the hepatobiliary phase using a hepatobiliary MR contrast agent. However, interpreting these “worrisome features” may be difficult due to the intense congestive changes, even using hepatocyte-specific contrast agents.<sup>199</sup> Similarly, adding diffusion-weighted sequences has not enabled further characterization of nodules.<sup>185</sup> Several studies have demonstrated that LI-RADS (Liver Imaging Reporting and Data System) could overestimate the probability of malignancy in FALD, compared to biopsy, as portal venous and delayed phase washout in contrast-enhanced CT and MRI can also be seen in benign nodules, and cannot be applied in FALD and other vascular liver diseases.<sup>139,179,180,186,199,252,265–268</sup> This could be explained by the delayed liver wash-in and -out in FALD secondary to the inherent congestion. Consequently, all suspicious nodules should undergo biopsy and be evaluated in referral centres.<sup>141,179,265,269</sup> (Table 2). Finally, the optimal management for nodules <1 cm showing typical HCC patterns has yet to be clarified in non-FALD patients. A multidisciplinary board discussion to review such tiny and apparently typical lesions is recommended.

### What are the epidemiological peculiarities of HCC in FALD?

The risk of HCC is increased in patients with Fontan circulation and may appear at younger ages than in other liver diseases.<sup>265,270,271</sup> In a prospective cohort of 103 patients with FALD, the cumulative incidence rates of HCC at 10, 20, and 30 years postoperatively were 0.8, 2.9, and 13.3%, respectively.<sup>272</sup> Similarly, 10 of 339 consecutive Fontan patients had HCC after a median follow-up of 2.9 years (annual incidence of 0.89%).<sup>273</sup> These rates are markedly increased compared to the low annual incidence of HCC in the general European populations aged 25 to 34 years (0.11 to 0.95 per 100,000 people).<sup>274</sup> Of note, these frequencies are based on cohorts of patients treated at the beginning of Fontan-type surgery (*i.e.*, with the initial types of surgery and mostly performed at a later age). Consequently, the impact of changes in surgical techniques and perioperative management on the risk of HCC should be addressed in prospective studies.

Distinctively, 44–50% of HCC cases in FALD are diagnosed in the absence of cirrhosis, which is in contrast to only 20% of patients who develop HCC in the context of non-cirrhotic livers in other aetiologies.<sup>82,139,265,269,270,275,276</sup> Finally, up to 40% of HCC cases in FALD are diagnosed in the advanced stages of the neoplastic disease, which explains the reported poor survival outcomes (12- and 24-month survival rates of 50–60% and 37–40%, respectively).<sup>265,269,273,277</sup>

### Is HCC surveillance justified in FALD?

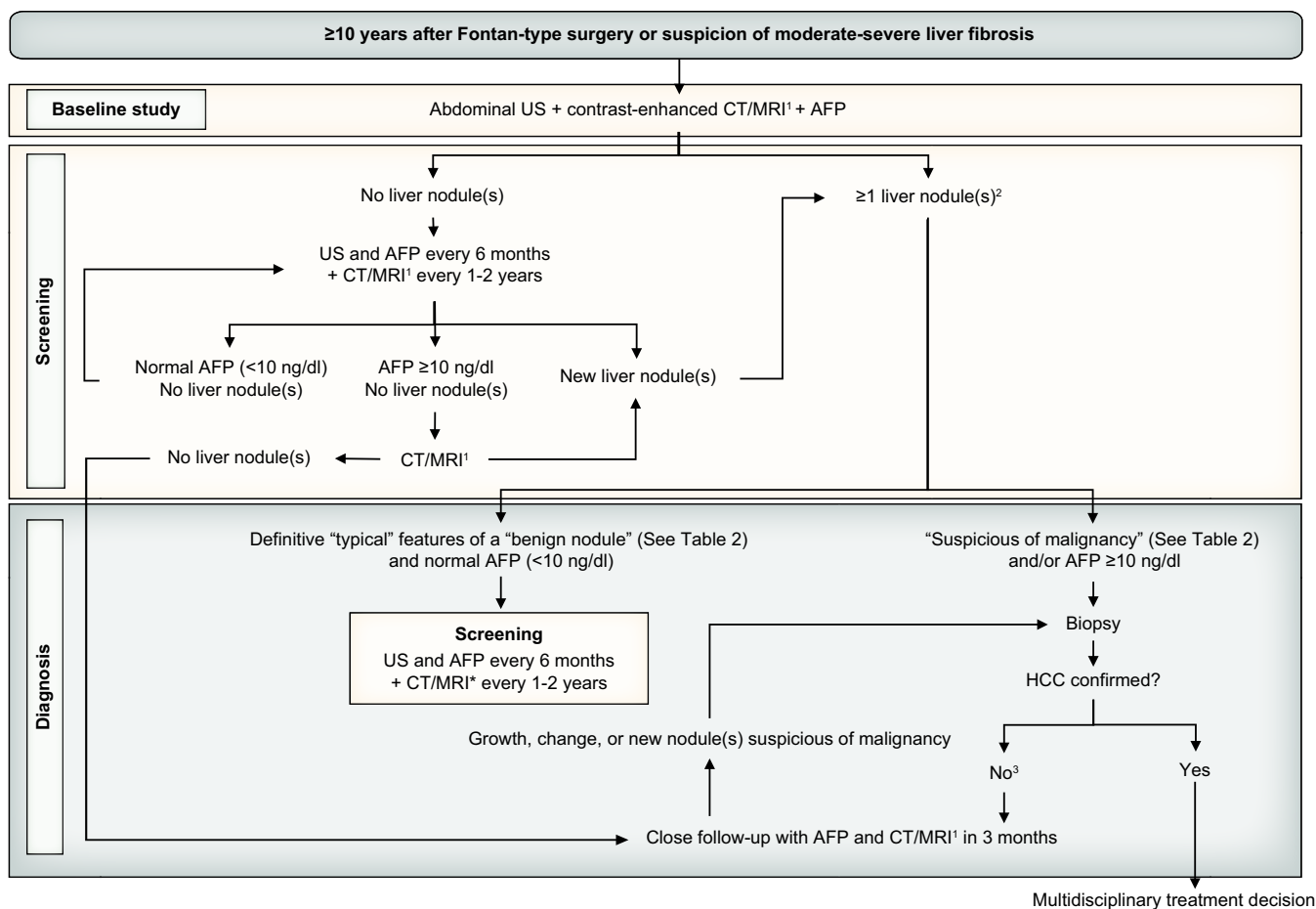
As in other scenarios, in FALD, the diagnosis of HCC in pre-symptomatic stages offers a clear survival benefit (1-year mortality rates of 60% vs. 30% in the symptomatic and asymptomatic phases, respectively).<sup>270,273</sup> The advantage of an early diagnosis could be higher in FALD given the younger age of patients at HCC diagnosis (~30 years in FALD vs. ~70 years in non-FALD liver disease), which implies a more substantial effect on years of life lost.<sup>265</sup> Cost-effectiveness studies addressing surveillance strategies for HCC in patients with non-FALD chronic liver disease indicate that an incidence of 1.5% per year or greater in patients with cirrhosis and at least 0.2% per year in those without cirrhosis would justify HCC surveillance.<sup>278–282</sup> These numbers are similar to those reported in FALD, with a cumulative incidence of 5% during a median follow-up of 3 years (1.3% per year) in the only prospective study focused on HCC diagnosis.<sup>82</sup> Finally, the cumulative HCC incidence in FALD is close to that previously reported in patients with Budd-Chiari syndrome (4% after 5 years of follow-up), where HCC surveillance is highly recommended.<sup>283,284</sup> These data and our expert opinion support the HCC screening recommendation in FALD.

### What is the best surveillance strategy for HCC in FALD?

Even though it is impossible to establish evidence-based guidelines, there is a comprehensive agreement on the need to perform liver imaging follow-up for early detection of possible malignancy.<sup>30,143,154,223,285</sup> Only one study has assessed the benefit of HCC surveillance imaging in FALD. However, the study's retrospective design and the heterogeneous follow-up precluded the authors from recommending specific methods and intervals for surveillance.<sup>3</sup>

In a recent systematic review, HCC was very unlikely within the first 10 years after Fontan-type surgery (only one case of HCC was diagnosed before this time point), with an exponential increase in risk over time.<sup>265,273</sup> Other suggested predictive factors of new-onset HCC are higher body mass index, worse NYHA functional class, poorer results on serological biomarkers of liver fibrosis (FIB-4 and APRI score), early Fontan circulatory failure, MELD-XI scores  $\geq 19$ , and high levels of serum AFP.<sup>116,130,265,273,286</sup>

The rate of tumour growth should dictate the ideal surveillance interval up to the limit of its detectability. The mean HCC volume doubling time has yet to be addressed in FALD, but extrapolating the knowledge from HCC in other aetiologies, a



**Fig. 3.** Flow diagram for evaluation of liver nodules and HCC surveillance and diagnosis in FALD. (1) Multiphasic contrast-enhanced CT/multiphasic contrast-enhanced MRI, or (preferable) gadoxetic-enhanced MRI; (2) The optimal management for nodules <1 cm showing typical HCC patterns has yet to be clarified, and a multidisciplinary board discussion is recommended; (3) Consider re-biopsy. AFP, alpha-fetoprotein; FALD, Fontan-associated liver disease; HCC, hepatocellular carcinoma; US, ultrasound.



6-month interval seems a reasonable choice.<sup>287–289</sup> A longer interval of 12 months is probably more cost-effective, but would result in fewer early-stage diagnoses.<sup>290</sup>

Based on the current evidence and our expert opinion, active HCC surveillance might be initiated at least 10 years after completion of the Fontan procedure and strongly considered earlier in case of Fontan circulatory failure, even in the absence of cirrhosis. As detailed before, the sensitivity of liver ultrasound for diagnosing liver nodules in FALD is low, and contrast-enhanced modalities may be more suitable for this population to identify the full spectrum of nodules. In a prospective and multicentre cohort comparing ultrasound to MRI/CT, 2/8 patients with suspected malignant nodules were not identified by ultrasound, though none of these nodules were finally HCC at biopsy.<sup>179</sup> On the other hand, in a systematic review, HCC nodules were visible on ultrasound in 9 of 10 patients with reported findings.<sup>259</sup> Consequently, ultrasound could be useful as an HCC screening tool and has important advantages, such as low costs and low side effect rates.

A practical option could be to combine serial ultrasound (every 6 months) by experienced personnel with contrast-enhanced imaging at baseline (10 years after surgery) and periodically during follow-up to identify the whole spectrum of liver nodules. MRI is generally preferred over CT as hepatobiliary contrast agents offer some advantages in diagnostic accuracy and it is non-irradiating. However, a significant drawback is that MRI is contraindicated in many Fontan patients with old cardiac devices.<sup>291</sup> Although we lack robust evidence, performing an MRI at least every 1–2 years could be a practical and reasonable approach (see algorithm in Fig. 3). Importantly, this expert opinion-based recommendation is founded on HCC incidences from patients treated with Fontan-type surgeries decades ago. The surgical and perioperative improvements may decrease the HCC risk in the future, and this recommendation could be modified.

### Is AFP determination useful for screening proposes?

Serum AFP is a valuable complementary biomarker for diagnosing HCC in FALD, as it is above the standard upper limit in 74–80% of patients diagnosed with HCC.<sup>265,269</sup> These rates are not equal in non-FALD aetiologies, with a very small proportion of patients (10–20%) presenting abnormal AFP levels at diagnosis of HCC.<sup>292</sup> In contrast, in a large prospective series with a high prevalence of non-neoplastic nodules (48%), no patient with Fontan-type surgery without HCC showed elevated AFP (defined as >7 ng/dl).<sup>179</sup> This is not the rule in viral or alcohol-related chronic liver diseases, where fluctuating levels of AFP might reflect flares or inflammatory-mediated exacerbations of underlying disease.<sup>293</sup> Results from a large cohort of stable Fontan patients identified that the likelihood of HCC was 26 times higher in patients with AFP levels  $\geq 10$  ng/dl. Interestingly, patients who did not develop HCC had a substantially lower value of AFP (median: 2.9 ng/dl), which supports its role in predicting new-onset HCC in this population.<sup>273</sup> Consequently,

elevated AFP levels in patients with FALD should always prompt suspicion of HCC.

## Management of hepatocellular carcinoma in Fontan patients

### Recommendations

- The management of HCC in FALD should follow current clinical practice guidelines in HCC and should be discussed in multidisciplinary teams in centres that are highly experienced in FALD (**Very low LoE, strong recommendation**).
- Local ablation (radiofrequency or microwave) should be considered the first-line therapy for solitary HCC  $\leq 2$  cm over surgery. Beyond this size, solitary HCC can be treated with surgical resection, especially in patients with preserved liver and cardiac function. Although local ablation in HCC >2 cm may be less effective, it can be employed alone or combined with transarterial therapies in selected patients with high surgical risk (**Very low LoE, strong recommendation**).
- Transarterial therapies are indicated in patients with unresectable HCC who are not candidates for local ablation. As portosystemic, extrahepatic, and right-to-left cardiac shunts are frequent in FALD, the risk of adverse events with these treatments may be considered (**Very low LoE, weak recommendation**).
- Systemic therapy is indicated in patients with preserved liver function, good performance status, and advanced or metastatic tumours. It can be employed in progressing tumours or those which are unsuitable for loco-regional therapies. A careful evaluation of cardiac function is suggested before using potentially cardiotoxic drugs (**Very low LoE, weak recommendation**).
- Although liver transplantation has been considered the first-line option for HCC within Milan criteria unsuitable for resection or local curative treatment, no specific recommendations can be made in FALD. The indication of liver transplantation should be made on a case-by-case basis in highly experienced centres (**Very low LoE, strong recommendation**).

### What are the specific considerations for HCC treatment in FALD?

Treatment modalities used in Fontan patients with HCC have been very heterogeneous. In a systematic review, treatment was reported in 62 out of 65 patients, and transarterial chemoembolization (TACE) was the most common therapy (28.6%), followed by surgical resection (19%). Best supportive care alone was offered in up to 20% of cases, highlighting the high rate of

late HCC diagnosis in Fontan patients.<sup>265</sup> In general, the management of HCC in FALD should follow current clinical practice guidelines updated in 2022.<sup>278,294</sup> However, Fontan patients have unique anatomical and functional abnormalities that should be considered when tailoring treatment. This document mainly focuses on these specific considerations.

**Surgical resection:** The rate of surgical complications and long-term survival of Fontan patients treated with tumour resection is unknown, but the significant risk of cardiac comorbidity may burden results. In general, liver resection can be performed by open surgery (laparotomy) or minimally invasive operations (laparoscopic). Open abdominal surgeries are associated with a high risk of bleeding and cardiac decompensation in the Fontan population.<sup>295</sup> The laparoscopic approach appears safer, with fewer postoperative complications and a potentially non-significant impact on liver function. Still, pneumoperitoneum can modify abdominal and intrathoracic pressures, hindering cardiac preload during surgery.<sup>296</sup> The choice between open or laparoscopic surgery depends on the tumour size, the number of satellite lesions, the location, and the surgical team's preference or expertise.<sup>297</sup> As the risk of massive bleeding secondary to high CVP is the major concern in this population, extraordinary surgical maneuvers (Pringle maneuver, reverse Trendelenburg position, veno-venous bypassing, or inflow plus outflow ligation) could be needed.<sup>297–301</sup> Thus, specialized anaesthesia and perioperative management, including cardiac and nutritional optimization, is crucial in this fragile population. The anaesthetic goal is the preservation of an adequate CVP, avoiding systemic hypotension, and ensuring proper flow through the pulmonary circulation.<sup>297</sup> A central venous catheter and trans-oesophageal echocardiogram should continuously monitor CVP and cardiac contractility. Consequently, these hepatic surgeries should be performed in highly specialized centres.

**Local ablation:** Local ablation (mainly radiofrequency or microwave) should be considered the standard of care for Fontan patients with HCC  $\leq 2$  cm, given the presumably lower risk of complications and it conferring the same survival benefit as surgical resection in other hepatopathies.<sup>302</sup> Although local ablation beyond this size is less effective, it can be employed alone or combined with transarterial therapies in selected patients in whom surgery is not appropriate. Importantly, the frequent use of pacemakers and other cardiac devices in Fontan patients may limit the applicability of radiofrequency. Ethanol injection, laser ablation, or cryoablation could be suitable options in those cases where thermal ablation is not technically possible, but there is no reported data in FALD.

**Transarterial therapies:** Although TACE has been the most common therapy employed in Fontan patients, as a unique treatment or a bridge to transplant, evidence regarding its effectiveness and safety is scarce.<sup>270,273,303,304</sup> Classically, patients with bilirubin  $>2$ -3 mg/dl or slight fluid retention requiring diuretics are considered at high risk of adverse events and suboptimal survival after TACE. These considerations may not be accurate in Fontan patients, as slight bilirubin elevations are persistent and do not always reflect liver impairment, and mild ascites could be due to other non-liver-related complications. Notably, portosystemic, extrahepatic and right-to-left cardiac shunts are frequent in this population and may increase the risk of adverse events of TACE, as shown by the reported cases of unexpected retinal artery embolism,<sup>305</sup>

depositions of radiopaque substance in the brain,<sup>306</sup> and development of posterior reversible leukoencephalopathy following TACE (personal data). Transarterial radioembolization using yttrium-90 microspheres has been employed in Fontan patients with HCC, with results comparable to TACE in unresectable tumours.<sup>232</sup> One of the advantages of transarterial radioembolization is that it can be used in patients with compromised portal inflow.

**External radiation therapy:** The role of external radiation therapy has been scarcely evaluated in Fontan patients.<sup>270,307</sup> The current evidence of external radiotherapy in HCC without FALD is also controversial, and most series have focused on its combination with local treatments (*i.e.*, TACE). There are only five case reports of patients with Fontan circulation who have been satisfactorily treated with proton beam therapy without side effects or recurrence.<sup>277,308</sup>

**Systemic therapy:** As a unique or combined treatment, systemic therapy has been documented in 11 Fontan patients with unresectable HCC. Recently, the increasing number of systemic therapies with demonstrated evidence of efficacy in HCC has changed the landscape of cancer management. According to current clinical practice guidelines, three different treatments can be used as first-line: i) tyrosine-kinase inhibitors (sorafenib and lenvatinib); ii) the combination of antiangiogenic drugs and immunotherapy (atezolizumab-bevacizumab); and iii) combinations of different immunotherapies (tremelimumab-durvalumab).<sup>294,309</sup> Unfortunately, the evidence for using these agents in Fontan patients is minimal and mainly restricted to sorafenib, due to the relatively short period of time that the aforementioned combinations have been clinically available compared to long-term experience with sorafenib. The safety of systemic therapy in this scenario has not been established, but we should be aware of potential cardiotoxicity, particularly with tyrosine-kinase inhibitors. Lately, several case reports have suggested using cisplatin-based regimens though the results in FALD have been poor. Cisplatin-based regimens are not recommended in EASL current guidelines; thus, we recommend against their use in FALD.<sup>270,310,311</sup>

**Liver and combined heart-liver transplantation:** Although liver transplantation is the first-line option for HCC within Milan criteria (three nodules, each  $<3$  cm in size) and unsuitable for resection/ablation, the major limitation in the Fontan population is the reasonable doubt about if isolated liver transplantation is safe and valuable. Only one successful case of living-donor isolated liver transplantation and no cases of combined heart-liver transplantation have been reported in patients with FALD and HCC.<sup>312</sup> If these patients should be evaluated for combined heart-liver transplantation is a matter of debate since current policies in most centres contemplate the presence of solid malignancy within the past 5 years as an absolute contraindication for heart transplantation.<sup>313</sup> Until more evidence is available, we cannot make any recommendations.

**Palliative and best supportive care:** Patients with terminal HCC with a life expectancy of less than 3-4 months should receive palliative care focused on pain, nutrition, and psychological support.<sup>278</sup> The clinical picture of Fontan patients with terminal HCC is particularly complex, resulting from symptoms deriving from their liver and cardiac disease, along with the effect of tumour bulk. Palliative care in Fontan patients is an unmet need that reference centres should urgently address to

include practitioners specialized in supporting this young, frail, and unfortunate population.

In summary, while current general recommendations on HCC are based on robust scientific evidence, the particular features of Fontan patients highlight the complexity of management at the individual level and the need to personalize decisions at the tumour board level based on stage of liver disease, cardiac function, and performance status. Multiparametric evaluation should be integrated into highly proficient multidisciplinary boards where hepatologists, oncologists, cardiologists, anaesthesiologists, interventional radiologists, nurses, and nutritional experts are actively involved.

## Other liver-related issues

### Recommendations

- All Fontan patients should be screened for HCV and HBV infection. Vaccination against HBV and HAV is universally recommended (**Moderate LoE, strong recommendation**).
- Sarcopenia and malnutrition should be identified early and treated in patients with Fontan circulatory failure and/or advanced FALD (**Low LoE, strong recommendation**).
- In patients with advanced FALD and an established indication, antithrombotic treatment should not be discouraged (**Very low LoE, strong recommendation**).

### Which other measures can be implemented for liver care in Fontan patients?

Patients who had cardiac surgery in childhood before the implementation of blood donor screening have a five-fold increased prevalence of HCV infection compared with the age-matched general population.<sup>314,315</sup> Therefore, all Fontan patients should be screened for HCV and HBV infection. Vaccinations against HAV and HBV and follow-up serologies to confirm the presence (and maintenance) of protective antibodies are recommended. Revaccination is advised if a protective antibody response is absent.<sup>88,150,204</sup>

A co-existing liver disorder should be excluded and treated, including metabolic, viral, and autoimmune diseases. Patients should be counseled on lifestyle measures to prevent obesity, promote regular physical activity and a healthy diet, and avoid alcohol and drug use. Weight control is particularly relevant as weight gain in adulthood is associated with a higher risk of developing HCC in FALD.<sup>14,273,316</sup> On the other side, sarcopenia and malnutrition are ominous landmarks in patients with Fontan circulatory failure and advanced liver disease.<sup>317–319</sup> Thus, their early identification and treatment should be a priority.

### Can antithrombotic therapy be used in patients with advanced FALD?

Thrombosis is a significant complication after Fontan-type surgery, associated with an increased risk of advanced FALD and death.<sup>100,320</sup> Many authors support that anticoagulation is indicated in the presence or history of atrial thrombus, atrial arrhythmias, previous thromboembolic events, or with a patent fenestration.<sup>321,322</sup> However, the use of anticoagulants in

patients with advanced FALD is a matter of debate. Recent data suggest a protective effect of warfarin on FALD, reducing the risk of HCC.<sup>272</sup> Moreover, in an animal model of FALD, fibrosis regression was observed after warfarin administration.<sup>90</sup> Consequently, we can conclude that advanced FALD is not a contraindication for anticoagulation, and its potential beneficial clinical effects need to be examined in the future.

Aspirin is an alternative to anticoagulation in Fontan patients.<sup>323</sup> Although recent evidence supports that regular use of aspirin reduces the risk of HCC, liver-related complications, and death in chronic liver disease, we lack specific studies on FALD.<sup>324</sup> Hence, we cannot systematically recommend aspirin use in FALD, but it should not be discouraged in patients with an established indication.

Despite the extensive use of direct oral anticoagulants (DOACs) in patients at risk of thrombotic complications, experience in adult Fontan patients is limited.<sup>325</sup> Indeed, there is a recommendation from the American Heart Association against using DOACs in this population due to the scarce safety and efficacy data, along with concerns regarding abnormal coagulation secondary to FALD.<sup>326,327</sup> While not well studied in Fontan patients specifically, based on the pharmacokinetic and pharmacodynamic properties and safety profile of DOACs in patients with chronic liver diseases, DOACs may be employed in patients with FALD with preserved liver function.<sup>328</sup> DOAC treatment in children is still evolving, and no recommendations can be made for this population.

### Are angiotensin-converting enzyme inhibitors indicated to ameliorate FALD progression?

ACE inhibitors are often indicated for ventricular systolic or diastolic dysfunction, atrioventricular valve regurgitation, preservation of normal ventricular function, and arterial hypertension in Fontan patients.<sup>329,330</sup> Theoretically, they may downregulate angiotensin II receptors on activating hepatic stellate cells, which are responsible for cell proliferation, contraction, and collagen secretion.<sup>331–335</sup> However, this antifibrotic effect has not been evaluated in FALD. In addition, a recent prospective study showed no improvement in exercise capacity or ventricular function after short-term ACE inhibition in paediatric Fontan patients with moderate-good systolic function.<sup>336</sup> Thus, there is no evidence to recommend the systematic use of ACE inhibitors as a specific therapy for FALD.

### Should pulmonary vasodilators be routinely indicated in advanced FALD to ameliorate liver damage?

Pulmonary vasodilators improve systemic venous return and exercise capacity in Fontan patients.<sup>337–341</sup> Whether this improvement may diminish liver congestion is debatable. A retrospective cross-sectional study found a correlation between the severity of FALD and pulmonary artery and ventricular end-diastolic pressures. In contrast, the transpulmonary gradient did not increase significantly in patients with advanced FALD, suggesting a minor role of increased pulmonary resistance in FALD progression.<sup>113</sup> Therefore, pulmonary vasodilators cannot be routinely recommended to decrease liver damage and should only be considered if pulmonary vascular resistance is increased.<sup>342–344</sup>

## Heart and heart-liver transplantation in FALD

### Recommendations

- Advanced FALD *per se* cannot be considered as an indication for heart transplantation, but FALD progression might indicate haemodynamic deterioration and, subsequently, the need for heart transplantation (**Low LoE, weak recommendation**).
- In patients with an indication for heart transplantation (Fontan circulatory failure, severe ventricular dysfunction or refractory PLE or PB) and compensated advanced FALD with preserved liver function, liver transplantation cannot be systematically recommended. These patients should be evaluated for isolated heart transplantation (**Low LoE, strong recommendation**).
- Liver transplantation alone is not generally recommended in Fontan patients. Fontan patients with an indication for liver transplantation due to liver insufficiency or HCC should be evaluated for combined heart-liver transplantation (**Low LoE, strong recommendation**).
- Although hepatic fibrosis regression and resolution of liver-related clinical complications are possible after isolated heart transplantation in patients with advanced FALD, post-transplant liver surveillance may be maintained (**Low LoE, weak recommendation**).

### What are the current indications for heart transplantation in Fontan patients?

Heart transplantation is the only definitive curative treatment option for patients with Fontan circulatory failure.<sup>345</sup> However, the decision to transplant is frequently empirical. Among paediatric patients, ventricular systolic dysfunction is the most common indication for heart transplantation.<sup>346–348</sup> However, this primary indication is less frequent in adulthood, and most patients referred for transplant have circulatory failure but preserved ventricular function.<sup>146,349</sup> Mechanical problems of Fontan circulation can usually be surgically or interventionally solved, and pathway obstruction is rarely the only reason for cardiac transplantation.<sup>350</sup> PLE refractory to medical and interventional treatment is another classical indication for heart transplantation, present in 36% of transplanted patients.<sup>351</sup> Due to the promising results of lymphatic interventions, PB has become a rarer indication, reported in only 7% of waitlisted patients in the contemporary era, compared to 15% in the past.<sup>352</sup>

### Is advanced FALD an indication *per se* for heart transplantation?

There is no evidence that advanced FALD *per se* is an indication for cardiac transplantation. However, as monitoring of FALD is mandatory in all Fontan patients, detection of liver damage progression might indicate haemodynamic deterioration and, subsequently, the need for cardiac

transplantation. Therefore, a detailed haemodynamic assessment, including echocardiography, cardiac catheterization, and MRI, should be performed when FALD progression is observed. As heart transplant alone in the setting of advanced FALD can lead to a reduction in FALD progression, with an improvement of liver-related signs and symptoms, early consideration for heart transplant alone should be given to avoid combined heart-liver transplantation in the setting of an overall shortage of donor organs.<sup>353</sup>

### When should combined heart-liver transplantation be considered?

Liver transplantation alone is not generally recommended in Fontan patients due to the challenging management of systemic pressures during the anhepatic and reperfusion stages of surgery.<sup>14</sup> Currently, guidelines concerning the indication and timing of combined cardiac and liver transplantation in Fontan patients are missing.<sup>354</sup> It is well-known that multi-organ dysfunction is associated with poor outcomes after heart transplantation. Particularly, some studies have determined that MELD-XI, which evaluates kidney and liver function, is a good predictor of early and late mortality after heart transplantation in Fontan patients.<sup>146,355–359</sup> Combined with the protective effect of combined liver-heart transplantation on cellular rejection, these findings have led some authors to consider combined transplantation in patients with Fontan circulatory failure and severe liver fibrosis (grade 3 or 4), with favourable results.<sup>360–363</sup> However, other studies have shown no differences in survival between cirrhotic and non-cirrhotic Fontan patients who undergo heart transplantation,

### Box 1. Unmet needs in FALD research and future directions.

- Impact of FALD on global and heart transplant-free survival of Fontan patients.
- Impact of improvements in the surgical and perioperative management of patients with a univentricular heart on FALD progression and HCC risk.
- Role of FALD surveillance programmes based on liver biopsy and on non-invasive methods.
- Role of lymphography in diagnosing and staging FALD.
- Evaluation of different cut-offs of elastography for ruling in and ruling out severe fibrosis.
- Role of elastography in predicting strong clinical outcomes (risk of liver decompensation, unfavourable cardiac outcomes, need for transplantation, and death).
- Role of spleen elastography in FALD.
- A better understanding of hepatic haemodynamics. Evaluation of the significance of absolute values of hepatic free and wedged pressures.
- Potential beneficial clinical effects of anticoagulation in advanced FALD.
- Sensitivity and specificity of ultrasound for detection of HCC.
- Prospective validation of HCC surveillance algorithms and implementation of screening programmes to identify at-risk candidate populations.
- Effectiveness and safety of treatment options for HCC in FALD.
- Palliative care focused on the unique characteristics of Fontan patients.

FALD, Fontan-associated liver disease; HCC, hepatocellular carcinoma.

concluding that severe fibrosis, while cirrhosis is compensated, should not be a contraindication for isolated heart transplantation.<sup>364–366</sup> Additionally, a remarkable hepatic remodeling may follow cardiac transplantation in advanced FALD.<sup>367</sup> Consequently, there is no evidence to systematically indicate combined transplantation in all failing Fontan patients with compensated severe liver fibrosis. This option should probably be reserved for those cases with liver insufficiency, which is very rare in FALD, or severe liver-related complications.<sup>149</sup> Nonetheless, each transplant programme should determine its specific thresholds based on institutional experience, preferences, and recent transplant outcomes.<sup>353</sup>

### Should liver surveillance be maintained after heart transplantation in Fontan patients?

The effect of isolated heart transplantation on the course of FALD post-transplantation is not well understood and is probably heterogeneous.<sup>368,369</sup> A small case series, including mostly patients with histologically proven cirrhosis, has demonstrated no progression of FALD, resolution of ascites, and freedom from HCC in the mid-term after heart transplantation.<sup>353</sup> A sequential strategy of liver transplantation following heart transplantation may be an option in case of liver disease progression. However, only a few cases of patients with congenital cardiac disease have been documented, with a high mortality rate on the waiting list, and further studies in FALD are needed.<sup>363,370</sup> The small number of patients included and the short follow-up preclude us from recommending stopping liver monitoring after heart transplantation. We suggest that long-term liver surveillance is mandatory.

## Role of specialized units in FALD

### Recommendations

- The FALD surveillance programme should be considered one of the most critical parts of lifelong specialized care, and a multidisciplinary approach is mandatory (**Low LoE, strong recommendation**).
- A FALD surveillance programme should be recommended to detect liver disease progression at a stage early enough to consider interventions to optimize Fontan circulation and prevent advanced liver fibrosis (**Low LoE, strong recommendation**).

- A FALD surveillance programme for FALD may include an initial screening at baseline (before Fontan-type surgery), followed by a 2-3 yearly screening in children and adolescents consisting of clinical assessment by expert hepatologists, biochemical evaluation, and liver Doppler ultrasound (with or without LSM) (**Very low evidence, weak recommendation**).

### How should Fontan patients with FALD be managed in multidisciplinary units?

All Fontan patients require lifelong specialized multidisciplinary care in a tertiary centre.<sup>30</sup> Beyond comprehensive cardiologic follow-up by specialists in congenital heart disease, several specialties might be needed during long-term follow-up: cardiac surgery, hepatology, gastroenterology, nephrology, radiology, pathology, psychology, endocrinology, specialized nursery, and social workers, among others. Optimizing haemodynamics is the central therapeutic principle in managing Fontan patients.<sup>69</sup> Then, cardiologic examinations will generally account for the greatest share of follow-up diagnostics, especially in younger Fontan patients.<sup>371,372</sup> The ultimate aim of surveillance is to detect FALD progression at a sufficiently early stage to consider interventions to optimize the Fontan circulation in due time and to prevent advanced fibrosis.<sup>95</sup> Therefore, installing a minimally invasive FALD screening protocol in children and adolescents seems advisable to facilitate the early detection of advanced FALD and eventually initiate treatment optimization.<sup>181,207</sup> A consensus on assessment content, timing, and frequency has to be established. However, there is growing evidence that an initial screening at baseline (before Fontan creation) followed by 2-3 yearly FALD screening in children and adolescents consisting of clinical examination, biochemical evaluation, and liver Doppler ultrasound (with or without liver stiffness assessment) might be beneficial and allow for early FALD detection in the individual patient.<sup>204,207,372,373</sup>

## Unmet needs and future directions

### What are the research priorities in FALD?

FALD is an emerging liver disease that represents a significant clinical challenge. The characteristics of the Fontan population make this unique entity different. The need for robust evidence in management has been the most significant barrier to implementing the current evidence-based position paper. Multi-institutional collaborative registries and prospective studies are imperative. However, as in most orphan diseases, the lack of funding sources for research represents a clear drawback for augmenting knowledge in FALD. The panel suggests that increasing public funds for research in FALD should be a priority. **Box 1** summarizes the study's goals for the future.

### Affiliations

<sup>1</sup>Gastroenterology and Hepatology Department, Hospital Universitario Ramón y Cajal, Madrid, Spain; <sup>2</sup>Instituto Ramón y Cajal de Investigación Sanitaria (IRYCIS), CIBEREHD (Centro de Investigación Biomédica en Red Enfermedades Hepáticas y Digestivas), University of Alcalá, Madrid, Spain; <sup>3</sup>DHU Unity, Pôle des Maladies de l'Appareil Digestif, Service d'Hépatologie, Hôpital Beaujon, AP-HP, Clichy, France; <sup>4</sup>Université Denis Diderot-Paris 7, Sorbonne Paris Cité, Paris, France; <sup>5</sup>Department of Gastroenterology and Hepatology, Radboud University Medical Center, Nijmegen, The Netherlands; <sup>6</sup>Pediatric Cardiology Department, Hospital Universitario Ramón y Cajal, Madrid, Spain; <sup>7</sup>Instituto Ramón y Cajal de Investigación Sanitaria (IRYCIS), University of Alcalá, Madrid, Spain; <sup>8</sup>Department of Pediatrics, Section of Pediatric Cardiology, Rigshospitalet, Copenhagen, Denmark; <sup>9</sup>Department of Congenital Heart Disease/Pediatric Cardiology, Deutsches Herzzentrum Berlin, Berlin, Germany;

<sup>10</sup>Department of Pediatric Gastroenterology, Hepatology and Nutrition, Ghent University Hospital, Belgium; <sup>11</sup>Department of Pediatrics, Beatrix Children's Hospital / University Medical Center Groningen, The Netherlands; <sup>12</sup>Adult Congenital and Paediatric Heart Unit, Freeman Hospital, Newcastle Upon Tyne Hospitals NHS Foundation Trust, Newcastle Upon Tyne, UK; <sup>13</sup>Department of Pediatric Radiology, Queen Silvia Children's Hospital, Sahlgrenska University Hospital, Behandlingsvagen 7, 41650 Göteborg, Sweden; <sup>14</sup>Pathology of Cardiac Transplantation and Regenerative Medicine Unit, Department of Cardiac, Thoracic and Vascular Sciences and Public Health, University of Padua, Padua, Italy; <sup>15</sup>Centre de recherche sur l'inflammation, INSERM1149, Université Paris Cité, Paris, France; <sup>16</sup>Pathology Department, Beaujon Hospital, APHP.Nord, Clichy, France; <sup>17</sup>AP-HP, Service d'Hépatologie, Hôpital Beaujon, DMU DIGEST, Centre de Référence des Maladies Vasculaires du Foie, FILFOIE, Clichy, France; <sup>18</sup>Université Paris-Cité, Inserm, Centre de recherche sur l'inflammation, UMR 1149, Paris, France; <sup>19</sup>Barcelona Hepatic Hemodynamic Laboratory, Liver Unit, Hospital Clínic, Institut de Investigacions Biomèdiques August Pi i Sunyer (IDIBAPS), Departament de Medicina i Ciències de la Salut, University of Barcelona, Barcelona, Spain; <sup>20</sup>CIBEREHD (Centro de Investigación Biomédica en Red Enfermedades Hepáticas y Digestivas), Health Care Provider of the European Reference Network on Rare Liver Disorders (ERN-Liver), Spain

## Abbreviations

ACE, angiotensin-converting enzyme; AFP, alpha-fetoprotein; APRI, aspartate aminotransferase-to-platelet ratio index; CVP, central venous pressure; DOACs, direct oral anticoagulants; EASL, European Association for the Study of the Liver; ERN RARE-LIVER, European Reference Network on Rare Liver Diseases; FALD, Fontan-associated liver disease; FNH, focal nodular hyperplasia; HCC, hepatocellular carcinoma; HVPG, hepatic venous pressure gradient; INR, international normalized ratio; LoE, level of evidence; LSM, liver stiffness measurement; MELD, model for end-stage liver disease; MELD-XI, MELD excluding the international normalized ratio; MRE, magnetic resonance elastography; NSBBs, non-selective beta-blockers; NYHA, New York Heart Association; PB, plastic bronchitis; PLE, protein-losing enteropathy; SAAG, serum albumin ascites gradient; SSM, spleen stiffness measurement; TACE, transarterial chemoembolization; TE, transient elastography; TIPS, transjugular intrahepatic portosystemic shunt.

## Conflict of interest

Please refer to the accompanying ICMJE disclosure forms for further details.

## Authors' contributions

Hepatology: Luis Téllez, Audrey Payancé, Eric Tjwa, Pierre Emmanuel Rautou (EASL representative), Juan Carlos García Pagán (ERN RARE-LIVER representative and chair). Cardiology: María Jesús del Cerro, Lars Idorn, Stanislav Ovroutski. Paediatric Hepatology: Ruth De Bruyne. Cardiac Surgery: Fabrizio De Rita. Radiology: Charlotte de Lange. Pathology: Annalisa Angelini.

## Disclaimer

This position document reflects the current state of knowledge at the time of publication, and clinical consensus judgments when knowledge is lacking. The expected changes in the state of scientific information mandate that periodic review and updating will be needed. The recommendations included in this document do not apply to all patients, and each must be adapted and tailored to each individual patient.

## Supplementary data

Supplementary data to this article can be found online at <https://doi.org/10.1016/j.jhep.2023.07.013>.

## References

- [1] Clift P, Celermajer D. Managing adult Fontan patients: where do we stand? *Eur Respir Rev* 2016 Dec;25(142):438–450. <https://doi.org/10.1183/16000617.0091-2016>. PMID: 27903666; PMCID: PMC9487559.
- [2] Moodie DS, Ritter DG, Tajik AH, McGoon DC, Danielson GK, O'Fallon WM. Long-term follow-up after palliative operation for univentricular heart. *Am J Cardiol* 1984 Jun 1;53(11):1648–1651. [https://doi.org/10.1016/0002-9149\(84\)90595-2](https://doi.org/10.1016/0002-9149(84)90595-2). PMID: 6203396.
- [3] Lee MG, Brizard CP, Galati JC, Iyengar AJ, Rakhra SS, Konstantinov IE, et al. Outcomes of patients born with single-ventricle physiology and aortic arch obstruction: the 26-year Melbourne experience. *J Thorac Cardiovasc Surg* 2014 Jul;148(1):194–201. <https://doi.org/10.1016/j.jtcvs.2013.07.076>. Epub 2013 Sep 24. PMID: 24075567.
- [4] Fontan F, Baudet E. Surgical repair of tricuspid atresia. *Thorax* 1971 May;26(3):240–248. <https://doi.org/10.1136/thx.26.3.240>. PMID: 5089489; PMCID: PMC1019078.
- [5] d'Udekem Y, Iyengar AJ, Galati JC, Forsdick V, Weintraub RG, Wheaton GR, et al. Redefining expectations of long-term survival after the Fontan procedure: twenty-five years of follow-up from the entire population of Australia and New Zealand. *Circulation* 2014 Sep 9;130(11 Suppl 1):S32–S38. <https://doi.org/10.1161/CIRCULATIONAHA.113.007764>. PMID: 25200053.
- [6] Konstantinov IE, Alexi-Meskishvili VV. Cavo-pulmonary shunt: from the first experiments to clinical practice. *Ann Thorac Surg* 1999 Sep;68(3):1100–1106. [https://doi.org/10.1016/s0003-4975\(99\)00877-2](https://doi.org/10.1016/s0003-4975(99)00877-2). PMID: 10510029.
- [7] Glenn WW. A temporary bidirectional superior vena cava-pulmonary artery shunt. *J Thorac Cardiovasc Surg* 1997 Dec;114(6):1123–1125. [https://doi.org/10.1016/S0022-5223\(97\)70032-1](https://doi.org/10.1016/S0022-5223(97)70032-1). PMID: 9434711.
- [8] de Leval MR, Kilner P, Gewillig M, Bull C. Total cavopulmonary connection: a logical alternative to atriopulmonary connection for complex Fontan operations. Experimental studies and early clinical experience. *J Thorac Cardiovasc Surg* 1988 Nov;96(5):682–695. PMID: 3184963.
- [9] Marcelletti C, Corno A, Giannico S, Marino B. Inferior vena cava-pulmonary artery extracardiac conduit. A new form of right heart bypass. *J Thorac Cardiovasc Surg* 1990 Aug;100(2):228–232. PMID: 2143549.
- [10] Ben Ali W, Bouhout I, Khairy P, Bouchard D, Poirier N. Extracardiac versus lateral tunnel fontan: a meta-analysis of long-term results. *Ann Thorac Surg* 2019 Mar;107(3):837–843. <https://doi.org/10.1016/j.athoracsur.2018.08.041>. Epub 2018 Oct 10. PMID: 30315799.
- [11] Plappert L, Edwards S, Senatore A, De Martini A. The epidemiology of persons living with fontan in 2020 and projections for 2030: development of an epidemiology model providing multinational estimates. *Adv Ther* 2022 Feb;39(2):1004–1015. <https://doi.org/10.1007/s12325-021-02002-3>. Epub 2021 Dec 22. PMID: 34936056; PMCID: PMC8866255.
- [12] Schilling C, Dalziel K, Nunn R, Du Plessis K, Shi WY, Celermajer D, et al. The fontan epidemic: population projections from the Australia and New Zealand fontan registry. *Int J Cardiol* 2016 Sep 15;219:14–19. <https://doi.org/10.1016/j.ijcard.2016.05.035>. Epub 2016 May 14. PMID: 27257850.
- [13] Idorn L, Olsen M, Jensen AS, Juul K, Reimers JI, Sørensen K, et al. Univentricular hearts in Denmark 1977 to 2009: incidence and survival. *Int J Cardiol* 2013 Aug 20;167(4):1311–1316. <https://doi.org/10.1016/j.ijcard.2012.03.182>. Epub 2012 Apr 21. PMID: 22521378.
- [14] Emamaullee J, Zaidi AN, Schiano T, Kahn J, Valentino PL, Hofer RE, et al. Fontan-associated liver disease: screening, management, and transplant considerations. *Circulation* 2020 Aug 11;142(6):591–604. <https://doi.org/10.1161/CIRCULATIONAHA.120.045597>. Epub 2020 Aug 10. PMID: 32776846; PMCID: PMC7422927.
- [15] Téllez L, Rodríguez de Santiago E, Albillos A. Fontan-associated liver disease. *Rev Esp Cardiol (Engl Ed)* 2018 Mar;71(3):192–202. <https://doi.org/10.1016/j.rec.2017.10.052>. English, Spanish. Epub 2018 Feb 9. PMID: 29433942.
- [16] Pai M, Iorio A, Meerpohl J, Taruscio D, Laricchiuta P, Mincarone P, et al. Developing methodology for the creation of clinical practice guidelines for rare diseases: a report from RARE-Bestpractices. *Rare Dis* 2015;3(1):e1058463. <https://doi.org/10.1080/21675511.2015.1058463>.
- [17] Pai M, Yeung GHT, Akl EA, Darzi A, Hillis C, Legault K, et al. Strategies for eliciting and synthesizing evidence for guidelines in rare diseases. *BMC Med Res Methodol* 2019 Mar 28;19(1):67. <https://doi.org/10.1186/s12874-019-0713-0>. PMID: 30922227; PMCID: PMC6437842.
- [18] Laks H, Pearl JM, Haas GS, Drinkwater DC, Milgater E, Jarmakani JM, et al. Partial Fontan: advantages of an adjustable interatrial communication. *Ann Thorac Surg* 1991 Nov;52(5):1084–1094. [https://doi.org/10.1016/0003-4975\(91\)91286-5](https://doi.org/10.1016/0003-4975(91)91286-5). discussion 1094–5. PMID: 1953128.
- [19] Ivanov Y, Buratto E, Ishigami S, Chowdhuri KR, Schulz A, Brizard CP, Konstantinov IE. Kawashima Procedure: the impact of age. *Ann Thorac Surg* 2023 Aug;116(2):366–372. <https://doi.org/10.1016/j.athoracsur.2022.10.015>. Epub 2022 Oct 23. PMID: 36288759.
- [20] Kreutzer G, Galíndez E, Bono H, De Palma C, Laura JP. An operation for the correction of tricuspid atresia. *J Thorac Cardiovasc Surg* 1973 Oct;66(4):613–621. PMID: 4518787.

- [21] Björk VO, Olin CL, Bjarke BB, Thorén CA. Right atrial-right ventricular anastomosis for correction of tricuspid atresia. *J Thorac Cardiovasc Surg* 1979 Mar;77(3):452–458. PMID: 762988.
- [22] Laschinger JC, Ringel RE, Brenner JI, McLaughlin JS. Extracardiac total cavopulmonary connection. *Ann Thorac Surg* 1992 Aug;54(2):371–373. [https://doi.org/10.1016/0003-4975\(92\)91407-z](https://doi.org/10.1016/0003-4975(92)91407-z). PMID: 1637237.
- [23] Gewillig M, Brown SC, van de Bruaene A, Rychik J. Providing a framework of principles for conceptualising the Fontan circulation. *Acta Paediatr* 2020 Apr;109(4):651–658. <https://doi.org/10.1111/apa.15098>. Epub 2020 Jan 8. PMID: 31737940; PMCID: PMC7155129.
- [24] Gewillig M, Brown SC. The Fontan circulation after 45 years: update in physiology. *Heart* 2016 Jul 15;102(14):1081–1086. <https://doi.org/10.1136/heartjnl-2015-307467>. Epub 2016 May 24. PMID: 27220691; PMCID: PMC4941188.
- [25] Penny DJ, Redington AN. Doppler echocardiographic evaluation of pulmonary blood flow after the Fontan operation: the role of the lungs. *Br Heart J* 1991 Nov;66(5):372–374. <https://doi.org/10.1136/hrt.66.5.372>. PMID: 1747298; PMCID: PMC1024778.
- [26] Sallmon H, Ovroutski S, Schleiger A, Photiadis J, Weber SC, Nordmeyer J, et al. Late Fontan failure in adult patients is predominantly associated with deteriorating ventricular function. *Int J Cardiol* 2021 Dec 1;344:87–94. <https://doi.org/10.1016/j.ijcard.2021.09.042>. Epub 2021 Sep 23. PMID: 34563595.
- [27] Gewillig M, Goldberg DJ. Failure of the fontan circulation. *Heart Fail Clin* 2014 Jan;10(1):105–116. <https://doi.org/10.1016/j.hfc.2013.09.010>. PMID: 24275298.
- [28] Avitabile CM, Goldberg DJ, Leonard MB, Wei ZA, Tang E, Paridon SM, et al. Leg lean mass correlates with exercise systemic output in young Fontan patients. *Heart* 2018 Apr;104(8):680–684. <https://doi.org/10.1136/heartjnl-2017-311661>. Epub 2017 Oct 7. PMID: 28988207; PMCID: PMC7831371.
- [29] Allen KY, Downing TE, Glatz AC, Rogers LS, Ravishankar C, Rychik J, et al. Effect of fontan-associated morbidities on survival with intact fontan circulation. *Am J Cardiol* 2017 Jun 1;119(11):1866–1871. <https://doi.org/10.1016/j.amjcard.2017.03.004>. Epub 2017 Mar 16. PMID: 28385177.
- [30] Rychik J, Atz AM, Celermajer DS, Deal BJ, Gatzoulis MA, Gewillig MH, et al. American heart association council on cardiovascular disease in the young and council on cardiovascular and stroke nursing. Evaluation and management of the child and adult with fontan circulation: a scientific statement from the American heart association. *Circulation* 2019 Jul 1;CIR0000000000006966. <https://doi.org/10.1161/CIR.0000000000006966>. Epub ahead of print. PMID: 31256636.
- [31] Idorn L, Juul K, Jensen AS, Hanel B, Nielsen KG, Andersen H, et al. Arrhythmia and exercise intolerance in Fontan patients: current status and future burden. *Int J Cardiol* 2013 Sep 30;168(2):1458–1465. <https://doi.org/10.1016/j.ijcard.2012.12.055>. Epub 2013 Jan 18. PMID: 23333363.
- [32] Téllez L, Rodríguez-Santiago E, Albillos A. Fontan-associated liver disease: a review. *Ann Hepatol* 2018 Mar 1;17(2):192–204. <https://doi.org/10.5604/01.3001.0010.8634>. PMID: 29469053.
- [33] Krieger EV, Moko LE, Wu F, Landzberg MJ, Valente AM, Assenza GE, et al. Single ventricle anatomy is associated with increased frequency of nonalcoholic cirrhosis. *Int J Cardiol* 2013 Sep 1;167(5):1918–1923. <https://doi.org/10.1016/j.ijcard.2012.05.002>. Epub 2012 Jun 22. PMID: 22727975.
- [34] Alsaied T, Rathod RH, Aboulhosn JA, Budts W, Anderson JB, Baumgartner H, et al. Reaching consensus for unified medical language in Fontan care. *ESC Heart Fail* 2021 Oct;8(5):3894–3905. <https://doi.org/10.1002/ehf2.13294>. Epub 2021 Jun 30. PMID: 34190428; PMCID: PMC8497335.
- [35] Rathgeber SL, Lam C, Harris KC, Grewal J. Hepatic and renal consequences of single-ventricle physiology palliated with the fontan operation. *Can J Cardiol* 2022 Jul;38(7):1002–1011. <https://doi.org/10.1016/j.cjca.2022.04.022>. Epub 2022 May 4. PMID: 35525398.
- [36] Udink Ten Cate FE, Hannes T, Germund I, Khalil M, Huntgeburth M, Apitz C, et al. Towards a proposal for a universal diagnostic definition of protein-losing enteropathy in Fontan patients: a systematic review. *Heart* 2016 Jul 15;102(14):1115–1119. <https://doi.org/10.1136/heartjnl-2015-308823>. Epub 2016 Mar 31. PMID: 27033590.
- [37] Schleiger A, Ovroutski S, Peters B, Schubert S, Photiadis J, Berger F, et al. Treatment strategies for protein-losing enteropathy in Fontan-palliated patients. *Cardiol Young* 2020 May;30(5):698–709. <https://doi.org/10.1017/S1047951120000864>. Epub 2020 May 4. PMID: 32364090.
- [38] Diab SG, Godang K, Müller LO, Almaas R, de Lange C, Brunvand L, et al. Progressive loss of bone mass in children with Fontan circulation. *Congenit Heart Dis* 2019 Nov;14(6):996–1004. <https://doi.org/10.1111/chd.12848>. Epub 2019 Oct 10. PMID: 31600039.
- [39] Schafstedde M, Nordmeyer S, Schleiger A, Nordmeyer J, Berger F, Kramer P, et al. Persisting and reoccurring cyanosis after Fontan operation is associated with increased late mortality. *Eur J Cardiothorac Surg* 2021 Dec 27;61(1):54–61. <https://doi.org/10.1093/ejcts/ezab298>. PMID: 34195822.
- [40] Idorn L, Jensen AS, Juul K, Overgaard D, Nielsen NP, Sørensen K, et al. Quality of life and cognitive function in Fontan patients, a population-based study. *Int J Cardiol* 2013 Oct 9;168(4):3230–3235. <https://doi.org/10.1016/j.ijcard.2013.04.008>. Epub 2013 Apr 28. PMID: 23632112.
- [41] Mohanakumar S, Telinius N, Kelly B, Lauridsen H, Boedtker D, Pedersen M, et al. Morphology and function of the lymphatic vasculature in patients with a fontan circulation. *Circ Cardiovasc Imaging* 2019 Apr;12(4):e008074. <https://doi.org/10.1161/CIRCIMAGING.118.008074>. PMID: 30943769.
- [42] Dori Y, Smith CL. Lymphatic disorders in patients with single ventricle heart disease. *Front Pediatr* 2022 Jun 10;10:828107. <https://doi.org/10.3389/fped.2022.828107>. PMID: 35757132; PMCID: PMC9226478.
- [43] Monagle P, Cochran A, McCrindle B, Benson L, Williams W, Andrew M. Thromboembolic complications after fontan procedures—the role of prophylactic anticoagulation. *J Thorac Cardiovasc Surg* 1998 Mar;115(3):493–498. [https://doi.org/10.1016/s0022-5223\(98\)70310-1](https://doi.org/10.1016/s0022-5223(98)70310-1). PMID: 9535434.
- [44] Balling G, Vogt M, Kaemmerer H, Eicken A, Meisner H, Hess J. Intracardiac thrombus formation after the Fontan operation. *J Thorac Cardiovasc Surg* 2000 Apr;119(4 Pt 1):745–752. [https://doi.org/10.1016/S0022-5223\(00\)70010-9](https://doi.org/10.1016/S0022-5223(00)70010-9). PMID: 10733763.
- [45] Attard C, Huang J, Monagle P, Ignjatovic V. Pathophysiology of thrombosis and anticoagulation post Fontan surgery. *Thromb Res* 2018 Dec;172:204–213. <https://doi.org/10.1016/j.thromres.2018.04.011>. Epub 2018 Apr 14. PMID: 29685556.
- [46] Valente AM, Bhatt AB, Cook S, Earing MG, Gersony DR, Aboulhosn J, et al. AARCC (alliance for adult research in congenital Cardiology) investigators. The CALF (congenital heart disease in adults lower extremity systemic venous health in fontan patients) study. *J Am Coll Cardiol* 2010 Jul 6;56(2):144–150. <https://doi.org/10.1016/j.jacc.2010.02.048>. PMID: 20620728.
- [47] Pundi KN, Pundi KN, Johnson JN, Dearani JA, Li Z, Driscoll DJ, et al. Sudden cardiac death and late arrhythmias after the Fontan operation. *Congenit Heart Dis* 2017 Jan;12(1):17–23. <https://doi.org/10.1111/chd.12401>. Epub 2016 Aug 22. PMID: 27545004.
- [48] Lasa JJ, Glatz AC, Daga A, Shah M. Prevalence of arrhythmias late after the Fontan operation. *Am J Cardiol* 2014 Apr 1;113(7):1184–1188. <https://doi.org/10.1016/j.amjcard.2013.12.025>. Epub 2014 Jan 14. PMID: 24513470.
- [49] Wan D, Grewal J, Barlow A, Kiess M, Human D, Krahn AD, et al. Atrial arrhythmias and thromboembolic complications in adults post Fontan surgery. *Open Heart* 2020 Oct;7(2):e001224. <https://doi.org/10.1136/openhrt-2019-001224>. PMID: 33060140; PMCID: PMC7566428.
- [50] Schleiger A, Kramer P, Salzmann M, Danne F, Schubert S, Bassir C, et al. Evaluation of Fontan failure by classifying the severity of Fontan-associated liver disease: a single-centre cross-sectional study. *Eur J Cardiothorac Surg* 2020 Oct 28:ezaa310. <https://doi.org/10.1093/ejcts/ezaa310>. Epub ahead of print. PMID: 33111145.
- [51] Emamaullee J, Martin S, Goldbeck C, Rocque B, Barbeta A, Kohli R, et al. Evaluation of fontan-associated liver disease and ethnic disparities in long-term survivors of the fontan procedure: a population-based study. *Ann Surg* 2022 Sep 1;276(3):482–490. <https://doi.org/10.1097/SLA.0000000000005581>. Epub 2022 Jun 29. PMID: 35766375; PMCID: PMC9388565.
- [52] Lindsay I, Johnson J, Everitt MD, Hoffman J, Yetman AT. Impact of liver disease after the fontan operation. *Am J Cardiol* 2015 Jan 15;115(2):249–252. <https://doi.org/10.1016/j.amjcard.2014.10.032>. Epub 2014 Oct 30. PMID: 25534765.
- [53] Zafar F, Lubert AM, Katz DA, Hill GD, Opatowsky AR, Alten JA, et al. Long-term kidney function after the fontan operation: JACC review topic of the week. *J Am Coll Cardiol* 2020 Jul 21;76(3):334–341. <https://doi.org/10.1016/j.jacc.2020.05.042>. PMID: 32674796.
- [54] Khuong JN, Wilson TG, Grigg LE, Bullock A, Celermajer D, Disney P, et al. Fontan-associated nephropathy: predictors and outcomes. *Int J Cardiol* 2020 May 1;306:73–77. <https://doi.org/10.1016/j.ijcard.2020.01.014>. Epub 2020 Jan 10. PMID: 31955974.

- [55] Anne P, Du W, Mattoo TK, Zilberman MV. Nephropathy in patients after Fontan palliation. *Int J Cardiol* 2009 Feb 20;132(2):244–247. <https://doi.org/10.1016/j.ijcard.2007.11.079>. Epub 2008 Jan 29. PMID: 18234362.
- [56] Alsaied T, Bokma JP, Engel ME, Kuijpers JM, Hanke SP, Zuhlke L, et al. Factors associated with long-term mortality after Fontan procedures: a systematic review. *Heart* 2017 Jan 15;103(2):104–110. <https://doi.org/10.1136/heartjnl-2016-310108>. Epub 2016 Nov 9. PMID: 28057809.
- [57] Rychik J, Goldberg D, Rand E, Semeao E, Russo P, Dori Y, et al. End-organ consequences of the Fontan operation: liver fibrosis, protein-losing enteropathy and plastic bronchitis. *Cardiol Young* 2013 Dec;23(6):831–840. <https://doi.org/10.1017/S1047951113001650>. PMID: 24401255.
- [58] Bhatt AB, Landzberg MJ, Gerhard-Herman M, Rodriguez-Huertas E, Graham D, Valente AM. Pathophysiology of chronic venous insufficiency in adults with a Fontan circulation (a pre-defined substudy of the CALF investigation). *Int J Cardiol* 2013 Apr 30;165(1):41–45. <https://doi.org/10.1016/j.ijcard.2011.07.053>. Epub 2011 Aug 11. PMID: 21839529.
- [59] Caruthers RL, Kempa M, Loo A, Gulbransen E, Kelly E, Erickson SR, et al. Demographic characteristics and estimated prevalence of Fontan-associated plastic bronchitis. *Pediatr Cardiol* 2013 Feb;34(2):256–261. <https://doi.org/10.1007/s00246-012-0430-5>. Epub 2012 Jul 15. PMID: 22797520; PMCID: PMC3586576.
- [60] Inai K, Inuzuka R, Ono H, Nii M, Ohtsuki S, Kurita Y, et al. Predictors of long-term mortality among perioperative survivors of Fontan operation. *Eur Heart J* 2022 Jul 1;43(25):2373–2384. <https://doi.org/10.1093/eurheartj/ehab826>. PMID: 34888643.
- [61] Broda CR, Downing TE, John AS. Diagnosis and management of the adult patient with a failing Fontan circulation. *Heart Fail Rev* 2020 Jul;25(4):633–646. <https://doi.org/10.1007/s10741-020-09932-0>. PMID: 32185561.
- [62] Gewillig M. The Fontan circulation. *Heart* 2005 Jun;91(6):839–846. <https://doi.org/10.1136/hrt.2004.051789>. PMID: 15894794; PMCID: PMC1768934.
- [63] Goldberg DJ, Shaddy RE, Ravishankar C, Rychik J. The failing Fontan: etiology, diagnosis and management. *Expert Rev Cardiovasc Ther* 2011 Jun;9(6):785–793. <https://doi.org/10.1586/erc.11.75>. PMID: 21714609.
- [64] Book WM, Gerardin J, Saraf A, Marie Valente A, Rodriguez 3rd F. Clinical phenotypes of fontan failure: implications for management. *Congenit Heart Dis* 2016 Jul;11(4):296–308. <https://doi.org/10.1111/chd.12368>. Epub 2016 May 26. PMID: 27226033.
- [65] Poh C, Hornung T, Celermajer DS, Radford DJ, Justo RN, Andrews D, et al. Modes of late mortality in patients with a Fontan circulation. *Heart* 2020 Sep;106(18):1427–1431. <https://doi.org/10.1136/heartjnl-2019-315862>. Epub 2020 Feb 25. PMID: 32098807.
- [66] Poh CL, Cordina RL, Iyengar AJ, Zannino D, Grigg LE, Wheaton GR, et al. Pre- and Post-operative determinants of transplantation-free survival after Fontan. The Australia and New Zealand experience. *Int J Cardiol Heart Vasc* 2021 Jul 7;35:100825. <https://doi.org/10.1016/j.ijcha.2021.100825>. PMID: 34286062; PMCID: PMC8273214.
- [67] Kramer P, Schleiger A, Schafstedde M, Danne F, Nordmeyer J, Berger F, et al. A multimodal score accurately classifies fontan failure and late mortality in adult fontan patients. *Front Cardiovasc Med* 2022 Mar 10;9:767503. <https://doi.org/10.3389/fcvm.2022.767503>. PMID: 35360016; PMCID: PMC8960137.
- [68] Poh CL, d'Udekem Y. Life after surviving fontan surgery: a meta-analysis of the incidence and predictors of late death. *Heart Lung Circ* 2018 May;27(5):552–559. <https://doi.org/10.1016/j.hlc.2017.11.007>. Epub 2017 Dec 20. PMID: 29402692.
- [69] Dennis M, Zannino D, du Plessis K, Bullock A, Disney PJS, Radford DJ, et al. Clinical outcomes in adolescents and adults after the fontan procedure. *J Am Coll Cardiol* 2018 Mar 6;71(9):1009–1017. <https://doi.org/10.1016/j.jacc.2017.12.054>. PMID: 29495980.
- [70] de Leval MR, Deanfield JE. Four decades of Fontan palliation. *Nat Rev Cardiol* 2010 Sep;7(9):520–527. <https://doi.org/10.1038/nrcardio.2010.99>. Epub 2010 Jun 29. PMID: 20585329.
- [71] Downing TE, Allen KY, Glatz AC, Rogers LS, Ravishankar C, Rychik J, et al. Long-term survival after the Fontan operation: twenty years of experience at a single center. *J Thorac Cardiovasc Surg* 2017 Jul;154(1):243–253.e2. <https://doi.org/10.1016/j.jtcvs.2017.01.056>. Epub 2017 Mar 6. PMID: 28341469.
- [72] Kotani Y, Chetan D, Zhu J, Saedi A, Zhao L, Mertens L, et al. Fontan failure and death in contemporary fontan circulation: analysis from the last two decades. *Ann Thorac Surg* 2018 Apr;105(4):1240–1247. <https://doi.org/10.1016/j.athoracsur.2017.10.047>. Epub 2018 Feb 15. PMID: 29397930.
- [73] Fontan F, Kirklin JW, Fernandez G, Costa F, Naftel DC, Tritto F, et al. Outcome after a "perfect" Fontan operation. *Circulation* 1990 May;81(5):1520–1536. <https://doi.org/10.1161/01.cir.81.5.1520>. PMID: 2331765.
- [74] Greutmann M, Tobler D, Kovacs AH, Greutmann-Yantiri M, Haile SR, Held L, et al. Increasing mortality burden among adults with complex congenital heart disease. *Congenit Heart Dis* 2015 Mar-Apr;10(2):117–127. <https://doi.org/10.1111/chd.12201>. Epub 2014 Jul 7. PMID: 25043406.
- [75] Diller GP, Kempny A, Alonso-Gonzalez R, Swan L, Uebing A, Li W, et al. Survival prospects and circumstances of death in contemporary adult congenital heart disease patients under follow-up at a large tertiary centre. *Circulation* 2015 Dec 1;132(22):2118–2125. <https://doi.org/10.1161/CIRCULATIONAHA.115.017202>. Epub 2015 Sep 14. PMID: 26369353.
- [76] Atz AM, Zak V, Mahony L, Uzark K, D'agincourt N, Goldberg DJ, et al. Pediatric heart network investigators. Longitudinal outcomes of patients with single ventricle after the fontan procedure. *J Am Coll Cardiol* 2017 Jun 6;69(22):2735–2744. <https://doi.org/10.1016/j.jacc.2017.03.582>. PMID: 28571639; PMCID: PMC5604334.
- [77] Lemmer JH, Coran AG, Behrendt DM, Heidelberger KP, Stern AM. Liver fibrosis (cardiac cirrhosis) five years after modified Fontan operation for tricuspid atresia. *J Thorac Cardiovasc Surg* 1983 Nov;86(5):757–760. PMID: 6632950.
- [78] Baek JS, Bae EJ, Ko JS, Kim GB, Kwon BS, Lee SY, et al. Late hepatic complications after Fontan operation; non-invasive markers of hepatic fibrosis and risk factors. *Heart* 2010 Nov;96(21):1750–1755. <https://doi.org/10.1136/hrt.2010.201772>. PMID: 20956491.
- [79] Camposilvan S, Milanese O, Stellan G, Pettenazzo A, Zancan L, D'Antiga L. Liver and cardiac function in the long term after Fontan operation. *Ann Thorac Surg* 2008 Jul;86(1):177–182. <https://doi.org/10.1016/j.athoracsur.2008.03.077>. PMID: 18573420.
- [80] Wu FM, Kogon B, Earing MG, Aboulhosen JA, Broberg CS, John AS, et al. Alliance for adult research in congenital Cardiology (AARCC) investigators. Liver health in adults with fontan circulation: a multicenter cross-sectional study. *J Thorac Cardiovasc Surg* 2017 Mar;153(3):656–664. <https://doi.org/10.1016/j.jtcvs.2016.10.060>. Epub 2016 Nov 12. PMID: 27955914.
- [81] Wu FM, Earing MG, Aboulhosen JA, Johncilla ME, Singh MN, Odze RD, et al. Alliance for adult research in congenital Cardiology (AARCC) investigators. Predictive value of biomarkers of hepatic fibrosis in adult fontan patients. *J Heart Lung Transpl* 2017 Feb;36(2):211–219. <https://doi.org/10.1016/j.healun.2016.07.011>. Epub 2016 Jul 27. PMID: 27592026.
- [82] Nandwana SB, Olaiya B, Cox K, Sahu A, Mittal P. Abdominal imaging surveillance in adult patients after fontan procedure: risk of chronic liver disease and hepatocellular carcinoma. *Curr Probl Diagn Radiol* 2018 Jan-Feb;47(1):19–22. <https://doi.org/10.1067/j.cpradiol.2017.04.002>. Epub 2017 Apr 11. PMID: 28602501.
- [83] Elder RW, McCabe NM, Hebson C, Veledar E, Romero R, Ford RM, et al. Features of portal hypertension are associated with major adverse events in Fontan patients: the VAST study. *Int J Cardiol* 2013 Oct 9;168(4):3764–3769. <https://doi.org/10.1016/j.ijcard.2013.06.008>. Epub 2013 Jul 9. PMID: 23849105; PMCID: PMC3805740.
- [84] Wilson TG, d'Udekem Y, Winlaw DS, Cordina RL, Celermajer DS, Wheaton GR, et al. Australian and New Zealand Fontan Registry. Hepatic and renal end-organ damage in the Fontan circulation: a report from the Australian and New Zealand Fontan Registry. *Int J Cardiol* 2018 Dec 15;273:100–107. <https://doi.org/10.1016/j.ijcard.2018.07.118>. Epub 2018 Jul 25. PMID: 30060970.
- [85] Goldberg DJ, Surrey LF, Glatz AC, Dodds K, O'Byrne ML, Lin HC, et al. Hepatic fibrosis is universal following fontan operation, and severity is associated with time from surgery: a liver biopsy and hemodynamic study. *J Am Heart Assoc* 2017 Apr 26;6(5):e004809. <https://doi.org/10.1161/JAHA.116.004809>. PMID: 28446492; PMCID: PMC5524062.
- [86] Johnson JA, Cetta F, Graham RP, Smyrk TC, Driscoll DJ, Phillips SD, et al. Identifying predictors of hepatic disease in patients after the Fontan operation: a postmortem analysis. *J Thorac Cardiovasc Surg* 2013 Jul;146(1):140–145. <https://doi.org/10.1016/j.jtcvs.2012.09.005>. Epub 2012 Oct 13. PMID: 23072704.
- [87] Schwartz MC, Sullivan L, Cohen MS, Russo P, John AS, Guo R, et al. Hepatic pathology may develop before the Fontan operation in children with functional single ventricle: an autopsy study. *J Thorac Cardiovasc Surg* 2012 Apr;143(4):904–909. <https://doi.org/10.1016/j.jtcvs.2011.08.038>. Epub 2011 Sep 28. PMID: 21955477.
- [88] Hilscher MB, Wells ML, Venkatesh SK, Cetta F, Kamath PS. Fontan-associated liver disease. *Hepatology* 2022 May;75(5):1300–1321. <https://doi.org/10.1002/hep.32406>. Epub 2022 Mar 15. PMID: 35179797.



- [89] Kendall TJ, Stedman B, Hacking N, Haw M, Vettukattill JJ, Salmon AP, et al. Hepatic fibrosis and cirrhosis in the Fontan circulation: a detailed morphological study. *J Clin Pathol* 2008 Apr;61(4):504–508. <https://doi.org/10.1136/jcp.2007.052365>. Epub 2007 Oct 26. PMID: 17965217.
- [90] Simonetto DA, Yang HY, Yin M, de Assuncao TM, Kwon JH, Hilscher M, et al. Chronic passive venous congestion drives hepatic fibrogenesis via sinusoidal thrombosis and mechanical forces. *Hepatology* 2015 Feb;61(2):648–659. <https://doi.org/10.1002/hep.27387>. Epub 2015 Jan 5. PMID: 25142214; PMCID: PMC4303520.
- [91] Hilscher MB, Sehrawat T, Arab JP, Zeng Z, Gao J, Liu M, et al. Mechanical stretch increases expression of CXCL1 in liver sinusoidal endothelial cells to recruit neutrophils, generate sinusoidal microthrombi, and promote portal hypertension. *Gastroenterology* 2019 Jul;157(1):193–209.e9. <https://doi.org/10.1053/j.gastro.2019.03.013>. Epub 2019 Mar 11. PMID: 30872106; PMCID: PMC6581607.
- [92] Thomas H. LSEC stretch promotes fibrosis during hepatic vascular congestion. *Nat Rev Gastroenterol Hepatol* 2019 May;16(5):262–263. <https://doi.org/10.1038/s41575-019-0146-6>. PMID: 30971753.
- [93] Iwakiri Y. Nitric oxide in liver fibrosis: the role of inducible nitric oxide synthase. *Clin Mol Hepatol* 2015 Dec;21(4):319–325. <https://doi.org/10.3350/cmh.2015.21.4.319>. Epub 2015 Dec 24. PMID: 26770919; PMCID: PMC4712158.
- [94] Haggerty CM, Restrepo M, Tang E, de Zélicourt DA, Sundareswaran KS, Mirabella L, et al. Fontan hemodynamics from 100 patient-specific cardiac magnetic resonance studies: a computational fluid dynamics analysis. *J Thorac Cardiovasc Surg* 2014 Oct;148(4):1481–1489. <https://doi.org/10.1016/j.jtcvs.2013.11.060>. Epub 2013 Dec 31. PMID: 24507891; PMCID: PMC6815671.
- [95] Gordon-Walker TT, Bove K, Veldtman G. Fontan-associated liver disease: a review. *J Cardiol* 2019 Sep;74(3):223–232. <https://doi.org/10.1016/j.jcc.2019.02.016>. Epub 2019 Mar 28. PMID: 30928109.
- [96] Lightsey JM, Rockey DC. Current concepts in ischemic hepatitis. *Curr Opin Gastroenterol* 2017 May;33(3):158–163. <https://doi.org/10.1097/MOG.0000000000000355>. PMID: 28346236.
- [97] Dijkstra H, Wolff D, van Melle JP, Bartelds B, Willems TP, Oudkerk M, et al. Diminished liver microperfusion in Fontan patients: a biexponential DWI study. *PLoS One* 2017 Mar 3;12(3):e0173149. <https://doi.org/10.1371/journal.pone.0173149>. PMID: 28257439; PMCID: PMC5336266.
- [98] Durongpisitkul K, Driscoll DJ, Mahoney DW, Wollan PC, Mottram CD, Puga FJ, et al. Cardiorespiratory response to exercise after modified Fontan operation: determinants of performance. *J Am Coll Cardiol* 1997 Mar 15;29(4):785–790. [https://doi.org/10.1016/s0735-1097\(96\)00568-2](https://doi.org/10.1016/s0735-1097(96)00568-2). PMID: 9091525.
- [99] Ohuchi H, Mori A, Nakai M, Fujimoto K, Iwasa T, Sakaguchi H, et al. Pulmonary arteriovenous fistulae after fontan operation: incidence, clinical characteristics, and impact on all-cause mortality. *Front Pediatr* 2022 Jun 9;10:713219. <https://doi.org/10.3389/fped.2022.713219>. PMID: 35757115; PMCID: PMC9218217.
- [100] Daems JJN, Attard C, Van Den Helm S, Breur J, D'Udekem Y, du Plessis K, et al. Cross-sectional assessment of haemostatic profile and hepatic dysfunction in Fontan patients. *Open Heart* 2021 May;8(1):e001460. <https://doi.org/10.1136/openhrt-2020-001460>. PMID: 33972403; PMCID: PMC8112412.
- [101] Skubera M, Gołęb A, Plicner D, Natorka J, Ząbczyk M, Trojnariska O, et al. Properties of plasma clots in adult patients following fontan procedure: relation to clot permeability and lysis time-multicenter study. *J Clin Med* 2021 Dec 20;10(24):5976. <https://doi.org/10.3390/jcm10245976>. PMID: 34945271; PMCID: PMC8709107.
- [102] McCrindle BW, Michelson AD, Van Bergen AH, Suzana Horowitz E, Pablo Sandoval J, Justino H, et al. UNIVERSE study investigators \*. Thromboprophylaxis for children post-fontan procedure: insights from the UNIVERSE study. *J Am Heart Assoc* 2021 Nov 16;10(22):e021765. <https://doi.org/10.1161/JAHA.120.021765>. Epub 2021 Sep 24. Erratum in: *J Am Heart Assoc*. 2021 Dec 21;10(24):e020766. PMID: 34558312; PMCID: PMC8751951.
- [103] Tomkiewicz-Pajak L, Hoffman P, Trojnariska O, Lipczyńska M, Podolec P, Undas A. Abnormalities in blood coagulation, fibrinolysis, and platelet activation in adult patients after the Fontan procedure. *J Thorac Cardiovasc Surg* 2014 Apr;147(4):1284–1290. <https://doi.org/10.1016/j.jtcvs.2013.06.011>. Epub 2013 Jul 24. PMID: 23891464.
- [104] Procelewska M, Kolcz J, Januszewska K, Mroczek T, Malec E. Coagulation abnormalities and liver function after hemi-Fontan and Fontan procedures - the importance of hemodynamics in the early postoperative period. *Eur J Cardiothorac Surg* 2007 May;31(5):866–872. <https://doi.org/10.1016/j.ejcts.2007.01.033>. Epub 2007 Feb 27. PMID: 17329113.
- [105] Rauch R, Ries M, Hofbeck M, Buheitel G, Singer H, Klinge J. Hemostatic changes following the modified Fontan operation (total cavopulmonary connection). *Thromb Haemost* 2000 May;83(5):678–682. PMID: 10823261.
- [106] Jeong J, Tanaka M, Iwakiri Y. Hepatic lymphatic vascular system in health and disease. *J Hepatol* 2022 Jul;77(1):206–218. <https://doi.org/10.1016/j.jhep.2022.01.025>. Epub 2022 Feb 11. PMID: 35157960.
- [107] Tanaka M, Iwakiri Y. Lymphatics in the liver. *Curr Opin Immunol* 2018 Aug;53:137–142. <https://doi.org/10.1016/j.coi.2018.04.028>. Epub 2018 May 14. PMID: 29772409; PMCID: PMC6986420.
- [108] Alsaied T, Moore RA, Lang SM, Truong V, Lubert AM, Veldtman GR, et al. Myocardial fibrosis, diastolic dysfunction and elevated liver stiffness in the Fontan circulation. *Open Heart* 2020 Oct;7(2):e001434. <https://doi.org/10.1136/openhrt-2020-001434>. PMID: 33109703; PMCID: PMC7592252.
- [109] Rodríguez de Santiago E, Téllez L, Garrido-Lestache Rodríguez-Monte E, Garrido-Gómez E, Aguilera-Castro L, Álvarez-Fuente M, et al. Fontan protein-losing enteropathy is associated with advanced liver disease and a proinflammatory intestinal and systemic state. *Liver Int* 2020 Mar;40(3):638–645. <https://doi.org/10.1111/liv.14375>. Epub 2020 Jan 22. PMID: 31912956.
- [110] Wang A, Book WM, McConnell M, Lyle T, Rodby K, Mahle WT. Prevalence of hepatitis C infection in adult patients who underwent congenital heart surgery prior to screening in 1992. *Am J Cardiol* 2007 Oct 15;100(8):1307–1309. <https://doi.org/10.1016/j.amjcard.2007.05.059>. Epub 2007 Jul 25. PMID: 17920376.
- [111] Cox DA, Ginde S, Tweddell JS, Earing MG. Outcomes of a hepatitis C screening protocol in at-risk adults with prior cardiac surgery. *World J Pediatr Congenit Heart Surg* 2014 Oct;5(4):503–506. <https://doi.org/10.1177/2150135114547587>. PMID: 25324245.
- [112] Sung PS, Yoon SK. Amiodarone hepatotoxicity. *Hepatology* 2012 Jan;55(1):325–326. <https://doi.org/10.1002/hep.24627>. PMID: 21898482.
- [113] Schleiger A, Salzmann M, Kramer P, Danne F, Schubert S, Bassir C, et al. Severity of fontan-associated liver disease correlates with fontan hemodynamics. *Pediatr Cardiol* 2020 Apr;41(4):736–746. <https://doi.org/10.1007/s00246-020-02291-5>. Epub 2020 Feb 1. PMID: 32006084; PMCID: PMC7256101.
- [114] Schleiger A, Kramer P, Sallmon H, Jentsch N, Pileckaite M, Danne F, et al. Functional hepatic deterioration determined by  $^{13}\text{C}$ -methacetin breath test is associated with impaired hemodynamics and late Fontan failure in adults. *Front Cardiovasc Med* 2022 Sep 7;9:952080. <https://doi.org/10.3389/fcvm.2022.952080>. PMID: 36158803; PMCID: PMC9489932.
- [115] Hansen JH, Khodami JK, Moritz JD, Rinne K, Voges I, Scheewe J, et al. Surveillance of fontan associated liver disease in childhood and adolescence. *Semin Thorac Cardiovasc Surg* 2022 Summer;34(2):642–650. <https://doi.org/10.1053/j.semthor.2021.04.005>. Epub 2021 May 9. PMID: 33979666.
- [116] Yoon JS, Lee DH, Cho EJ, Song MK, Choi YH, Kim GB, et al. Risk of liver cirrhosis and hepatocellular carcinoma after fontan operation: a need for surveillance. *Cancers (Basel)* 2020 Jul 6;12(7):1805. <https://doi.org/10.3390/cancers12071805>. PMID: 32640555; PMCID: PMC7408507.
- [117] Lewis MJ, Hecht E, Ginns J, Benton J, Prince M, Rosenbaum MS. Serial cardiac MRIs in adult Fontan patients detect progressive hepatic enlargement and congestion. *Congenit Heart Dis* 2017 Mar;12(2):153–158. <https://doi.org/10.1111/ehd.12422>. Epub 2016 Nov 28. PMID: 27893192.
- [118] Agnoletti G, Ferraro G, Bordese R, Marini D, Gala S, Bergamasco L, et al. Fontan circulation causes early, severe liver damage. Should we offer patients a tailored strategy? *Int J Cardiol* 2016 Apr 15;209:60–65. <https://doi.org/10.1016/j.ijcard.2016.02.041>. Epub 2016 Feb 3. PMID: 26882184.
- [119] Kiesewetter CH, Sheron N, Vettukattill JJ, Hacking N, Stedman B, Millward-Sadler H, et al. Hepatic changes in the failing Fontan circulation. *Heart* 2007 May;93(5):579–584. <https://doi.org/10.1136/hrt.2006.094516>. Epub 2006 Sep 27. PMID: 17005713; PMCID: PMC1955554.
- [120] Surrey LF, Russo P, Rychik J, Goldberg DJ, Dodds K, O'Byrne ML, et al. Prevalence and characterization of fibrosis in surveillance liver biopsies of patients with Fontan circulation. *Hum Pathol* 2016 Nov;57:106–115. <https://doi.org/10.1016/j.humpath.2016.07.006>. Epub 2016 Jul 27. PMID: 27476041.
- [121] Ghaferi AA, Hutchins GM. Progression of liver pathology in patients undergoing the Fontan procedure: chronic passive congestion, cardiac cirrhosis, hepatic adenoma, and hepatocellular carcinoma. *J Thorac Cardiovasc Surg* 2005 Jun;129(6):1348–1352. <https://doi.org/10.1016/j.jtcvs.2004.10.005>. PMID: 15942576.
- [122] Pundi K, Pundi KN, Kamath PS, Cetta F, Li Z, Poterucha JT, et al. Liver disease in patients after the fontan operation. *Am J Cardiol* 2016 Feb

- 1;117(3):456–460. <https://doi.org/10.1016/j.amjcard.2015.11.014>. Epub 2015 Nov 18. PMID: 26704027.
- [123] Laohachai K, Badal T, Thamrin C, Robinson PD, Kennedy B, Rice K, et al. Older age at Fontan completion is associated with reduced lung volumes and increased lung reactance. *Int J Cardiol* 2022 Oct 1;364:38–43. <https://doi.org/10.1016/j.ijcard.2022.06.037>. Epub 2022 Jun 14. PMID: 35714716.
- [124] Evans WN, Acherman RJ, Restrepo H. Hepatic fibrosis gender differences in extracardiac Fontan patients. *J Card Surg* 2022 Nov;37(11):3520–3524. <https://doi.org/10.1111/jocs.16880>. Epub 2022 Sep 4. PMID: 36057990.
- [125] Evans WN, Acherman RJ, Mayman GA, Galindo A, Rothman A, Ciccolo ML, et al. Fontan-associated anatomical variants and hepatic fibrosis. *World J Pediatr Congenit Heart Surg* 2021 Mar;12(2):168–172. <https://doi.org/10.1177/2150135120969388>. PMID: 33684008.
- [126] Evans WN, Acherman RJ, Mayman GA, Galindo A, Rothman A, Winn BJ, et al. The rate of hepatic fibrosis progression in patients post-fontan. *Pediatr Cardiol* 2020 Jun;41(5):905–909. <https://doi.org/10.1007/s00246-020-02331-0>. Epub 2020 Mar 3. PMID: 32125444.
- [127] Evans WN, Acherman RJ, Mayman GA, Galindo A, Rothman A, Ciccolo ML, et al. Fontan venovenous collaterals and hepatic fibrosis. *J Card Surg* 2020 Nov;35(11):2974–2978. <https://doi.org/10.1111/jocs.14951>. Epub 2020 Aug 13. PMID: 32789925.
- [128] Mori M, Hebson C, Shioda K, Elder RW, Kogon BE, Rodriguez FH, et al. Catheter-measured hemodynamics of adult fontan circulation: associations with adverse event and end-organ dysfunctions. *Congenit Heart Dis* 2016 Dec;11(6):589–597. <https://doi.org/10.1111/chd.12345>. Epub 2016 Mar 2. PMID: 26932151.
- [129] Silva-Sepulveda JA, Fonseca Y, Vodkin I, Vaughn G, Newbury R, Vavinskaya V, et al. Evaluation of Fontan liver disease: correlation of transjugular liver biopsy with magnetic resonance and hemodynamics. *Congenit Heart Dis* 2019 Jul;14(4):600–608. <https://doi.org/10.1111/chd.12770>. Epub 2019 Apr 30. PMID: 31038848.
- [130] Inuzuka R, Nii M, Inai K, Shimada E, Shinohara T, Kogiso T, et al. Predictors of liver cirrhosis and hepatocellular carcinoma among perioperative survivors of the Fontan operation. *Heart* 2022 Oct 5. <https://doi.org/10.1136/heartjnl-2022-320940>. [heartjnl-2022-320940](https://doi.org/10.1136/heartjnl-2022-320940). Epub ahead of print. PMID: 35768191.
- [131] Wilson TG, Iyengar AJ, Zentner D, Zannino D, d'Udekem Y, Konstantinov IE. Liver cirrhosis after the fontan procedure: impact of atrioventricular valve failure. *Ann Thorac Surg* 2022 Jul 2;S0003-4975(22):924–929. <https://doi.org/10.1016/j.athoracsur.2022.06.018>. Epub ahead of print. PMID: 35792167.
- [132] Dai DF, Swanson PE, Krieger EV, Liou IW, Carithers RL, Yeh MM. Congestive hepatic fibrosis score: a novel histologic assessment of clinical severity. *Mod Pathol* 2014 Dec;27(12):1552–1558. <https://doi.org/10.1038/modpathol.2014.79>. Epub 2014 Jun 13. PMID: 24925051.
- [133] Myers RP, Cerini R, Sayegh R, Moreau R, Degott C, Lebrec D, et al. Cardiac hepatopathy: clinical, hemodynamic, and histologic characteristics and correlations. *Hepatology* 2003 Feb;37(2):393–400. <https://doi.org/10.1053/jhep.2003.50062>. PMID: 12540790.
- [134] Arcidi Jr JM, Moore GW, Hutchins GM. Hepatic morphology in cardiac dysfunction: a clinicopathologic study of 1000 subjects at autopsy. *Am J Pathol* 1981 Aug;104(2):159–166. PMID: 6455066; PMCID: PMC1903755.
- [135] Lefkowitz JH, Mendez L. Morphologic features of hepatic injury in cardiac disease and shock. *J Hepatol* 1986;2(3):313–327. [https://doi.org/10.1016/S0168-8278\(86\)80043-5](https://doi.org/10.1016/S0168-8278(86)80043-5). PMID: 3722787.
- [136] Schwartz MC, Sullivan LM, Glatz AC, Rand E, Russo P, Goldberg DJ, et al. Portal and sinusoidal fibrosis are common on liver biopsy after Fontan surgery. *Pediatr Cardiol* 2013 Jan;34(1):135–142. <https://doi.org/10.1007/s00246-012-0402-9>. Epub 2012 Jun 14. PMID: 22695765.
- [137] Wu FM, Jonas MM, Opatowsky AR, Harmon A, Raza R, Ukomadu C, et al. Portal and centrilobular hepatic fibrosis in Fontan circulation and clinical outcomes. *J Heart Lung Transpl* 2015 Jul;34(7):883–891. <https://doi.org/10.1016/j.healun.2015.01.993>. Epub 2015 Feb 11. PMID: 25863891.
- [138] Surrey LF, Russo P, Rychik J, Goldberg DJ, Dodds K, O'Byrne ML, et al. Defining the role of liver biopsy in the assessment of liver fibrosis in patients with Fontan circulation-reply. *Hum Pathol* 2017 Nov;69:141. <https://doi.org/10.1016/j.humpath.2017.04.029>. Epub 2017 Jun 8. PMID: 28603067.
- [139] Engelhardt EM, Trout AT, Sheridan RM, Veldtman GR, Dillman JR. Focal liver lesions following Fontan palliation of single ventricle physiology: a radiology-pathology case series. *Congenit Heart Dis* 2019 May;14(3):380–388. <https://doi.org/10.1111/chd.12730>. Epub 2018 Dec 20. PMID: 30569564.
- [140] Krings G, Can B, Ferrell L. Aberrant centrilobular features in chronic hepatic venous outflow obstruction: centrilobular mimicry of portal-based disease. *Am J Surg Pathol* 2014 Feb;38(2):205–214. <https://doi.org/10.1097/PAS.000000000000099>. PMID: 24418854.
- [141] Munsterman ID, Duijnhouwer AL, Kendall TJ, Bronkhorst CM, Ronot M, van Wettere M, et al. The clinical spectrum of Fontan-associated liver disease: results from a prospective multimodality screening cohort. *Eur Heart J* 2019 Apr 1;40(13):1057–1068. <https://doi.org/10.1093/eurheartj/ehy620>. PMID: 30346512.
- [142] Louie CY, Pham MX, Daugherty TJ, Kambham N, Higgins JP. The liver in heart failure: a biopsy and explant series of the histopathologic and laboratory findings with a particular focus on pre-cardiac transplant evaluation. *Mod Pathol* 2015 Jul;28(7):932–943. <https://doi.org/10.1038/modpathol.2015.40>. Epub 2015 Mar 20. PMID: 25793895.
- [143] Perucca G, de Lange C, Franchi-Abella S, Napolitano M, Riccabona M, Ključevšek D, et al. Surveillance of fontan-associated liver disease: current standards and a proposal from the European society of paediatric radiology abdominal task force. *Pediatr Radiol* 2021 Dec;51(13):2598–2606. <https://doi.org/10.1007/s00247-021-05173-x>. Epub 2021 Oct 15. PMID: 34654967; PMCID: PMC8599216.
- [144] Perucca G, de Lange C, Franchi-Abella S, Napolitano M, Riccabona M, Ključevšek D, et al. Radiologic follow-up in Fontan-associated liver disease in Europe: European Society of Paediatric Radiology survey demonstrates the need for a consensus protocol. *Pediatr Radiol* 2021 Dec;51(13):2607–2610. <https://doi.org/10.1007/s00247-021-05172-y>. Epub 2021 Oct 16. PMID: 34654969; PMCID: PMC8599243.
- [145] Vaikunth SS, Higgins JP, Concepcion W, Haeffele C, Wright GE, Chen S, et al. Does liver biopsy accurately measure fibrosis in Fontan-associated liver disease? A comparison of liver biopsy pre-combined heart and liver transplant and liver explant post-transplant. *Clin Transpl* 2020 Dec;34(12):e14120. <https://doi.org/10.1111/ctr.14120>. Epub 2020 Nov 1. PMID: 33053213.
- [146] Murtuza B, Hermuzi A, Crossland DS, Parry G, Lord S, Hudson M, et al. Impact of mode of failure and end-organ dysfunction on the survival of adult Fontan patients undergoing cardiac transplantation. *Eur J Cardiothorac Surg* 2017 Jan;51(1):135–141. <https://doi.org/10.1093/ejcts/ezw243>. Epub 2016 Jul 11. PMID: 27401703.
- [147] Haugk B, Bury Y, Coats L, O'Sullivan J, Hudson M. Defining the role of liver biopsy in the assessment of liver fibrosis in patients with Fontan circulation. *Hum Pathol* 2017 Nov;69:140. <https://doi.org/10.1016/j.humpath.2017.04.028>. Epub 2017 Jun 8. PMID: 28603062.
- [148] Rychik J, Veldtman G, Rand E, Russo P, Rome JJ, Krok K, et al. The precarious state of the liver after a Fontan operation: summary of a multidisciplinary symposium. *Pediatr Cardiol* 2012 Oct;33(7):1001–1012. <https://doi.org/10.1007/s00246-012-0315-7>. Epub 2012 Apr 26. PMID: 22534759; PMCID: PMC3442163.
- [149] Di Maria MV, Brown DW, Cetta F, Ginde S, Goldberg D, Menon SC, et al. Surveillance testing and preventive care after fontan operation: a multi-institutional survey. *Pediatr Cardiol* 2019 Jan;40(1):110–115. <https://doi.org/10.1007/s00246-018-1966-9>. Epub 2018 Aug 29. PMID: 30159585.
- [150] Téllez L, Rodríguez de Santiago E, Albillos A. Fontan-associated liver disease: pathophysiology, staging, and management. *Semin Liver Dis* 2021 Nov;41(4):538–550. <https://doi.org/10.1055/s-0041-1732355>. Epub 2021 Aug 16. PMID: 34399435.
- [151] Borquez AA, Silva-Sepulveda J, Lee JW, Vavinskaya V, Vodkin I, El-Sabroun H, et al. Transjugular liver biopsy for Fontan associated liver disease surveillance: technique, outcomes and hemodynamic correlation. *Int J Cardiol* 2021 Apr 1;328:83–88. <https://doi.org/10.1016/j.ijcard.2020.11.037>. Epub 2020 Dec 2. PMID: 33278420.
- [152] Bedossa P, Dargère D, Paradis V. Sampling variability of liver fibrosis in chronic hepatitis C. *Hepatology* 2003 Dec;38(6):1449–1457. <https://doi.org/10.1016/j.hep.2003.09.022>. PMID: 14647056.
- [153] Srinivasan A, Guzman AK, Rand EB, Rychik J, Goldberg DJ, Russo PA, et al. Percutaneous liver biopsy in Fontan patients. *Pediatr Radiol* 2019 Mar;49(3):342–350. <https://doi.org/10.1007/s00247-018-4311-9>. Epub 2018 Nov 30. PMID: 30506328.
- [154] Hilscher MB, Johnson JN, Cetta F, Driscoll DJ, Poterucha JJ, Sanchez W, et al. Surveillance for liver complications after the Fontan procedure. *Congenit Heart Dis* 2017 Mar;12(2):124–132. <https://doi.org/10.1111/chd.12446>. Epub 2017 Jan 31. PMID: 28140526.
- [155] de Franchis R, Bosch J, Garcia-Tsao G, Reiberger T, Ripoll C, Baveno VII Faculty. Baveno VII - renewing consensus in portal hypertension. *J Hepatol* 2022 Apr;76(4):959–974. <https://doi.org/10.1016/j.jhep.2021.12.022>. Epub 2021 Dec 30. Erratum in: *J Hepatol*. 2022 Apr 14;: PMID: 35120736.

- [156] Egbe AC, Miranda WR, Veldtman GR, Graham RP, Kamath PS. Hepatic venous pressure gradient in fontan physiology has limited diagnostic and prognostic significance. *CJC Open* 2020 May 4;2(5):360–364. <https://doi.org/10.1016/j.cjco.2020.04.011>. PMID: 32995721; PMCID: PMC7499375.
- [157] Cho Y, Kabata D, Ehara E, Yamamoto A, Mizuochi T, Mushiaki S, et al. Assessing liver stiffness with conventional cut-off values overestimates liver fibrosis staging in patients who received the Fontan procedure. *Hepatology* 2021 May;51(5):593–602. <https://doi.org/10.1111/hepr.13627>. Epub 2021 Mar 6. PMID: 33677839.
- [158] Hsia TY, Khambadkone S, Deanfield JE, Taylor JF, Migliavacca F, De Leval MR. Subdiaphragmatic venous hemodynamics in the Fontan circulation. *J Thorac Cardiovasc Surg* 2001 Mar;121(3):436–447. <https://doi.org/10.1067/mtc.2001.112527>. PMID: 11241078.
- [159] Lubert AM, Alsaied T, Trout AT, Dillman JR, Palermo JJ, Eichelbrenner F, et al. Developing an adolescent and adult fontan management programme. *Cardiol Young* 2022 Feb;32(2):230–235. <https://doi.org/10.1017/S104795112100175X>. Epub 2021 May 10. PMID: 33966676.
- [160] Kaulitz R, Haber P, Sturm E, Schäfer J, Hofbeck M. Serial evaluation of hepatic function profile after Fontan operation. *Herz* 2014 Feb;39(1):98–104. <https://doi.org/10.1007/s00059-013-3811-5>. Epub 2013 May 8. PMID: 23649317.
- [161] Emamaullee J, Khan S, Weaver C, Goldbeck C, Yanni G, Kohli R, et al. Non-invasive biomarkers of Fontan-associated liver disease. *JHEP Rep* 2021 Sep 14;3(6):100362. <https://doi.org/10.1016/j.jhepr.2021.100362>. PMID: 34693238; PMCID: PMC8517550.
- [162] Smaś-Suska M, Skubera M, Wilkosz T, Weryński P, Kołcz J, Olszowska M, et al. Noninvasive assessment of liver status in adult patients after the Fontan procedure. *Pol Arch Intern Med* 2019 Mar 29;129(3):181–188. <https://doi.org/10.20452/pamw.4452>. Epub 2019 Feb 19. PMID: 30778020.
- [163] Zafar F, Lubert AM, Trout AT, Katz DA, Palermo JJ, Opatowsky AR, et al. Abdominal CT and MRI findings of portal hypertension in children and adults with fontan circulation. *Radiology* 2022 Jun;303(3):557–565. <https://doi.org/10.1148/radiol.211037>. Epub 2022 Mar 15. PMID: 35289663.
- [164] Sessa A, Allaire M, Lebray P, Medmoun M, Tiritilli A, Iaria P, et al. From congestive hepatopathy to hepatocellular carcinoma, how can we improve patient management? *JHEP Rep* 2021 Jan 27;3(2):100249. <https://doi.org/10.1016/j.jhepr.2021.100249>. PMID: 33665589; PMCID: PMC7902554.
- [165] Opatowsky AR, Carazo M, Singh MN, Dimopoulos K, Cardona-Estrada DA, Elantably A, et al. Creatinine versus cystatin C to estimate glomerular filtration rate in adults with congenital heart disease: results of the Boston Adult Congenital Heart Disease Biobank. *Am Heart J* 2019 Aug;214:142–155. <https://doi.org/10.1016/j.ahj.2019.04.018>. Epub 2019 May 22. PMID: 31203159.
- [166] Meadows J, Jenkins K. Protein-losing enteropathy: integrating a new disease paradigm into recommendations for prevention and treatment. *Cardiol Young* 2011 Aug;21(4):363–377. <https://doi.org/10.1017/S1047951111000102>. Epub 2011 Feb 25. PMID: 21349233.
- [167] Ofei SY, Texter K, Garipey C, Smith S, Zaidi AN, Phelps C. Pediatric fontan associated liver disease: non-invasive evaluation with serologic markers and acoustic radiation force impulse (ARFI) elastography. *Prog Pediatr Cardiol* 2019 Jun;53:21–27. <https://doi.org/10.1016/j.ppedcard.2018.09.004>. Epub 2018 Oct 6. PMID: 32818014; PMCID: PMC7430913.
- [168] Byrne RD, Weingarten AJ, Clark DE, Huang S, Perri RE, Scanga AE, et al. More than the heart: hepatic, renal, and cardiac dysfunction in adult Fontan patients. *Congenit Heart Dis* 2019 Sep;14(5):765–771. <https://doi.org/10.1111/chd.12820>. Epub 2019 Jul 7. PMID: 31282062.
- [169] An HS, Choi YH, Song MK, Lee SY, Kim GB, Bae EJ. Early development of hepatic fibrosis after Fontan procedure: a non-invasive study of a sub-clinical liver disease. *Int J Cardiol* 2020 Dec 1;320:64–69. <https://doi.org/10.1016/j.ijcard.2020.08.009>. Epub 2020 Aug 13. PMID: 32800914.
- [170] Ackerman T, Geerts A, Van Vlierberghe H, De Backer J, François K. Hepatic changes in the fontan circulation: identification of liver dysfunction and an attempt to streamline follow-up screening. *Pediatr Cardiol* 2018 Dec;39(8):1604–1613. <https://doi.org/10.1007/s00246-018-1937-1>. Epub 2018 Jul 21. PMID: 30032312.
- [171] Sethasathien S, Silvilairat S, Sittiwangkul R, Makonkawkeyoon K, Pongprot Y. Associated factors of liver disease after fontan operation in relation to ultrasound liver elastography. *Pediatr Cardiol* 2020 Dec;41(8):1639–1644. <https://doi.org/10.1007/s00246-020-02422-y>. Epub 2020 Aug 1. PMID: 32740670.
- [172] Shimizu M, Miyamoto K, Nishihara Y, Izumi G, Sakai S, Inai K, et al. Risk factors and serological markers of liver cirrhosis after Fontan procedure. *Heart Vessels* 2016 Sep;31(9):1514–1521. <https://doi.org/10.1007/s00380-015-0743-4>. Epub 2015 Sep 19. PMID: 26386570.
- [173] Evans WN, Acherman RJ, Ciccolo ML, Carrillo SA, Galindo A, Rothman A, et al. MELD-XI scores correlate with post-fontan hepatic biopsy fibrosis scores. *Pediatr Cardiol* 2016 Oct;37(7):1274–1277. <https://doi.org/10.1007/s00246-016-1428-1>. Epub 2016 Jun 14. PMID: 27300556.
- [174] Guha IN, Bokhandi S, Ahmad Z, Sheron N, Cope R, Marshall C, et al. Structural and functional uncoupling of liver performance in the Fontan circulation. *Int J Cardiol* 2013 Mar 20;164(1):77–81. <https://doi.org/10.1016/j.ijcard.2011.06.062>. Epub 2011 Jul 23. PMID: 21788088.
- [175] Osawa Y, Kawai H, Tsunoda T, Komatsu H, Okawara M, Tsutsui Y, et al. Cluster of differentiation 44 promotes liver fibrosis and serves as a biomarker in congestive hepatopathy. *Hepatology* 2021 Apr 8;5(8):1437–1447. <https://doi.org/10.1002/hep4.1721>. PMID: 34430787; PMCID: PMC8369942.
- [176] Wallihan DB, Podberesky DJ. Hepatic pathology after Fontan palliation: spectrum of imaging findings. *Pediatr Radiol* 2013 Mar;43(3):330–338. <https://doi.org/10.1007/s00247-012-2531-y>. Epub 2012 Oct 6. PMID: 23052733.
- [177] Najashi KA, Najashi NA, Ahmed T, Abdelnaeem R, Alolit S, Zuaybir AA, et al. The prognostic role of liver volumetry in Fontan patients. *Cardiol Young* 2022 Oct 19:1–6. <https://doi.org/10.1017/S1047951122002992>. Epub ahead of print. PMID: 36258282.
- [178] Bae JM, Jeon TY, Kim JS, Kim S, Hwang SM, Yoo SY, et al. Fontan-associated liver disease: spectrum of US findings. *Eur J Radiol* 2016 Apr;85(4):850–856. <https://doi.org/10.1016/j.ejrad.2016.02.002>. Epub 2016 Feb 4. PMID: 26971434.
- [179] Téllez L, Rodríguez de Santiago E, Minguez B, Payance A, Clemente A, Baiges A, et al. VALDIG an EASL consortium. Prevalence, features and predictive factors of liver nodules in Fontan surgery patients: the VALDIG Fonliver prospective cohort. *J Hepatol* 2020 Apr;72(4):702–710. <https://doi.org/10.1016/j.jhep.2019.10.027>. Epub 2019 Nov 11. PMID: 31726116.
- [180] Thrane KJ, Müller LSO, Suther KR, Thomassen KS, Holmström H, Thaulow E, et al. Spectrum of Fontan-associated liver disease assessed by MRI and US in young adolescents. *Abdom Radiol (NY)* 2021 Jul;46(7):3205–3216. <https://doi.org/10.1007/s00261-021-02994-0>. Epub 2021 Mar 10. PMID: 33688987; PMCID: PMC8215034.
- [181] De Bruyne R, Vandekerckhove K, Van Overschelde H, Hendrick F, Vande Walle C, De Groot K, et al. Non-invasive assessment of liver abnormalities in pediatric Fontan patients. *Eur J Pediatr* 2022 Jan;181(1):159–169. <https://doi.org/10.1007/s00431-021-04163-3>. Epub 2021 Jul 6. PMID: 34231051.
- [182] Song J, Kim K, Huh J, Kang IS, Kim SH, Yang JH, et al. Imaging assessment of hepatic changes after fontan surgery. *Int Heart J* 2018 Sep 26;59(5):1008–1014. <https://doi.org/10.1536/ihj.17-349>. Epub 2018 Aug 29. PMID: 30158375.
- [183] Kutty S, Rathod RH, Danford DA, Celermajer DS. Role of imaging in the evaluation of single ventricle with the Fontan palliation. *Heart* 2016 Feb;102(3):174–183. <https://doi.org/10.1136/heartjnl-2015-308298>. Epub 2015 Nov 13. PMID: 26567230.
- [184] Chavhan GB, Farras Roca L, Coblenz AC. Liver magnetic resonance imaging: how we do it. *Pediatr Radiol* 2022 Feb;52(2):167–176. <https://doi.org/10.1007/s00247-021-05053-4>. Epub 2021 Apr 2. PMID: 33797616.
- [185] Wolff D, van Melle JP, Dijkstra H, Bartelds B, Willems TP, Hillege H, et al. The Fontan circulation and the liver: a magnetic resonance diffusion-weighted imaging study. *Int J Cardiol* 2016 Jan 1;202:595–600. <https://doi.org/10.1016/j.ijcard.2015.09.088>. Epub 2015 Sep 28. PMID: 26447669.
- [186] Dillman JR, Trout AT, Alsaied T, Gupta A, Lubert AM. Imaging of Fontan-associated liver disease. *Pediatr Radiol* 2020 Oct;50(11):1528–1541. <https://doi.org/10.1007/s00247-020-04776-0>. Epub 2020 Aug 18. PMID: 32809067.
- [187] Navallas M, Yoo SJ, Chavhan GB, Amirabadi A, Ling SC, Seed M, et al. Semiquantitative characterization of dynamic magnetic resonance perfusion of the liver in pediatric Fontan patients. *Pediatr Radiol* 2022 Mar;52(3):483–492. <https://doi.org/10.1007/s00247-021-05221-6>. Epub 2021 Dec 2. PMID: 34854967.
- [188] Kim TH, Yang HK, Jang HJ, Yoo SJ, Khalili K, Kim TK. Abdominal imaging findings in adult patients with Fontan circulation. *Insights Imaging* 2018 Jun;9(3):357–367. <https://doi.org/10.1007/s13244-018-0609-2>. Epub 2018 Apr 5. PMID: 29623675; PMCID: PMC5991003.
- [189] de Lange C, Reichert MJE, Pagano JJ, Seed M, Yoo SJ, Broberg CS, et al. Increased extracellular volume in the liver of pediatric Fontan patients. *J Cardiovasc Magn Reson* 2019 Jul 15;21(1):39. <https://doi.org/10.1186/s12968-019-0545-4>. PMID: 31303178; PMCID: PMC6628496.
- [190] Ramachandran P, Serai SD, Veldtman GR, Lang SM, Mazur W, Trout AT, et al. Assessment of liver T1 mapping in fontan patients and its correlation

- with magnetic resonance elastography-derived liver stiffness. *Abdom Radiol (NY)* 2019 Jul;44(7):2403–2408. <https://doi.org/10.1007/s00261-019-01990-9>. PMID: 30903232.
- [191] Kazour I, Serai SD, Xanthakos SA, Fleck RJ. Using T1 mapping in cardiovascular magnetic resonance to assess congestive hepatopathy. *Abdom Radiol (NY)* 2018 Oct;43(10):2679–2685. <https://doi.org/10.1007/s00261-018-1528-x>. PMID: 29500649; PMCID: PMC6120811.
- [192] DiPaola FW, Schumacher KR, Goldberg CS, Friedland-Little J, Parameswaran A, Dillman JR. Effect of Fontan operation on liver stiffness in children with single ventricle physiology. *Eur Radiol* 2017 Jun;27(6):2434–2442. <https://doi.org/10.1007/s00330-016-4614-x>. Epub 2016 Oct 17. PMID: 27752831.
- [193] Deorsola L, Aidala E, Casciaro MT, Valori A, Agnoletti G, Pace Napoleone C. Liver stiffness modifications shortly after total cavopulmonary connection. *Interact Cardiovasc Thorac Surg* 2016 Oct;23(4):513–518. <https://doi.org/10.1093/icvts/ivw186>. Epub 2016 Jun 16. PMID: 27316659.
- [194] Chen B, Schreiber RA, Human DG, Potts JE, Guttman OR. Assessment of liver stiffness in pediatric fontan patients using transient elastography. *Can J Gastroenterol Hepatol* 2016;2016:7125193. <https://doi.org/10.1155/2016/7125193>. Epub 2016 Aug 30. PMID: 27656638; PMCID: PMC5021462.
- [195] Kutty SS, Peng Q, Danford DA, Fletcher SE, Perry D, Talmon GA, et al. Liver Adult-Pediatric-Congenital-Heart-Disease Dysfunction Study (LADS) Group. Increased hepatic stiffness as consequence of high hepatic after-load in the Fontan circulation: a vascular Doppler and elastography study. *Hepatology* 2014 Jan;59(1):251–260. <https://doi.org/10.1002/hep.26631>. Epub 2013 Nov 19. PMID: 23913702.
- [196] Sugimoto M, Oka H, Kajihama A, Nakau K, Kuwata S, Kurishima C, et al. Non-invasive assessment of liver fibrosis by magnetic resonance elastography in patients with congenital heart disease undergoing the Fontan procedure and intracardiac repair. *J Cardiol* 2016 Sep;68(3):202–208. <https://doi.org/10.1016/j.jicc.2016.05.016>. Epub 2016 Jul 2. PMID: 27381938.
- [197] Melero-Ferrer JL, Osa-Sáez A, Buendía-Fuentes F, Ballesta-Cuñat A, Flors L, Rodríguez-Serrano M, et al. Fontan circulation in adult patients: acoustic radiation force impulse elastography as a useful tool for liver assessment. *World J Pediatr Congenit Heart Surg* 2014 Jul;5(3):365–371. <https://doi.org/10.1177/2150135114530172>. PMID: 24958037.
- [198] de Lange C. Imaging of complications following Fontan circulation in children - diagnosis and surveillance. *Pediatr Radiol* 2020 Sep;50(10):1333–1348. <https://doi.org/10.1007/s00247-020-04682-5>. Epub 2020 May 28. Erratum in: *Pediatr Radiol*. 2020 Aug 20; PMID: 32468285; PMCID: PMC7445207.
- [199] Trout AT, Sheridan RM, Serai SD, Xanthakos SA, Su W, Zhang B, et al. Diagnostic performance of MR elastography for liver fibrosis in children and young adults with a spectrum of liver diseases. *Radiology* 2018 Jun;287(3):824–832. <https://doi.org/10.1148/radiol.2018172099>. Epub 2018 Feb 22. PMID: 29470938.
- [200] Yoo BW, Choi JY, Eun LY, Park HK, Park YH, Kim SU. Congestive hepatopathy after Fontan operation and related factors assessed by transient elastography. *J Thorac Cardiovasc Surg* 2014 Oct;148(4):1498–1505. <https://doi.org/10.1016/j.jtcvs.2014.04.010>. Epub 2014 Apr 13. PMID: 24823284.
- [201] Evans WN, Acherman RJ, Ciccolo ML, Carrillo SA, Galindo A, Rothman A, et al. A composite noninvasive index correlates with liver fibrosis scores in post-Fontan patients: preliminary findings. *Congenit Heart Dis* 2018 Jan;13(1):38–45. <https://doi.org/10.1111/chd.12558>. Epub 2017 Dec 1. PMID: 29194972.
- [202] Schachter JL, Patel M, Horton SR, Mike Devane A, Ewing A, Abrams GA. FibroSURE and elastography poorly predict the severity of liver fibrosis in Fontan-associated liver disease. *Congenit Heart Dis* 2018 Sep;13(5):764–770. <https://doi.org/10.1111/chd.12650>. Epub 2018 Aug 12. PMID: 30101472.
- [203] Wu FM, Opatowsky AR, Raza R, Harney S, Ukomadu C, Landzberg MJ, et al. Transient elastography may identify Fontan patients with unfavorable hemodynamics and advanced hepatic fibrosis. *Congenit Heart Dis* 2014 Sep-Oct;9(5):438–447. <https://doi.org/10.1111/chd.12159>. Epub 2014 Jan 13. PMID: 24418160.
- [204] Rathgeber SL, Harris KC. Fontan-associated liver disease: evidence for early surveillance of liver health in pediatric fontan patients. *Can J Cardiol* 2019 Feb;35(2):217–220. <https://doi.org/10.1016/j.cjca.2018.11.019>. Epub 2018 Nov 29. PMID: 30760429.
- [205] Shin YR, Kim SU, Lee S, Choi JY, Park HK, Yoo JE, et al. Noninvasive surrogates are poor predictors of liver fibrosis in patients with Fontan circulation. *J Thorac Cardiovasc Surg* 2022 Oct;164(4):1176–1185.e3. <https://doi.org/10.1016/j.jtcvs.2021.12.028>. Epub 2021 Dec 24. PMID: 35034765.
- [206] Poterucha JT, Johnson JN, Qureshi MY, O'Leary PW, Kamath PS, Lennon RJ, et al. Magnetic resonance elastography: a novel technique for the detection of hepatic fibrosis and hepatocellular carcinoma after the fontan operation. *Mayo Clin Proc* 2015 Jul;90(7):882–894. <https://doi.org/10.1016/j.mayocp.2015.04.020>. Epub 2015 Jun 6. PMID: 26059757; PMCID: PMC4500048.
- [207] Rathgeber SL, Guttman OR, Lee AF, Voss C, Hemphill NM, Schreiber RA, et al. Fontan-associated liver disease: spectrum of disease in children and adolescents. *J Am Heart Assoc* 2020 Jan 7;9(1):e012529. <https://doi.org/10.1161/JAHA.119.012529>. Epub 2020 Jan 4. PMID: 31902322; PMCID: PMC6988152.
- [208] Friedrich-Rust M, Koch C, Rentzsch A, Sarrazin C, Schwarz P, Herrmann E, et al. Noninvasive assessment of liver fibrosis in patients with Fontan circulation using transient elastography and biochemical fibrosis markers. *J Thorac Cardiovasc Surg* 2008 Mar;135(3):560–567. <https://doi.org/10.1016/j.jtcvs.2007.09.039>. PMID: 18329470.
- [209] Serai SD, Wallihan DB, Venkatesh SK, Ehman RL, Campbell KM, Sticka J, et al. Magnetic resonance elastography of the liver in patients status-post fontan procedure: feasibility and preliminary results. *Congenit Heart Dis* 2014 Jan-Feb;9(1):7–14. <https://doi.org/10.1111/chd.12144>. Epub 2013 Oct 17. PMID: 24134059; PMCID: PMC4584140.
- [210] Chemello L, Padalino M, Zanon C, Benvenuto ' L, Biffanti R, Mancuso D, et al. Role of transient elastography to stage fontan-associated liver disease (FALD) in adults with single ventricle congenital heart disease correction. *J Cardiovasc Dev Dis* 2021 Sep 23;8(10):117. <https://doi.org/10.3390/jcdd8100117>. PMID: 34677186; PMCID: PMC8537825.
- [211] Alsaied T, Possner M, Lubert AM, Trout AT, Szugye C, Palermo JJ, et al. Relation of magnetic resonance elastography to fontan failure and portal hypertension. *Am J Cardiol* 2019 Nov 1;124(9):1454–1459. <https://doi.org/10.1016/j.amjcard.2019.07.052>. Epub 2019 Aug 7. PMID: 31474329.
- [212] Diaz ES, Dillman JR, Veldtman GR, Trout AT. MRI measured liver stiffness does not predict focal liver lesions after the Fontan operation. *Pediatr Radiol* 2019 Jan;49(1):99–104. <https://doi.org/10.1007/s00247-018-4264-z>. Epub 2018 Sep 29. PMID: 30269160.
- [213] Egbe A, Miranda WR, Connolly HM, Khan AR, Al-Otaibi M, Venkatesh SK, et al. Temporal changes in liver stiffness after Fontan operation: results of serial magnetic resonance elastography. *Int J Cardiol* 2018 May 1;258:299–304. <https://doi.org/10.1016/j.ijcard.2018.01.108>. Epub 2018 Feb 9. PMID: 29433966.
- [214] Brayer SW, Zafar F, Lubert AM, Trout AT, Palermo JJ, Opatowsky AR, et al. Relation of magnetic resonance elastography to fontan circulatory failure in a cohort of pediatric and adult patients. *Pediatr Cardiol* 2021 Dec;42(8):1871–1878. <https://doi.org/10.1007/s00246-021-02707-w>. Epub 2021 Aug 26. PMID: 34448042.
- [215] Wallihan DB, Podberesky DJ, Marino BS, Sticka JS, Serai S. Relationship of MR elastography determined liver stiffness with cardiac function after Fontan palliation. *J Magn Reson Imaging* 2014 Dec;40(6):1328–1335. <https://doi.org/10.1002/jmri.24496>. Epub 2013 Nov 8. PMID: 24408379.
- [216] Nedredal GI, Yin M, McKenzie T, Lillegard J, Luebke-Wheeler J, Talwalkar J, et al. Portal hypertension correlates with splenic stiffness as measured with MR elastography. *J Magn Reson Imaging* 2011 Jul;34(1):79–87. <https://doi.org/10.1002/jmri.22610>. Epub 2011 May 23. PMID: 21608066; PMCID: PMC3121904.
- [217] Colecchia A, Ravaioli F, Marasco G, Colli A, Dajti E, Di Biase AR, et al. A combined model based on spleen stiffness measurement and Baveno VI criteria to rule out high-risk varices in advanced chronic liver disease. *J Hepatol* 2018 Aug;69(2):308–317. <https://doi.org/10.1016/j.jhep.2018.04.023>. Epub 2018 May 3. PMID: 29729368.
- [218] Procopet B, Berzigotti A, Abroades JG, Turon F, Hernandez-Gea V, García-Pagán JC, et al. Real-time shear-wave elastography: applicability, reliability and accuracy for clinically significant portal hypertension. *J Hepatol* 2015 May;62(5):1068–1075. <https://doi.org/10.1016/j.jhep.2014.12.007>. Epub 2014 Dec 13. PMID: 25514554.
- [219] Serai SD, Elsingery MM, Hartung EA, Otero HJ. Liver and spleen volume and stiffness in patients post-Fontan procedure and patients with ARPKD compared to normal controls. *Clin Imaging* 2022 Sep;89:147–154. <https://doi.org/10.1016/j.clinimag.2022.06.022>. Epub 2022 Jul 8. PMID: 35835018.
- [220] Padalino MA, Chemello L, Cavalletto L, Angelini A, Fedrigo M. Prognostic value of liver and spleen stiffness in patients with fontan associated liver disease (FALD): a case series with histopathologic comparison.

- J Cardiovasc Dev Dis 2021 Mar 16;8(3):30. <https://doi.org/10.3390/jcdd8030030>. PMID: 33809668; PMCID: PMC8002245.
- [221] Aliyev B, Bayramoglu Z, Nişli K, Omeroglu RE, Dindar A. Quantification of hepatic and splenic stiffness after fontan procedure in children and clinical implications. *Ultrasound Q* 2020 Dec;36(4):350–356. <https://doi.org/10.1097/RUQ.0000000000000541>. PMID: 33298772.
- [222] Simmons MA, Revzin M, To U, Liapakis A, Fahey J, Elder RW. A window into portal hemodynamics in adult fontan patients? *Int J Cardiol* 2021 Jan 15;323:61–64. <https://doi.org/10.1016/j.ijcard.2020.09.047>. Epub 2020 Sep 24. PMID: 32979426.
- [223] Daniels CJ, Bradley EA, Landzberg MJ, Aboulhosn J, Beekman 3rd RH, Book W, et al. Fontan-associated liver disease: proceedings from the American college of Cardiology stakeholders meeting, October 1 to 2, 2015, Washington DC. *J Am Coll Cardiol* 2017 Dec 26;70(25):3173–3194. <https://doi.org/10.1016/j.jacc.2017.10.045>. PMID: 29268929.
- [224] Hebson CL, McCabe NM, Elder RW, Mahle WT, McConnell M, Kogon BE, et al. Hemodynamic phenotype of the failing Fontan in an adult population. *Am J Cardiol* 2013 Dec 15;112(12):1943–1947. <https://doi.org/10.1016/j.amjcard.2013.08.023>. Epub 2013 Sep 25. PMID: 24075283; PMCID: PMC4505550.
- [225] Madala S, MacDougall K, Polavarapu A, Gurala D, Gumaste V, Morvillo G. An emphasis on screening to detect liver cirrhosis and hepatocellular carcinoma in patients having undergone the fontan procedure in early childhood. *Case Rep Gastroenterol* 2020 Nov 23;14(3):615–623. <https://doi.org/10.1159/000510332>. PMID: 33362449; PMCID: PMC7747073.
- [226] Mair DD, Hagler DJ, Julsrud PR, Puga FJ, Schaff HV, Danielson GK. Early and late results of the modified Fontan procedure for double-inlet left ventricle: the Mayo Clinic experience. *J Am Coll Cardiol* 1991 Dec;18(7):1727–1732. [https://doi.org/10.1016/0735-1097\(91\)90511-7](https://doi.org/10.1016/0735-1097(91)90511-7). PMID: 1720436.
- [227] Téllez L, Guerrero A, Albillos A. Medical approach to fontan patients. In: de Franchis R, editor. *Portal hypertension VII*. Cham: Springer; 2022. [https://doi.org/10.1007/978-3-031-08552-9\\_58](https://doi.org/10.1007/978-3-031-08552-9_58).
- [228] Velupula M, Sheron N, Guha N, Salmon T, Hacking N, Veldtman GR. Direct measurement of porto-systemic gradient in a failing Fontan circulation. *Congenit Heart Dis* 2011 Mar-Apr;6(2):175–178. <https://doi.org/10.1111/j.1747-0803.2010.00451.x>. Epub 2011 Mar 1. PMID: 21356034.
- [229] Bradley E, Hendrickson B, Daniels C. Fontan liver disease: review of an emerging epidemic and management options. *Curr Treat Options Cardiovasc Med* 2015 Nov;17(11):51. <https://doi.org/10.1007/s11936-015-0412-z>. PMID: 26407544; PMCID: PMC5831136.
- [230] Miranda WR, Borlaug BA, Hagler DJ, Connolly HM, Egbe AC. Haemodynamic profiles in adult Fontan patients: associated haemodynamics and prognosis. *Eur J Heart Fail* 2019 Jun;21(6):803–809. <https://doi.org/10.1002/ehfj.1365>. Epub 2019 Jan 23. PMID: 30672076.
- [231] Runyon BA, Montano AA, Akriviadis EA, Antillon MR, Irving MA, McHutchison JG. The serum-ascites albumin gradient is superior to the exudate-transudate concept in the differential diagnosis of ascites. *Ann Intern Med* 1992 Aug 1;117(3):215–220. <https://doi.org/10.7326/0003-4819-117-3-215>. PMID: 1616215.
- [232] Asrani SK, Asrani NS, Freese DK, Phillips SD, Warnes CA, Heimbach J, et al. Congenital heart disease and the liver. *Hepatology* 2012 Sep;56(3):1160–1169. <https://doi.org/10.1002/hep.25692>. Epub 2012 Aug 2. PMID: 22383293.
- [233] Biggins SW, Angeli P, Garcia-Tsao G, Ginès P, Ling SC, Nadim MK, et al. Diagnosis, evaluation, and management of ascites, spontaneous bacterial peritonitis and hepatorenal syndrome: 2021 practice guidance by the American association for the study of liver diseases. *Hepatology* 2021 Aug;74(2):1014–1048. <https://doi.org/10.1002/hep.31884>. PMID: 33942342.
- [234] Runyon BA. Cardiac ascites: a characterization. *J Clin Gastroenterol* 1988 Aug;10(4):410–412. <https://doi.org/10.1097/00004836-198808000-00013>. PMID: 3418089.
- [235] Farias AQ, Silvestre OM, Garcia-Tsao G, da Costa Seguro LF, de Campos Mazo DF, Bacal F, et al. Serum B-type natriuretic peptide in the initial workup of patients with new onset ascites: a diagnostic accuracy study. *Hepatology* 2014 Mar;59(3):1043–1051. <https://doi.org/10.1002/hep.26643>. Epub 2014 Jan 13. Erratum in: *hepatology*. 2014 May;59(5):2058. PMID: 23907731.
- [236] European Association for the Study of the Liver. Electronic address: easloffice@easloffice.eu; European Association for the Study of the Liver. *EASL Clinical Practice Guidelines on nutrition in chronic liver disease*. *J Hepatol* 2019 Jan;70(1):172–193. <https://doi.org/10.1016/j.jhep.2018.06.024>. Epub 2018 Aug 23. PMID: 30144956; PMCID: PMC6657019.
- [237] European Association for the Study of the Liver. Electronic address: easloffice@easloffice.eu; European association for the study of the liver. *EASL clinical practice guidelines for the management of patients with decompensated cirrhosis*. *J Hepatol* 2018 Aug;69(2):406–460. <https://doi.org/10.1016/j.jhep.2018.03.024>. Epub 2018 Apr 10. Erratum in: *J Hepatol*. 2018 Nov;69(5):1207. PMID: 29653741.
- [238] Ephrem G, Hebson C, John A, Moore E, Jokhadar M, Ford R, et al. Frontiers in Fontan failure: innovation and improving outcomes: a conference summary. *Congenit Heart Dis* 2019 Mar;14(2):128–137. <https://doi.org/10.1111/chd.12685>. Epub 2018 Oct 20. PMID: 30343507.
- [239] Ovroutski S, Ewert P, Alexi-Meskisvili V, Peters B, Hetzer R, Berger F. Dilatation and stenting of the fontan pathway: impact of the stensis treatment on chronic ascites. *J Interv Cardiol* 2008 Feb;21(1):38–43. <https://doi.org/10.1111/j.1540-8183.2007.00323.x>. Epub 2007 Dec 13. PMID: 18093098.
- [240] Itkin M, Nadolski GJ. Modern techniques of lymphangiography and interventions: current status and future development. *Cardiovasc Intervent Radiol* 2018 Mar;41(3):366–376. <https://doi.org/10.1007/s00270-017-1863-2>. Epub 2017 Dec 18. PMID: 29256071.
- [241] Hraska V, Mitchell ME, Woods RK, Hoffman GM, Kindel SJ, Ginde S. Innominate vein turn-down procedure for failing fontan circulation. *Semin Thorac Cardiovasc Surg Pediatr Card Surg Annu* 2020;23:34–40. <https://doi.org/10.1053/j.pcsu.2020.01.002>. PMID: 32354545.
- [242] Smith CL, Dori Y, O'Byrne ML, Glatz AC, Gillespie MJ, Rome JJ. Transcatheter thoracic duct decompression for multicompartment lymphatic failure after fontan palliation. *Circ Cardiovasc Interv* 2022 Jul;15(7):e011733. <https://doi.org/10.1161/CIRCINTERVENTIONS.121.011733>. Epub 2022 Jun 16. PMID: 35708032.
- [243] Rajpal S, Opatowsky AR, Rutherford A, Wu F. Hemodynamic effects of paracentesis in a patient with a fontan circulation. *World J Pediatr Congenit Heart Surg* 2019 May;10(3):357–359. <https://doi.org/10.1177/2150135118779351>. Epub 2018 Oct 24. PMID: 30354929.
- [244] Wu FM, Valente AM, Nigrovic PA, Rutherford AE, Singh MN. Intraoperative corticosteroids for recurrent ascites in adolescents with Fontan circulation: initial clinical experience. *J Card Surg* 2021 Feb;36(2):735–738. <https://doi.org/10.1111/jocs.15244>. Epub 2020 Dec 11. PMID: 33305839.
- [245] Koteda Y, Suda K, Kishimoto S, Iemura M. Portal-systemic encephalopathy after Fontan-type operation in patient with polysplenia syndrome. *Eur J Cardiothorac Surg* 2009 Jun;35(6):1083–1085. <https://doi.org/10.1016/j.ejcts.2009.02.043>. Epub 2009 Apr 10. PMID: 19362492.
- [246] Singh S, Roy B, Pike N, Daniel E, Ehlerl L, Lewis AB, et al. Altered brain diffusion tensor imaging indices in adolescents with the Fontan palliation. *Neuroradiology* 2019 Jul;61(7):811–824. <https://doi.org/10.1007/s00234-019-02208-x>. Epub 2019 Apr 30. PMID: 31041457; PMCID: PMC6582969.
- [247] Ricci MF, Martin BJ, Joffe AR, Dinu IA, Alton GY, Guerra GG, et al. Western Canadian complex pediatric therapies follow-up program. Deterioration of functional abilities in children surviving the fontan operation. *Cardiol Young* 2018 Jun;28(6):868–875. <https://doi.org/10.1017/S104795118000537>. Epub 2018 Apr 25. PMID: 29690942.
- [248] Miike H, Ohuchi H, Hayama Y, Isawa T, Sakaguchi H, Kurosaki K, et al. Systemic artery vasoconstrictor therapy in fontan patients with high cardiac output-heart failure: a single-center experience. *Pediatr Cardiol* 2021 Mar;42(3):700–706. <https://doi.org/10.1007/s00246-020-02532-7>. Epub 2021 Jan 8. PMID: 33416919.
- [249] Jacobs ML, Pourmoghadam KK. Thromboembolism and the role of anti-coagulation in the Fontan patient. *Pediatr Cardiol* 2007 Nov-Dec;28(6):457–464. <https://doi.org/10.1007/s00246-007-9006-1>. PMID: 17762953.
- [250] Firdouse M, Agarwal A, Chan AK, Mondal T. Thrombosis and thromboembolic complications in fontan patients: a literature review. *Clin Appl Thromb Hemost* 2014 Jul;20(5):484–492. <https://doi.org/10.1177/1076029613520464>. Epub 2014 Jan 24. PMID: 24463598.
- [251] Kaulitz R, Sieverding L, Hofbeck M. Portal vein thrombosis in Fontan-associated liver disease. *Cardiol Young* 2020 Jun;30(6):883–885. <https://doi.org/10.1017/S1047951120000992>. Epub 2020 May 14. PMID: 32406357.
- [252] Wells ML, Hough DM, Fidler JL, Kamath PS, Poterucha JT, Venkatesh SK. Benign nodules in post-Fontan livers can show imaging features considered diagnostic for hepatocellular carcinoma. *Abdom Radiol (NY)* 2017 Nov;42(11):2623–2631. <https://doi.org/10.1007/s00261-017-1181-9>. PMID: 28785785.
- [253] Horvat N, Rocha MS, Chagas AL, Oliveira BC, Pacheco MP, Binotto MA, et al. Multimodality screening of hepatic nodules in patients with congenital heart disease after fontan procedure: role of ultrasound, ARFI elastography,

- CT, and MRI. *AJR Am J Roentgenol* 2018 Dec;211(6):1212–1220. <https://doi.org/10.2214/AJR.18.19762>. Epub 2018 Sep 24. PMID: 30247977.
- [254] Bryant T, Ahmad Z, Millward-Sadler H, Burney K, Stedman B, Kendall T, et al. Arterialised hepatic nodules in the Fontan circulation: hepato-cardiac interactions. *Int J Cardiol* 2011 Sep 15;151(3):268–272. <https://doi.org/10.1016/j.ijcard.2010.05.047>. Epub 2010 Jun 16. PMID: 20557964.
- [255] Bulut OP, Romero R, Mahle WT, McConnell M, Braithwaite K, Shehata BM, et al. Magnetic resonance imaging identifies unsuspected liver abnormalities in patients after the Fontan procedure. *J Pediatr* 2013 Jul;163(1):201–206. <https://doi.org/10.1016/j.jpeds.2012.12.071>. Epub 2013 Feb 4. PMID: 23391043.
- [256] Kuwabara M, Niwa K, Toyoda T, Shirai T, Tateno S, Ohuchi H, et al. Research committee of the Japanese society of pediatric Cardiology and cardiac surgery. Liver cirrhosis and/or hepatocellular carcinoma occurring late after the fontan procedure - a nationwide survey in Japan. *Circ J* 2018 Mar 23;82(4):1155–1160. <https://doi.org/10.1253/circj.CJ-17-1053>. Epub 2018 Feb 14. PMID: 29445059.
- [257] Sempoux C, Balabaud C, Paradis V, Bioulac-Sage P. Hepatocellular nodules in vascular liver diseases. *Virchows Arch* 2018 Jul;473(1):33–44. <https://doi.org/10.1007/s00428-018-2373-6>. Epub 2018 May 26. PMID: 29804132.
- [258] Sempoux C, Paradis V, Komuta M, Wee A, Calderaro J, Balabaud C, et al. Hepatocellular nodules expressing markers of hepatocellular adenomas in Budd-Chiari syndrome and other rare hepatic vascular disorders. *J Hepatol* 2015 Nov;63(5):1173–1180. <https://doi.org/10.1016/j.jhep.2015.06.017>. Epub 2015 Jun 25. PMID: 26119687.
- [259] Yao JV, Sood S, Lokan J, Murugasu A, Grigg L, Zentner D. Hepatic adenoma masquerading as a hepatocellular carcinoma in a patient with a Fontan procedure on the oral contraceptive pill. *Intern Med J* 2021 Apr;51(4):613–615. <https://doi.org/10.1111/imj.15267>. PMID: 33890370.
- [260] Babaoglu K, Binnetoglu FK, Aydoğan A, Altun G, Gürbüz Y, Inan N, et al. Hepatic adenomatosis in a 7-year-old child treated earlier with a Fontan procedure. *Pediatr Cardiol* 2010 Aug;31(6):861–864. <https://doi.org/10.1007/s00246-010-9685-x>. Epub 2010 Mar 4. PMID: 20204345.
- [261] Asrani SK, Warnes CA, Kamath PS. Hepatocellular carcinoma after the Fontan procedure. *N Engl J Med* 2013 May 2;368(18):1756–1757. <https://doi.org/10.1056/NEJMc1214222>. PMID: 23635071.
- [262] Roncalli M, Roz E, Coggi G, Di Rocco MG, Bossi P, Minola E, et al. The vascular profile of regenerative and dysplastic nodules of the cirrhotic liver: implications for diagnosis and classification. *Hepatology* 1999 Nov;30(5):1174–1178. <https://doi.org/10.1002/hep.510300507>. PMID: 10534338.
- [263] Sethasathien S, Silvilairat S, Sittiwangkul R, Makonkawkeyoon K, Pongprot Y, Woragidpoonpol S. Liver nodules after the Fontan operation: role of the computerised tomography scan. *Cardiol Young* 2022 Jun;32(6):930–935. <https://doi.org/10.1017/S1047951121003309>. Epub 2021 Aug 9. PMID: 34365989.
- [264] Panvini N, Dioguardi Borgia M, Sartoris R, Maino C, Van Wettere M, Plessier A, et al. MR imaging features and long-term evolution of benign focal liver lesions in Budd-Chiari syndrome and Fontan-associated liver disease. *Diagn Interv Imaging* 2022 Feb;103(2):111–120. <https://doi.org/10.1016/j.diii.2021.09.001>. Epub 2021 Oct 19. PMID: 34654671.
- [265] Rodríguez De Santiago E, Téllez L, Guerrero A, Albillos A. Hepatocellular carcinoma after Fontan surgery: a systematic review. *Hepatol Res* 2021 Jan;51(1):116–134. <https://doi.org/10.1111/hepr.13582>. Epub 2020 Dec 12. PMID: 33037858.
- [266] Çolaklar A, Lehnert SJ, Tirkes T. Benign hepatic nodules mimicking hepatocellular carcinoma in the setting of fontan-associated liver disease: a case report. *Euroasian J Hepatogastroenterol* 2020 Jan-Jun;10(1):42–44. <https://doi.org/10.5005/jp-journals-10018-1315>. PMID: 32742972; PMCID: PMC7376597.
- [267] Yang HK, Jang HJ, Khalili K, Wald RM, Yoo SJ, Kim TK. CT and MR imaging findings of the livers in adults with Fontan palliation: an observational study. *Abdom Radiol (NY)* 2020 Jan;45(1):188–202. <https://doi.org/10.1007/s00261-019-02119-8>. PMID: 31471707.
- [268] Haeffele C, Aggarwal A, Lutchman G, Veldtman GR, Wu FM, Lui GK. Fontan liver lesions: not always HCC. *JACC Case Rep* 2019 Aug 21;1(2):175–178. <https://doi.org/10.1016/j.jaccas.2019.05.031>. PMID: 34316779; PMCID: PMC8301494.
- [269] Possner M, Gordon-Walker T, Egbe AC, Poterucha JT, Warnes CA, Connolly HM, et al. Hepatocellular carcinoma and the Fontan circulation: clinical presentation and outcomes. *Int J Cardiol* 2021 Jan 1;322:142–148. <https://doi.org/10.1016/j.ijcard.2020.08.057>. Epub 2020 Aug 21. PMID: 32828959.
- [270] Egbe AC, Poterucha JT, Warnes CA, Connolly HM, Baskar S, Ginde S, et al. Hepatocellular carcinoma after fontan operation: multicenter case series. *Circulation* 2018 Aug 14;138(7):746–748. <https://doi.org/10.1161/CIRCULATIONAHA.117.032717>. PMID: 30359134.
- [271] Nii M, Inuzuka R, Inai K, Shimada E, Shinohara T, Kogiso T, et al. Incidence and expected probability of liver cirrhosis and hepatocellular carcinoma after fontan operation. *Circulation* 2021 Dec 21;144(25):2043–2045. <https://doi.org/10.1161/CIRCULATIONAHA.121.056870>. Epub 2021 Dec 20. PMID: 34928702.
- [272] Sakamori R, Yamada R, Tahata Y, Kodama T, Hikita H, Tatsumi T, et al. The absence of warfarin treatment and situs inversus are associated with the occurrence of hepatocellular carcinoma after Fontan surgery. *J Gastroenterol* 2022 Feb;57(2):111–119. <https://doi.org/10.1007/s00535-021-01842-8>. Epub 2022 Jan 22. PMID: 35064829.
- [273] Ohuchi H, Hayama Y, Nakajima K, Kurosaki K, Shiraishi I, Nakai M. Incidence, predictors, and mortality in patients with liver cancer after fontan operation. *J Am Heart Assoc* 2021 Feb 16;10(4):e016617. <https://doi.org/10.1161/JAHA.120.016617>. Epub 2021 Feb 4. PMID: 33538186; PMCID: PMC7955326.
- [274] Globalcan. <http://gco.iarc.fr/today>.
- [275] van Meer S, van Erpecum KJ, Sprengers D, Coenraad MJ, Klümper HJ, Janszen PL, et al. Hepatocellular carcinoma in cirrhotic versus noncirrhotic livers: results from a large cohort in the Netherlands. *Eur J Gastroenterol Hepatol* 2016 Mar;28(3):352–359. <https://doi.org/10.1097/MEG.0000000000000527>. PMID: 26629867.
- [276] Mazzarelli C, Cannon MD, Hudson M, Heaton N, Sarker D, Kane P, et al. Hepatocellular carcinoma as a complication of vascular disease of the liver after fontan procedure. *Hepatology* 2019 Feb;69(2):911–913. <https://doi.org/10.1002/hep.30194>. Epub 2018 Dec 28. PMID: 30055116.
- [277] Sagawa T, Kogiso T, Sugiyama H, Hashimoto E, Yamamoto M, Tokushige K. Characteristics of hepatocellular carcinoma arising from Fontan-associated liver disease. *Hepatol Res* 2020 Jul;50(7):853–862. <https://doi.org/10.1111/hepr.13500>. Epub 2020 Apr 30. PMID: 32219953.
- [278] European Association for the Study of the Liver. Electronic address: easloffice@easloffice.eu; European association for the study of the liver. EASL clinical practice guidelines: management of hepatocellular carcinoma. *J Hepatol* 2018 Jul;69(1):182–236. <https://doi.org/10.1016/j.jhep.2018.03.019>. Epub 2018 Apr 5. Erratum in: *J Hepatol*. 2019 Apr;70(4):817. PMID: 29628281.
- [279] Sarasin FP, Giostra E, Hadengue A. Cost-effectiveness of screening for detection of small hepatocellular carcinoma in western patients with Child-Pugh class A cirrhosis. *Am J Med* 1996 Oct;101(4):422–434. [https://doi.org/10.1016/S0002-9343\(96\)00197-0](https://doi.org/10.1016/S0002-9343(96)00197-0). PMID: 8873514.
- [280] Sherman M, Colombo M. Hepatocellular carcinoma screening and diagnosis. *Semin Liver Dis* 2014 Nov;34(4):389–397. <https://doi.org/10.1055/s-0034-1394139>. Epub 2014 Nov 4. PMID: 25369301.
- [281] Sherman M. Limitations of screening for hepatocellular carcinoma. *Hepat Oncol* 2014 Apr;1(2):161–163. <https://doi.org/10.2217/hep.13.22>. Epub 2014 Mar 20. PMID: 30190948; PMCID: PMC6096434.
- [282] Díaz-González Á, Forner A. Surveillance for hepatocellular carcinoma. *Best Pract Res Clin Gastroenterol* 2016 Dec;30(6):1001–1010. <https://doi.org/10.1016/j.bpg.2016.10.006>. Epub 2016 Oct 21. PMID: 27938779.
- [283] Moucari R, Rautou PE, Cazals-Hatem D, Geara A, Bureau C, Consigny Y, et al. Hepatocellular carcinoma in Budd-Chiari syndrome: characteristics and risk factors. *Gut* 2008 Jun;57(6):828–835. <https://doi.org/10.1136/gut.2007.139477>. Epub 2008 Jan 24. PMID: 18218675.
- [284] European Association for the Study of the Liver. Electronic address: easloffice@easloffice.eu. EASL Clinical Practice Guidelines: vascular diseases of the liver. *J Hepatol* 2016 Jan;64(1):179–202. <https://doi.org/10.1016/j.jhep.2015.07.040>. Epub 2015 Oct 26. PMID: 26516032.
- [285] Zentner D, Celermajer DS, Gentles T, d'Udekem Y, Ayer J, Blue GM, et al. Management of people with a fontan circulation: a cardiac society of Australia and New Zealand position statement. *Heart Lung Crit Care* 2020 Jan;29(1):5–39. <https://doi.org/10.1016/j.hlcc.2019.09.010>. Epub 2019 Nov 15. PMID: 31735685.
- [286] Kogiso T, Sagawa T, Taniai M, Shimada E, Inai K, Shinohara T, et al. Risk factors for Fontan-associated hepatocellular carcinoma. *PLoS One* 2022 Jun 17;17(6):e0270230. <https://doi.org/10.1371/journal.pone.0270230>. PMID: 35714161; PMCID: PMC9205474.
- [287] Barbara L, Benzi G, Gaiani S, Fusconi F, Zironi G, Siringo S, et al. Natural history of small untreated hepatocellular carcinoma in cirrhosis: a multivariate analysis of prognostic factors of tumor growth rate and patient

- survival. *Hepatology* 1992 Jul;16(1):132–137. <https://doi.org/10.1002/hep.1840160122>. PMID: 1352268.
- [288] Ebara M, Hatanro R, Fukuda H, Yoshikawa M, Sugiura N, Saisho H. Natural course of small hepatocellular carcinoma with underlying cirrhosis. A study of 30 patients. *Hepatogastroenterology* 1998 Aug;45(Suppl 3):1214–1220. PMID: 9730377.
- [289] Sheu JC, Sung JL, Chen DS, Yang PM, Lai MY, Lee CS, et al. Growth rate of asymptomatic hepatocellular carcinoma and its clinical implications. *Gastroenterology* 1985 Aug;89(2):259–266. [https://doi.org/10.1016/0016-5085\(85\)90324-5](https://doi.org/10.1016/0016-5085(85)90324-5). PMID: 2408960.
- [290] Andersson KL, Salomon JA, Goldie SJ, Chung RT. Cost effectiveness of alternative surveillance strategies for hepatocellular carcinoma in patients with cirrhosis. *Clin Gastroenterol Hepatol* 2008 Dec;6(12):1418–1424. <https://doi.org/10.1016/j.cgh.2008.08.005>. Epub 2008 Aug 19. PMID: 18848905; PMCID: PMC4340842.
- [291] Mondésert B, Moore JP, Khairy P. Cardiac implantable electronic devices in the fontan patient. *Can J Cardiol* 2022 Jul;38(7):1048–1058. <https://doi.org/10.1016/j.cjca.2022.04.024>. Epub 2022 May 17. PMID: 35588949.
- [292] Biselli M, Conti F, Gramenzi A, Frigerio M, Cucchetti A, Fatti G, et al. A new approach to the use of  $\alpha$ -fetoprotein as surveillance test for hepatocellular carcinoma in patients with cirrhosis. *Br J Cancer* 2015 Jan 6;112(1):69–76. <https://doi.org/10.1038/bjc.2014.536>. Epub 2014 Oct 14. PMID: 25314061; PMCID: PMC4453600.
- [293] Di Bisceglie AM, Sterling RK, Chung RT, Everhart JE, Dienstag JL, Bonkovsky HL, et al. Serum alpha-fetoprotein levels in patients with advanced hepatitis C: results from the HALT-C Trial. *J Hepatol* 2005 Sep;43(3):434–441. <https://doi.org/10.1016/j.jhep.2005.03.019>. PMID: 16136646.
- [294] Reig M, Forner A, Rimola J, Ferrer-Fàbrega J, Burrel M, Garcia-Criado Á, et al. BCLC strategy for prognosis prediction and treatment recommendation: the 2022 update. *J Hepatol* 2022 Mar;76(3):681–693. <https://doi.org/10.1016/j.jhep.2021.11.018>. Epub 2021 Nov 19. PMID: 34801630; PMCID: PMC8866082.
- [295] Kwon S, Scovel L, Yeh M, Dorsey D, Dembo G, Krieger EV, et al. Surgical management of hepatocellular carcinoma after Fontan procedure. *J Gastrointest Oncol* 2015 Jun;6(3):E55–E60. <https://doi.org/10.3978/j.issn.2078-6891.2015.009>. PMID: 26029468; PMCID: PMC4397258.
- [296] Angelico R, Lisignoli V, Monti L, Pariente R, Grimaldi C, Saffiotti MC, et al. Laparoscopic liver resection for hepatocellular carcinoma in Fontan-associated chronic liver disease. The first case report. *Int J Surg Case Rep* 2019;59:144–147. <https://doi.org/10.1016/j.ijscr.2019.05.029>. Epub 2019 May 23. PMID: 31146196; PMCID: PMC6541760.
- [297] Weyker PD, Allen-John Webb C, Emond JC, Brentjens TE, Johnston TA. Anesthetic implications of extended right hepatectomy in a patient with fontan physiology. *A A Case Rep* 2014 Apr 15;2(8):99–101. <https://doi.org/10.1213/XAA.0000000000000012>. PMID: 25611770.
- [298] Lo KS, Chan MY, Ma KW, Tsang SH, Cheung TT, Lo CM. Left hepatectomy in a patient with a Fontan circulation. *Transl Gastroenterol Hepatol* 2018 Aug 2;3:51. <https://doi.org/10.21037/tgh.2018.07.10>. PMID: 30225385; PMCID: PMC6131229.
- [299] Iwata M, Sakamoto K, Ito C, Sakamoto A, Uraoka M, Nagaoka T, et al. Laparoscopic partial liver resection for hepatocellular carcinoma arising from Fontan-associated liver disease: a case report. *Surg Case Rep* 2021 May 10;7(1):115. <https://doi.org/10.1186/s40792-021-01198-4>. PMID: 33970375; PMCID: PMC8110647.
- [300] Yokota Y, Noda T, Kobayashi S, Matsumoto K, Sakano Y, Iwagami Y, et al. A case report of Fontan procedure-related hepatocellular carcinoma: pure laparoscopic approach by low and stable pneumoperitoneum. *BMC Surg* 2020 Apr 21;20(1):80. <https://doi.org/10.1186/s12893-020-00741-8>. PMID: 32316959; PMCID: PMC7171803.
- [301] Nemoto S, Ariizumi SI, Kotera Y, Omori A, Yamashita S, Kato TA, et al. A patient with post-Fontan operation underwent left hepatectomy and caudate lobectomy for hepatocellular carcinoma: a case report. *Surg Case Rep* 2020 May 19;6(1):104. <https://doi.org/10.1186/s40792-020-00866-1>. PMID: 32430849; PMCID: PMC7237549.
- [302] Josephus Jitta D, Wagenaar LJ, Mulder BJ, Guichelaar M, Bouman D, van Melle JP. Three cases of hepatocellular carcinoma in Fontan patients: review of the literature and suggestions for hepatic screening. *Int J Cardiol* 2016 Mar 1;206:21–26. <https://doi.org/10.1016/j.ijcard.2015.12.033>. Epub 2016 Jan 2. PMID: 26773766.
- [303] Gasparrini F, Lenci I, Gagliardi MG, Spada M, Salimei F, Orlacchio A. Repeated TACE in HCC after Fontan surgery and situs viscerum inversus: a case report. *Radiol Case Rep* 2021 Jul 9;16(9):2564–2569. <https://doi.org/10.1016/j.radcr.2021.06.031>. PMID: 34306288; PMCID: PMC8283149.
- [304] Orlacchio A, Gasparrini F, Lenci I, Gagliardi MG, Spada M, Guazzaroni M, et al. Transarterial chemoembolization for hepatocellular carcinoma in Fontan surgery patient. *Radiol Case Rep* 2020 Oct 10;15(12):2602–2606. <https://doi.org/10.1016/j.radcr.2020.09.056>. PMID: 33088372; PMCID: PMC7557894.
- [305] Rosenbaum J, Vrazas J, Lane GK, Hardikar W. Cardiac cirrhosis and hepatocellular carcinoma in a 13-year-old treated with doxorubicin microbead transarterial chemoembolization. *J Paediatr Child Health* 2012 Mar;48(3):E140–E143. <https://doi.org/10.1111/j.1440-1754.2010.01932.x>. Epub 2010 Dec 29. PMID: 21199060.
- [306] Yamada K, Shinmoto H, Kawamura Y, Wakamatsu H, Kawachi T, Soga S, et al. Transarterial embolization for pediatric hepatocellular carcinoma with cardiac cirrhosis. *Pediatr Int* 2015 Aug;57(4):766–770. <https://doi.org/10.1111/ped.12619>. Epub 2015 May 27. PMID: 26013052.
- [307] Rutledge BP, Devara A, Benjaram S, Judd S, Ehrnpreis M. Transplant-amenable hepatocellular carcinoma in a fontan patient. *Case Rep Gastroenterol* 2019 Jun 26;13(2):275–279. <https://doi.org/10.1159/000501198>. PMID: 31341459; PMCID: PMC6639574.
- [308] Ogasawara Y, Kogiso T, Sagawa T, Kodama K, Tanai M, Numajiri H, et al. A case of Fontan-related hepatocellular carcinoma successfully treated with proton beam therapy. *Clin J Gastroenterol* 2020 Feb;13(1):73–78. <https://doi.org/10.1007/s12328-019-01010-9>. Epub 2019 Jul 4. PMID: 31273674.
- [309] Bruix J, Chan SL, Galle PR, Rimassa L, Sangro B. Systemic treatment of hepatocellular carcinoma: an EASL position paper. *J Hepatol* 2021 Oct;75(4):960–974. <https://doi.org/10.1016/j.jhep.2021.07.004>. Epub 2021 Jul 10. PMID: 34256065.
- [310] Suzuki H, Niizeki T, Shirono T, Koteda Y, Kinjo Y, Mizukami N, et al. Robust effect of hepatic arterial infusion chemotherapy and radiation therapy on hepatocellular carcinoma arising from fontan-associated liver disease. *Intern Med* 2022 Apr 15;61(8):1145–1150. <https://doi.org/10.2169/internalmedicine.8154-21>. Epub 2021 Sep 25. PMID: 34565776; PMCID: PMC9107970.
- [311] Oh C, Youn JK, Han JW, Kim GB, Kim HY, Jung SE. Hepatocellular carcinoma after the Fontan procedure in a 16-year-old girl: a case report. *Medicine (Baltimore)* 2016 Oct;95(41):e4823. <https://doi.org/10.1097/MD.0000000000004823>. PMID: 27741102; PMCID: PMC5072929.
- [312] Cho MK, Kwon JH, Gwak MS, Joh JW, Hwang J, Kim GS. Liver transplantation in an adult patient with hepatocellular carcinoma following liver cirrhosis as a complication of the Fontan procedure – A case report. *Anesth Pain Med (Seoul)* 2020 Oct 30;15(4):466–471. <https://doi.org/10.17085/apm.20037>. Epub 2020 Oct 21. PMID: 33329850; PMCID: PMC7724127.
- [313] Brown KN, Abraham J, Kanmanthareddy A. Heart transplantation patient selection. In: *StatPearls [internet]. Treasure Island (FL: StatPearls Publishing; 2022 Jun 7. 2022 Jan–*. PMID: 30725775.
- [314] Vogt M, Mühlbauer F, Braun SL, Lang T, Busch R, Lange R, et al. Prevalence and risk factors of hepatitis C infection after cardiac surgery in childhood before and after blood donor screening. *Infection* 2004 Jun;32(3):134–137. <https://doi.org/10.1007/s15010-004-2209-y>. PMID: 15188071.
- [315] Alter H. Discovery of non-A, non-B hepatitis and identification of its etiology. *Am J Med* 1999 Dec 27;107(6B):16S–20S. [https://doi.org/10.1016/s0002-9343\(99\)00375-7](https://doi.org/10.1016/s0002-9343(99)00375-7). PMID: 10653450.
- [316] Byrne RD, Weingarten AJ, Clark DE, Healan SJ, Richardson TL, Huang S, et al. Sizing up fontan failure: association with increasing weight in adulthood. *Pediatr Cardiol* 2021 Aug;42(6):1425–1432. <https://doi.org/10.1007/s00246-021-02628-8>. Epub 2021 May 4. PMID: 33948709.
- [317] Aby ES, Saab S. Frailty, sarcopenia, and malnutrition in cirrhotic patients. *Clin Liver Dis* 2019 Nov;23(4):589–605. <https://doi.org/10.1016/j.cld.2019.06.001>. Epub 2019 Aug 21. PMID: 31563213.
- [318] Shiina Y, Nagao M, Shimomiya Y, Inai K. Secondary sarcopenia assessed by computed tomography can predict hospitalization for heart failure in adults with Fontan circulation. *J Cardiol* 2021 Jan;77(1):10–16. <https://doi.org/10.1016/j.jicc.2020.06.009>. Epub 2020 Oct 23. PMID: 33317800.
- [319] Miranda WR, Jain CC, Borlaug BA, Connolly HM, Egbe AC. Exercise invasive hemodynamics in adults post-Fontan: a novel tool in understanding functional limitation and liver disease. *J Heart Lung Transpl* 2022 Jun;41(6):704–707. <https://doi.org/10.1016/j.healun.2022.02.023>. Epub 2022 Mar 9. PMID: 35400586.
- [320] Alsaid T, Possner M, Lubert AM, Trout AT, Gandhi JP, Garr B, et al. Thromboembolic events are independently associated with liver stiffness in

- patients with fontan circulation. *J Clin Med* 2020 Feb 4;9(2):418. <https://doi.org/10.3390/jcm9020418>. PMID: 32032996; PMCID: PMC7073638.
- [321] Alsaied T, Alsidawi S, Allen CC, Faircloth J, Palumbo JS, Veldtman GR. Strategies for thromboprophylaxis in Fontan circulation: a meta-analysis. *Heart* 2015 Nov;101(21):1731-1737. <https://doi.org/10.1136/heartjnl-2015-307930>. Epub 2015 Aug 28. PMID: 26319122.
- [322] Monagle P, Cochrane A, Roberts R, Manlhiot C, Weintraub R, Szechtman B, et al. A multicenter, randomized trial comparing heparin/warfarin and acetylsalicylic acid as primary thromboprophylaxis for 2 years after the Fontan procedure in children. *J Am Coll Cardiol* 2011 Aug 2;58(6):645-651. <https://doi.org/10.1016/j.jacc.2011.01.061>. PMID: 21798429.
- [323] Attard C, Monagle PT, d'Udekem Y, Mackay MT, Briody J, Cordina R, et al. Long-term outcomes of warfarin versus aspirin after Fontan surgery. *J Thorac Cardiovasc Surg* 2021 Oct;162(4):1218-1228.e3. <https://doi.org/10.1016/j.jtcvs.2020.12.102>. Epub 2021 Jan 5. PMID: 33563422.
- [324] Tan JL, Sidhu-Brar S, Woodman R, Chinnaratha MA. Regular aspirin use is associated with a reduced risk of hepatocellular carcinoma (HCC) in chronic liver disease: a systematic review and meta-analysis. *J Gastrointest Cancer* 2022 Jun 18. <https://doi.org/10.1007/s12029-022-00842-y>. Epub ahead of print. PMID: 35717551.
- [325] Kazerouninia A, Georgekutty J, Kendsersky P, Byrne RD, Seto B, Chu PY, et al. A multisite retrospective review of direct oral anticoagulants compared to warfarin in adult fontan patients. *Cardiovasc Drugs Ther* 2022 Jan 13. <https://doi.org/10.1007/s10557-021-07298-5>. Epub ahead of print. PMID: 35022950.
- [326] Stout KK, Broberg CS, Book WM, Cecchin F, Chen JM, Dimopoulos K, et al. American heart association council on clinical Cardiology, council on functional genomics and translational biology, and council on cardiovascular radiology and imaging. Chronic heart failure in congenital heart disease: a scientific statement from the American heart association. *Circulation* 2016 Feb 23;133(8):770-801. <https://doi.org/10.1161/CIR.0000000000000352>. Epub 2016 Jan 19. PMID: 26787728.
- [327] Yang H, Bouma BJ, Dimopoulos K, Khairy P, Ladouceur M, Niwa K, et al. Non-vitamin K antagonist oral anticoagulants (NOACs) for thromboembolic prevention, are they safe in congenital heart disease? Results of a worldwide study. *Int J Cardiol* 2020 Jan 15;299:123-130. <https://doi.org/10.1016/j.ijcard.2019.06.014>. Epub 2019 Jun 13. PMID: 31307847.
- [328] Semmler G, Pomej K, Bauer DJM, Balcar L, Simbrunner B, Binter T, et al. Safety of direct oral anticoagulants in patients with advanced liver disease. *Liver Int* 2021 Sep;41(9):2159-2170. <https://doi.org/10.1111/liv.14992>. Epub 2021 Jul 10. PMID: 34152697; PMCID: PMC8456813.
- [329] Wilson TG, Iyengar AJ, Winlaw DS, Weintraub RG, Wheaton GR, Gentles TL, et al. Australia and New Zealand fontan registry. Use of ACE inhibitors in fontan: rational or irrational? *Int J Cardiol* 2016 May 1;210:95-99. <https://doi.org/10.1016/j.ijcard.2016.02.089>. Epub 2016 Feb 18. PMID: 26938683.
- [330] Mainwaring RD, Lamberti JJ, Moore JW, Billman GF, Nelson JC. Comparison of the hormonal response after bidirectional Glenn and Fontan procedures. *Ann Thorac Surg* 1994 Jan;57(1):59-63. [https://doi.org/10.1016/0003-4975\(94\)90365-4](https://doi.org/10.1016/0003-4975(94)90365-4). discussion 64. PMID: 8279919.
- [331] Pereira RM, dos Santos RA, da Costa Dias FL, Teixeira MM, Simões e Silva AC. Renin-angiotensin system in the pathogenesis of liver fibrosis. *World J Gastroenterol* 2009 Jun 7;15(21):2579-2586. <https://doi.org/10.3748/wjg.15.2579>. PMID: 19496186; PMCID: PMC2691487.
- [332] Paizis G, Gilbert RE, Cooper ME, Murthi P, Schembri JM, Wu LL, et al. Effect of angiotensin II type 1 receptor blockade on experimental hepatic fibrogenesis. *J Hepatol* 2001 Sep;35(3):376-385. [https://doi.org/10.1016/S0168-8278\(01\)00146-5](https://doi.org/10.1016/S0168-8278(01)00146-5). PMID: 11592599.
- [333] Yoshiji H, Kuriyama S, Fukui H. Angiotensin-I-converting enzyme inhibitors may be an alternative anti-angiogenic strategy in the treatment of liver fibrosis and hepatocellular carcinoma. Possible role of vascular endothelial growth factor. *Tumour Biol* 2002 Nov-Dec;23(6):348-356. <https://doi.org/10.1159/000069792>. PMID: 12677092.
- [334] Wei HS, Lu HM, Li DG, Zhan YT, Wang ZR, Huang X, et al. The regulatory role of AT 1 receptor on activated HSCs in hepatic fibrogenesis: effects of RAS inhibitors on hepatic fibrosis induced by CCl<sub>4</sub>. *World J Gastroenterol* 2000 Dec;6(6):824-828. <https://doi.org/10.3748/wjg.v6.i6.824>. PMID: 11819703; PMCID: PMC4728269.
- [335] Croquet V, Moal F, Veal N, Wang J, Oberti F, Roux J, et al. Hemodynamic and antifibrotic effects of losartan in rats with liver fibrosis and/or portal hypertension. *J Hepatol* 2002 Dec;37(6):773-780. [https://doi.org/10.1016/S0168-8278\(02\)00307-0](https://doi.org/10.1016/S0168-8278(02)00307-0). PMID: 12445418.
- [336] Havelveld LM, Blom NA, Terol Espinosa de Los Monteros C, Kuipers IM, Rammeloo LAJ, Hazekamp MG, et al. 3-Month enalapril treatment in pediatric fontan patients with moderate to good systolic ventricular function. *Am J Cardiol* 2022 Jan 15;163:98-103. <https://doi.org/10.1016/j.amjcard.2021.10.013>. Epub 2021 Nov 10. PMID: 34774285.
- [337] Oka N, Miyamoto T, Tomoyasu T, Hayashi H, Miyaji K. Risk factors for mid-term liver disease after the fontan procedure. *Int Heart J* 2020 Sep 29;61(5):979-983. <https://doi.org/10.1536/ihj.20-059>. Epub 2020 Sep 12. PMID: 32921662.
- [338] Khambadkone S, Li J, de Leval MR, Cullen S, Deanfield JE, Redington AN. Basal pulmonary vascular resistance and nitric oxide responsiveness late after Fontan-type operation. *Circulation* 2003 Jul 1;107(25):3204-3208. <https://doi.org/10.1161/01.CIR.0000074210.49434.40>. Epub 2003 Jun 23. PMID: 12821557.
- [339] Hebert A, Jensen AS, Idorn L, Sørensen KE, Søndergaard L. The effect of bosentan on exercise capacity in Fontan patients; rationale and design for the TEMPO study. *BMC Cardiovasc Disord* 2013 May 11;13:36. <https://doi.org/10.1186/1471-2261-13-36>. PMID: 23663658; PMCID: PMC3658877.
- [340] Rhodes J, Ubeda-Tikkanen A, Clair M, Fernandes SM, Graham DA, Millren CE, et al. Effect of inhaled iloprost on the exercise function of Fontan patients: a demonstration of concept. *Int J Cardiol* 2013 Oct 3;168(3):2435-2440. <https://doi.org/10.1016/j.ijcard.2013.03.014>. Epub 2013 Mar 29. PMID: 23545150; PMCID: PMC4288936.
- [341] Giardini A, Balducci A, Specchia S, Gargiulo G, Bonvicini M, Picchio FM. Effect of sildenafil on haemodynamic response to exercise and exercise capacity in Fontan patients. *Eur Heart J* 2008 Jul;29(13):1681-1687. <https://doi.org/10.1093/eurheartj/ehn215>. Epub 2008 Jun 4. PMID: 18534975.
- [342] Wang W, Hu X, Liao W, Rutahoa WH, Malenka DJ, Zeng X, et al. The efficacy and safety of pulmonary vasodilators in patients with Fontan circulation: a meta-analysis of randomized controlled trials. *Pulm Circ* 2019 Jan-Mar;9(1):2045894018790450. <https://doi.org/10.1177/2045894018790450>. Epub 2018 Jul 4. PMID: 29972332; PMCID: PMC6348526.
- [343] Agnoletti G, Gala S, Ferroni F, Bordese R, Appendini L, Pace Napoleone C, et al. Endothelin inhibitors lower pulmonary vascular resistance and improve functional capacity in patients with Fontan circulation. *J Thorac Cardiovasc Surg* 2017 Jun;153(6):1468-1475. <https://doi.org/10.1016/j.jtcvs.2017.01.051>. Epub 2017 Feb 10. PMID: 28283234.
- [344] Snarr BS, Paridon SM, Rychik J, Goldberg DJ. Pulmonary vasodilator therapy in the failing Fontan circulation: rationale and efficacy. *Cardiol Young* 2015 Dec;25(8):1489-1492. <https://doi.org/10.1017/S1047951115002309>. PMID: 26675595.
- [345] Tabarsi N, Guan M, Simmonds J, Toma M, Kiess M, Tsang V, et al. Meta-Analysis of the effectiveness of heart transplantation in patients with a failing fontan. *Am J Cardiol* 2017 Apr 15;119(8):1269-1274. <https://doi.org/10.1016/j.amjcard.2017.01.001>. Epub 2017 Jan 25. PMID: 28233535.
- [346] Davies RR, Sorabella RA, Yang J, Mosca RS, Chen JM, Quaegebeur JM. Outcomes after transplantation for "failed" Fontan: a single-institution experience. *J Thorac Cardiovasc Surg* 2012 May;143(5):1183-1192.e4. <https://doi.org/10.1016/j.jtcvs.2011.12.039>. PMID: 22500594.
- [347] Michielon G, van Melle JP, Wolff D, Di Carlo D, Jacobs JP, Mattila IP, et al. Favourable mid-term outcome after heart transplantation for late Fontan failure. *Eur J Cardiothorac Surg* 2015 Apr;47(4):665-671. <https://doi.org/10.1093/ejcts/ezu280>. Epub 2014 Jul 17. PMID: 25035415.
- [348] Miller JR, Simpson KE, Epstein DJ, Lancaster TS, Henn MC, Schuessler RB, et al. Improved survival after heart transplant for failed Fontan patients with preserved ventricular function. *J Heart Lung Transpl* 2016 Jul;35(7):877-883. <https://doi.org/10.1016/j.healun.2016.02.005>. Epub 2016 Mar 10. PMID: 27068035; PMCID: PMC6954486.
- [349] Griffiths ER, Kaza AK, Wylar von Ballmoos MC, Loyola H, Valente AM, Blume ED, et al. Evaluating failing Fontans for heart transplantation: predictors of death. *Ann Thorac Surg* 2009 Aug;88(2):558-563. <https://doi.org/10.1016/j.athoracsur.2009.03.085>. discussion 563-4. PMID: 19632412; PMCID: PMC2844259.
- [350] Sathananthan G, Johal N, Verma T, Sandhu S, Chakrabarti S, Riahi M, et al. Clinical importance of fontan circuit thrombus in the adult population: significant association with increased risk of cardiovascular events. *Can J Cardiol* 2019 Dec;35(12):1807-1814. <https://doi.org/10.1016/j.cjca.2019.08.038>. Epub 2019 Sep 5. PMID: 31813509.
- [351] Dipchand AI, Honjo O, Alonso-Gonzalez R, McDonald M, Roche SL. Heart transplant indications, considerations, and outcomes in fontan patients: age-related nuances, transplant listing, and disease-specific indications. *Can J Cardiol* 2022 Jul;38(7):1072-1085. <https://doi.org/10.1016/j.cjca.2022.02.019>. Epub 2022 Feb 28. PMID: 35240250.
- [352] Bearl DW, Cantor R, Koehl D, Gossett JG, Bock MJ, Halnon N, et al. Fontan-associated plastic bronchitis waitlist and heart transplant



- outcomes: a PHTS analysis. *Pediatr Transpl* 2021 Aug;25(5):e13951. <https://doi.org/10.1111/ptr.13951>. Epub 2021 Jan 6. PMID: 33405353.
- [353] Broda CR, Alonso-Gonzalez R, Ghaneekar A, Gulamhusein A, McDonald M, Luk A, et al. Fate of the liver in the survivors of adult heart transplant for a failing Fontan circulation. *J Heart Lung Transpl* 2022 Mar;41(3):283–286. <https://doi.org/10.1016/j.healun.2021.10.020>. Epub 2021 Nov 11. PMID: 34953719.
- [354] Greenway SC, Crossland DS, Hudson M, Martin SR, Myers RP, Prieur T, et al. Fontan-associated liver disease: implications for heart transplantation. *J Heart Lung Transpl* 2016 Jan;35(1):26–33. <https://doi.org/10.1016/j.healun.2015.10.015>. Epub 2015 Oct 19. PMID: 26586487.
- [355] Amdani S, Simpson KE, Thrush P, Shih R, Simmonds J, Knecht K, et al. Hepatorenal dysfunction assessment with the Model for End-Stage Liver Disease Excluding INR score predicts worse survival after heart transplant in pediatric Fontan patients. *J Thorac Cardiovasc Surg* 2022 Apr;163(4):1462–1473.e12. <https://doi.org/10.1016/j.jtcvs.2021.02.014>. Epub 2021 Feb 18. PMID: 33745714.
- [356] Egbe AC, Miranda WR, Anderson JH, Katta RR, Goda AY, Andi K, et al. Determinants and prognostic implications of hepatorenal dysfunction in adults with congenital heart disease. *Can J Cardiol* 2022 Nov;38(11):1742–1750. <https://doi.org/10.1016/j.cjca.2022.07.018>. Epub 2022 Aug 4. PMID: 35934261.
- [357] Berg CJ, Bauer BS, Hageman A, Aboulhosn JA, Reardon LC. Mortality risk stratification in fontan patients who underwent heart transplantation. *Am J Cardiol* 2017 May 15;119(10):1675–1679. <https://doi.org/10.1016/j.amjcard.2017.02.005>. Epub 2017 Mar 1. PMID: 28341356.
- [358] Assenza GE, Graham DA, Landzberg MJ, Valente AM, Singh MN, Bashir A, et al. MELD-XI score and cardiac mortality or transplantation in patients after Fontan surgery. *Heart* 2013 Apr;99(7):491–496. <https://doi.org/10.1136/heartjnl-2012-303347>. Epub 2013 Feb 13. PMID: 23406689.
- [359] Lewis M, Ginns J, Schulze C, Lippel M, Chai P, Bacha E, et al. Outcomes of adult patients with congenital heart disease after heart transplantation: impact of disease type, previous thoracic surgeries, and bystander organ dysfunction. *J Card Fail* 2016 Jul;22(7):578–582. <https://doi.org/10.1016/j.cardfail.2015.09.002>. Epub 2015 Nov 11. PMID: 26432646.
- [360] D'Souza BA, Fuller S, Gleason LP, Hornsby N, Wald J, Krok K, et al. Single-center outcomes of combined heart and liver transplantation in the failing Fontan. *Clin Transpl* 2017 Mar;31(3). <https://doi.org/10.1111/ctr.12892>. Epub 2017 Feb 4. PMID: 27988989.
- [361] Reardon LC, Lin JP, VanArsdell GS, Kaldas FM, Lluri G, Tan W, et al. Orthotopic heart and combined heart liver transplantation: the ultimate treatment option for failing fontan physiology. *Curr Transpl Rep* 2021;8(1):9–20. <https://doi.org/10.1007/s40472-021-00315-4>. Epub 2021 Feb 4. PMID: 33564612; PMCID: PMC7861581.
- [362] Sganga D, Hollander SA, Vaikunth S, Haeffele C, Bensen R, Navaratnam M, et al. Comparison of combined heart–liver vs heart-only transplantation in pediatric and young adult Fontan recipients. *J Heart Lung Transpl* 2021 Apr;40(4):298–306. <https://doi.org/10.1016/j.healun.2020.12.008>. Epub 2020 Dec 29. PMID: 33485775; PMCID: PMC8026537.
- [363] Bradley EA, Pinyoluksana KO, Moore-Clingenpeel M, Miao Y, Daniels C. Isolated heart transplant and combined heart-liver transplant in adult congenital heart disease patients: insights from the united network of organ sharing. *Int J Cardiol* 2017 Feb 1;228:790–795. <https://doi.org/10.1016/j.ijcard.2016.11.121>. Epub 2016 Nov 10. PMID: 27888756.
- [364] Simpson KE, Esmaeeli A, Khanna G, White F, Turmelle Y, Eghtesady P, et al. Liver cirrhosis in Fontan patients does not affect 1-year post-heart transplant mortality or markers of liver function. *J Heart Lung Transpl* 2014 Feb;33(2):170–177. <https://doi.org/10.1016/j.healun.2013.10.033>. Epub 2013 Oct 25. PMID: 24365764; PMCID: PMC3985609.
- [365] Rodriguez DS, Mao C, Mahle WT, Kanter KR, Alazraki A, Braithwaite K, et al. Pretransplantation and post-transplantation liver disease assessment in adolescents undergoing isolated heart transplantation for fontan failure. *J Pediatr* 2021 Feb;229:78–85.e2. <https://doi.org/10.1016/j.jpeds.2020.09.044>. Epub 2020 Sep 22. PMID: 32976893.
- [366] Hofferberth SC, Singh TP, Bastardi H, Blume ED, Fynn-Thompson F. Liver abnormalities and post-transplant survival in pediatric Fontan patients. *Pediatr Transpl* 2017 Dec;21(8). <https://doi.org/10.1111/ptr.13061>. Epub 2017 Nov 3. PMID: 29105236.
- [367] Bouchardy J, Meyer P, Yerly P, Blanche C, Hullin R, Giostra E, et al. Regression of advanced liver fibrosis after heart transplantation in a patient with prior fontan surgery for complex congenital heart disease. *Circ Heart Fail* 2018 Nov;11(11):e003754. <https://doi.org/10.1161/CIRCHEARTFAILURE.117.003754>. PMID: 30571198.
- [368] Ybarra AM, Khanna G, Turmelle YP, Stoll J, Castleberry CD, Scheel J, et al. Heterogeneous outcomes of liver disease after heart transplantation for a failed Fontan procedure. *Pediatr Transpl* 2021 Dec;25(8):e14094. <https://doi.org/10.1111/ptr.14094>. Epub 2021 Jul 22. PMID: 34296503.
- [369] Griffiths ER, Lambert LM, Ou Z, Shaaban A, Rezvani M, Carlo WF, et al. Fontan-associated liver disease after heart transplant. *Pediatr Transpl* 2022 Nov 15:e14435. <https://doi.org/10.1111/ptr.14435>. Epub ahead of print. PMID: 36380561.
- [370] Kim MH, Nguyen A, Lo M, Kumar SR, Bucuvalas J, Glynn EF, et al. Big data in transplantation practice—the devil is in the detail—fontan-associated liver disease. *Transplantation* 2021 Jan 1;105(1):18–22. <https://doi.org/10.1097/TP.0000000000003308>. PMID: 32639398.
- [371] Warnes CA, Williams RG, Bashore TM, Child JS, Connolly HM, Dearani JA, et al. ACC/AHA 2008 guidelines for the management of adults with congenital heart disease: a report of the American college of Cardiology/American heart association task force on practice guidelines (writing committee to develop guidelines on the management of adults with congenital heart disease). Developed in collaboration with the American society of echocardiography, heart rhythm society, international society for adult congenital heart disease, society for cardiovascular angiography and interventions, and society of thoracic surgeons. *J Am Coll Cardiol* 2008 Dec 2;52(23):e143–e263. <https://doi.org/10.1016/j.jacc.2008.10.001>. PMID: 19038677.
- [372] Gnanappa GK, Celermajer DS, Sholler GF, Gentles T, Winlaw D, d'Udekem Y, et al. The long-term management of children and adults with a fontan circulation: a systematic review and survey of current practice in Australia and New Zealand. *Pediatr Cardiol* 2017 Jan;38(1):56–69. <https://doi.org/10.1007/s00246-016-1484-6>. Epub 2016 Oct 27. PMID: 27787594.
- [373] Keung CY, Zentner D, Gibson RN, Phan DH, Grigg LE, Sood S, et al. Fontan-associated liver disease: pathophysiology, investigations, predictors of severity and management. *Eur J Gastroenterol Hepatol* 2020 Aug;32(8):907–915. <https://doi.org/10.1097/MEG.0000000000001641>. PMID: 31851099.