

University of Groningen

A patient with recurrent syncope-it does matter how slow and long you go

Roseboom, Eva; Maass, Alexander H; Ter Maaten, Jozine M

Published in:
 Netherlands Heart Journal

DOI:
[10.1007/s12471-023-01779-y](https://doi.org/10.1007/s12471-023-01779-y)

IMPORTANT NOTE: You are advised to consult the publisher's version (publisher's PDF) if you wish to cite from it. Please check the document version below.

Document Version
 Publisher's PDF, also known as Version of record

Publication date:
 2023

[Link to publication in University of Groningen/UMCG research database](#)

Citation for published version (APA):

Roseboom, E., Maass, A. H., & Ter Maaten, J. M. (2023). A patient with recurrent syncope-it does matter how slow and long you go: Rythm Puzzle - Answer. *Netherlands Heart Journal*, 31, 410-411.
<https://doi.org/10.1007/s12471-023-01779-y>

Copyright

Other than for strictly personal use, it is not permitted to download or to forward/distribute the text or part of it without the consent of the author(s) and/or copyright holder(s), unless the work is under an open content license (like Creative Commons).

The publication may also be distributed here under the terms of Article 25fa of the Dutch Copyright Act, indicated by the "Taverne" license. More information can be found on the University of Groningen website: <https://www.rug.nl/library/open-access/self-archiving-pure/taverne-amendment>.

Take-down policy

If you believe that this document breaches copyright please contact us providing details, and we will remove access to the work immediately and investigate your claim.

Downloaded from the University of Groningen/UMCG research database (Pure): <http://www.rug.nl/research/portal>. For technical reasons the number of authors shown on this cover page is limited to 10 maximum.



A patient with recurrent syncope – it does matter how slow and long you go

Eva Roseboom · Alexander H. Maass · Jozine M. ter Maaten

Accepted: 13 March 2023 / Published online: 3 May 2023
 © The Author(s) 2023

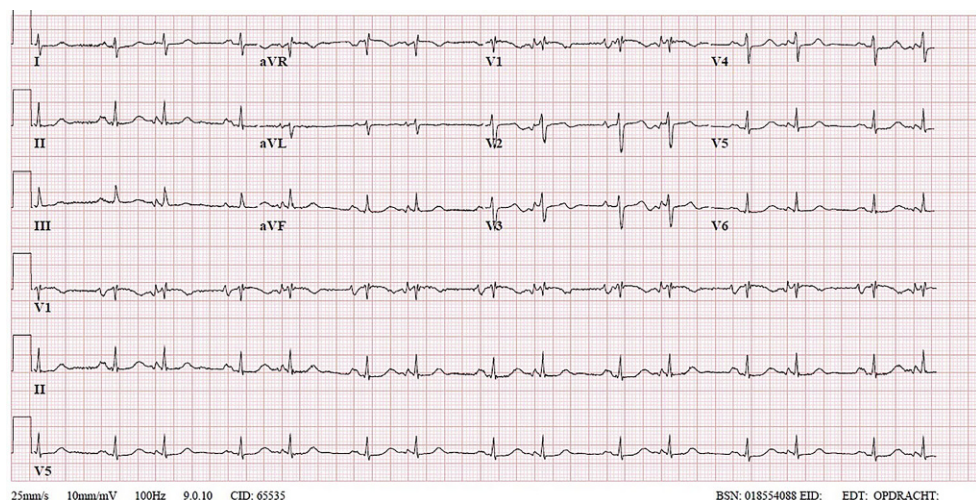
Answer

Torsade de pointes is a polymorphic ventricular tachycardia (VT) with cyclic alteration of the QRS axis, in the context of prolonged repolarisation [1]. Stereotypically, it is initiated by an early afterdepolarisation in a short-long-short sequence. Fig. 1b (in the question) shows VT with characteristic sinusoidal alteration of the QRS axis, which is only preceded by a single long-coupled premature ventricular complex arising from the T wave in prolonged QT interval.

Our patient developed long QT syndrome due to the use of sotalol. Current guidelines on atrial fibrillation suggest sotalol may be considered for long-

term rhythm control [2]. Sotalol is a nonselective beta-blocker with class III antiarrhythmic properties, blocking potassium efflux and prolonging phase 3 of the action potential. It acts in a dose-dependent manner and exhibits reverse use dependence, being more potent in bradycardia. Therefore, an ambulatory 24-hour ECG recording is recommended to evaluate QT interval prolongation and bradyarrhythmias. Since sotalol is renally excreted, it is vital to monitor kidney function throughout treatment and implement dose adjustments accordingly. Proarrhythmia is reported in 1–4% of sotalol users, with a higher prevalence in women and patients with serum creatinine > 124 µmol/l [3].

Fig. 1 Electrocardiogram after cessation of sotalol showing restoration of conduction intervals and normal conduction of premature atrial contractions



E. Roseboom (✉) · A. H. Maass · J. M. ter Maaten
 Department of Cardiology, University Medical Centre
 Groningen, University of Groningen, Groningen, The
 Netherlands
e.roseboom@umcg.nl



Similar to all beta-blockers, sotalol can lead to conduction slowing. The appearance of fragmentation of T waves in Fig. 1a (in the question) are in fact blocked premature atrial contractions (PACs) in bigeminy. An ECG recorded after cessation of sotalol showed restoration of conduction intervals and normal conduction of PACs (Fig. 1). The patient was discharged with bisoprolol and scheduled for cavotricuspid isthmus ablation.

Conflict of interest E. Roseboom, A.H. Maass and J.M. ter Maaten declare that they have no competing interests.

Open Access This article is licensed under a Creative Commons Attribution 4.0 International License, which permits use, sharing, adaptation, distribution and reproduction in any medium or format, as long as you give appropriate credit to the original author(s) and the source, provide a link to the Creative Commons licence, and indicate if changes were made. The images or other third party material in this article are included in the article's Creative Commons licence, unless indicated otherwise in a credit line to the material. If material is not included in the article's Creative Commons licence and

your intended use is not permitted by statutory regulation or exceeds the permitted use, you will need to obtain permission directly from the copyright holder. To view a copy of this licence, visit <http://creativecommons.org/licenses/by/4.0/>.

References

1. Khan IA. Long QT syndrome: diagnosis and management. *Am Heart J.* 2002;143:7–14.
2. Hindricks G, Potpara T, Dagres N, Arbelo E, Bax JJ, Blomström-Lundqvist C, et al. ESC Scientific Document Group. 2020 ESC Guidelines for the diagnosis and management of atrial fibrillation developed in collaboration with the European Association for Cardio-Thoracic Surgery (EACTS): The Task Force for the diagnosis and management of atrial fibrillation of the European Society of Cardiology (ESC) Developed with the special contribution of the European Heart Rhythm Association (EHRA) of the ESC. *Eur Heart J.* 2021;42:373–498.
3. Lehmann MH, Hardy S, Archibald D, Quart B, MacNeil DJ. Sex difference in risk of torsade de pointes with d,l-sotalol. *Circulation.* 1996;94:2535–41.