

University of Groningen

Genital gender-affirming surgery for transgender women

van der Sluis, Wouter B.; Schäfer, Tim; Nijhuis, Tim H.J.; Bouman, Mark Bram

Published in:
Best Practice and Research: Clinical Obstetrics and Gynaecology

DOI:
[10.1016/j.bpobgyn.2022.102297](https://doi.org/10.1016/j.bpobgyn.2022.102297)

IMPORTANT NOTE: You are advised to consult the publisher's version (publisher's PDF) if you wish to cite from it. Please check the document version below.

Document Version
Publisher's PDF, also known as Version of record

Publication date:
2023

[Link to publication in University of Groningen/UMCG research database](#)

Citation for published version (APA):

van der Sluis, W. B., Schäfer, T., Nijhuis, T. H. J., & Bouman, M. B. (2023). Genital gender-affirming surgery for transgender women. *Best Practice and Research: Clinical Obstetrics and Gynaecology*, 86, Article 102297. <https://doi.org/10.1016/j.bpobgyn.2022.102297>

Copyright

Other than for strictly personal use, it is not permitted to download or to forward/distribute the text or part of it without the consent of the author(s) and/or copyright holder(s), unless the work is under an open content license (like Creative Commons).

The publication may also be distributed here under the terms of Article 25fa of the Dutch Copyright Act, indicated by the "Taverne" license. More information can be found on the University of Groningen website: <https://www.rug.nl/library/open-access/self-archiving-pure/taverne-amendment>.

Take-down policy

If you believe that this document breaches copyright please contact us providing details, and we will remove access to the work immediately and investigate your claim.

Downloaded from the University of Groningen/UMCG research database (Pure): <http://www.rug.nl/research/portal>. For technical reasons the number of authors shown on this cover page is limited to 10 maximum.




ELSEVIER

Contents lists available at ScienceDirect

Best Practice & Research Clinical Obstetrics and Gynaecology

journal homepage: www.elsevier.com/locate/bpobgyn



12

Genital gender-affirming surgery for transgender women



Wouter B. van der Sluis, MD PhD^{a, b, *},
Tim Schäfer, MD PhD^{b, c}, Tim H.J. Nijhuis, MD PhD^d,
Mark-Bram Bouman, MD PhD^{a, b, e}

^a Department of Plastic, Reconstructive and Hand Surgery, Amsterdam University Medical Center, Location VUmc, Amsterdam, the Netherlands

^b Gender Clinic, Bosch en Duin, the Netherlands

^c Department of Plastic Surgery, University Medical Centre Groningen, Groningen, the Netherlands

^d Department of Plastic and Reconstructive Surgery, Radboud University Medical Centre, Nijmegen, the Netherlands

^e Amsterdam Public Health (APH) Research Institute, Amsterdam University Medical Center, Location VUmc, Amsterdam, the Netherlands

A B S T R A C T

Keywords:

Transgender
Gender dysphoria
Vaginoplasty
Vulvoplasty
Orchiectomy

Transgender women may opt for genital gender-affirming surgery (gGAS), which comprises bilateral orchiectomy, gender-affirming vulvoplasty, or vaginoplasty. Vaginoplasty is chosen most frequently in this population, penile inversion vaginoplasty being the surgical gold standard. In selected cases, skin graft vaginoplasty, intestinal vaginoplasty, or peritoneal vaginoplasty may be indicated. In this article, we discuss the various types of gGAS for transgender women, (contra)-indications, intraoperative considerations, techniques, surgical outcomes, and postoperative patient-reported outcomes.

© 2023 The Authors. Published by Elsevier Ltd. This is an open access article under the CC BY license (<http://creativecommons.org/licenses/by/4.0/>).

Abbreviations: gGAS, genital gender-affirming surgery.

* Corresponding author. Department of Plastic, Reconstructive and Hand Surgery, Amsterdam University Medical Center, Location VUmc, De Boelelaan 1117, 1081 HV, Amsterdam, the Netherlands.

E-mail address: w.vandersluis@amsterdamumc.nl (W.B. van der Sluis).

<https://doi.org/10.1016/j.bpobgyn.2022.102297>

1521-6934/© 2023 The Authors. Published by Elsevier Ltd. This is an open access article under the CC BY license (<http://creativecommons.org/licenses/by/4.0/>).

Introduction

The number of transgender individuals who opt for medical and/or surgical care is increasing worldwide, particularly in recent years [1]. In our center, approximately 80% of transgender women opt for a form of genital gender-affirming surgery (gGAS). gGAS comprises bilateral orchiectomy, gender-affirming vulvoplasty, or vaginoplasty [2]. Vaginoplasty is chosen most frequently in this population.

In this article, we discuss the various types of gGAS procedures for transgender women, (contra-)indications, intraoperative considerations, surgical outcomes, and postoperative patient-reported outcomes.

Indications and (relative) contraindications

When transgender women opt for gGAS, all options are meticulously discussed during the pre-operative phase together with both a psychologist and a plastic surgeon. The latter also takes into account certain anatomical aspects to check which surgery is technically feasible. Shared decision-making is very important to make the right decision for the individual. With regard to (contra-)indications for these surgical procedures, we follow the Standards of Care for the Health of Transsexual, Transgender, and Gender Nonconforming People [3]. Bilateral orchiectomy, as is performed in all gGAS procedures, causes infertility, and individuals need to be counseled preoperatively on reproductive functions and fertility preservation, for example, by semen preservation.

Indications for gGAS include.

- Having well-documented, persistent gender incongruence. Other possible causes of apparent gender incongruence were identified and excluded.
- Being able to provide informed consent.
- Understanding the effects of surgery on reproduction and previous exploration of reproductive options.
- Age of majority.
- Having experienced repressing of testosterone and living in the gender role for a minimum of 6 months or longer.
- Two referrals from qualified mental health professionals.

Contra-indications.

- Severe psychiatric or somatic comorbidity that hampers
 - o 1. The peri- and postoperative recovery process and/or
 - o 2. Adequate identification of gender dysphoria by the psychologist.
- *For the vaginoplasty procedure:* Though somewhat debated [4], having a BMI>30 is regarded as a contraindication in our center.
- *For the vaginoplasty procedure:* Smoking.

Vaginoplasty

During vaginoplasty, urethral shortening, clitoroplasty, labiaplasty, penectomy, and orchiectomy are performed. Vaginoplasty subtypes are divided by the way the neovaginal canal is lined. The surgical gold standard in primary vaginoplasty cases is penile inversion vaginoplasty, in which the neovagina is lined using a pedicled inverted penile skin flap, sometimes augmented with (scrotal) skin grafts. Other options comprise skin graft vaginoplasty, intestinal vaginoplasty, or peritoneal vaginoplasty.

Penile inversion vaginoplasty

Surgical technique

Penile inversion vaginoplasty is the most frequently performed vaginoplasty procedure in transgender women [2]. Different surgeons have different modifications in certain parts of the procedure, but most major steps are uniform (Fig. 1).

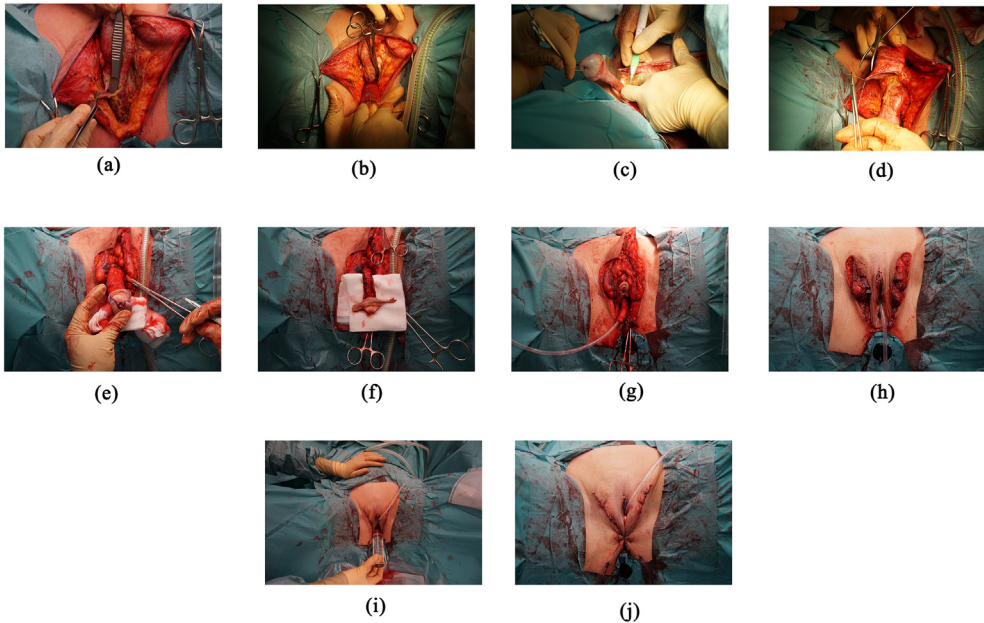


Fig. 1. Penile inversion vaginoplasty. A. Dissection of the bulbospongiosus muscle from the corpora. B. Blunt dissection of the neovaginal cavity. C. Orchiectomy. D. The penile skin is separated from the corpora. E. W-shaped marking for clitoroplasty. F. Neoclitoris and labia minora, made from the remaining skin, are dissected as a pedicled neurovascular flap to the penile base. G. The neoclitoris is fixed on the remnants of the ligated corpora. H. The penile skin flap is inverted in the neovaginal canal. I. Superfluous scrotal skin is trimmed, and all remaining wounds are sutured. J. A neovaginal tampon is placed and sutured in place.

The procedure is performed under general anesthesia, in lithotomy position and under sterile conditions with antibiotic prophylaxis. After transurethral catheterization, a midline incision is made and a triangular, dorsally based, perineoscrotal flap of approximately 2×2 cm is created. This is later used to insert in the base of the penile skin flap to prevent introital contracture. The bulbospongiosus muscle is dissected from the corpus spongiosum and left attached to its base. This muscle is not divided yet for possible use for tissue coverage in case of intraoperative rectal injury. Superfluous corpus spongiosum tissue is oversewn and removed from the urethra so that the individual does not experience a 'feeling of erection' after surgery, which may even make neovaginal access difficult. The neovaginal cavity is then created bluntly at the rectoprostatic fascia (Denonvilliers' fascia). Care is taken not to injure nearby structures, such as the rectum. A clamp with a lubricated gauze is inserted rectally to guide the surgeon in the neovaginal cavity dissection and aid visualization of a possible rectal injury. When the peritoneal fold is reached, dissection is stopped, and a temporary hemostatic gauze is placed in the neovaginal cavity.

The urethra is shortened at the adequate level, the urinary catheter is replaced, and the neomeatus is spatulated to prevent meatal stenosis. Subsequently, bilateral orchiectomy is performed at the level of the external inguinal ring after ligation of the spermatic cord. The labia minora are made out of preputial skin, leaving this attached to the neoclitoris, which is made out of the corona and part of the glans. A circumcision is marked and cut 2–3 cm from the neck of glans, with the prepuce pulled gently proximally. The penile skin is separated from the corpora digitally. When there is sufficient penile skin, the top is closed using resorbable stitches. When the penile skin quantity is insufficient, this is augmented using typically full-thickness scrotal skin grafts or a pedicled scrotal fasciocutaneous flap [5,6].

The neoclitoris is marked at the dorsal side of the glans with its base at the corona. A Satinsky clamp is placed at the base of the corpora, as a penile tourniquet, to facilitate quick dissection of the

neoclitoral complex and its neurovascular bundle, which is dissected to the penile base. The corpora cavernosa are ligated and disposed of. The neoclitoral complex and urethra are sewn into place with resorbable sutures on top of the remnants of the corpora cavernosa. The hemostatic gauze is removed from the cavity, and the cavity is checked for bleeding. The bulbospongiosus muscle is removed. Subsequently, the penile skin flap can be inverted in the neovaginal cavity. At the neoclitoral level, a skin incision is made to be able to access the neoclitoris, labia minora, and meatus. Superfluous scrotal skin is removed when shaping the labia majora. The perineoscrotal flap is inserted in the penile skin flap, and all remaining wounds are sutured. A neovaginal tampon (gauze in a condom) is inserted and fixated using a Vicryl 0 suture.

Postoperatively, the individual is generally hospitalized for 5 days, after which the neovaginal tampon and transurethral catheter are removed and dilation is started.

Outcomes

An overview of surgical outcomes of penile inversion vaginoplasty is presented in [Table 1](#). All major studies on surgical complications of penile inversion vaginoplasty are of a retrospective nature [7–16]. The mean operative time ranges between 180 and 380 min, depending on the reporting center. Intra-operative rectal injury occurs in approximately 1% of individuals. Rectoneovaginal fistulas are reported to occur in 0–2% of cases. Although they are uncommon, the consequences are severe. Not infrequently, (temporary) fecal diversion by colostomy needs to be performed to aid primary or delayed fistula repair. Revision vaginoplasty needs to be performed in 2–3% historically. The great diversity in pre- and postoperative protocols between centers, for example, with regard to postoperative dilation, the availability of a specialized pelvic floor physiotherapist, and duration of clinical follow-up, makes a direct comparison of certain outcomes, such as neovaginal stenosis rate, impossible.

With regard to quality of life and sexual health after surgery, there is consensus in literature that most transgender individuals are satisfied with the results of their genital surgery and quality of life is better compared with preoperatively [17–21]. A well-known problem is that there is no widely accepted, standardized and validated questionnaire to assess postoperative satisfaction, and this is work in progress [22]. To date, no Core Outcome Set, an agreed standardized set of outcomes, is formulated, but this will certainly be the case in the future.

Intestinal vaginoplasty

Intestinal vaginoplasty is generally performed in revision vaginoplasty cases. In our center, it is also performed in primary cases when there is a lack of sufficient penoscrotal skin, which may be present because of previous use of puberty-suppressing hormones, penile (self-)trauma, circumcision, or biological variation [23]. Specific contraindications for intestinal vaginoplasty are having a history of extensive abdominal surgery, ulcerative colitis, and intestinal malignancy. In our center, the procedure is performed by a gender surgeon simultaneously with a dedicated gastrointestinal surgeon with experience in the gender surgery field. The advantages of using an intestinal segment are adequate depth and width and self-lubricating characteristics. The disadvantages are the need for abdominal surgery and specifically intestinal anastomosis.

Surgical technique (in primary vaginoplasty cases)

In our center, the procedure is performed laparoscopically because laparoscopic surgery has less scars, less postoperative pain, less wound complications, and a shorter recovery period compared with an open procedure.

Generally speaking, the perineal part of the surgery is much like the procedure described above. For the abdominal part, see also [Fig. 2](#). Trocars are placed umbilically ($n = 1$) and, after pneumoperitoneum is achieved, in the right abdomen ($n = 2$). Generally, we use a sigmoid segment because of its diameter and anatomic proximity to the perineal site. Others may use the ileum or the ascending colon [24,25]. The sigmoid is released from its lateral adhesions diathermically. The mesosigmoid is mobilized and relevant vasculature is identified. The sigmoid is stapled distally. The sigmoid segment can be regarded as a pedicled flap on the sigmoid artery. The sigmoid arteries are branches, typically 2–4, of the inferior mesenteric artery. Subsequently, the distal sigmoid is transected to the sigmoid arterial base. In this way, the segment can be adequately mobilized to reach the

Table 1
Reported surgical outcomes in literature reporting on >100 procedures.

Author	Year	Number of included individuals	Intraoperative complications	Postoperative complications	Clinical follow-up time
Goddard et al. [7]	2007	222	Rectal injury (0.4%)	Haemorrhage (3.2%) Wound infection (16.8%) Meatal stenosis (23%) Neovaginal stenosis (6.1%) Prolapse (1.8%)	Median 56 d (range 8–351)
Reed [8].	2011	250	Rectal injury (2.8%)	Urethrovaginal fistula (0.8%) Meatal stenosis (6%) Neovaginal stenosis (1.2%) Prolapse (2.4%)	NR
Rossi Neto et al. [9]	2012	332	Rectal injury (3.3%)	Haemorrhage (3.3%) Rectovaginal fistula (1.8%) Urethrovaginal fistula (3.9%) Meatal stenosis (39.8%) Introital stenosis (14.5%) Neovaginal stenosis (12%) Prolapse (1.2%)	NR
Sigurjonsson et al. [10]	2015	205	–	Haemorrhage (10.7%) Wound infection (9.8%) Rectovaginal fistula (2%)	NR
Wangjiraniran et al. [11]	2015	395	–	Haemorrhage (3%) Wound infection (4%) Prolapse (0.3%)	NR
Buncamper et al. [12]	2016	475	Bleeding that required transfusion (4.8%) Rectal injury (2.3%) Urethral injury (1.1%)	Urinary retention (13.9%) Wound infection (4.6%) Urinary tract infection (4.4%) Meatal stenosis (9.7%) Introital stenosis (2.5%) Rectovaginal fistula (0.6%) Minor prolapse (3.8%)	Median 7.8 y (range 1–15.9)
Gaither et al. [13]	2018	330	–	Neovaginal stenosis (3%) Rectovaginal fistula (0.9%) Vesicovaginal fistula (0.9%) Wound infection (1.5%)	Median 3 months (range 3–73)
Massie et al. [14]	2018	117	–	Urinary retention (9%) Haemorrhage (10%) Urinary tract infection (7%) Neovaginal stenosis (4%) Rectovaginal fistula (2%) Prolapse (2%)	Mean 21 months (range 13–34)
Ives et al. [15]	2019	101	Bleeding that required transfusion (2%) Rectal/bladder injury (4%)	Wound infection (1%) Haemorrhage (5%) Meatal stenosis (10.9%)	NR
Maurer et al. [16]	2022	108	Bleeding that required transfusion (3.7%) Rectal injury (4.6%)	Haemorrhage (1.9%) Wound infection (18%) Urethrovaginal fistula (0.9%) Urethral necrosis (4.6%) Meatal stenosis (8.3%) Introital stenosis (9.3%) Neovaginal stenosis (14%)	Median 6.3 m. Range NR

NR not reported.

perineal site, without tension on the vascular pedicle. Using indocyanine green can help assess the perfusion of the segment [26,27].

The peritoneal fold is opened diathermically between the rectum and the bladder. When adequately mobilized and with intact vascularization, the segment is stapled proximally and transposed to the perineal site, where the genital surgeon opens the distal staple line and sutures the segment in place.

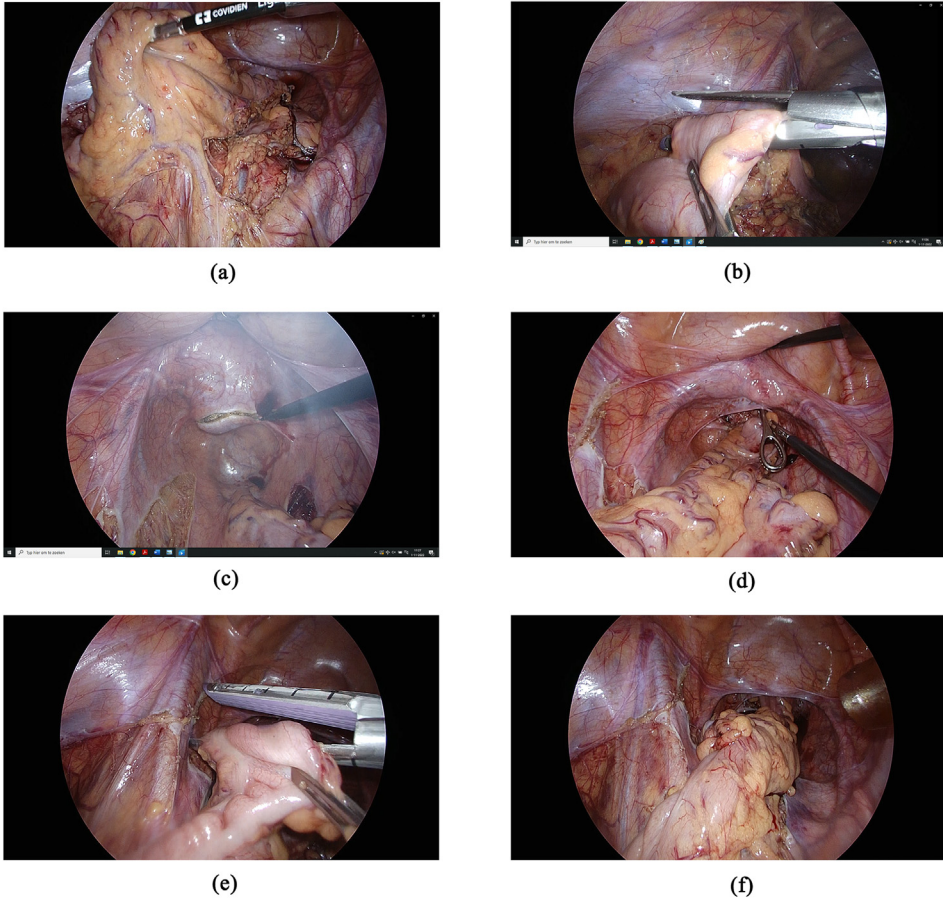


Fig. 2. Intra-abdominal part of sigmoid vaginoplasty. A. Vascularization of the pedicled segment after mobilization. B. The distal part of the segment is stapled. C. Opening of the peritoneum guided by external pressure from the genital surgeon. D. The distal part is brought to the perineal site. E. The proximal part of the segment is stapled. F. End view after fixation of the neovagina on the promontory and side-to-side anastomosis to restore intestinal continuity.

The proximal part is fixated on the promontory to prevent postoperative prolapse. Intestinal continuity is restored by side-to-side anastomosis. All wounds are closed with resorbable sutures.

Outcomes

Generally speaking, wound problems of the external genitalia formed during intestinal vaginoplasty are comparable to other vaginoplasty subtypes. When looking at the abdominal part of the surgery, sigmoid vaginoplasty seems to have a similar complication rate compared with other types of elective colorectal surgery [28–30]. Intra-abdominal complications, such as bowel segment necrosis, anastomotic leakage, ileus, or rectoneovaginal fistulas, are rare (all <1%). Introital stenosis (1–8%) is somewhat more common. Note that studies are predominantly of a retrospective nature and with a short follow-up time. In studies that do report a longer follow-up, the number of included individuals is low [31,32].

Satisfaction and quality of life after surgery are reported to be high, but again, there is a lack of quality-of-life measures and (standardized) patient-reported outcomes [30,33,34].

Long-term follow-up advice

A specific remark has to be made on the longer-term follow-up after intestinal vaginoplasty. When the sigmoid is used for this procedure, the colonocytes are subject to starvation over time as luminal nutrients from feces are no longer passing by. Subsequently, inflammatory changes occur, which is commonly described as diversion neovaginitis [35–37]. Though little is known about this clinical entity, individuals may have severe clinical symptoms, comprising pain, neovaginal bleeding, and malodor. Treatment consists of refeeding the colonocytes with topical short-chain fatty acids and/or anti-inflammatory topical drugs. A gastroenterologist may be consulted in these cases. Given that a small degree of inflammation exists in all postoperative individuals, and prolonged inflammation may lead to a higher risk of colorectal cancer, for instance, in inflammatory bowel disease patients, we advise 5-year follow-up of these individuals.

Peritoneal vaginoplasty

Using the peritoneum for vaginal reconstruction, sometimes known as the Davydov technique, is historically most frequently performed in patients with congenital vaginal absence. In the transgender population, peritoneal vaginoplasty is predominantly performed as a revision vaginoplasty procedure.

Some surgeons feel that it is, in their hands, not safe to dissect the neovaginal cavity by a perineal approach only and opt for a simultaneous laparoscopic/robotic abdominal approach to provide a better overview during the neovaginal cavity dissection [38]. In these cases, the peritoneal fold is opened and no wound surface is available for full-thickness skin grafts. Therefore, small peritoneal flaps are used as a closure cap of some centimeters at neovaginal top. This is sutured to the ends of the full-thickness skin grafts lining the vaginal wall.

In primary cases, most authors use peritoneal flaps from the anterior rectum and/or posterior bladder, which have a random vascularization pattern [39,40]. Others, as do we, use an inferiorly based flap from the parietal peritoneum of the lower abdominal wall, pedicled on the deep inferior epigastric artery and vein [41].

The advantages of this procedure are that the donor site is inconspicuous and the peritoneal tissue is hairless, well-vascularized, and potentially self-lubricating. The disadvantages are the need for intra-abdominal surgery and the fact that long-term follow-up studies on this issue are lacking. No uniform postoperative protocols are in place with regard to dilation and little is known about the outcomes and re-epithelialization of the tissue.

Revision vaginoplasty

Revision vaginoplasty is a challenging procedure. Before performing revision vaginoplasty, a thorough analysis needs to be performed to determine why the previous vaginoplasty had failed to check whether there are any factors that can be changed before commencing the next procedure such as pelvic floor hypertonicity and inadequate postoperative self-dilatation.

In particular after the use of skin grafts as neovaginal lining, redissection of the same cavity is difficult because of adhesions and scarring [42]. Therefore, there is a high (~10%) risk of intraoperative rectal injury. Approximately 20% of intraoperatively recognized and repaired rectal injuries give rise to a rectoneovaginal fistula [43]. Sometimes, (temporary) colostomy has to be performed in these cases.

With this in mind, we prefer a simultaneous intra-abdominal and perineal approach. The intra-abdominal approach, most of the time performed laparoscopically, provides a better view of the operative field, making the neovaginal removal easier and with fewer risks. However, the risk of intraoperative rectal injury and subsequently rectoneovaginal fistulas remains higher compared with primary vaginoplasty. Individuals need to be counseled on this to check whether they are able to cope with these possible complications.

What tissue is used as neovaginal lining is quite surgeon dependent. When only a perineal approach is chosen, the peritoneal fold is not opened and the neovagina can be lined using skin grafts, for example, from the groin or lower abdomen. When the peritoneal fold is opened, during an abdominal approach, skin graft vaginoplasty is no longer possible and one can either choose intestinal tissue or peritoneal flaps. Which is better is not yet determined.

Bilateral orchiectomy

In transgender women or nonbinary individuals assigned male at birth, bilateral orchiectomy, removal of both testicles, is the least-invasive option of all gGAS procedures. Some individuals opt for orchiectomy because they are not eligible for vaginoplasty, some see it as a preceding step to a future vaginoplasty procedure, and some individuals opt for orchiectomy because of the absence of genital dysphoria or motivations related to their gender identity [44]. In our center, smoking and obesity are discouraged before surgery but are not regarded as a contraindication for this procedure. After surgery, individuals can discontinue anti-testosterone treatment.

Surgical technique

Most orchiectomy procedures are performed under general anesthesia, but spinal anesthesia is also an option. A single scrotal midline incision is used, which does not hamper a possible future vaginoplasty procedure [45]. During surgery, both testicles are removed, including spermatic cords, generally onto the external inguinal ring. Local anesthesia can be given to genital branch of genitofemoral nerve intraoperatively. After hemostasis is achieved, the wound is closed in layers. Compared with other procedures, orchiectomy is less invasive and can be performed in day surgery with low postoperative analgesia.

Outcomes

Few studies report on the outcomes of bilateral orchiectomy in the transgender population [44,46]. Most individuals have no complications after surgery (91–93%). Minor complications such as haemorrhage or a scrotal abscess may arise but are generally well-treatable.

Vulvoplasty

Some transgender women or nonbinary individuals assigned male at birth opt for vulvoplasty as gGAS procedure. Vulvoplasty, sometimes known as no-depth vaginoplasty, is essentially the same procedure as a vaginoplasty procedure, but without creation and lining of a neovaginal canal, meaning that penectomy, orchiectomy, clitoroplasty, and labiaplasty are all performed. Not creating a neovaginal canal decreases the risk of intraoperative damage to the rectum or the urethra and possible subsequent sequelae, such as rectoneovaginal or urethraneovaginal fistulas [47–49].

Some individuals may opt for this procedure because of somatic reasons, for example, having a history of pelvic radiotherapy or extensive perirectal fistulas because of ulcerative colitis. Others choose this option because they do not wish to engage in penetrative neovaginal sexual intercourse after surgery or because 'having a neovaginal canal' is not a part of their individual body image. Postoperative dilation is not necessary, and the hospitalization duration is shorter.

Outcomes

Only a few studies have reported exclusively on this subpopulation. The reported postoperative complications are generally minor, such as wound dehiscence, urinary infection, or meatal stenosis. Major complications, such as rectal injuries, are not reported. When individuals do want to opt for a neovaginal canal creation after surgery, this is still possible, but we generally do not see the vulvoplasty as the first phase of a vaginoplasty procedure.

Summary

gGAS in transgender women has taken a flight compared with earlier days. There are multiple options to choose from, hopefully fitting the anatomical possibilities and individuals' treatment

desires. Looking at the vaginoplasty procedures, surgical complications are frequent but generally minor and well-treatable. Postoperative satisfaction is high. Revision vaginoplasty remains a challenge for the reconstructive surgeon. Having a multidisciplinary, dedicated, experienced surgical team seems advisable when performing all subtypes of gGAS.

Practice points

- Gender-affirming genital surgery comprises bilateral orchiectomy, gender-affirming vulvoplasty, or vaginoplasty.
- Bilateral orchiectomy is the least-invasive procedure, and there are a few postoperative complications.
- Gender-affirming vulvoplasty is the same as a vaginoplasty in which no vaginal cavity is dissected. There is little to no risk of intraoperative rectal or urethral injuries. Postoperatively, penetrative neovaginal sexual intercourse is not possible.
- Vaginoplasty is the most frequently chosen procedure. Subdivisions are made depending on the tissue type that lines the neovaginal cavity.

Research agenda

- Long-term follow-up studies on all types of outcomes are scarce.
- Though surgical outcomes are quite well-described, quality of life and satisfaction studies are hampered by nonvalidated questionnaires. Formulation and creation of these questionnaires is an important process.
- Studies are predominantly of a retrospective nature. Prospective studies should be performed in the future.
- Currently, no Core Outcome Set is formulated.
- Which tissue is best to line the neovagina in revision cases (peritoneum vs. intestinal tissue) is yet to be determined.

Declaration of competing interest

The authors have no conflicts of interest.

Acknowledgements

None.

References

- [1] Wiepjes CM, Nota NM, de Blok CJM, Klaver M, de Vries ALC, Wensing-Kruger SA, et al. The amsterdam cohort of gender dysphoria study (1972-2015): trends in prevalence, treatment, and regrets. *J Sex Med* 2018;15:582–90.
- [2] van der Sluis WB, de Nie I, Steensma TD, van Mello NM, Lissenberg-Witte BI, Bouman MB. Surgical and demographic trends in genital gender-affirming surgery in transgender women: 40 years of experience in Amsterdam. *Br J Surg* 2021; 109:8–11.
- [3] Coleman E, Radix AE, Bouman WP, Brown GR, de Vries ALC, Deutsch MB, et al. Standards of care for the health of transgender and gender diverse People, version 8. *Int J Transgend Health* 2022;23(Suppl 1):S1–259.
- [4] Brownstone LM, DeRieux J, Kelly DA, Sumlin LJ, Gaudiani JL. Body mass index requirements for gender-affirming surgeries are not empirically based. *Transgend Health* 2021;6:121–4.
- [5] Buncamper ME, van der Sluis WB, de Vries M, Witte BI, Bouman MB, Mullender MG. Penile inversion vaginoplasty with or without additional full-thickness skin graft: to graft or not to graft? *Plast Reconstr Surg* 2017;139:649e–56e.

- [6] Nijhuis THJ, Özer M, van der Sluis WB, Al-Tamini M, Salim A, Thomas P, et al. The bilateral pedicled epilated scrotal flap: a powerful adjunctive for creation of more neovaginal depth in penile inversion vaginoplasty. *J Sex Med* 2020;17:1033–40.
- [7] Goddard JC, Vickery RM, Qureshi A, Summerton DJ, Khoosal D, Terry TR. Feminizing genitoplasty in adult transsexuals: early and long-term surgical results. *BJU Int* 2007;100:607613.
- [8] Reed HM. Aesthetic and functional male to female genital and perineal surgery: feminizing vaginoplasty. *Semin Plast Surg* 2011;25:163174.
- [9] Rossi Neto R, Hintz F, Krege S, Rubben H, Vom Dorp F. Gender reassignment surgery: a 13 year review of surgical outcomes. *Int Braz J Urol* 2012;38:97107.
- [10] Sigurjonsson H, Rinder J, Möllermark C, Farneboa F, Lundgren TK. Male to female gender reassignment surgery: surgical outcomes of consecutive patients during 14 years. *JPRAS Open* 2015;6:6973.
- [11] Wangjiraniran B, Selvaggi G, Chokrungravanont P, Jindarak S, Khobunsongserm S, Tiewtranon P. Male-to-female vaginoplasty: precha's surgical technique. *J Plast Surg Hand Surg* 2015;49:153159.
- [12] Buncamper ME, van der Sluis WB, van der Pas RSD, Özer M, Smit JM, Witte BI, et al. Surgical outcome after penile inversion vaginoplasty: a retrospective study of 475 transgender women. *Plast Reconstr Surg* 2016;138:999–1007.
- [13] Gaither TW, Awad MA, Osterberg EC, Murphy GP, Romero A, Bowers ML, et al. Postoperative complications following primary penile inversion vaginoplasty among 330 male-to-female transgender patients. *J Urol* 2018;199:760–5.
- [14] Massie JP, Morrison SD, Van Maasdam J, Satterwhite T. Predictors of patient satisfaction and postoperative complications in penile inversion vaginoplasty. *Plast Reconstr Surg* 2018;141:911e–21e.
- [15] Ives GC, Fein LA, Finch L, Sluiter EC, Lane M, Kuzon WM, et al. Evaluation of BMI as a risk factor for complications following gender-affirming penile inversion vaginoplasty. *Plast Reconstr Surg Glob Open* 2019;7:e2097.
- [16] Maurer V, Howaldt M, Feldmann I, Ludwig T, Vetterlein MW, Gild P, et al. Penile flap inversion vaginoplasty in transgender women: contemporary morbidity and learning-curve analysis from a high-volume reconstructive center. *Front Surg* 2022;9:836335.
- [17] Özer M, Toulabi SP, Fisher AD, T'Sjoen G, Buncamper ME, Monstrey S, et al. ESSM position statement "sexual wellbeing after gender affirming surgery". *Sex Med* 2022;10:100471.
- [18] Horbach SE, Bouman MB, Smit JM, Özer M, Buncamper ME, Mullender MG. Outcome of vaginoplasty in male-to-female transsexuals: a systematic review of surgical techniques. *J Sex Med* 2015;12:1499–512.
- [19] Buncamper ME, Honselaar JS, Bouman MB, Özer M, Kreukels BP, Mullender MG. Aesthetic and functional outcomes of neovaginoplasty using penile skin in male-to-female transsexuals. *J Sex Med* 2015;12:1626–34.
- [20] Hontscharuk R, Alba B, Hamidian Jahromi A, Schechter L. Penile inversion vaginoplasty outcomes: complications and satisfaction. *Andrology* 2021;9:1732–43.
- [21] Papadopoulos NA, Lellé JD, Zavlin D, Herschbach P, Henrich G, Kovacs L, et al. Quality of life and patient satisfaction following male-to-female sex reassignment surgery. *J Sex Med* 2017;14:721–30.
- [22] Klassen AF, Kaur M, Johnson N, Kreukels BP, McEvenue G, Morrison SD, et al. International phase I study protocol to develop a patient-reported outcome measure for adolescents and adults receiving gender-affirming treatments (the GENDER-Q). *BMJ Open* 2018;8:e025435.
- [23] Bouman MB, Buncamper ME, van der Sluis WB, Meijerink WJ. Total laparoscopic sigmoid vaginoplasty. *Fertil Steril* 2016;106:e22–3.
- [24] van der Sluis WB, Pavan N, Liguori G, Bucci S, Bizic MR, Kojovic V, et al. Ileal vaginoplasty as vaginal reconstruction in transgender women and patients with disorders of sex development: an international, multicentre, retrospective study on surgical characteristics and outcomes. *BJU Int* 2018;121:952–8.
- [25] Garcia MM, Shen W, Zhu R, Stettler I, Zaliznyak M, Barnajian M, et al. Use of right colon vaginoplasty in gender affirming surgery: proposed advantages, review of technique, and outcomes. *Surg Endosc* 2021;35:5643–54.
- [26] van der Sluis WB, Bouman MB, Al-Tamimi M, Meijerink WJ, Tuijnman JB. Real-time indocyanine green fluorescent angiography in laparoscopic sigmoid vaginoplasty to assess perfusion of the pedicled sigmoid segment. *Fertil Steril* 2019;112:967–9.
- [27] Flor-Lorente B, Rosciano JG, Pérez-Pérez T, Sancho-Muriel J, García-Granero Á, Nohales-Alfonso FJ, et al. Gender dysphoria: laparoscopic sigmoid vaginoplasty. Another utility of indocyanine green. *Colorectal Dis* 2021 Dec;23(12):3272–5.
- [28] Bouman MB, van der Sluis WB, Buncamper ME, Özer M, Mullender MG, Meijerink WJH. Primary total laparoscopic sigmoid vaginoplasty in transgender women with penoscrotal hypoplasia: a prospective cohort study of surgical outcomes and follow-up of 42 patients. *Plast Reconstr Surg* 2016;138:614e–23e.
- [29] Salgado CJ, Nugent A, Kuhn J, Janette M, Bahna H. Primary sigmoid vaginoplasty in transwomen: technique and outcomes. *BioMed Res Int* 2018;4907208. 2018.
- [30] Bouman MB, van Zeijl MC, Buncamper ME, Meijerink WJ, van Bodegraven AA, Mullender MG. Intestinal vaginoplasty revisited: a review of surgical techniques, complications, and sexual function. *J Sex Med* 2014;11:1835–47.
- [31] Morrison SD, Satterwhite T, Grant DW, Kirby J, Laub Sr DR, VanMaasdam J. Long-term outcomes of rectosigmoid neocolporrhaphy in male-to-female gender reassignment surgery. *Plast Reconstr Surg* 2015;136:386–94.
- [32] van der Sluis WB, Bouman MB, de Boer NK, Buncamper ME, van Bodegraven AA, Neeffjes-Borst EA, et al. Long-term follow-up of transgender women after secondary intestinal vaginoplasty. *J Sex Med* 2016;13:702–10.
- [33] Bouman MB, van der Sluis WB, van Woudenberg Hamstra LE, Buncamper ME, Kreukels BPC, Meijerink WJH, et al. Patient-reported esthetic and functional outcomes of primary total laparoscopic intestinal vaginoplasty in transgender women with penoscrotal hypoplasia. *J Sex Med* 2016;13:1438–44.
- [34] di Summa PG, Watfa W, Krähnenbühl S, Schaffer C, Raffoul W, Bauquis O. Colic-based transplant in sexual reassignment surgery: functional outcomes and complications in 43 consecutive patients. *J Sex Med* 2019;16:2030–7.
- [35] van der Sluis WB, Bouman M, Meijerink W, Neeffjes-Borst EA, van Bodegraven AA. Refractory diversion neovaginitis in a sigmoid-colon-derived neovagina: clinical and histopathological considerations. *Frontline Gastroenterol* 2016;7:227–30.
- [36] van der Sluis WB, Neeffjes-Borst EA, Bouman MB, Meijerink WJ, De Boer NK, Mullender MG, et al. Morphological spectrum of neovaginitis in autologous sigmoid transplant patients. *Histopathology* 2016;68:1004–12.
- [37] van der Sluis WB, Bouman MB, Meijerink WJH, Elfering L, Mullender MG, de Boer NKH, et al. Diversion neovaginitis after sigmoid vaginoplasty: endoscopic and clinical characteristics. *Fertil Steril* 2016;105:834–839.e1.

- [38] Dy GW, Jun MS, Blasdel G, Bluebond Langner R, Zhao LC. Outcomes of gender affirming peritoneal flap vaginoplasty using the da vinci single port versus xi robotic systems. *Eur Urol* 2021;79:676–83.
- [39] Salibian AA, Schechter LS, Kuzon WM, Bouman MB, van der Sluis WB, Zhao LC, et al. Vaginal canal reconstruction in penile inversion vaginoplasty with flaps, peritoneum, or skin grafts: where is the evidence? *Plast Reconstr Surg* 2021;147:634e–43e.
- [40] Castanon CDG, Matic S, Bizic M, Stojanovic B, Bencic M, Gruber N, et al. Laparoscopy assisted peritoneal pull-through vaginoplasty in transgender women. *Urology* 2022;166:301–2.
- [41] Smith SM, Yuan N, Stelmar J, Pa-C GL, Gupta A, Kim HL, et al. An alternative option for gender-affirming revision vaginoplasty: the tubularized urachus-peritoneal hinge flap. *Sex Med* 2022;10:100572.
- [42] Van der Sluis WB, Bouman MB, Buncamper ME, Mullender MG, Meijerink WJ. Revision vaginoplasty: a comparison of surgical outcomes of laparoscopic intestinal versus perineal full-thickness skin graft vaginoplasty. *Plast Reconstr Surg* 2016;138:793–800.
- [43] van der Sluis WB, Bouman MB, Buncamper ME, Pigot GLS, Mullender MG, Meijerink WJHJ. Clinical characteristics and management of neovaginal fistulas after vaginoplasty in transgender women. *Obstet Gynecol* 2016;127:1118–26.
- [44] Van der Sluis WB, Steensma TD, Bouman MB. Orchiectomy in transgender individuals: a motivation analysis and report of surgical outcomes. *Int J Transgend Health* 2020;21:176–81.
- [45] Francis C, Grober E, Potter E, Blodgett N, Krakowsky Y. A simple guide for simple orchiectomy in transition-related surgeries. *Sex Med Rev* 2020;8:492–6.
- [46] Hana T, Raveendran L, Grober E, Potter E, Blodgett N, Krakowsky Y. Initial clinical experience with simple orchiectomy procedures in the context of transition-related surgeries. *Int J Transgend Health* 2020;21:403–9.
- [47] van der Sluis WB, Steensma TD, Timmermans FW, Smit JM, de Haseth K, Özer M, et al. Gender-confirming vulvoplasty in transgender women in The Netherlands: incidence, motivation analysis, and surgical outcomes. *J Sex Med* 2020;17:1566–73.
- [48] Milrod C, Monto M, Karasic DH. Recommending or rejecting "the dimple": WPATH-affiliated medical professionals' experiences and attitudes toward gender-confirming vulvoplasty in transgender women. *J Sex Med* 2019;16:586–95.
- [49] Jiang D, Witten J, Berli J, Dugi 3rd D. Does depth matter? Factors affecting choice of vulvoplasty over vaginoplasty as gender-affirming genital surgery for transgender women. *J Sex Med* 2018;15:902–6.